



# High cure rate and satisfaction in patients with periductal mastitis via the latissimus dorsi myocutaneous flap technique: a retrospective study

Lihui Pan, Huifen Zhen, Miaomiao Jia, Chao Ding, Xiaojun Zhang, Jinnan Gao, Fan Guo

Department of Breast Surgery, The Third Hospital of Shanxi Medical University, Shanxi Bethune Hospital (Tongji Hospital of Shanxi), Taiyuan, China

*Contributions:* (I) Conception and design: F Guo; (II) Administrative support: J Gao; (III) Provision of study materials or patients: H Zhen, X Zhang, M Jia, C Ding; (IV) Collection and assembly of data: L Pan; (V) Data analysis and interpretation: L Pan, H Zhen; (VI) Manuscript writing: All authors; (VII) Final approval of manuscript: All authors.

*Correspondence to:* Fan Guo, MMed. Department of Breast Surgery, The Third Hospital of Shanxi Medical University, Shanxi Bethune Hospital (Tongji Hospital of Shanxi), No. 99 Longcheng Street, Xiaodian District, Taiyuan 030032, China. Email: guofanhe@163.com.

**Background:** Periductal mastitis (PDM) is a complex benign breast disease with a prolonged course and a high probability of recurrence after treatment. There is a variety of available treatments for PDM, but none of these options have been widely accepted. A standard strategy has been especially difficult to establish in patients with PDM accompanied by large tumors or large skin ruptures, as these seriously affect the appearance of the breasts after surgeries, which can lead to feelings of lower self-esteem among patients. Therefore, finding a reliable volume replacement has become a focus of our research efforts. With the widespread use of latissimus dorsi in breast reconstruction, we attempted to use the latissimus muscle (skin) flap for stage I repair in patients with large-defect PDM. Our study is the first of its kind to evaluate the clinical effect and patient satisfaction of the latissimus dorsi myocutaneous flap (LDMF) technique in PDM.

**Methods:** Thirty-two patients with PDM and more than about 20% loss of breast volume admitted to the Department of Breast Surgery of Shanxi Bethune Hospital from March 2017 to July 2021 were enrolled. After lesion removal, the LDMF technique was applied to these patients for immediate completion of breast contour revision. All patients were periodically followed up to assess the efficacy of the procedure and their satisfaction with the breasts' shape.

**Results:** Three patients (9.4%) developed dorsal effusion after removal of the back drain; six patients (18.8%) developed mild limitation of the activity of the affected upper limb; and three patients (9.4%) experienced local recurrence of inflammation after the operation, all of whom underwent a second operation. The cure rate of the patients treated with LDMF was 90.6%, the overall satisfaction rate of the patients was 96.9%, and doctor's evaluation of satisfaction was 90.6%.

**Conclusions:** In patients with poor results after anti-infective and local treatment and those with more than 20% defect volume following lesion removal, the LDMF technique yields a high cure rate and good patient satisfaction.

**Keywords:** Periductal mastitis (PDM); latissimus dorsi muscle; complications; satisfaction

Submitted Nov 25, 2023. Accepted for publication Apr 18, 2024. Published online Jun 21, 2024.

doi: 10.21037/gs-23-484

View this article at: <https://dx.doi.org/10.21037/gs-23-484>

## Introduction

Periductal mastitis (PDM), defined as a form of nonlactating mastitis (NLM) in which inflammation of the duct is present under the areola, occurs in the nonlactation period, primarily affects young women, and has an unknown pathogenesis. The extent of lesion involvement in PDM varies (1). In clinical practice, the use of antibiotics, surgical incision, and drainage of abscesses are the main methods of treatment. When there is failure of conservative management, surgery may be required, and thorough removal the lesion is the key to preventing recurrence. A defect exceeding 20% of the breast volume can often lead to the destruction of the breast shape after surgery (2). The latissimus dorsi is the largest flat muscle in human body and is often harvested to repair various defects of the superficial organs. With the extensive development of breast cancer plastic surgery and breast-conserving surgery, tissue replacement repair with latissimus dorsi myocutaneous flap (LDMF) has achieved good results in patients with more than 20% defects of the superficial organs (3,4).

In our study, the LDMF technique was used for one-stage breast repair in patients with poor clinical effects of conservative treatment and more than 20% defect volume. The common influencing factors of PDM were analyzed, and regular follow-up was conducted to evaluate the efficacy of LDMF and patient satisfaction with its outcome.

### Highlight box

#### Key findings

- For patients with poor results after anti-infective and local treatment and those with more than 20% defect volume after lesion removal, application of the latissimus dorsi myocutaneous flap (LDMF) technique could achieve a high cure rate and patient satisfaction.

#### What is known and what is new?

- The latissimus dorsi is the largest flat muscle in the human body and is often harvested to repair various defects of superficial organs. Among patients with periductal mastitis, a defect exceeding 20% volume of the breast volume often leads to the destruction of the breast shape after surgery.
- We evaluated the clinical effect and satisfaction of LDMF technique in patients with periductal mastitis.

#### What is the implication, and what should change now?

- The use of LDMF for one-stage repair after surgery in patients with mastitis and large defects is safe and effective and can significantly improve the cure rate of mastitis while providing better patient satisfaction.

We present this article in accordance with the STROBE reporting checklist (available at <https://gs.amegroups.com/article/view/10.21037/ggs-23-484/rc>).

## Methods

### General information

Our study collected the clinicopathological data of 32 patients admitted to the Breast Surgery Department of Shanxi Bethune Hospital from March 2017 to July 2021 who received quadrantectomy and immediate reconstruction with the LDMF technique. All included patients were confirmed to have PDM via paraffin pathology before surgery. The age range of patients was 20–50 years, and the average age was 32.9 years. The course of disease lasted from about 1 week to 12 months, with an average course of 2.3 months. All the enrolled patients underwent routine tests such as double breast and axillary lymph node color ultrasound examination and blood routine examination. Before and after the operation, pus bacteria culture and drug sensitivity tests were performed. The exclusion criteria for patients were the following: (I) other breast diseases such as benign and malignant breast tumors; (II) complete cure after anti-infection or local incision and drainage; (III) other surgical methods used to repair breast defects; (IV) Incomplete clinical data; (V) loss to follow-up; and (VI) two-stage reconstruction. This study was conducted in accordance with the Declaration of Helsinki (as revised in 2013) and was approved by the ethics committee of Shanxi Bethune Hospital (No. YXLL-2024-047). Informed consent was obtained from all the patients.

### Treatment

#### Preoperative preparation

After admission, a comprehensive medical history of each patient was collected, and breast ultrasound and/or mammography were completed (for women over 40 years old or less than 40 years old but with an ultrasound report of Breast Imaging-Reporting and Data System category 4B or above). After local anesthesia of lidocaine was administered, 14 G air-core needle puncture was completed under ultrasound guidance, and the specimens were sent for pathological examination, culture, and antimicrobial sensitivity testing. First-generation cephalosporin anti-infection treatment was temporarily given as routine practice, and antibiotics administration was adjusted

according to the drug sensitivity results. After five to seven days of conservative treatment, the patient's condition was further evaluated with breast ultrasound. The patients whose defect volume exceeded 20% were included in our study.

### Surgical procedure

- (I) Lesion excision: Before the operation, patients were photographed in a standing position, tilting 45 degrees and 90 degrees bilaterally; the long and short diameters of the lesion were marked; and the distal and proximal distances of the lesion from the stopping point of the latissimus dorsi muscle in the axilla were measured. Following this, the bilateral lower breast crease, the nipple at the intersection of the midclavicular line and the lower crease, the anterior border of the latissimus dorsi muscle, and the subscapularis angle line were marked. The island of the LDMF was then designated as the area of the flap. After general anesthesia was applied, the patient was placed on the side of their healthy breast, with the affected side facing up. First, after the inflammatory lesion was resected, the trauma cavity was rinsed with hydrogen peroxide, saline, and iodine. Before the operative area was sterilized again, gloves and instruments were refreshed, and a tunnel running in the axillary direction was made.
- (II) Preparation of the LDMF: According to the flap designed in advance, an elliptical incision was made on the back near the breast lesion, and the subcutaneous tissue was then incised diagonally to the distal end of the first incision. The anterior edge of the latissimus dorsi muscle was then freed, and the anterior edge of the latissimus dorsi muscle was located and freed downward and posteriorly. The lower, inner, and outer sides of the myocutaneous flap were also completely free, and the myocutaneous flap was then dissected in the direction of the armpit so that the descending branch of the thoracodorsal blood vessels could be located. Care was taken to protect the important branches. Subsequently, the descending branch of the dorsal thoracic blood vessels was found and protected, the upper part of the inner part of the flap along the descending branch was dissected, and the end point of the latissimus dorsi muscle was partially dissected.
- (III) Repair and contouring: The myocutaneous flap was transferred from the axillary tunnel to the

affected breast defect. The operative cavity of the back was washed with sterilized water, hemostasis was performed, negative pressure drainage was established, the lateral crease was reshaped, and the incision was closed according to the layers of sutures. The flap was folded and shaped according to the natural form of the opposite breast, a drain was placed, and the incision was closed. All incisions were resterilized and covered.

### Follow-up

After operation, a plastic bra was immediately bound and fixed, antibiotics were administered for five to seven days according to the drug sensitivity results, wound dressing was changed regularly, and negative pressure drainage was continued in the operation cavity. The drainage tube was removed when the drainage volume was less than 15 mL for three consecutive days. Routine outpatient reexaminations were conducted (three months and six months after operation). Cure was considered to be no recurrence within six months after the operation.

### Evaluation of satisfaction

The evaluation of satisfaction was conducted six months after the operation. To conduct a two-way evaluation of satisfaction with the aesthetic effect of the repaired breasts according to the patients with PDM and breast surgeons, we used the Harris standard, which consists of four grades: excellent, good, average, and poor.

### Statistical analysis

SPSS 27.0 software (IBM Corp., Armonk, NY, USA) was used to analyze all data. Count data are expressed as numbers and percentages, and measurement data are expressed as the mean and range. In this study, only three patients experienced local recurrence and underwent a second operation on the same side of the breast. The endpoint events and sample size were thus small, and therefore there was no further multifactor or single-factor analysis conducted for the influencing factors of recurrence and second operation.

## Results

### *Clinical characteristics of patients*

From March 2017 to July 2021, 32 patients with PDM

**Table 1** Basic clinical characteristics

Clinicopathologic features	Cases (%)
Onset age (years)	
≤30	9 (28.1)
>30 and ≤40	20 (62.5)
>40	3 (9.4)
Duration of illness (months)	
≤1	17 (53.1)
>1 and ≤3	10 (31.3)
>3 and ≤6	3 (9.4)
>6	2 (6.3)
Location of lesion	
Left	19 (59.4)
Right	13 (40.6)
Lesion quadrant	
Outer upper	3 (9.4)
Outer lower	3 (9.4)
Inner upper	3 (9.4)
Inner lower	1 (3.1)
Central area	3 (9.4)
Outer upper + outer lower	3 (9.4)
Inner upper + inner lower	5 (15.6)
Inner upper + outer upper	4 (12.5)
Inner lower + outer lower	5 (15.6)
Outer upper + central area	1 (3.1)
Outer lower + central area	1 (3.1)
Nipple invagination	
Left	8 (25.0)
Right	8 (25.0)
None	16 (50.0)
Breastfeeding	
Left	2 (6.3)
Right	6 (18.8)
Left + right	22 (68.8)
None	2 (6.3)
Breastfeeding time (months)	
≤18	18 (56.3)
>18	12 (37.5)
None	2 (6.3)

**Table 1** (continued)**Table 1** (continued)

Clinicopathologic features	Cases (%)
Smoking history	
Yes	1 (3.1)
No	31 (96.9)
Second-hand smoke	
Yes	14 (43.8)
No	18 (56.3)
WBC count (10 <sup>9</sup> /L)	
≤9.5	24 (75.0)
>9.5	8 (25.0)
Neutrophil (%)	
≤75	25 (78.1)
>75	7 (21.9)
Preoperative anti-infection (days)	
≤7	29 (90.6)
>7	3 (9.4)
Postoperative anti-infection (days)	
≤7	24 (75.0)
>7	8 (25.0)

WBC, white blood cell.

underwent immediate repair with the LDMF technique. Among these patients, 19 (59.4%) had left mastitis and 13 (40.6%) had right mastitis; in addition, 13 (40.6%) had lesions in the same quadrant, and 19 (59.4%) had lesions in different quadrants. Of the 32 patients, 16 had combined nipple inversion (50.0%), 2 patients were not breastfeeding (6.3%), 1 patient had a history of smoking (3.1%), and 14 patients had a history of secondhand smoke exposure (43.8%). Moreover, eight (25.0%) patients had elevated infection-related markers (absolute and percentage of white blood cell count and/or neutrophils) on admission, all of whom were treated with anti-inflammatory therapy before and after surgery. The hospital length of stay ranged from 9 to 25 days, with an average of 14.2 days. The cost of surgery ranged from CNY ¥5,880 to CNY ¥12,923, and the average cost of surgery was CNY ¥8,689.7 (Table 1).

### Postoperative complications

The mean postoperative follow-up time was 14.0 months (3.0–54.0 months). The mean duration of drainage in the

**Table 2** Complications and satisfaction after surgery

Complications and satisfaction	Cases (%)
Back effusion	
Yes	3 (9.4)
No	29 (90.6)
Limited movement of affected arm	
Yes	6 (18.8)
No	26 (81.3)
Local recurrence	
Yes	3 (9.4)
No	29 (90.6)
Contralateral mastitis	
Yes	2 (6.3)
No	30 (93.8)
Secondary operation	
Yes	3 (9.4)
No	29 (90.6)
Satisfaction (patients)	
Poor	1 (3.1)
Average	3 (9.4)
Good	11 (34.4)
Excellent	17 (53.1)
Satisfaction (physician)	
Poor	3 (9.4)
Average	0
Good	0
Excellent	29 (90.6)

breast cavity after surgery was 7.1 days (5–9 days), and the mean duration of drainage in the back cavity was 18.0 days (6–35 days). Among the 32 patients included in our study, 3 (9.4%) developed dorsal effusion after removal of the back drain, 6 (18.8%) developed mild limitation in the mobility of the upper limb of the affected side, 3 (9.4%) developed local recurrence of inflammation in the affected breast after the operation, and 3 received a second operation, of whom 2 (6.3%) only underwent local debridement and suturing for the lesion and 1 (3.1%) underwent mastectomy because the recurrent area accounted for more than 50% of the whole affected breast. This patient and her family were fully

informed of the condition and the risk of recurrence, and they strongly requested total mastectomy, and after signing the informed consent, the patient underwent the surgery. Moreover, two patients (6.3%) experienced contralateral mastitis at four and eight months after surgery, respectively (Table 2).

### Postoperative evaluation of satisfaction

In the study, the Harris standard was used to evaluate the aesthetic effect of the repaired breasts. One patient (3.1%) indicated poor satisfaction with the shape of the repaired breast, three patients (9.4%) indicated average satisfaction, eleven patients (34.4%) indicated good satisfaction, and seventeen patients (53.1%) indicated excellent satisfaction. The overall satisfaction rate of patients was 96.9%, and that of the breast surgeons was 90.6% (Table 2).

### Discussion

PDM is a chronic benign breast disease characterized by ductal dilatation of the breast accompanied by infiltration of inflammatory cells such as plasma cells and lymphocytes; it is also known as *duct ectasia* or *plasma cell mastitis* and is occasionally referred to as *obliterative mastitis* (5). PDM accounts for about 0.3% to 5% of benign breast diseases, with the majority of patients being women of childbearing age. The onset age ranges from 25 to 46 years old, and the disease is rare among men (6). The incidence of the PDM in China is about 1.9% to 5.0% but has recently risen significantly, occurring in women of all ages after puberty. The reported average age of onset of PDM ranges from 34 to 46 years old, with 64% of patients being younger than 40 years old (7). In the present study, the mean age was 32.9 years old, which is younger than that reported for China.

PDM is a type of autoimmune disease (8) whose occurrence is related to lactation and infection factors (especially *Corynebacterium kroppenstedtii* infection). Other possible factors include trauma, obesity, hormone levels in the body, oral contraceptives, and ethnicity, among others (9), with one study also identifying smoking as an important risk factor (10). It is speculated that smoking is related to the damage of the duct under the areola. Oltean *et al.* recommend that smoking patients with recurrent PDM should quit smoking for six weeks before the second operation in order to ensure better cure (11). In our study, 1 patient had a history of smoking (3.1%), and 15 patients

had a history of secondhand smoke exposure (43.7%). Therefore, it is necessary to strengthen smoking cessation education. Previous studies have also confirmed that nipple dysplasia, breast structure disorders (12), congenital nipple inversion (13), lactation disorder, breast duct blockage, etc., may be factors influencing the emergence of PDM (14). Of the 32 patients in our study, 16 had inverted nipple or nipple retraction (50.0%) and 2 were not breastfeeding (6.3%). Hence, it is strongly recommended that women of childbearing age should have their breast development assessed before pregnancy, take timely and effective corrective measures, and strengthen their knowledge of breastfeeding and breastfeeding skills. The patients who attended our hospital for mastitis were generally late in diagnosis and had severe damage to the breast tissue: 31 had 20–50% volume destruction, and 1 had 50% volume destruction.

Although PDM is a benign disease, the effect of routine use of antibacterial drugs is poor. The recurrence rate after traditional treatment ranges from 2% to 50%. Moreover, first-generation cephalosporins may be a suboptimal choice, as they may not adequately treat infection of anaerobic bacteria. On the other hand, cephalosporins can be administered together with an antibiotic for anaerobic infections, such as metronidazole. Considering a mixed aerobic-anaerobic infection, another option is the administration of antimicrobials that are active against both components. The abscess in patients with PDM is susceptible to repeated bursting, sinus formation, and fistula or ulcer, which seriously damages the integrity of breast tissue and breast function and seriously affects the physical and mental health of patients (1). Zhou *et al.* compared the use of ultrasound-guided microwave ablation for traditional surgery in PDM treatment and found that microwave ablation was a more effective treatment than traditional surgery in terms of postoperative pain, wound healing, and breast appearance (15). However, for patients with large lesions, surgery is still the main treatment method for PDM at present. In the acute stage of inflammation, broad-spectrum antibacterial drugs should be used to control the disease and alleviate the general condition of patients, and timely surgical intervention should be performed. The principle of surgery is to completely remove all the pathological tissues visible to the naked eye and ensure that the margin is negative to achieve cure. Nevertheless, it is difficult to provide a relatively good appearance of the breast after the traditional abscess incision, drainage, or quadrant resection, which may even cause breast abnormalities and

seriously burden patients with adverse psychological effects.

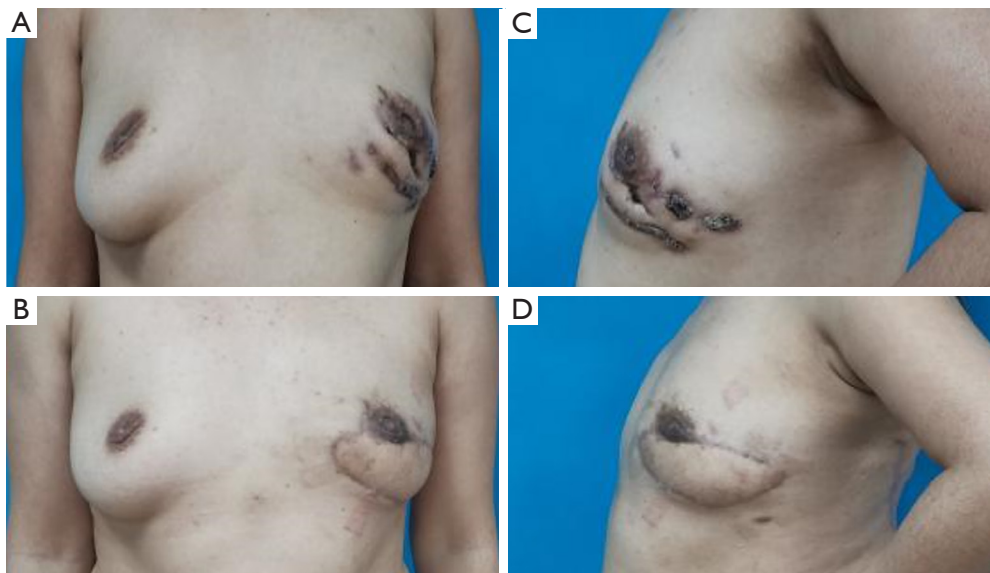
The LDMF is currently one of the most widely used flaps for breast reconstruction, chest wall coverage, and other procedures (16,17). The latissimus dorsi muscle has certain advantages for breast repair. In addition to stable survival, it has considerable thickness, which can successfully repair breast defects and replace the role of the pectoralis major muscle in providing adequate blood nutrition for adjacent tissue structures. In this regard, the LDMF has also been used to repair previously irradiated breasts (18), and fat-augmented latissimus dorsi (FALD) autologous reconstruction is superior to latissimus dorsi-plus-implant reconstruction for those women subjected to irradiation (19,20). Since its advantages in breast reconstruction were first described by Tansini in 1906 (21), LDMF has been widely used in breast reconstruction, achieving effective individualized treatment. Although the study by Xu *et al.* showed that immediate breast reconstruction of mastitis may increase the risk of infection (22), to our knowledge, there is no record of using this reconstruction technique in the treatment of mastitis. Our team used the latissimus dorsi muscle (skin) flap for immediate breast repair after mastitis surgery. After follow-up, the cure rate of mastitis reached 90.6%, the overall satisfaction of patients was 96.9%, the satisfaction of doctors was 90.6%, and the secondary operation rate was only 9.4%. It is important to note that this is an extensive surgery for the treatment of a benign condition, and despite good results, is not free from complications.

### Limitations

The limitations of this study are the small number of cases and the short follow-up period. Furthermore, the findings of our study may not be generalizable to other populations. Therefore, further studies are needed to demonstrate the safety and efficacy of this surgical procedure.

### Conclusions

This study confirmed that the use of the LDMF technique for one-stage repair after surgery in patients with PDM with large defects is safe, can significantly improve the cure rate of mastitis, and can obtain better patient and physician satisfaction. Moreover, the back drainage time is not longer than that of the traditional abscess incision. The novel method may thus represent a breakthrough in the surgical treatment of mastitis (*Figure 1*).



**Figure 1** Breast appearance pre- and postoperation (A,C: 1 day before surgery; B,D: 3 months after surgery).

## Acknowledgments

*Funding:* None.

## Footnote

*Reporting Checklist:* The authors have completed the STROBE reporting checklist. Available at <https://gs.amegroups.com/article/view/10.21037/gS-23-484/rc>

*Data Sharing Statement:* Available at <https://gs.amegroups.com/article/view/10.21037/gS-23-484/dss>

*Peer Review File:* Available at <https://gs.amegroups.com/article/view/10.21037/gS-23-484/prf>

*Conflicts of Interest:* All authors have completed the ICMJE uniform disclosure form (available at <https://gs.amegroups.com/article/view/10.21037/gS-23-484/coif>). The authors have no conflicts of interest to declare.

*Ethical Statement:* The authors are accountable for all aspects of the work in ensuring that questions related to the accuracy or integrity of any part of the work are appropriately investigated and resolved. This study was conducted in accordance with the Declaration of Helsinki (as revised in 2013) and was approved by the ethics committee of Shanxi Bethune Hospital (No. YXLL-2024-047).

Informed consent was obtained from all the patients.

*Open Access Statement:* This is an Open Access article distributed in accordance with the Creative Commons Attribution-NonCommercial-NoDerivs 4.0 International License (CC BY-NC-ND 4.0), which permits the non-commercial replication and distribution of the article with the strict proviso that no changes or edits are made and the original work is properly cited (including links to both the formal publication through the relevant DOI and the license). See: <https://creativecommons.org/licenses/by-nc-nd/4.0/>.

## References

1. Xu H, Liu R, Lv Y, et al. Treatments for Periductal Mastitis: Systematic Review and Meta-Analysis. *Breast Care (Basel)* 2022;17:55-62.
2. Dalci K, Gumus S, Saritas AG, et al. Modified techniques versus Hadfield's procedure in patients with periductal mastitis. *BMC Surg* 2022;22:40.
3. Javeed S, Naeem MS, Awais M, et al. Outcome of modified fleur-de-lis latissimus dorsi myocutaneous flap for breast reconstruction *Asian J Surg* 2024;47:2161-7.
4. Kim H, Eo P, Ryu JY, et al. Boomerang latissimus dorsi flap in immediate or delayed breast reconstruction. *Gland Surg* 2023;12:894-904.
5. Xing M, Zhang S, Zha X, et al. Current Understanding and Management of Plasma Cell Mastitis: Can We Benefit

- from What We Know? *Breast Care (Basel)* 2022;17:321-9.
6. Jiao Y, Chang K, Jiang Y, et al. Identification of periductal mastitis and granulomatous lobular mastitis: a literature review. *Ann Transl Med* 2023;11:158.
  7. Zhou F, Liu L, Yu Z. Expert consensus on diagnosis and treatment of non-lactation mastitis. *Chinese Journal of Practical Surgery* 2016;36:755-8.
  8. Zhang HJ, Ding PP, Zhang XS, et al. MAC mediates mammary duct epithelial cell injury in plasma cell mastitis and granulomatous mastitis. *Int Immunopharmacol* 2022;113:109303.
  9. Zeng Y, Zhang D, Zhao W, et al. Predisposing Factors for Granulomatous Lobular Mastitis: A Case-Control Study. *Int J Womens Health* 2023;15:1063-75.
  10. Sarkar DK, Banerjee R, Gupta S, et al. Management of idiopathic granulomatous mastitis: a prospective study. *Ann R Coll Surg Engl* 2023;105:218-24.
  11. Oltean HN, Soliman AS, Omar OS, et al. Risk factors for chronic mastitis in morocco and egypt. *Int J Inflamm* 2013;2013:184921.
  12. Zhang Y, Zhou Y, Mao F, et al. Clinical characteristics, classification and surgical treatment of periductal mastitis. *J Thorac Dis* 2018;10:2420-7.
  13. Yukun L, Ke G, Jiaming S. Application of Nipple Retractor for Correction of Nipple Inversion: A 10-Year Experience. *Aesthetic Plast Surg* 2016;40:707-15.
  14. Aghajanzadeh M, Hassanzadeh R, Alizadeh Sefat S, et al. Granulomatous mastitis: Presentations, diagnosis, treatment and outcome in 206 patients from the north of Iran. *Breast* 2015;24:456-60.
  15. Zhou Y, Xu ZF, Xing W, et al. Comparative study of ultrasound-guided microwave ablation and traditional surgery in the treatment of plasma cell mastitis: a multicenter study. *Quant Imaging Med Surg* 2023;13:1838-48.
  16. Löfstrand J, Paganini A, Grimby-Ekman A, et al. Long-term patient-reported back and shoulder function after delayed breast reconstruction with a latissimus dorsi flap: case-control cohort study. *Br J Surg* 2024;111:znad296.
  17. Lee JS, Kang HS, Park J, et al. Postoperative Scar Management Using Laser Therapy for Breast Reconstruction With Latissimus Dorsi Flap. *In Vivo* 2024;38:842-8.
  18. Longo B, D'Orsi G, Vanni G, et al. Fat-Augmented Latissimus Dorsi Flap for Secondary Breast Reconstruction in Small to Medium-Sized Irradiated Breasts. *Plast Reconstr Surg* 2023;152:1165-73.
  19. Longo B, D'Orsi G, Giacalone M, et al. The Ergonomic FALD Flap for One-stage Total Breast Reconstruction. *Plast Reconstr Surg Glob Open* 2023;11:e5262.
  20. Demiri EC, Dionysiou DD, Tsimponis A, et al. Outcomes of Fat-Augmented Latissimus Dorsi (FALD) Flap Versus Implant-Based Latissimus Dorsi Flap for Delayed Post-radiation Breast Reconstruction. *Aesthetic Plast Surg* 2018;42:692-701.
  21. Maxwell GP. Iginio Tansini and the origin of the latissimus dorsi musculocutaneous flap. *Plast Reconstr Surg* 1980;65:686-92.
  22. Xu H, Jiang Y, Liao M, et al. Continuous postoperative negative pressure irrigation assisted mammoplasty in treating chronic refractory plasma cell mastitis. *Gland Surg* 2020;9:2071-8.

(English Language Editor: J. Gray)

**Cite this article as:** Pan L, Zhen H, Jia M, Ding C, Zhang X, Gao J, Guo F. High cure rate and satisfaction in patients with periductal mastitis via the latissimus dorsi myocutaneous flap technique: a retrospective study. *Gland Surg* 2024;13(6):794-801. doi: 10.21037/gs-23-484