



Risk factor analysis and clinical experience of treating capsular contracture after prepectoral implant-based breast reconstruction

Da-Som Kim^{1#^}, Yi-Jun Moon^{1#^}, Hyung-Chul Lee^{1^}, Jae-Ho Chung^{1^}, Seung-Pil Jung^{2^}, Eul-Sik Yoon^{1^}

¹Department of Plastic and Reconstructive Surgery, Korea University Hospital, Seoul, Republic of Korea; ²Division of Breast and Endocrine Surgery, Korea University Hospital, Seoul, Republic of Korea

Contributions: (I) Conception and design: DS Kim, YJ Moon, HC Lee, JH Chung; (II) Administrative support: None; (III) Provision of study materials or patients: None; (IV) Collection and assembly of data: DS Kim, YJ Moon; (V) Data analysis and interpretation: DS Kim, YJ Moon; (VI) Manuscript writing: All authors; (VII) Final approval of manuscript: All authors.

[#]These authors contributed equally to this work.

Correspondence to: Hyung-Chul Lee, MD, PhD. Department of Plastic and Reconstructive Surgery, Korea University Hospital, 73 Goryeodae-ro, Seongbuk-gu, Seoul 02841, Republic of Korea. Email: jobdragon@hanmail.net.

Background: Capsular contracture is one of the most common and severe complications after implant-based breast reconstruction. Recently, prepectoral implant-based breast reconstruction using acellular dermal matrix (ADM) has become an alternative to subpectoral implant-based reconstruction. However, risk factors for capsular contracture associated with recent prepectoral reconstruction trends are not well refined yet. Thus, the aim of this study was to determine risk factors for capsular contracture, and share our experience of treating capsular contracture in prepectoral reconstruction.

Methods: This retrospective comparative study focused on 110 patients who underwent prepectoral implant-based breast reconstruction with ADM. Risk factors of capsular contracture were analyzed by comparing a capsular contracture group (27 cases) and a non-capsular contracture group (83 cases). Secondary treatment after capsular contracture development was analyzed in capsular contracture group.

Results: According to univariate and multivariate analyses of risk factors for capsular contracture, single staged implant-based reconstruction (direct-to-implant), infection, and postoperative radiotherapy were significantly related to the development of capsular contracture. Also, surgical intervention including capsulectomy and capsulotomy with implant change showed a significant higher remission rate than other groups.

Conclusions: Our study provides insights into risk factors and treatment choices for capsular contracture after prepectoral implant-based breast reconstruction with ADM. These findings can aid selection of patients, postoperative care and preventative treatment before reconstruction.

Keywords: Capsular contracture; breast reconstruction; acellular dermal matrix (ADM)

Submitted Feb 29, 2024. Accepted for publication Jun 11, 2024. Published online Jun 27, 2024.

doi: 10.21037/gs-24-70

View this article at: <https://dx.doi.org/10.21037/gs-24-70>

[^] ORCID: Da-Som Kim, 0000-0003-4413-7626; Yi-Jun Moon, 0009-0001-3977-7744; Hyung-Chul Lee, 0000-0003-2482-8112; Jae-Ho Chung, 0000-0002-8351-2444; Seung-Pil Jung, 0000-0003-3967-2974; Eul-Sik Yoon, 0000-0001-5734-6625.

Introduction

Implant based breast reconstruction after oncologic resection has been widely used for over 50 years (1). Silicone breast implants are most commonly used nowadays. They are thought to be non-toxic and non-inflammatory. However, some local and systemic adverse effects have been reported (2). Among reported complications, capsular contracture is the most common and serious complication of implant-based breast reconstruction. In severe cases, reoperation might be needed (3). Fibrous tissues around an implant are physiologic responses after implant insertion. However, excessive fibrous capsule formation can lead to serious events such as deformation, rotation/displacement of the breast, tenderness, hardness, and pain (4).

Capsular contracture is most likely a multifactorial condition consisting of not only immunobiological factors, but also patient, surgery, and implant-specific risk factors (5). Patient factors, radiotherapy, infections, biofilm, implant factors, surgery factors could affect the development for

capsular contracture. According to previous study, the average rate for capsular contracture after implant breast reconstruction is about 25–30% (6). Many former research studies have found out that breast reconstruction in patients with breast cancer, subglandular positioning of the implant, postoperative hematoma and a smooth shell of the implant could be related to a higher risk of capsular contracture development (7).

Recently, prepectoral implant-based breast reconstruction has been replacing subpectoral reconstruction. This is because the implant stability has been improved, the intraoperative mastectomy skin flap perfusion assessment has become more advanced, and the advancement of processing acellular dermal matrix (ADM) allowed to place the implant in a prepectoral manner (5). Prepectoral implants could also benefit from avoiding the need to dissect the pectoral muscle and avoiding the animation deformity, which is one of the most troublesome disadvantages of subpectoral implants.

Regarding the texture of the implants, previous literature has reported that textured implants were associated with the increased risk of breast implant-associated anaplastic large cell lymphoma (BIA-ALCL). While smooth implants are known to have a slightly increased risk of capsular contracture, the majority of surgeons prefer to use smooth round implants than textured implants due to the risk of BIA-ALCL. However, the risk factors of capsular contracture associated specifically with prepectoral smooth round implants are not well refined yet.

Thus, the aim of this study was to determine risk factors for capsular contracture to provide a clue to prevent it in prepectoral implant-based breast reconstruction. Another purpose of this study was to share our experience of successful treatment of capsular contracture in our center. We present this article in accordance with the STROBE reporting checklist (available at <https://gs.amegroups.com/article/view/10.21037/ggs-24-70/rc>).

Methods

Study design

This retrospective analysis was approved by our institutional review board (protocol number 2023AN0201). It was performed in accordance with principles of the Declaration of Helsinki (as revised in 2013). Individual consent for this retrospective analysis was waived. Medical records including detailed operation notes, follow-up records, and photographs were collected and analyzed.

Highlight box

Key findings

- Analyzing risk factors and treatment choices for capsular contracture especially after prepectoral implant-based breast reconstruction with acellular dermal matrix (ADM).

What is known and what is new?

- Capsular contracture is one of the most common and complicated problems after implant-based breast reconstruction. However, previous studies analyzed risk factors of capsular contracture mostly for subpectoral implant reconstruction. There were lacking studies of risk factors for capsular contracture and treatment options after capsular contracture in prepectoral implant reconstruction.
- We compared 110 patients who underwent prepectoral implant-based breast reconstruction with ADM. Risk factors of capsular contracture were analyzed by comparing a capsular contracture group (27 cases) and a non-capsular contracture group (83 cases). By univariate and multivariate analyses of risk factors for capsular contracture, single staged implant-based reconstruction (direct-to-implant), infection, and postoperative radiotherapy were significantly related to the development of capsular contracture in prepectoral breast reconstruction.

What is the implication, and what should change now?

- Analyzing risk factors for capsular contracture is important for preventing capsular contracture. Also, our study revealed surgical intervention including capsulectomy and capsulotomy with implant change showed a significant higher remission rate than other treatment.

To assess risk factors of capsular contracture after prepectoral implant-based breast reconstruction, we compared demographics and surgical characteristics of breast with capsular contracture ($n=27$, capsular contracture group) and control group without capsular contracture ($n=83$, no contracture group). Clinical presentations of capsular contracture included a firm, tight breast that could cause distortion and pain of the breast. The Baker classification was used in this study to classify the degree of capsular contracture (8). In the Baker classification, the degree of capsular contracture has four grades: grade I, a normal, soft breast; grade II, a minimally firm breast; grade III, a moderately firm breast with some visible deformity; and grade IV, a painful, hard, distorted breast.

In this study, capsular contracture breasts of grade II to IV were included. Two surgeons assessed and graded capsular contracture during patients' follow up outpatient clinic visits.

Patients

Only patients with clear surgical details and prepectoral implant-based breast reconstruction with ADM were included in this study. In this study, donated human ADM was used. Patients with subpectoral or autologous tissue-based reconstructions or unclear surgical details were excluded in this study. Finally, data of 110 breasts in 96 patients who underwent prepectoral implant-based breast reconstruction between October 2020 and December 2021 were included.

Operative technique

A prophylactic intravenous cefazalone, a 1st-generation cephalosporin was administered 1 hour before the surgical initiation. Breast reconstruction procedures were performed either directly after mastectomy for cancer treatment or after a prophylactic mastectomy. Skin sparing mastectomy (SSM) or nipple sparing mastectomy (NSM) were performed depended on oncological considerations. Evaluation of the skin flap's thickness and blood supply using indocyanine green angiography was done post-mastectomy to determine if immediate breast reconstruction with an implant was viable. If the viability of skin flap after surgery was considered favorable and the nipple areolar complex (NAC) was preserved, prepectoral direct to implant (DTI) was conducted. If not, reconstruction using an expander was carried out first, followed by serial inflation. A permanent silicone implant

was inserted during the second stage operation. ADM was considered, with options like anterior draping or customized/traditional wrapping selected for its use.

Anterior draping technique

The anterior draping technique involves utilizing a sheet of ADM that is tailored to fit the breast pocket and implant size. The ADM is customized and prepared on a separate sterile surface, rehydrated sequentially in iodine and normal saline. Following dissection, the prepectoral pocket is created, and the ADM is positioned over the pectoralis muscle in the prepectoral plane. It is secured in place with interrupted sutures using 2/0 Vicryl (Ethicon, Raritan, NJ, USA). Superior, medial and lateral borders of the ADM were fixed to the skin flap respectively. After that, several sutures were done using 3/0 Vicryl (Ethicon, Raritan) to fix the ADM to the skin flap. Lastly, the inferior border of the ADM was sutured to the skin flap.

Customized or traditional wrapping technique

Customized ADM has four linear straps at each corner with two sizes (14 cm × 14 cm and 16 cm × 16 cm). Customized ADM is premanufactured to easily cover the implant and has linear strap handle for fixation. A rectangular body of the customized ADM covered the anterior aspect of the implant. Four linear straps were used to cover the posterior aspect of implant (*Figure 1*). When a small-sized implant was used, a prosthesis was fully wrapped in a figure of each straps covering the whole posterior area in turn. When a large-sized implant was used, paired straps on opposite sides were sutured together to form an X shape.

Traditional wrapping method used rectangular shaped ADM to fully wrapping the implant. After wrapping was completely done, superior, medial, and lateral corners of the wrapped ADM were sutured to pectoralis muscle to mimic a natural ptotic feature (*Figure 2*).

Outcome measure

The degree of capsular contracture was assessed by plastic surgeons according to the Baker classification. The follow-up period of each patient was at least 6 months. If capsular contracture was developed during the follow-up period, surgical interventions including capsulectomy with or without implant change were performed for patients. Surgical intervention was determined according to the surgeon's consideration and patients' pain or discomfort. Whether to perform a total or partial capsulectomy

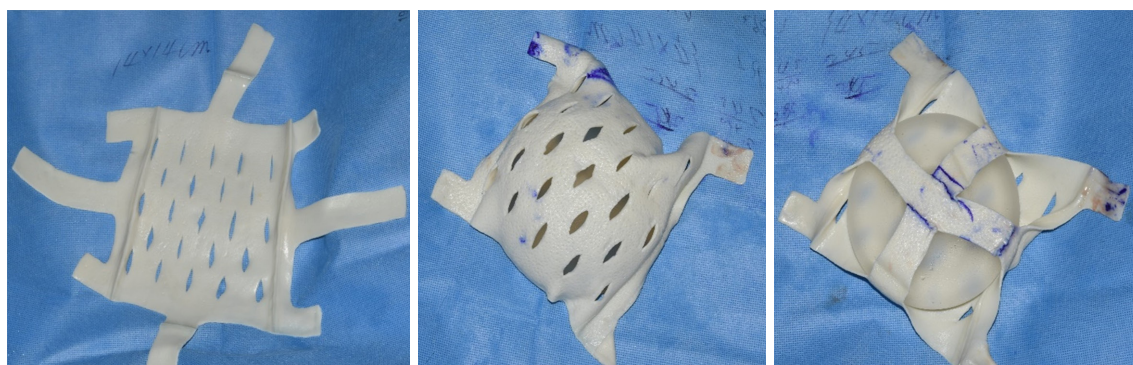


Figure 1 Pre-designed customized acellular dermal matrix.



Figure 2 Traditional wrapping method of acellular dermal matrix.

was determined based on the surgical field. Portions of thickened capsule were removed completely. Anterior and posterior capsules were then removed partially or totally.

Statistical analysis

All statistical analyses were performed using SPSS version 24.0 software (IBM Corp., Redmond, WA, USA). Chi-squared test was used for categorical variables. Fischer's exact test was used for categorical variables when the expected values of the contingency table were below 5, and Student *t*-test was used for continuous variables. Univariate and multivariate analyses were performed using binary logistic regression models to analyze risk factors of capsular contracture after prepectoral implant-based breast reconstruction. For all analyses, a value of $P < 0.05$ was considered statistically significant.

Results

Patient demographics

We analyzed a total of 110 breasts in 96 patients including 27 breasts that developed capsular contracture postoperatively and 83 breasts that did not develop capsular contracture postoperatively. The follow-up period of each patient was at least 6 months (*Table 1*). There was no significant difference in mean age, tobacco use, or diabetes mellitus. However, body mass index (BMI), average days of drain insertion, and hypertension showed significant differences ($P < 0.05$) between the two groups. Patients who developed capsular contracture showed higher BMI, longer duration of drain insertion, higher tendency of hypertension. Preoperative chemotherapy and postoperative radiotherapy also showed significant differences between the two groups. On the other hand, there was no significant

Table 1 Patient demographics and surgical characteristics

Characteristic	Total	No capsular contracture	Capsular contracture	P value
Total No. of breasts	110	83 (75.5)	27 (24.5)	
Age, years	47.3±9.6	47.4±9.8	46.9±9.0	0.56
BMI, kg/m ²	22.1±3.4	21.6±3.0	23.6±4.0	0.007*
Average days of drain inserted	8.9±5.5	8.0±4.6	11.6±6.9	0.002*
Comorbidity				
Tobacco use	8 (7.3)	6 (7.2)	2 (7.4)	0.98
Hypertension	10 (9.1)	4 (4.8)	6 (22.2)	0.006*
Diabetes mellitus	3 (2.7)	3 (3.6)	0	0.32
Preoperative chemotherapy	13 (11.8)	5 (6.0)	8 (29.6)	0.001*
Postoperative chemotherapy	31 (28.2)	23 (27.7)	8 (29.6)	0.85
Preoperative radiotherapy	2 (1.8)	0	2 (7.4)	0.06
Postoperative radiotherapy	12 (10.9)	3 (3.6)	9 (33.3)	<0.001*
Mastectomy type				0.06
Nipple-sparing mastectomy	78 (70.9)	55 (66.3)	23 (85.2)	
Skin-sparing mastectomy	32 (29.1)	28 (33.7)	4 (14.8)	
Reconstruction type				0.002*
Single-staged	66 (60.0)	43 (51.8)	23 (85.2)	
Two-staged	44 (40.0)	40 (48.2)	4 (14.8)	
Preoperative volume, mL	310.0±130.6	313.5±134.7	299.3±119.0	0.63
Mastectomy volume, mL	217.0±110.7	201.7±92.1	264.2±147.0	0.045*
Implant volume, mL	294.7±97.3	287.5±95.8	317.0±100.3	0.17
Incision				0.82
Inframammary fold	91 (82.7)	69 (83.1)	22 (81.5)	
Circumareolar	9 (8.2)	6 (7.2)	3 (11.1)	
Reduction pattern	3 (2.7)	2 (2.4)	1 (3.7)	
Mid-axillary	7 (6.4)	6 (7.2)	1 (3.7)	
ADM using method				0.25
Anterior draping	56 (50.9)	46 (55.4)	10 (37.0)	
Wrapping	39 (35.5)	27 (32.5)	12 (44.4)	
Customized	15 (13.6)	10 (12.0)	5 (18.5)	
Complication				
Infection	8 (7.3)	1 (1.2)	7 (25.9)	<0.001*
Hematoma	3 (2.7)	1 (1.2)	2 (7.4)	0.15
Seroma	14 (12.7)	9 (10.8)	5 (18.5)	0.33

Data were presented as n (%) or mean ± SD. *, statistically significant. BMI, body mass index; ADM, acellular dermal matrix; SD, standard deviation.

Table 2 Treatment choices for capsular contracture

Treatment choice	Capsular contracture (Baker grade)			Complete remission [%]
	II	III	IV	
Conservative care	9	6	1	0
Capsulectomy without implant change	2	0	1	1 [33]
Capsulectomy with implant change	0	1	6	5 [71]
Explantation	0	0	1	1 [100]
Total	11	7	9	7 [26]

difference in mastectomy type, mastectomy incision line, or ADM using method between the two groups. For complications, only infection showed statistically significant difference between the capsular contracture group and no capsular contracture group.

Treatment choices for capsular contracture

If capsular contracture occurred during the postoperative periods, the degree of capsular contracture was determined according to the Baker classification. Nine of 11 cases of grade II capsular contracture underwent conservative care, which include active breast massage education for patients to achieve larger pocket size and routine follow-ups. However, they did not achieve complete remission (Table 2). One case of grade III capsular contracture and six cases of grade IV capsular contracture, had secondary surgery of capsulectomy with implant change. Of these cases, 5 (71%) showed complete remission after a secondary surgery. Higher grade of capsular contracture and treatment choice of capsulectomy with implant change or explantation showed the better outcomes with higher complete remission rates.

Univariate and multivariate analyses of risk factors of capsular contracture

In binary logistic regression analysis, the reconstruction type of a single staged implant-based breast reconstruction was a significant risk factor of capsular contracture ($P=0.004$, Table 3). It was also a statistically significant factor in the multivariate regression analysis ($P=0.01$, Table 4). Infection and more than 7 days of drain insertion were statistically significant factors in the univariate analysis. However, only infection was a statistically significant factor in the multivariate analysis. Postoperative radiotherapy was

a significant risk factor of capsular contracture in both univariate and multivariate analyses ($P<0.001$ and $P=0.03$ respectively).

Case 1 Baker grade II capsular contracture with conservative care

A 40-year-old woman, who was a non-smoker, was diagnosed ductal carcinoma *in situ* of the right breast. The patient had a BMI of 22.85 kg/m². Her initial volume of right breast was 157 mL. She underwent prepectoral direct-to-implant (Mentor®, Santa Barbara, CA, smooth round) reconstruction with ADM (anterior draping method) after a NSM for her right breast. She did not undertake radiation therapy before or after the operation. This patient had drains for 11 days postoperatively. At the 6-month follow-up, the patient showed grade II capsular contracture on her breast (Figure 3). After that, only conservative treatment was done.

Case 2 Baker grade IV capsular contracture with capsulectomy and implant change

A 34-year-old woman, who was a non-smoker, was diagnosed invasive ductal carcinoma on her left breast with positive result of *BRCA* gene mutation for her right breast. The patient had a BMI of 21.07 kg/m². Her initial volume was 171 mL for the left breast and 115 mL for her right breast. She underwent prepectoral direct-to-implant (Mentor®, smooth round) reconstruction with an ADM (wrapping method) after a NSM for both her breasts. The patient did not undertake radiation therapy before or after the operation. The patient had drains for 10 days after surgery. At about 3 months after the surgery, the patient had infection of her right breast. Grade IV capsular contracture appeared on her breast with palpable hardness and pain.

Table 3 Univariate analysis of possible risk factors of capsular contracture

Factors	Odds ratio (95% CI)	Significance (P value)
Age (>50 years)	0.3686 (0.276–1.705)	0.42
Mastectomy type	0.342 (0.108–1.084)	0.07
Reconstruction type	0.187 (0.059–0.588)	0.004*
Incision type	0.937 (0.538–1.633)	0.82
Seroma	1.869 (0.567–6.157)	0.30
Infection	28.700 (3.338–246.767)	0.002*
Hematoma	6.560 (0.571–75.403)	0.13
Days of drain inserted (>7 days)	3.102 (1.136–8.471)	0.03*
Preoperative volume	0.999 (0.996–1.003)	0.62
Mastectomy volume	1.005 (1.001–1.009)	0.02*
Implant volume	1.003 (0.999–1.008)	0.17
Preoperative chemotherapy	6.568 (1.930–22.353)	0.003*
Postoperative chemotherapy	0.898 (0.517–1.558)	0.70
Preoperative radiotherapy	0.00 (0.00–0.00)	0.99
Postoperative radiotherapy	13.33 (3.278–54.238)	<0.001*
ADM draping type	1.605 (0.885–2.911)	0.12
Hypertension	5.643 (1.458–21.845)	0.01*
Diabetes mellitus	0.00 (0.00–0.00)	0.99
BMI (>25 kg/m ²)	2.291 (0.786–6.674)	0.13
Tobacco use	1.027 (0.195–5.414)	0.98

*, statistically significant. CI, confidence interval; ADM, acellular dermal matrix; BMI, body mass index.

Table 4 Multivariate analysis of possible risk factors of capsular contracture

Factors	Odds ratio (95% CI)	Significance (P value)
Reconstruction type	0.103 (0.018–0.592)	0.01*
Infection	13.351 (1.087–163.913)	0.02*
Mastectomy volume	1.004 (0.999–1.009)	0.09†
Hypertension	3.689 (0.797–17.077)	0.09†
Postoperative radiotherapy	9.246 (1.312–65.173)	0.03*

*, statistically significant; †, borderline significance. Variables including age, incision type, reconstruction type, days of drain inserted, hematoma, seroma, preoperative volume, implant volume, ADM draping type, preoperative and postoperative chemotherapy, DM were controlled. CI, confidence interval; ADM, acellular dermal matrix; DM, diabetes mellitus.

Finally, revisional surgery was performed with total capsulectomy and implant change. The patient then showed complete remission of capsular contracture (*Figure 4*).

Discussion

Capsular contracture is a common complication following implant based breast reconstruction. It can lead to aesthetic deformities, discomfort, and the need for additional surgical interventions (9). Therefore, understanding risk factors of capsular contracture development is crucial for optimizing surgical outcomes. This retrospective analysis aimed to identify risk factors for capsular contracture after prepectoral implant-based breast reconstruction using ADM. Our findings shed light on several important factors that can contribute to the development of capsular

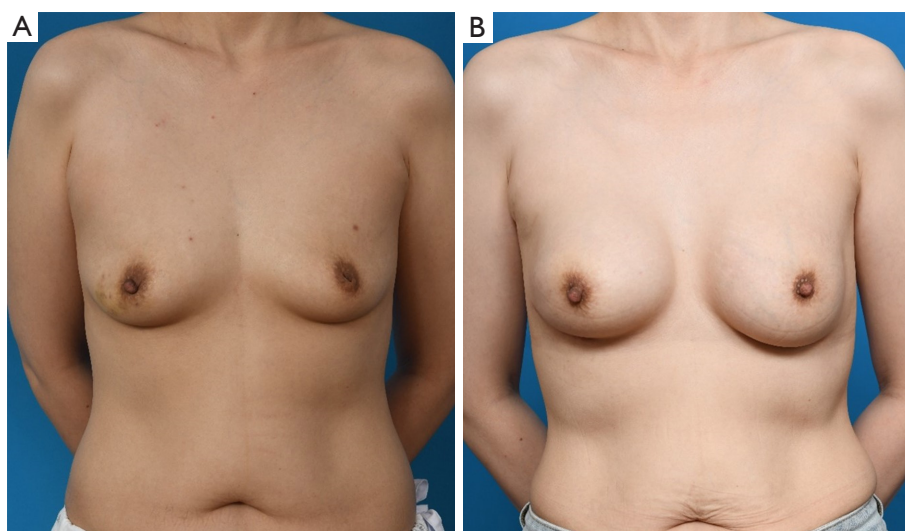


Figure 3 The patient underwent prepectoral direct-to-implant reconstruction with acellular dermal matrix (anterior draping). (A) Preoperative clinical photo. (B) Postoperative clinical photo of the patient at 2 year and 6 months after reconstruction. The patient had grade II capsular contracture with a conservative treatment.

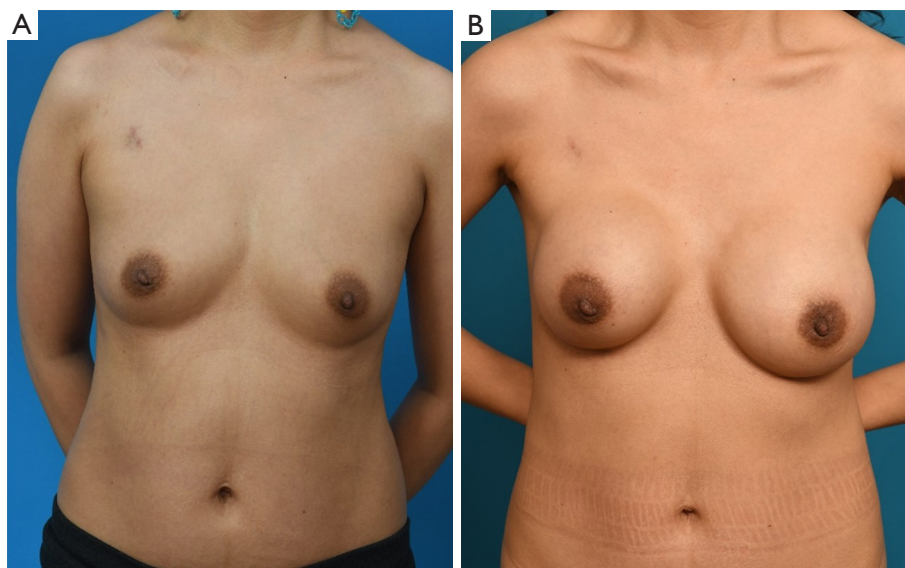


Figure 4 The patient underwent prepectoral direct-to-implant reconstruction with acellular dermal matrix (wrapping method). (A) Preoperative clinical photo. (B) Postoperative clinical photo at 2 years after reconstruction surgery. At 3 months after first surgery, the patient presented infection on her right breast. Grade IV capsular contracture was appeared on her right breast. The patient underwent total capsulectomy with implant change.

contracture. They provide insights into potential treatment options.

Findings of this study are consistent with previous research, confirming that certain risk factors play a

significant role in the development of capsular contracture. One crucial finding was that single-staged implant-based reconstruction, involving immediate implant insertion after mastectomy, was associated with a higher risk of

capsular contracture. This observation aligns with the work of Henriksen *et al.* (1). It highlights the importance of considering alternative surgical approaches, such as two-staged reconstruction, to reduce the risk of capsular contracture. Another significant risk factor identified in this study was postoperative radiotherapy. Radiotherapy has been recognized as a factor contributing to the development of capsular contracture in several studies (4,9,10). Our result reinforced its importance in the context of prepectoral implant-based breast reconstruction.

Infection was also identified as a statistically significant risk factor for capsular contracture in the present study. Pool *et al.* (2) and Safran *et al.* (11) have reported similar findings, emphasizing the need for stringent infection control measures during and after surgery. Surgeons must take proactive steps to minimize the risk of infections, such as using aseptic techniques and appropriate antibiotics. Therefore, sterile, atraumatic techniques, meticulous hemostasis, and local antimicrobial agents are commonly recommended during reconstruction (12).

Historically, numerous studies have shown that capsular contracture rates were higher when using the prepectoral plane compared to the subpectoral plane. However, recently rates of capsular contracture were significantly lower in the prepectoral plane than in subpectoral plane (7,13-16). In the past, high rates of capsular contracture with prepectoral technique were obviated by the advent or conversion to submuscular plane (17). The prevailing belief was that the subpectoral plane could reduce capsular formation by minimizing mechanical friction in the surrounding tissue, thereby reducing local inflammation and ultimately decreasing capsular formation. However, the widespread application of ADM in breast reconstruction has significantly contributed to overall lower rates of capsular contracture regardless of techniques (18). Multiple clinical studies have demonstrated a distinct reduction in capsular contracture rates among patients who received ADM compared to those who did not (19-21). Decreased granulation tissue and collagen deposition in prepectoral breast reconstruction, along with alterations in skeletal muscle fibrosis, have been proposed as potential explanations for the diminished occurrence of capsular pathology (9).

The choice of implant type, specifically the use of smooth round implants, was not addressed in our results, although it is common in the context of BIA-ALCL concerns (5,15). Previous studies have reported that smooth round

implants are most commonly used due to the association of textured implants with BIA-ALCL (22,23). Some meta-analysis studies have found that the capsular contracture rate of a smooth implant is significantly higher than that of a textured implant (24,25). The impact of implant type on the risk of capsular contracture is a relevant consideration. Future research should examine this aspect further.

When deciding treatment choices for capsular contracture, we observed that the severity of capsular contracture, as assessed by the Baker classification, influenced the treatment approach. Grade II cases mostly underwent conservative care. However, remission was not achieved in the majority of cases. On the other hand, grade III and grade IV cases often required surgical intervention in the form of capsulectomy with implant change. Other literatures have suggested selective capsulotomy with partial capsulectomy in capsular contracture patients (26). However, severe capsular contractures including grade IV capsular contractures required more aggressive surgical manipulations like total capsulectomies. Whether to perform partial or total capsulectomy was decided on the surgical field according to capsule thickness, degree of contracture and amounts of taken ADM. In a systematic review, it was evident that capsulectomy had potential for treating capsular contracture (27). This systematic review also presented many evidences of lower recurrence rates in studies exchanging implants after capsular contracture. Using initial implant in the same pocket had high capsular contracture recurrence rates (27,28). Thus, it is not recommended. Also in our study, capsulectomy with an implant change showed a higher remission rate (71%) than that without an implant change (33%). Therefore, it is essential to change new implant when performing surgical intervention for capsular contracture. Current literature often states that a personalized approach to treat capsular contracture is needed, since all individual patients have different implants with different clinical situations (6). Our study has introduced one aspect of a customized approach to individual patients with different grades of capsular contractures.

The identification of risk factors associated with capsular contracture has important clinical implications. By recognizing these factors, surgeons can take proactive measures to minimize the occurrence of capsular contracture and optimize patient outcomes. For example, strategies aimed to reducing the risk of infection, such as meticulous surgical technique, appropriate antibiotic

prophylaxis, and patient education on postoperative wound care, could be implemented (29). Similarly, the potential role of radiation therapy in promoting capsular contracture should be carefully considered, and alternative treatment options could be explored for patients who are at high risk (30). Early intervention for higher-grade capsular contracture appears to be associated with better outcomes. However, further research is needed to better understand the underlying mechanisms and refine preventive strategies.

It is important to acknowledge limitations of our study. While this study provides insights into risk factors for capsular contracture, it could benefit from certain improvements. First, the retrospective nature of this study limited its ability to establish a causality. In addition, it might have a selection bias. A prospective study design would strengthen the validity of our findings. Moreover, the minimal follow up period for capsular contracture in this study was 6 months, which is relatively short regarding the nature of a capsular contracture. Further study would be necessary to provide longer follow ups for capsular contracture. Third, the sample size of 110 patients was relatively small, warranting caution when generalizing results of this study. A larger cohort study involving multiple centers would provide more robust evidence on the identified risk factors.

Conclusions

In conclusion, our study provides insights into risk factors and treatment choices for capsular contracture after prepectoral implant-based breast reconstruction with ADM. Findings of this study highlight the importance of patient characteristics, surgical techniques, and postoperative management in the development of capsular contracture. Infection, prolonged drain insertion, single-staged breast reconstruction, and postoperative radiotherapy are identified as significant risk factors, implying the importance of preventive measure and careful patient selection.

Future research should continue to investigate strategies for reducing capsular contracture and improving outcomes of breast reconstruction patients. By understanding and addressing these risk factors, surgeons can strive to optimize outcomes and reduce the incidence of capsular contracture in prepectoral implant-based breast reconstruction.

Acknowledgments

Funding: This research was supported by a grant of Korea

University Anam Hospital, Seoul, Republic of Korea.

Footnote

Reporting Checklist: The authors have completed the STROBE reporting checklist. Available at <https://gs.amegroups.com/article/view/10.21037/gc-24-70/rc>

Data Sharing Statement: Available at <https://gs.amegroups.com/article/view/10.21037/gc-24-70/dss>

Peer Review File: Available at <https://gs.amegroups.com/article/view/10.21037/gc-24-70/prf>

Conflicts of Interest: All authors have completed the ICMJE uniform disclosure form (available at <https://gs.amegroups.com/article/view/10.21037/gc-24-70/coif>). The authors have no conflicts of interest to declare.

Ethical Statement: The authors are accountable for all aspects of the work in ensuring that questions related to the accuracy or integrity of any part of the work are appropriately investigated and resolved. This retrospective analysis was approved by our institutional review board (protocol number 2023AN0201). It was performed in accordance with principles of the Declaration of Helsinki (as revised in 2013). Individual consent for this retrospective analysis was waived.

Open Access Statement: This is an Open Access article distributed in accordance with the Creative Commons Attribution-NonCommercial-NoDerivs 4.0 International License (CC BY-NC-ND 4.0), which permits the non-commercial replication and distribution of the article with the strict proviso that no changes or edits are made and the original work is properly cited (including links to both the formal publication through the relevant DOI and the license). See: <https://creativecommons.org/licenses/by-nc-nd/4.0/>.

References

- Henriksen TF, Hölmich LR, Friis S, et al. The Danish Registry for Plastic Surgery of the Breast: establishment of a nationwide registry for prospective follow-up, quality assessment, and investigation of breast surgery. *Plast Reconstr Surg* 2003;111:2182-9; discussion 2190-1.
- Pool SMW, Wolthuisen R, Mouës-Vink CM. Silicone breast prostheses: A cohort study of complaints,

- complications, and explantations between 2003 and 2015. *J Plast Reconstr Aesthet Surg* 2018;71:1563-9.
3. Stevens WG, Calobrace MB, Alizadeh K, et al. Ten-year Core Study Data for Sientra's Food and Drug Administration-Approved Round and Shaped Breast Implants with Cohesive Silicone Gel. *Plast Reconstr Surg* 2018;141:7S-19S.
 4. Jacobson JM, Gatti ME, Schaffner AD, et al. Effect of incision choice on outcomes in primary breast augmentation. *Aesthet Surg J* 2012;32:456-62.
 5. Bachour Y. Capsular Contracture in Breast Implant Surgery: Where Are We Now and Where Are We Going? *Aesthetic Plast Surg* 2021;45:1328-37.
 6. Susini P, Nisi G, Pierazzi DM, et al. Advances on Capsular Contracture-Prevention and Management Strategies: A Narrative Review of the Literature. *Plast Reconstr Surg Glob Open* 2023;11:e5034.
 7. Spear SL, Murphy DK; Allergan Silicone Breast Implant U.S. Natrelle round silicone breast implants: Core Study results at 10 years. *Plast Reconstr Surg* 2014;133:1354-61.
 8. Spear SL, Baker JL Jr. Classification of capsular contracture after prosthetic breast reconstruction. *Plast Reconstr Surg* 1995;96:1119-23; discussion 1124.
 9. Sobti N, Weitzman RE, Nealon KP, et al. Evaluation of capsular contracture following immediate prepectoral versus subpectoral direct-to-implant breast reconstruction. *Sci Rep* 2020;10:1137.
 10. Rosato RM, Dowden RV. Radiation therapy as a cause of capsular contracture. *Ann Plast Surg* 1994;32:342-5.
 11. Safran T, Al-Badarin F, Al-Halabi B, et al. Aesthetic Limitations in Direct-to-Implant Prepectoral Breast Reconstruction. *Plast Reconstr Surg* 2022;150:22e-31e.
 12. Wan D, Rohrich RJ. Revisiting the Management of Capsular Contracture in Breast Augmentation: A Systematic Review. *Plast Reconstr Surg* 2016;137:826-41.
 13. Kulmala I, McLaughlin JK, Pakkanen M, et al. Local complications after cosmetic breast implant surgery in Finland. *Ann Plast Surg* 2004;53:413-9.
 14. Hammond DC, Migliori MM, Caplin DA, et al. Mentor Contour Profile Gel implants: clinical outcomes at 6 years. *Plast Reconstr Surg* 2012;129:1381-91.
 15. Namnoum JD, Largent J, Kaplan HM, et al. Primary breast augmentation clinical trial outcomes stratified by surgical incision, anatomical placement and implant device type. *J Plast Reconstr Aesthet Surg* 2013;66:1165-72.
 16. Largent JA, Reisman NR, Kaplan HM, et al. Clinical trial outcomes of high- and extra high-profile breast implants. *Aesthet Surg J* 2013;33:529-39.
 17. Holzgreve W, Beller FK. Surgical complications and follow-up evaluation of 163 patients with subcutaneous mastectomy. *Aesthetic Plast Surg* 1987;11:45-8.
 18. Nahabedian MY. Acellular dermal matrices in primary breast reconstruction: principles, concepts, and indications. *Plast Reconstr Surg* 2012;130:44S-53S.
 19. Ganesh Kumar N, Berlin NL, Kim HM, et al. Development of an evidence-based approach to the use of acellular dermal matrix in immediate expander-implant-based breast reconstruction. *J Plast Reconstr Aesthet Surg* 2021;74:30-40.
 20. Kim JH, Hong SE. A Comparative Analysis between Subpectoral versus Prepectoral Single Stage Direct-to-Implant Breast Reconstruction. *Medicina (Kaunas)* 2020;56:537.
 21. Franceschini G, Masetti R. Immediate implant-based breast reconstruction with acellular dermal matrix after conservative mastectomy: can a more effective alternative be used in the near future? *Eur J Surg Oncol* 2021;47:1225-6.
 22. de Boer M, van Leeuwen FE, Hauptmann M, et al. Breast Implants and the Risk of Anaplastic Large-Cell Lymphoma in the Breast. *JAMA Oncol* 2018;4:335-41.
 23. Marra A, Viale G, Pileri SA, et al. Breast implant-associated anaplastic large cell lymphoma: A comprehensive review. *Cancer Treat Rev* 2020;84:101963.
 24. Zhai P, Wu Y, Yang D, et al. A systematic review and meta-analysis of capsular contracture rate after breast augmentation with textured and smooth breast prostheses. *Gland Surg* 2022;11:166-74.
 25. Camirand A, Doucet J. Breast augmentation: teaching our patients how compression can help prevent capsular contracture. *Aesthetic Plast Surg* 2000;24:221-6.
 26. Susini P, Marcaccini G, Giardino FR, et al. Selective Capsulotomies and Partial Capsulectomy in Implant-Based Breast Reconstruction Revision Surgery. *Breast J* 2024;2024:9097040.
 27. Boyd CJ, Chiodo MV, Lisiecki JL, et al. Systematic Review of Capsular Contracture Management following Breast Augmentation: An Update. *Plast Reconstr Surg* 2024;153:303e-21e.
 28. Little G, Baker JL Jr. Results of closed compression capsulotomy for treatment of contracted breast implant capsules. *Plast Reconstr Surg* 1980;65:30-3.
 29. Henriksen TF, Fryzek JP, Hölmich LR, et al. Surgical intervention and capsular contracture after breast

- augmentation: a prospective study of risk factors. *Ann Plast Surg* 2005;54:343-51.
30. Steiert AE, Boyce M, Sorg H. Capsular contracture by silicone breast implants: possible causes, biocompatibility, and prophylactic strategies. *Med Devices (Auckl)* 2013;6:211-8.

Cite this article as: Kim DS, Moon YJ, Lee HC, Chung JH, Jung SP, Yoon ES. Risk factor analysis and clinical experience of treating capsular contracture after prepectoral implant-based breast reconstruction. *Gland Surg* 2024;13(6):987-998. doi: 10.21037/gs-24-70