



# Omission of axillary surgery in cN0, postmenopausal ER-positive/HER2-negative breast cancer patients undergoing breast-conserving treatment

Yeonjoo Kwon<sup>1#</sup>, Jihe Lim<sup>2#</sup>, Boram Ha<sup>3</sup>, Sanghwa Kim<sup>4</sup>, Jung Ho Park<sup>4</sup>, Young Ah Lim<sup>1</sup>, Hee-Joon Kang<sup>1</sup>, Doyil Kim<sup>4</sup>, Janghee Lee<sup>1^</sup>

<sup>1</sup>Department of Surgery, Dongtan Sacred Heart Hospital, Hallym University, Hwaseong-si, Republic of Korea; <sup>2</sup>Department of Radiology, Dongtan Sacred Heart Hospital, Hallym University, Hwaseong-si, Republic of Korea; <sup>3</sup>Department of Radiation Oncology, Dongtan Sacred Heart Hospital, Hallym University, Hwaseong-si, Republic of Korea; <sup>4</sup>Department of Surgery, Hallym University Sacred Heart Hospital, Hallym University, Hwaseong-si, Republic of Korea

*Contributions:* (I) Conception and design: Y Kwon, J Lee; (II) Administrative support: J Lee; (III) Provision of study materials or patients: J Lim, B Ha, J Lee; (IV) Collection and assembly of data: S Kim, JH Park, J Lee; (V) Data analysis and interpretation: Y Kwon, J Lee; (VI) Manuscript writing: All authors; (VII) Final approval of manuscript: All authors.

<sup>#</sup>These authors contributed equally to this work.

*Correspondence to:* Janghee Lee, MD. Department of Surgery, Dongtan Sacred Heart Hospital, Hallym University, 7, Keunjaebong-gil, Hwaseong-si, Gyeonggi-do 18450, Republic of Korea. Email: doctorlee85@outlook.kr.

**Background:** Previous clinical trials have diminished the significance of lymph node (LN) metastasis and axillary surgery in breast cancer, particularly in cN0, postmenopausal estrogen receptor (ER)-positive/human epidermal growth factor receptor 2 (HER2)-negative patients undergoing breast-conserving treatment (BCT). We assessed the replacement of axillary surgery with preoperative imaging modalities by analyzing the proportion of high nodal burden (HNB) patients with  $\geq 3$  LN metastases in these patients.

**Methods:** We retrospectively identified 333 cN0, postmenopausal ER-positive/HER2-negative breast cancer patients who underwent BCT in two hospitals between January 2003 and December 2017. The proportion of LN metastasis patients and the number of metastatic LN were investigated. Risk factors of LN metastasis were analyzed and recurrence-free survival (RFS) was compared.

**Results:** Axillary surgery confirmed LN metastasis in 81 (24.3%) of the cN0 patients. The clinical tumor size (cT) and age were factors associated with LN metastasis [cT: odds ratio (OR), 2.92, 95% confidence interval (CI): 1.69–5.05,  $P < 0.001$ ; age: OR, 0.33, 95% CI: 0.11–0.99,  $P = 0.048$ ]. However, HNB patients with  $\geq 3$  LN metastases were 15 (4.5%) of all the patients. There was statistically significant difference in the incidence of HNB between patients with cT1 tumors (3.6%) and those with cT2 tumors (7.4%) ( $P < 0.001$ ).

**Conclusions:** In cN0, postmenopausal ER-positive/HER2-negative patients who underwent BCT, patients with cT1 tumors had lower rate of LN metastasis, and there were fewer instances of HNB. Therefore, in these patients, omission of axillary surgery including SLNB can be carefully considered.

**Keywords:** Estrogen receptor-positive/human epidermal growth factor receptor 2-negative breast cancer (ER+/HER2- breast cancer); breast-conserving treatment (BCT); axillary surgery; postmenopausal women; lymph node metastasis

Submitted May 03, 2024. Accepted for publication Aug 05, 2024. Published online Aug 28, 2024.

doi: 10.21037/gs-24-146

View this article at: <https://dx.doi.org/10.21037/gs-24-146>

<sup>^</sup> ORCID: 0000-0003-1790-0788.

## Introduction

Breast cancer is the most common malignancy in women worldwide (1). Breast cancer treatment is divided into locoregional therapy, and systemic therapy. The guidelines for breast cancer are rapidly changing and becoming increasingly complex owing to the development of new drugs and several trials.

Before the 1990s, axillary surgery for breast cancer typically involved complete lymph node (LN) dissection. As sentinel LN biopsy (SLNB) has demonstrated its ability of replace axillary LN dissection (ALND) and reduce axillary complications, SLNB has become the standard procedure in breast cancer patients without LN metastasis (2-4). Furthermore, additional ALND has been omitted even when there are one or two LN metastases in patients undergoing breast-conserving treatment (BCT; breast-conserving surgery and radiotherapy) (5,6). Currently, most clinicians regard axillary surgery as a staging procedure rather than as a treatment.

Estrogen receptor (ER)-positive/human epidermal growth factor receptor 2 (HER2)-negative is the most common subtype of breast cancer and is known to have the best prognosis (7-9). Axillary LN metastasis is associated with poor outcomes in these patients and is an important factor in making chemotherapy decisions (10). However, the recent development of several multi-gene assays, including the 21-gene recurrence score (RS), has changed the procedure for chemotherapy decisions (11). Particularly, the results of A Clinical Trial RX for Positive Node, Endocrine Responsive Breast Cancer (RxPONDER) suggested that the 21-gene RS criteria for determining chemotherapy

of pathologic LNs (pN)1 were the same as those of pN0 in postmenopausal patients; therefore, the impact of LN staging was further reduced in these patient groups (12).

This decrease in axillary LN metastasis importance makes the necessity of axillary surgery in patients, postmenopausal with a low axillary nodal burden, such as clinical LNs (cN)0 patients, questionable. The purpose of our study was to determine whether axillary surgery including SLNB can be replaced with preoperative imaging modalities, including axillary ultrasonography (AUS) and breast magnetic resonance imaging (MRI), by analyzing the proportion of patients with a high nodal burden (HNB) with  $\geq 3$  LN metastases in patients with cN0, postmenopausal ER-positive/HER2-negative breast cancer who underwent BCT. We present this article in accordance with the STROBE reporting checklist (available at <https://gs.amegroups.com/article/view/10.21037/ggs-24-146/rc>).

## Methods

### Study population

We retrospectively identified postmenopausal, ER-positive/HER2-negative breast cancer patients with clinical tumor size (cT)1 and cT2 tumors diagnosed between January 2003 and December 2017 at Hallym University Sacred Heart Hospital and Dongtan Sacred Heart Hospital in South Korea. We included patients in our cohort who met the criteria for postmenopausal status regardless of age. LN negativity on preoperative AUS or breast MRI was evaluated in these patients. In cases where suspicious LN were identified on imaging, even if confirmed as benign through LN biopsy before breast surgery, they were not included in the cN0 group. Patients who had undergone neoadjuvant chemotherapy were also excluded because it is not an indication for omitting axillary surgery. HER2-positive breast cancer, triple-negative breast cancer (TNBC), and *de novo* stage IV breast cancer were also excluded. All clinicopathologic factors and prognosis of the patients were obtained through a medical chart review.

Our study adhered to Good Clinical Practice guidelines and was conducted in accordance with the Declaration of Helsinki (as revised in 2013). The study was approved by the institutional review board of Dongtan Sacred Heart Hospital (approval number: 2022-07-014-001), which waived the requirement for written informed consent owing to the retrospective study design. All participating hospitals/institutions were informed and agreed the study.

### Highlight box

#### Key findings

- Omission of axillary surgery.

#### What is known and what is new?

- With the exception of some patients, axillary surgery including sentinel lymph node biopsy is routinely performed in breast cancer surgery.
- In postmenopausal estrogen receptor-positive/human epidermal growth factor receptor 2-negative patients undergoing breast-conserving treatment, axillary surgery can be omitted if they are cN0, especially cT1 tumor.

#### What is the implication, and what should change now?

- Axillary surgery can be omitted in patients meeting the indications.

### *Imaging modality*

Preoperative hand-held breast ultrasound, including AUS, was performed using a linear transducer (iU22 and EPIQ 5G, Philips Medical System, Bothell, WA, USA and Sper Sonic Imagine, Hologic, Aix-en-Provence, France). Preoperative breast MRI was performed using dynamic contrast enhancement (MAGNETOM Skyra, Siemens Healthineers, Erlangen, Germany and Achieva, Philips, Bothell, WA, USA). Axillary LN metastasis was evaluated using axillary ultrasound and fat-suppressed contrast-enhanced T<sub>1</sub>-weighted MRI images. The AUS and MRI studies were interpreted by radiologists with over 10 years of experience specializing in breast imaging in each institution. Radiologic LN metastasis assessment was based on the presence of enlarged LN in the images. If enlarged LN were present, the determination of metastatic LN was performed according to the suspicious features including shape, symmetry of both sides, cortical thickness and fatty hilum reported in previous studies (13-17).

### *Procedure of axillary surgery*

SLNB was performed using dual tracer method with Technetium 99 and isosulfan blue dye. Technetium 99, a radioactive substance, was administered periareolarly prior to surgery, and sentinel LN (SLNs) were identified intraoperatively via a gamma detection system (Neoprobe<sup>®</sup>, Cincinnati, OH, USA). Isosulfan blue dye was injected during operation to identify nodes stained blue and subsequently removed them. We considered all LNs removed through SLNB as SLNs. Even if not identified as SLNs by dual tracer method, the removed non-SLNs were included in the total count of SLNs.

ALND was characterized by the removal of all LNs in axillary levels I and II. The performance of ALND was determined based on the frozen results of SLNs and the surgeon's judgement according to the guidelines at that time.

### *Clinical and pathologic characteristics of tumor*

cT stage was defined as the longest dimension on breast ultrasound. If there were two or more tumors, the size of the largest tumor was selected as the cT stage. We evaluated LN metastasis by serially cross-sectioning and microscopically examining them. Metastasis was defined as the presence of LN metastasis >0.2 mm, according

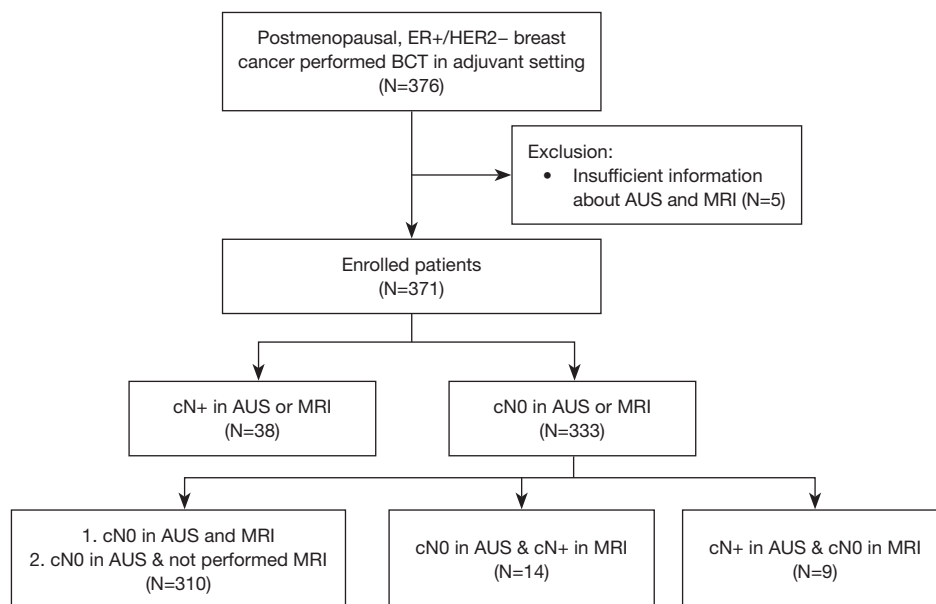
to the American Joint Committee on Cancer 8<sup>th</sup> edition anatomical stage classification (18). Malignant cell clusters classified as isolated tumor cells that are ≤0.2 mm were considered as not having LN metastasis. All pathologic features, including hormone receptor, HER2, histologic grade (HG), and nuclear grade (NG) were measured from the biopsy specimen. The cT stage was classified into cT1 and cT2 based on a 2 cm threshold, while HR and HER2 were categorized into positive and negative, and HG and NG was classified into I/II and III, respectively.

### *Radiation field according LN metastasis*

All patients scheduled for radiation underwent Computed Tomography (CT) simulation prior to radiotherapy. Conventional- or hypo-fractionated radiotherapy was administered to the whole breast regardless of LN metastasis (19). Additionally, in patients with LN metastases, radiation field was selectively extended to include axillary level I–III and supraclavicular area based on the physicians' judgment, considering clinicopathologic features of patients (11). Especially, for patients with HNB, strong consideration was given to the extension of the radiation field. A total radiation dose and fractionation ranged from 5,220 in 19 fractions to 6,120 cGy in 34 fractions.

### *Statistical analysis*

To compare the differences in clinicopathological factors between groups classified according to LN metastasis and HNB with ≥3 LN metastases, the chi-squared test was used for categorical variables, and the independent two-sample *t*-test was used for continuous variables. All missing data were excluded from the analysis. Univariate and multivariate binary logistic models were applied to identify risk factors for LN metastasis and HNB. Recurrence-free survival (RFS) was established as the endpoint for survival outcomes. It was defined as the period between breast cancer surgery and recurrence of breast cancer. Recurrence included locoregional recurrence in the ipsilateral breast or axillary LN and distant recurrence. Contralateral breast cancer was considered a secondary malignancy rather than a recurrence. Patients lost to follow-up were considered to have not experienced any recurrence events. Kaplan-Meier survival estimates were used to compare RFS, and group differences in the survival curves were analyzed using the log-rank test. *P*<0.05 was considered statistically significant. Statistical analyses were performed using SPSS version 25.0



**Figure 1** Flowchart of enrolled patients. ER, estrogen receptor; HER2, human epidermal growth factor receptor 2; BCT, breast-conserving treatment; AUS, axillary ultrasound; MRI, magnetic resonance imaging; LN, lymph node.

(IBM Inc., Armonk, NY, USA) and GraphPad Prism 9.0 (Boston, MA, USA).

## Results

### Baseline characteristics

We initially selected 376 patients with postmenopausal ER-positive/HER2-negative invasive breast cancer in an adjuvant setting (Figure 1). Excluding patients with insufficient metastasis information (N=5), a total of 371 patients were enrolled in the study. All enrolled patients underwent AUS, and 344 patients underwent MRI. Among them, 38 patients were clinically suspected of having LN metastasis in AUS and MRI, and 333 patients were classified as cN0 in AUS or MRI. Among the 333 cN0 patients, 310 either had both AUS and MRI or only underwent AUS, while 23 had discordant results between AUS and MRI. The sensitivity, specificity, positive predictive value, and negative predictive value for both AUS and MRI are documented in Table S1.

The clinicopathological characteristics of cN0 patients are summarized in Table 1. The average age was 59.1 years (range, 45–89 years). The number of patients with age <70 years was 295 (87.8%), and ALND was performed in 67 patients (20.1%). The average number of SLNs in patients was 4.8 (range, 1–13). 81 patients (24.1%) had cT2 tumor.

Eighty-one patients (24.3%) had LN metastasis. Of these, most were HG I/II (82.0%).

### Risk factors of axillary LN metastasis in cN0 patients

When comparing patients with and without LN metastasis, there was no difference in clinicopathological features between both groups other than age and type of axillary surgery (Table S2). In the univariate analysis, there were more axillary LN metastases for cT2 tumor [cT stage: odds ratio (OR), 2.92; 95% confidence interval (CI): 1.70–5.03;  $P < 0.001$ ; Table 2]. In addition, age  $\geq 70$  years was a factor associated with less occurrence of LN metastasis (OR, 0.33; 95% CI: 0.11–0.97;  $P = 0.04$ ). In the multivariate analysis, cT stage and age were also risk factors for LN metastasis (cT: OR, 2.92, 95% CI: 1.69–5.05,  $P < 0.001$ ; age: OR, 0.33, 95% CI: 0.11–0.99,  $P = 0.048$ ). Additionally, only cN+ in MRI did not contribute to distinguishing the presence of LN metastasis (OR, 0.38; 95% CI: 0.10–1.45;  $P = 0.16$ ).

### The proportion of patients who had LN metastasis and HNB

Eighty-one patients (24.3%) were pathologically diagnosed with LN metastasis after axillary surgery among patients with cN0. Furthermore, 66 patients had only one or two

**Table 1** Baseline characteristics of enrolled patients

Variables	Patients (N=333)
Age (years), average [range]	59.1 [45–89]
<70	295 (87.8)
≥70	38 (11.3)
Axillary surgery, n (%)	
SLNB only	266 (79.9)
ALND	67 (20.1)
Average number of SLN [range]	4.8 [1–13]
cT stage, n (%)	
I	252 (75.7)
II	81 (24.3)
LN metastasis, n (%)	
Negative	252 (75.7)
1–2 LN metastases	66 (19.8)
≥3 LN metastases	15 (4.5)
PR, n (%)	
Negative	77 (23.1)
Positive	256 (76.9)
Histologic grade, n (%)	
I/II	273 (82.0)
III	41 (12.3)
Unknown	19 (5.7)
Nuclear grade, n (%)	
I/II	277 (83.2)
III	40 (12.0)
Unknown	16 (4.8)
Radiotherapy, n (%)	
Performed	328 (98.5)
Breast only	318 (94.9)
Breast + regional	10 (3.0)
Not performed	5 (1.5)

SLNB, sentinel lymph node biopsy; ALND, axillary lymph node dissection; SLN, sentinel lymph node; LN, lymph node; PR, progesterone receptor.

LN metastases, accounting for 19.8% of all the patients and 81.5% of patients with metastasis (*Table 1*). The results of AUS in cN0 patients with LN metastasis have been

summarized in *Table S3*. Fifteen (4.5%) patients had HNB with ≥3 LN metastases.

In cT1 patients, there were 48 (19.1%) cases with LN metastases, and 9 cases (3.6%; 95% CI: 1–6%) with HNB, while in cT2 patients, there were 33 (40.7%; 95% CI: 30–51%) cases with LN metastases, and 6 cases (7.4%; 95% CI: 1–14%), showing a statistically significant difference ( $P < 0.001$ ; *Figure 2*). On the other hand, there was no significant difference in the incidence of HNB based on age or PR status (age:  $P = 0.11$ ; PR:  $P = 0.95$ ; *Figure S1*).

### Risk factors of HNB in cN0 patients

Patients with HNB more often had a higher incidence when AUS and MRI were discordant (*Table S4*). In univariate analysis, patients who suspected LN metastasis in only AUS, not in MRI and the number of SLNs were also associated with HNB (AUS cN+ & MRI cN0: OR, 15.00, 95% CI: 3.27–68.75,  $P < 0.001$ ; number of SLN: OR, 1.33, 95% CI: 1.06–1.67,  $P = 0.01$ ; *Table S5*). On the other hands, cases with only cN+ on MRI, not on AUS had no difference compared to cases with cN0 both MRI and AUS (OR, 5.00; 95% CI: 0.99–25.37;  $P = 0.052$ ). Furthermore, these features also statistically significant risk factors for HNB in the multivariate analysis (AUS cN+ & MRI cN0: OR, 16.71, 95% CI: 3.40–82.04,  $P = 0.001$ ; number of SLN: OR, 1.39, 95% CI 1.09–1.77,  $P = 0.007$ ). We conducted additional analysis using 4 LN metastases as the cut-off (*Table S6*).

### Discussion

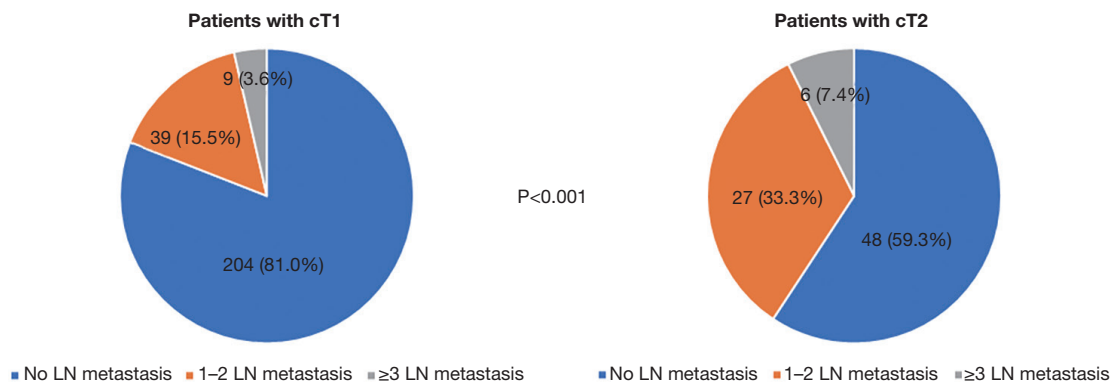
Our study analyzed the proportion of patients with pathologic axillary LN metastasis in cN0, postmenopausal ER-positive/HER2-negative patients who underwent BCT. Although LN metastases were not seen in the preoperative imaging modalities, metastases were present in approximately one-fourth of the patients. However, it was observed that in patients with cT1, the possibility of LN metastasis was significantly low. Furthermore, the number of patients with ≥3 LN metastases requiring additional procedures or treatment was small, particularly in cT1 patients. These investigations suggest the possibility of carefully omitting axillary surgery including SLNB in cN0, postmenopausal ER-positive/HER2-negative patients undergoing BCT with cT1 stage.

Since the American College of Surgeons Oncology Group (ACSOG) Z0011 study was published in the early 2010s, many clinicians have carefully skipped additional

**Table 2** Uni- and multivariate analysis of risk factors for axillary LN metastasis

Variables	Univariate analysis		Multivariate analysis	
	OR (95% CI)	P value	OR (95% CI)	P value
Age (years)				
<70	Reference		Reference	
≥70	0.33 (0.11–0.97)	0.04	0.33 (0.11–0.99)	0.048
Result of cN0 modality				
AUS and MRI or not performed MRI	Reference			
AUS cN0 and MRI cN+	0.38 (0.10–1.45)	0.16		
MRI cN0 and AUS cN+	0.69 (0.13–3.84)	0.68		
Number of SLN	1.09 (0.96–1.24)	0.20		
cT stage				
I	Reference		Reference	
II	2.92 (1.70–5.03)	<0.001	2.92 (1.69–5.05)	<0.001
PR				
Negative	Reference			
Positive	0.98 (0.54–1.76)	0.94		
Histologic grade				
I/II	Reference			
III	0.97 (0.45–2.09)	0.94		
Nuclear grade				
I/II	Reference			
III	0.99 (0.46–2.12)	0.97		

LN, lymph node; OR, odds ratio; CI, confidence intervals; AUS, axillary ultrasound; MRI, magnetic resonance imaging; SLN, sentinel lymph node; PR, progesterone receptor.



**Figure 2** Comparison of distribution of LN metastasis patients according to cT stage in cN0 patients. LN, lymph node.

ALND in cases of 1–2 metastases in SLNB that underwent BCT (5). In addition, the 10-year follow-up results of this study further confirmed that ALND is unnecessary and has become the standard procedure (6,11). These studies have provided evidence that axillary surgery can be safely reduced even in cases of axillary LN metastasis.

Some previous retrospective studies have suggested the possibility of omitting SLNB in specific patient groups, such as older patients or those with favorable tumor characteristics like ER-positive/HER2-negative (20,21). Furthermore, the latest results from the Sentinel Node vs Observation After Axillary Ultra-Sound (SOUND) trial, announced since the initiation of our research, indicate that SLNB can be cautiously omitted in cT1N0 patients (22,23). Although this study was conducted on patients of all ages and subtypes, the authors, considering clinical practice, mentioned that omission of axillary surgery is feasible only in postmenopausal ER-positive/HER2-negative patient group. Our study also, in accordance with current guidelines, excluded HER2-positive and TNBC patients.

The development of several multi-gene assays, including 21-gene RS, has changed the criteria for chemotherapy decisions. In particular, the results of the recently published The Trial Assigning Individualized Options for Treatment (TAILORx) and RxPONDER trials suggest that chemotherapy can be decided according to the 21-gene RS in pN0 and pN1 postmenopausal patients regardless of LN metastasis (12,24). Based on the combined results of these previous studies, we cautiously contemplate omission of axillary surgery including SLNB for nodal staging in these patients. However, as multi-gene assays, including 21-gene RS, remain relatively expensive, sufficient preoperative discussions with patients will be essential regarding potential complication of axillary surgery and economic burden associated with multi-gene assay.

The rate of LN metastasis in cN0 patients, as reported in previous studies, showed wide disparities. Keelan *et al.* reported that 23.1% of negative AUS breast cancer patients, including HER2-positive and TNBC patients, had LN metastases (25). In contrast, in a study by Choi *et al.*, 19.2% of cN0 patients had pathological LN metastasis, and Zhu *et al.* reported an LN metastasis rate of 38% (26,27). In our investigation, despite the combination of AUS and breast MRI, LN metastasis in patients with cN0 was 24.3%. Although one study reported that the detection of axillary LN metastasis improved when breast MRI was performed together with AUS alone, our study did not clearly demonstrate the benefit of MRI (28).

The current guidelines recommend additional ALND in patients with  $\geq 3$  LN metastases and adjuvant chemotherapy without 21-gene RS in patients with  $\geq 4$  metastases. In our cohort, 4.5% of HNB patients required further axillary surgery or absolute systemic therapy. In addition, HNB were observed in 3.6% and 7.4% of cT1 and cT2 cases, respectively. Based on these results, we debate that axillary surgery including SLNB can be carefully omitted in pT1 tumors. Keelan *et al.* also reported that 4.2% of patients had HNB, 2% had pT1 tumors, and 6.2% had pT2 tumors, similar to our investigation (25). In contrast, according to a systematic review by Leenders *et al.*, although the criteria for HNB differed by  $\geq 4$  LN metastases, the rate of HNB varied from 6.1–18.1% in each study (29). These discrepancies may be due to differences in the preoperative evaluation between the studies. AUS and breast MRI have been gradually developed in recent years, and the performance of the equipment may vary according to country, region, and institution. The diversity in the experience of radiologists may also be a reason for the accuracy differences. In this regard, our study was performed based on the opinions of well-trained radiologists with over 10 years of breast examination experience.

In our analysis, the risk factors for LN metastasis in cN0 patients were cT2 stage. These results were reported consistently in most studies, unlike the ratio of LN metastasis that varies in each study (25,27). Therefore, cT stage must be considered when determining the omission of axillary surgery including SLNB. Additionally, Tinterri *et al.* reported that, aside from tumor size, lobular histology, HG 3 and  $\geq 2$  SLN metastases are also risk factors for additional LN metastasis (30). These factors should definitely be considered in future studies on the omission of axillary surgery.

A limitation of our study is that, as a retrospective study, there may have been a selection bias. In addition, there were insufficient risk factors owing to the small number of patients, especially the number of HNB patients among cN0 patients. To compensate for this limitation, we reviewed preoperative AUS and breast MRI as accurately and made an effort to ensure most patients, including patients with a relatively long study period. Nevertheless, there was a difference in the proportion of HNB patients according to cT stage. Therefore, it can be said that there is some significance in identifying that predict HNB in cN0 patients. Furthermore, there is a concern regarding the omission of axillary surgery due to consideration related to the radiation field. While considering regional radiotherapy for patients in whom LN metastasis has not been confirmed

through axillary surgery is currently the predominant opinion, there is still insufficient evidence regarding the necessity of nodal irradiation. Additional research on the radiation field will be essential in the future.

Many recent studies in breast cancer are exploring de-escalation or omission of treatment as potential treatment approaches. Recent trial, including the SOUND trial, have investigated the omission of axillary surgery across various groups (22,31,32). Additionally, the development of multi-gene assays has contributed to a decreased proportion of patients receiving chemotherapy (33), and studies on omission of regional irradiation are also being reported (34). However, as locoregional treatment and systemic therapy have a mutually complementary relationship, research on treatment omission necessitated careful consideration of the impact on other therapeutic modalities. It is thought that relevant study and ongoing evidence will be necessary.

## Conclusions

In postmenopausal ER-positive/HER2-negative patients who underwent BCT, many patients had axillary LN metastasis, even with cN0 on AUS and breast MRI. However, it can be observed that patients with cT1 tumors tend to have significantly lower rates of LN metastasis. Furthermore, the proportion of patients with HNB was low, especially in patients with cT1 tumors. Therefore, in patients with cT1, omission of axillary surgery such as SLNB could be carefully considered. Further study is needed to investigate additional factor associated with axillary surgery, such as lympho-vascular invasion and specific criteria like cT1a-c.

## Acknowledgments

The abstract of this manuscripts was presented at the ESMO Congress 2022 (<https://www.esmo.org/meeting-calendar/past-meetings/esmo-congress-2022>). We would like to thank Editage ([www.editage.co.kr](http://www.editage.co.kr)) for English language editing

*Funding:* This work was supported by Hallym University Research Fund 2021 (No. HURF-2021-13).

## Footnote

*Reporting Checklist:* The authors have completed the STROBE reporting checklist. Available at <https://gs.amegroups.com/article/view/10.21037/gS-24-146/rc>

*Data Sharing Statement:* Available at <https://gs.amegroups.com/article/view/10.21037/gS-24-146/dss>

*Peer Review File:* Available at <https://gs.amegroups.com/article/view/10.21037/gS-24-146/prf>

*Conflicts of Interest:* All authors have completed the ICMJE uniform disclosure form (available at <https://gs.amegroups.com/article/view/10.21037/gS-24-146/coif>). The authors have no conflicts of interest to declare.

*Ethical Statement:* The authors are accountable for all aspects of the work in ensuring that questions related to the accuracy or integrity of any part of the work are appropriately investigated and resolved. The study was conducted in accordance with the Declaration of Helsinki (as revised in 2013). The study was approved by the institutional review board of Dongtan Sacred Heart Hospital (approval number: 2022-07-014-001), which waived the requirement for written informed consent owing to the retrospective study design. All participating hospitals/institutions were informed and agreed the study.

*Open Access Statement:* This is an Open Access article distributed in accordance with the Creative Commons Attribution-NonCommercial-NoDerivs 4.0 International License (CC BY-NC-ND 4.0), which permits the non-commercial replication and distribution of the article with the strict proviso that no changes or edits are made and the original work is properly cited (including links to both the formal publication through the relevant DOI and the license). See: <https://creativecommons.org/licenses/by-nc-nd/4.0/>.

## References

1. Sung H, Ferlay J, Siegel RL, et al. Global Cancer Statistics 2020: GLOBOCAN Estimates of Incidence and Mortality Worldwide for 36 Cancers in 185 Countries. *CA Cancer J Clin* 2021;71:209-49.
2. Veronesi U, Paganelli G, Viale G, et al. Sentinel-lymph-node biopsy as a staging procedure in breast cancer: update of a randomised controlled study. *Lancet Oncol* 2006;7:983-90.
3. Krag DN, Anderson SJ, Julian TB, et al. Sentinel-lymph-node resection compared with conventional axillary-lymph-node dissection in clinically node-negative patients with breast cancer: overall survival findings from the NSABP B-32 randomised phase 3 trial. *Lancet Oncol*



- 2010;11:927-33.
4. Ashikaga T, Krag DN, Land SR, et al. Morbidity results from the NSABP B-32 trial comparing sentinel lymph node dissection versus axillary dissection. *J Surg Oncol* 2010;102:111-8.
  5. Giuliano AE, Hunt KK, Ballman KV, et al. Axillary dissection vs no axillary dissection in women with invasive breast cancer and sentinel node metastasis: a randomized clinical trial. *JAMA* 2011;305:569-75.
  6. Giuliano AE, Ballman KV, McCall L, et al. Effect of Axillary Dissection vs No Axillary Dissection on 10-Year Overall Survival Among Women With Invasive Breast Cancer and Sentinel Node Metastasis: The ACOSOG Z0011 (Alliance) Randomized Clinical Trial. *JAMA* 2017;318:918-26.
  7. Howlader N, Altekruse SF, Li CI, et al. US incidence of breast cancer subtypes defined by joint hormone receptor and HER2 status. *J Natl Cancer Inst* 2014;106:dju055.
  8. Onitilo AA, Engel JM, Greenlee RT, et al. Breast cancer subtypes based on ER/PR and Her2 expression: comparison of clinicopathologic features and survival. *Clin Med Res* 2009;7:4-13.
  9. Tubtimhin S, Promthet S, Suwanrungruang K, et al. Molecular Subtypes and Prognostic Factors among Premenopausal and Postmenopausal Thai Women with Invasive Breast Cancer: 15 Years Follow-up Data. *Asian Pac J Cancer Prev* 2018;19:3167-74.
  10. Fisher B, Bauer M, Wickerham DL, et al. Relation of number of positive axillary nodes to the prognosis of patients with primary breast cancer. An NSABP update. *Cancer* 1983;52:1551-7.
  11. Gradishar WJ, Moran MS, Abraham J, et al. NCCN Guidelines® Insights: Breast Cancer, Version 4.2021. *J Natl Compr Canc Netw* 2021;19:484-93.
  12. Kalinsky K, Barlow WE, Gralow JR, et al. 21-Gene Assay to Inform Chemotherapy Benefit in Node-Positive Breast Cancer. *N Engl J Med* 2021;385:2336-47.
  13. Özler İ, Aydın H, Güler OC, et al. Can preoperative axillary ultrasound and biopsy of suspicious lymph nodes be an alternative to sentinel lymph node biopsy in clinical node negative early breast cancer? *Int J Clin Pract* 2021;75:e14332.
  14. Ecanow JS, Abe H, Newstead GM, et al. Axillary staging of breast cancer: what the radiologist should know. *Radiographics* 2013;33:1589-612.
  15. Cho N, Moon WK, Han W, et al. Preoperative sonographic classification of axillary lymph nodes in patients with breast cancer: node-to-node correlation with surgical histology and sentinel node biopsy results. *AJR Am J Roentgenol* 2009;193:1731-7.
  16. Kvistad KA, Rydland J, Smethurst HB, et al. Axillary lymph node metastases in breast cancer: preoperative detection with dynamic contrast-enhanced MRI. *Eur Radiol* 2000;10:1464-71.
  17. Yoshimura G, Sakurai T, Oura S, et al. Evaluation of Axillary Lymph Node Status in Breast Cancer with MRI. *Breast Cancer* 1999;6:249-58.
  18. Giuliano AE, Edge SB, Hortobagyi GN. Eighth Edition of the AJCC Cancer Staging Manual: Breast Cancer. *Ann Surg Oncol* 2018;25:1783-5.
  19. Smith BD, Bellon JR, Blitzblau R, et al. Radiation therapy for the whole breast: Executive summary of an American Society for Radiation Oncology (ASTRO) evidence-based guideline. *Pract Radiat Oncol* 2018;8:145-52.
  20. Chagpar AB, Hatzis C, Pusztai L, et al. Association of LN Evaluation with Survival in Women Aged 70 Years or Older With Clinically Node-Negative Hormone Receptor Positive Breast Cancer. *Ann Surg Oncol* 2017;24:3073-81.
  21. Dominici LS, Sineshaw HM, Jemal A, et al. Patterns of axillary evaluation in older patients with breast cancer and associations with adjuvant therapy receipt. *Breast Cancer Res Treat* 2018;167:555-66.
  22. Gentilini OD, Botteri E, Sangalli C, et al. Sentinel Lymph Node Biopsy vs No Axillary Surgery in Patients With Small Breast Cancer and Negative Results on Ultrasonography of Axillary Lymph Nodes: The SOUND Randomized Clinical Trial. *JAMA Oncol* 2023;9:1557-64.
  23. Gentilini O, Veronesi U. Abandoning sentinel lymph node biopsy in early breast cancer? A new trial in progress at the European Institute of Oncology of Milan (SOUND: Sentinel node vs Observation after axillary UltraSOUND). *Breast* 2012;21:678-81.
  24. Sparano JA, Gray RJ, Makower DF, et al. Adjuvant Chemotherapy Guided by a 21-Gene Expression Assay in Breast Cancer. *N Engl J Med* 2018;379:111-21.
  25. Keelan S, Heeney A, Downey E, et al. Breast cancer patients with a negative axillary ultrasound may have clinically significant nodal metastasis. *Breast Cancer Res Treat* 2021;187:303-10.
  26. Choi JS, Kim MJ, Moon HJ, et al. False negative results of preoperative axillary ultrasound in patients with invasive breast cancer: correlations with clinicopathologic findings. *Ultrasound Med Biol* 2012;38:1881-6.
  27. Zhu AQ, Li XL, An LW, et al. Predicting Axillary Lymph Node Metastasis in Patients With Breast Invasive Ductal Carcinoma With Negative Axillary Ultrasound Results

- Using Conventional Ultrasound and Contrast-Enhanced Ultrasound. *J Ultrasound Med* 2020;39:2059-70.
28. Ahn HS, Jang M, Kim SM, et al. Usefulness of preoperative breast magnetic resonance imaging with a dedicated axillary sequence for the detection of axillary lymph node metastasis in patients with early ductal breast cancer. *Radiol Med* 2019;124:1220-8.
  29. Leenders M, Kramer G, Belghazi K, et al. Can We Identify or Exclude Extensive Axillary Nodal Involvement in Breast Cancer Patients Preoperatively? *J Oncol* 2019;2019:8404035.
  30. Tinterri C, Canavese G, Gentile D. To Dissect or Not to Dissect? The Surgeon's Perspective on the Prediction of Greater Than or Equal to 4 Axillary Lymph Node Metastasis in Early-Stage Breast Cancer: A Comparative Analysis of the Per-Protocol Population of the SINODAR-ONE Clinical Trial. *Ann Surg Open* 2024;5:e405.
  31. Reimer T, Stachs A, Nekljudova V, et al. Restricted Axillary Staging in Clinically and Sonographically Node-Negative Early Invasive Breast Cancer (c/iT1-2) in the Context of Breast Conserving Therapy: First Results Following Commencement of the Intergroup-Sentinel-Mamma (INSEMA) Trial. *Geburtshilfe Frauenheilkd* 2017;77:149-57.
  32. Jung JG, Ahn SH, Lee S, et al. No axillary surgical treatment for lymph node-negative patients after ultrasonography [NAUTILUS]: protocol of a prospective randomized clinical trial. *BMC Cancer* 2022;22:189.
  33. Williams AD, Reyes SA, Arlow RL, et al. Is Age Trumping Genetic Profiling in Clinical Practice? Relationship of Chemotherapy Recommendation and Oncotype DX Recurrence Score in Patients Aged < 50 Years versus ≥ 50 Years, and Trends Over Time. *Ann Surg Oncol* 2018;25:2875-83.
  34. de Wild SR, de Munck L, Simons JM, et al. De-escalation of radiotherapy after primary chemotherapy in cT1-2N1 breast cancer (RAPCHEM; BOOG 2010-03): 5-year follow-up results of a Dutch, prospective, registry study. *Lancet Oncol* 2022;23:1201-10.

**Cite this article as:** Kwon Y, Lim J, Ha B, Kim S, Park JH, Lim YA, Kang HJ, Kim D, Lee J. Omission of axillary surgery in cN0, postmenopausal ER-positive/HER2-negative breast cancer patients undergoing breast-conserving treatment. *Gland Surg* 2024;13(8):1408-1417. doi: 10.21037/gs-24-146

**Table S1** Accuracy of AUS and MRI

Index	AUS	MRI
Sensitivity	72.3%	68.8%
Specificity	76.2%	77.0%
Positive predictive value	30.6%	32.7%
Negative predictive value	95.0%	93.8%

AUS, axillary ultrasound; MRI, magnetic resonance imaging.

**Table S2** Comparison of the clinicopathologic features of patients with or without LN metastasis

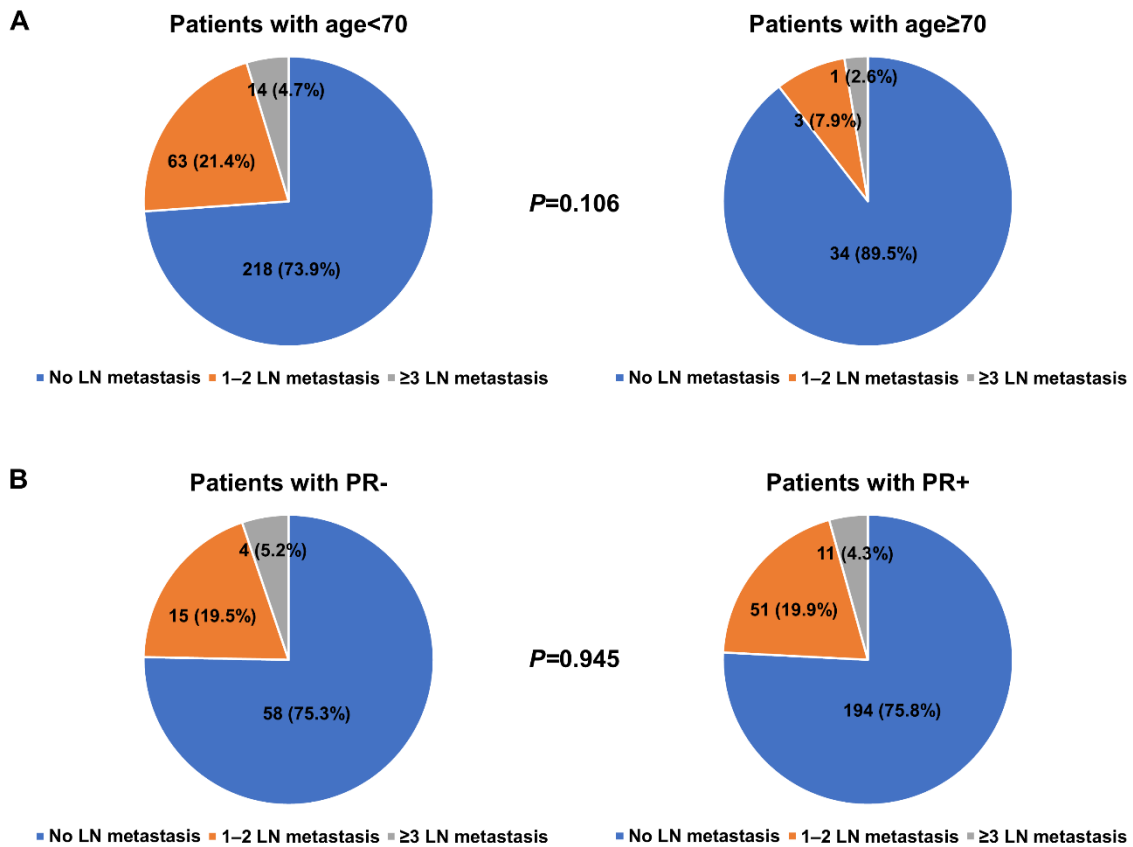
Variables	Patients with no LN metastasis (N=252) (%)	Patients with LN metastasis (N=81) (%)	P value
Age (years)			0.035
<70	218 (86.5)	77 (95.1)	
≥70	34 (13.5)	4 (4.9)	
Result of each modality			0.205
AUS & MRI cN0 or nor performed MRI	238 (76.8)	72 (88.9)	
AUS cN0 and MRI cN+	9 (3.6)	5 (6.2)	
AUS cN+ and MRI cN0	5 (2.0)	4 (4.9)	
Axillary surgery			<0.001
SLNB only	243 (96.4)	23 (28.4)	
ALND	9 (3.6)	58 (71.6)	
Average number of SLN	4.7 (1-13)	5.0 (1-13)	0.194
cT stage			
I	204 (81.0)	47 (58.8)	
II	48 (19.0)	33 (41.3)	
PR			0.935
Negative	58 (23.0)	19 (23.5)	
Positive	194 (77.0)	62 (76.5)	
Histologic grade			0.669
I/II	205 (81.3)	68 (84.0)	
III	31 (12.3)	10 (12.3)	
Unknown	16 (6.3)	3 (3.7)	
Nuclear grade			0.225
I/II	207 (82.1)	70 (86.4)	
III	30 (11.9)	10 (12.3)	
Unknown	15 (6.0)	1 (1.2)	
Radiotherapy			
Performed	249 (98.8)	79 (97.5)	0.410
Breast only	249 (100.0)	69 (87.3)	<0.001
Breast + regional	0 (0.0)	10 (12.7)	
Not performed	3 (1.2)	2 (2.5)	

LN, lymph node; AUS, axillary ultrasound; MRI, magnetic resonance imaging; SLNB, sentinel lymph node biopsy; ALND, axillary lymph node dissection; SLN, sentinel lymph node; PR, progesterone receptor.

**Table S3** Radiologic findings of cN0 patients in AUS with LN metastasis

Findings	Patients with 1-2 LN metastases (%)	Patients with $\geq 3$ LN metastases (%)	P value
Not any enlarged LN	56 (86.2)	9 (75.0)	0.328
Enlarged LN, but benign finding	9 (13.8)	3 (25.0)	
Total	65 (100.0)	12 (100.0)	

AUS, axillary ultrasound; LN, lymph node.



**Figure S1** Comparison of distribution of LN metastasis patients according to age and PR status. (A) Age; (B) PR. PR, progesterone receptor; LN, lymph node.

**Table S4** Comparison of the clinicopathologic feature with or without  $\geq 3$  LN metastasis

Variables	Patients with $\leq 2$ LN metastasis (N=318) (%)	Patients with $\geq 3$ LN metastasis (N=15) (%)	P value
Age (years)			0.554
<70	281 (95.3)	14 (4.7)	
$\geq 70$	37 (11.6)	1 (2.6)	
Result of each modality			<0.001
AUS & MRI cN0 or nor performed MRI	300 (94.3)	10 (66.7)	
AUS cN0 and MRI cN+	12 (3.8)	2 (13.3)	
AUS cN+ and MRI cN0	6 (1.9)	3 (20.0)	
Axillary surgery			<0.001
SLNB only	266 (83.6)	0 (0.0)	
ALND	52 (16.4)	15 (100.0)	
Average number of SLN	4.7 (1–13)	6.0 (1–13)	0.012
cT stage			0.148
I	243 (76.4)	9 (60.0)	
II	75 (23.6)	6 (40.0)	
PR			0.739
Negative	73 (23.0)	4 (26.7)	
Positive	245 (77.0)	11 (73.3)	
Histologic grade			0.630
I/II	262 (82.4)	11 (73.3)	
III	38 (11.9)	3 (20.0)	
Unknown	18 (5.7)	1 (6.7)	
Nuclear grade			0.670
I/II	264 (83.0)	13 (86.7)	
III	38 (11.9)	2 (13.3)	
Unknown	16 (5.0)	0 (0.0)	
Radiotherapy			0.495
Performed	64 (97.0)	15 (100.0)	<0.001
Breast only	62 (96.9)	7 (46.7)	
Breast + regional	2 (3.1)	8 (53.3)	
Not performed	2 (3.0)	0 (0.0)	

LN, lymph node; MRI, magnetic resonance imaging; SLNB, sentinel lymph node biopsy; ALND, axillary lymph node dissection; SLN, sentinel lymph node; PR, progesterone receptor.

**Table S5** Uni- and multivariate analyses of risk factors associated with  $\geq 3$  LN metastasis

Variables	Univariate analysis		Multivariate analysis	
	OR (95% CI)	P value	OR (95% CI)	P value
Age (years)				
<70	Reference			
$\geq 70$	0.54 (0.07-4.25)	0.560		
Result of cN0 modality				
AUS and MRI or nor performed MRI	Reference		Reference	
AUS cN0 and MRI cN+	5.00 (0.99-25.37)	0.052	4.55 (0.86-24.21)	0.075
MRI cN0 and AUS cN+	15.00 (3.27-68.75)	<0.001	16.71 (3.40-82.04)	0.001
Number of SLN	1.33 (1.06-1.67)	0.013	1.39 (1.09-1.77)	0.007
cT stage				
I	Reference		Reference	
II	2.16 (0.75-6.27)	0.156	2.11 (0.68-6.60)	0.199
PR				
Negative	Reference			
Positive	0.82 (0.25-2.65)	0.739		
Histologic grade				
I/II	Reference			
III	1.88 (0.50-7.05)	0.349		
Nuclear grade				
I/II	Reference			
III	1.07 (0.23-4.92)	0.932		

LN, lymph node; OR, odds ratio; CI, confidence intervals; AUS, axillary ultrasound; MRI, magnetic resonance imaging; SLN, sentinel lymph node; PR, progesterone receptor.

**Table S6** Uni- and multivariate analyses of risk factors associated with  $\geq 4$  LN metastasis

Variables	Univariate analysis		Multivariate analysis	
	OR (95% CI)	P value	OR (95% CI)	P value
Age (years)				
<70	Reference			
$\geq 70$	0.00 (0.00-NE)	0.998		
Result of cN0 modality				
AUS and MRI or nor performed MRI	Reference		Reference	
AUS cN0 and MRI cN+	10.17 (1.79-57.83)	0.009	8.49 (1.44-50.05)	0.018
MRI cN0 and AUS cN+	7.63 (0.80-72.99)	0.078	6.97 (0.71-68.53)	0.096
Number of SLN	1.22 (0.90-1.67)	0.206		
cT stage				
I	Reference		Reference	
II	3.2 (0.79-13.18)	0.104	2.64 (0.62-11.28)	0.190
PR				
Negative	Reference			
Positive	0.82 (0.25-2.65)	0.739		
Histologic grade				
I/II	Reference			
III	2.28 (0.45-11.71)	0.323		
Nuclear grade				
I/II	Reference			
III	0.99 (0.12-8.26)	0.992		

NE, not estimated; LN, lymph node; OR, odds ratio; CI, confidence intervals; AUS, axillary ultrasound; MRI, magnetic resonance imaging; SLN, sentinel lymph node; PR, progesterone receptor.