



# The diagnostic value of real-time ultrasound elastography and contrast-enhanced ultrasound in BI-RADS 4A breast lesions

Yindi Zhu<sup>1#</sup>, Li Jiang<sup>2#</sup>, Yue-Nan Chen<sup>2</sup>, Mingyue Wang<sup>1</sup>, Tina J. Hieken<sup>3</sup>, Mei-Fang Pan<sup>2</sup>, Dian Zhang<sup>2</sup>

<sup>1</sup>Department of Gynecology and Obstetrics, The First Affiliated Hospital of Soochow University, Suzhou, China; <sup>2</sup>Department of Ultrasound, Suzhou Xiangcheng People's Hospital, Suzhou, China; <sup>3</sup>Department of Surgery, Mayo Clinic, Rochester, MN, USA

*Contributions:* (I) Conception and design: Y Zhu, D Zhang; (II) Administrative support: MF Pan, D Zhang; (III) Provision of study materials or patients: L Jiang, YN Chen; (IV) Collection and assembly of data: L Jiang, YN Chen, M Wang; (V) Data analysis and interpretation: Y Zhu, L Jiang, D Zhang; (VI) Manuscript writing: All authors; (VII) Final approval of manuscript: All authors.

<sup>#</sup>The authors contributed equally to this work.

*Correspondence to:* Dian Zhang, MD; Mei-Fang Pan, MD. Department of Ultrasound, Suzhou Xiangcheng People's Hospital, 1060 Huayuan Road, Suzhou 215131, China. Email: 329036128@qq.com; csyx\_panmf@163.com.

**Background:** The Breast Imaging-Reporting and Data System (BI-RADS) is the primary system for classifying clinical breast lesions. Most early lesions identified via ultrasound are classified as BI-RADS 4A or lower. Although the vast majority of BI-RADS 4A lesions are benign, those lesions still have the possibility of malignancy in clinical practice, which is a controversial and noteworthy issue. This study aimed to assess the diagnostic value of real-time ultrasound elastography (UE) and contrast-enhanced ultrasound (CEUS) in evaluating BI-RADS 4A breast lesions.

**Methods:** A retrospective analysis was conducted of the UE and CEUS data of 52 BI-RADS 4A breast lesions from 52 patients between January 2020 and March 2023. All diagnoses were confirmed by surgical pathology. Lesion characteristics, including the margins, echogenicity, size, microcalcifications, blood flow patterns, UE scores, and CEUS features, were analyzed. CEUS scores were based on a five-point system, and the area under the curve (AUC) was calculated using MedCalc version 19.0.4.

**Results:** Based on the postoperative pathology, of the 52 lesions, 27 were benign and 25 were malignant. Compared to those with benign lesions, the patients with malignant lesions were older and had larger lesions ( $P < 0.05$ ). Features such as irregular morphology, indistinct margins, increased blood flow, and calcifications were more common in the malignant lesions than the benign lesions ( $P < 0.05$ ). The malignant lesions also had a higher prevalence of inhomogeneous enhancement, vasa vasorum, irregular enhanced morphology, and crab claw-like signs on CEUS than the benign lesions ( $P < 0.05$ ). The diagnostic accuracy of both the UE and CEUS individually was 76.9%, while the diagnostic accuracy of the UE and CEUS combined reached 80.8%. The AUCs of UE, CEUS, and the UE and CEUS combined were 0.761, 0.773, and 0.813, respectively.

**Conclusions:** UE and CEUS have significant diagnostic value for BI-RADS 4A breast lesions. Combining these techniques improves diagnostic accuracy and can help reduce unnecessary biopsies.

**Keywords:** Real-time ultrasound elastography; contrast-enhanced ultrasound (CEUS); Breast Imaging-Reporting and Data System 4A (BI-RADS 4A); breast cancer; diagnosis

Submitted Feb 28, 2025. Accepted for publication Mar 17, 2025. Published online Mar 26, 2025.

doi: 10.21037/gs-2025-93

View this article at: <https://dx.doi.org/10.21037/gs-2025-93>

## Introduction

The incidence of breast cancer has risen significantly presumably due to environmental changes and lifestyle factors, and it is now the leading cause of cancer-related death among women globally (1,2). Early detection is crucial for improving survival rates and the failure to detect breast cancers at an early stage represents a missed opportunity for optimal treatment and improved survival. In 2020 alone, there were approximately 2.3 million new breast cancer cases, and 685,000 breast cancer-related deaths worldwide, which corresponds to 16% of all female deaths due to cancer (3,4).

Histopathology is the gold standard for breast cancer diagnosis; however, its invasive nature limits its use as a first-line diagnostic method. Imaging techniques such as mammography, X-ray, ultrasound, and magnetic resonance imaging are essential for early detection (5-10). Among these, ultrasound is widely used due to its non-invasive, radiation-free, cost-effective and convenient nature.

The Breast Imaging-Reporting and Data System (BI-RADS), developed by the American Society of Radiology, is extensively applied in the diagnosis of breast cancer. BI-RADS 4 lesions have a 2–95% likelihood of malignancy, while that of BI-RADS 4A lesions is only 2–10% (11,12). Despite the low risk, the guidelines recommend biopsy for BI-RADS 4A lesions, which can place physical, financial, and psychological burdens on patients.

Real-time ultrasound elastography (UE) and contrast-enhanced ultrasound (CEUS) are emerging techniques that have enhanced diagnostic accuracy for tumors (13-16). However, the application of these techniques for BI-RADS 4A lesions specifically is underexplored. This study aimed to evaluate the diagnostic value of UE and CEUS in BI-RADS 4A breast lesions to streamline care, reduce unnecessary biopsies and improve clinical outcomes. We present this article in accordance with the STARD reporting checklist (available at <https://gs.amegroups.com/article/view/10.21037/gs-2025-93/rc>).

## Methods

### *General information and study design*

According to the American College of Radiology (ACR) BI-RADS Atlas (11), BI-RADS 4A lesions typically exhibit one suspicious feature, such as circumscribed margins suggestive of atypical fibroadenoma or probable abscess. The malignancy likelihood for BI-RADS 4A is 2–10%, necessitating biopsy for confirmation (11,17,18).

This retrospective study included 52 patients with BI-RADS 4A breast lesions treated at The First Affiliated Hospital of Soochow University and Suzhou Xiangcheng People's Hospital between January 2020 and March 2023. All patients underwent conventional ultrasound, UE, and CEUS examinations. The lesions were confirmed by histopathological analysis. The age of the patients ranged from 24 to 81 years (mean: 44.7±12.0 years), and the lesion sizes ranged from 3.8 to 52 mm (mean: 16.9±12.0 mm).

Based on the pathological examination results, 27 cases were allocated to the benign lesion group and 25 cases were allocated to the malignant lesion group. Under the 2013 American College of Radiology (ACR) BI-RADS (11), irregular morphology, mixed echoes, posterior echo attenuation, spiculated edges, microlobular edges, vertical orientation, microcalcifications, and ductal dilation are considered suspicious malignant features. Lesions with one suspicious ultrasound feature (e.g., mixed echoes, posterior shadowing) were classified as BI-RADS 4A, consistent with the ACR BI-RADS guidelines and prior studies (17,18). Lesions with multiple suspicious features were excluded to avoid overlap with BI-RADS 4B/C categories.

To be eligible for inclusion in the study, the patients had to meet the following inclusion criteria: have a BI-RADS 4A individual lesion; have a diagnosis confirmed by histopathological examination; and have not undergone any

### Highlight box

#### Key findings

- Real-time ultrasound elastography (UE) and contrast-enhanced ultrasound (CEUS) are effective diagnostic tools for breast lesions.
- Combining UE and CEUS enhances diagnostic accuracy for Breast Imaging-Reporting and Data System 4A breast lesions.

#### What is known, and what is new?

- Advances in UE and CEUS techniques have provided assistance in the diagnosis of breast nodules.
- The combined application of UE and CEUS enhances diagnostic accuracy, helping clinicians to better assess breast cancer and reduce unnecessary biopsies.

#### What is the implication, and what should change now?

- Using breast histopathology as the gold standard, this study evaluated the differential diagnostic value of UE, CEUS, and UE and CEUS combined. The combination of UE and CEUS enhances diagnostic accuracy, helping clinicians better assess breast cancer and reduce unnecessary biopsies.

clinical intervention before the ultrasound examination. Patients were excluded from the study if they met any of the following exclusion criteria: were pregnant or lactating females; had contraindications to imaging; had previously undergone chemotherapy or radiation therapy; had multiple or recurrent lesions in one breast; and/or had incomplete clinical data or a history of mental illness.

Written informed consent was obtained from all patients, and the study was approved by the Institutional Ethics Committee of the Suzhou Xiangcheng People's Hospital (No. 2016-014). The First Affiliated Hospital of Soochow University was informed and agreed with this study. The study was conducted in accordance with the Declaration of Helsinki (as revised in 2013).

### *Instruments and examination methods*

**Conventional ultrasound:** two-dimensional (2D) color Doppler ultrasound was performed using the LOGIQ E9 (GE Healthcare Milwaukee, WI, USA) with a probe frequency of 7.5–12.0 MHz. Prior to the ultrasound examination, the patient was placed in a supine position, and instructed to breathe calmly, raise their hands as much as possible, fully expose both breasts and armpits. The outer upper quadrant was selected as the starting point, and a 2D color Doppler ultrasound examination was first performed. The breast was comprehensively scanned in a counterclockwise direction in the right breast, and a clockwise direction in the left breast to explore the shape, position, internal echo, and other conditions of the lesion. The size, blood flow, aspect ratio, and other data of each lesion were recorded. Microcalcifications detected via ultrasound were classified as suspicious if clustered or irregular, following established protocols (12). However, ultrasound's inferior resolution compared to mammography for calcification morphology remains a limitation.

**UE examination:** Strain elastography was performed using the LOGIQ E9 system (GE Healthcare, Milwaukee, WI, USA). The maximum section of the lesion was first selected, after which the instrument was switched to elastic mode. A high-frequency linear array probe was used, and the probe frequency was set between 6–12 MHz. The probe was positioned perpendicular to the skin, and small vibrations were applied to the lesion to maintain a pressure index of 3–4. The area of interest was set to 2–3 times the size of the lesion. The elastic image of the lesion was dynamically observed, and when the quality index reached 60–70, an image was recorded. The characteristics of

the lesion were noted, and the hardness score was estimated based on the elastography image. Grading was performed according to color differences observed in the elastography.

The diagnostic criteria for UE adopted the 5-point scoring system and improved based on clinical experience on which 1 point indicates that the lesion image is predominantly green in color; 2 points indicate that the lesion image is surrounded by green with a slight blue hue; 3 points indicate that the green and blue each account for half of the lesion image; 4 points indicate that the lesion image is mainly blue with a slight green color; and 5 points indicate that the entire lesion image is blue (19). Under this grading system, scores of 1–3 points are considered indicative of benign lesions, while scores of 4–5 points suggest a higher likelihood of malignant lesions (8,19).

**CEUS examination:** the patient was instructed to remain still while 2.4 mL of contrast agent SonoVue (Bracco, Milan, Italy) was rapidly injected through the superficial vein of the elbow, followed by 5 mL of saline. Upon the initiation of the injection, dynamic images were stored in real time, capturing the entire imaging process. The probe was kept in the optimal section (with a clear and flat image) and observation continued for 1 minute. The probe was then moved to examine other sections until the contrast agent had dissipated. The following characteristics were recorded: enhancement intensity, enhancement scope, enhancement time, enhancement homogeneity, enhanced margin, enhanced morphology, filling defects, vasa vasorum, and the crab claw-like sign of the lesion.

The CEUS 5-point method was employed and improved based on clinical experience to assess the likelihood of malignancy on which 1 point indicates no enhancement within the lesion, with a clear boundary from surrounding tissues; 2 points indicate that the lesion shows equal enhancement, but the contour is not clearly defined in the enhanced image; 3 points indicate that the lesion shows uniform or uneven enhancement, with clear boundaries, regular morphology, and enhancement range consistent with the 2D image; 4 points indicate that the lesion appears uniformly or unevenly enhanced, with an irregular shape and an enhancement range greater than the two-dimensional image; and 5 points indicate that the lesion exhibits uneven enhancement, with an enhancement range exceeding that of the two-dimensional image, and may have areas of non-enhancement, and a crab claw-like sign around the periphery. Based on this grading system, lesions scored 4–5 points are considered malignant, while those scored 1–3 points are considered benign (20).

**Table 1** Comparison of the clinicopathological data of the benign and malignant breast lesion

Characteristics	Benign (n=27)	Malignant (n=25)	z/t value	P value
Age (years)			-3.061	0.004
Mean $\pm$ standard deviation	40.2 $\pm$ 10.9	49.6 $\pm$ 11.4		
Range	24–68	32–81		
Lesion size (mm)			-2.066	0.044
Mean $\pm$ standard deviation	13.7 $\pm$ 10.7	20.4 $\pm$ 12.6		
Range	3.8–48	4.0–52		
Side			-0.275	0.78
Right	14	12		
Left	13	13		
Pathological result, n (%)				
Fibroadenoma	10 (37.1)	–		
Adenopathy	3 (11.1)	–		
Intraductal papilloma	6 (22.2)	–		
Fibrocystic mastopathy	2 (7.4)	–		
Chronic inflammation	2 (7.4)	–		
Nodular lesion	4 (14.8)	–		
Invasive ductal carcinoma	–	20 (80.0)		
Papillary carcinoma	–	4 (16.0)		
Ductal carcinoma <i>in situ</i>	–	1 (4.0)		

### **Observation indicators and positive judgment criteria for combined diagnosis**

Using pathological results as the “gold standard”, the diagnostic results of CEUS and UE in breast lesions were statistically analyzed. The sensitivity, specificity, and accuracy of CEUS and UE in diagnosing breast lesions were compared. In the case of joint diagnosis, if both the UE and CEUS results indicated malignant lesions, the BI-RADS score was upgraded to level 4B. In all other cases, the score was downgraded to level 3. Discrepancies between the two experienced radiologists (D.Z. and L.J.) were resolved via discussion until a consensus was reached.

### **Statistical methods**

The statistical analysis was performed using SPSS 19.0 software (SPSS Inc., Chicago, IL, USA). The measurement data were presented as the mean  $\pm$  standard deviation. The Kolmogorov-Smirnov test was used to assess the normality

of the data distribution. For the normally distributed data, comparisons between two independent groups were made using the independent sample *t*-test. For the non-normally distributed data, the Chi-squared test was applied. The sensitivity, specificity, accuracy, positive predictive value, and negative predictive value of each diagnostic method were calculated. The area under the curve (AUC) values for each group were compared by the *Z*-test using MedCalc software (version 19.0.4, MedCalc Software Ltd., Ostend, Belgium). A *P* value of  $<0.05$  was considered statistically significant.

## **Results**

### **Clinical and pathological features**

As *Table 1* shows, of the 52 lesions, 27 were benign (e.g., fibroadenomas and intraductal papilloma) and 25 were malignant (e.g., invasive ductal carcinoma). The malignant lesions were associated with a larger size and older patient age ( $P < 0.05$ ).

**Table 2** Comparison of the conventional ultrasound characteristics between the benign and malignant breast lesions

Parameter	Pathology		$z/\chi^2$ value	P value
	Benign (n=27)	Malignant (n=25)		
Shape			-2.698	0.007
Regular	11	2		
Irregular	16	23		
Margin			-3.414	0.001
Clear	24	11		
Obscure	3	14		
Echogenicity			-1.374	0.17
Hypoechoogenicity	25	25		
Isoechoogenicity	0	0		
Hyperechoogenicity	0	0		
Mixed echo	2	0		
Rear features			-0.838	0.40
Attenuation	3	10		
No attenuation	22	8		
Augmentation	2	7		
Calcification			-3.574	<0.001
Yes	5	17		
No	22	8		
Axillary lymph nodes			-1.484	0.14
Yes	0	1		
No	27	24		
Blood flow			-2.886	0.004
Yes	10	24		
No	17	1		
Aspect ratio			-0.734	0.46
<1	20	16		
1	2	3		
>1	5	6		

### Screening of risk factors for breast lesions

Univariate analysis of the 52 breast lesions revealed statistically significant differences ( $P < 0.05$ ) between the benign and malignant nodules in terms of shape, margin, calcification, blood flow, enhancement time, enhancement homogeneity, vasa vasorum, crab claw-like sign, and

enhanced morphology (Tables 2,3). Doppler vascularity patterns were analyzed and compared to CEUS findings. The multivariate logistic regression analysis identified the primary indicators of malignant breast lesions as intratumoral calcification [odds ratio (OR) =0.117, 95% confidence interval (CI): 0.03–0.458,  $P=0.002$ ], an irregular shape (OR =6.901, 95% CI: 1.138–41.867,  $P=0.04$ ), the crab

**Table 3** Comparison of the CEUS characteristics between the benign and malignant breast lesions

Parameter	Pathology		z/ $\chi^2$ value	P value
	Benign (n=27)	Malignant (n=25)		
Enhancement intensity			0.000	>0.99
Hypoechoogenicity/isoechoogenicity	0	0		
Hyperechoogenicity	27	25		
Enhancement scope			-1.484	0.14
Not enlarged	22	2		
Enlarged	5	23		
Enhancement time			-5.259	<0.001
Fast-forward	27	23		
Same or slow-forward	0	2		
Enhancement homogeneity			-2.855	0.004
Homogeneous	16	5		
Inhomogeneous	11	20		
Filling defect			-0.825	0.41
Yes	12	14		
No	15	11		
Vasa vasorum			-3.348	0.001
Yes	4	15		
No	23	10		
Crab claw-like sign			-3.265	0.001
Present	2	13		
Absent	25	12		
Enhanced margin			-0.275	0.78
Clear	25	12		
Obscure	2	13		
Enhanced morphology			-5.223	<0.001
Regular	23	3		
Irregular	4	22		

CEUS, contrast-enhanced ultrasound.

claw-like sign (OR =0.148, 95% CI: 0.026–0.846, P=0.03), vasa vasorum (OR =0.186, 95% CI: 0.045–0.776, P=0.02), and an enhanced irregular shape (OR =17.788, 95% CI: 2.225–142.229, P=0.007).

#### **Diagnostic performance of UE and CEUS**

The distribution of the UE scores indicated that the

proportion of lesions with a score of 2 was higher in the benign lesion group than the malignant lesion group, while the proportion of lesions with a score of 4 was lower in the benign lesion group than the malignant group (*Table 4*). Similarly, the distribution of the CEUS scores revealed that the proportions of lesions with scores of 4 and 5 points were higher in the malignant lesion group than the benign lesion group (*Table 5*). Using pathology as the

gold standard, the sensitivity, specificity, and accuracy of the UE diagnosis were 56.0%, 96.3%, and 76.9%, respectively. The sensitivity, specificity, and accuracy of the CEUS diagnosis, were 88.0%, 66.7%, and 76.9%, respectively. The sensitivity, specificity, and accuracy of the UE and CEUS combined diagnosis were 96.0%, 66.7%, and 80.8%, respectively (Table 6). Figure 1 shows that the areas under the receiver operating characteristic (ROC) curves for UE, CEUS, and the UE and CEUS combined diagnosis were 0.761, 0.773, and 0.813, respectively.

## Discussion

Currently, BI-RADS is the primary classification system for determining the next treatment steps for breast lesions in clinical practice. However, due to the diversity of the clinical and pathological features of breast diseases and the complexity and variability of ultrasound images,

there is some overlap between the ultrasound results of benign and malignant lesions. This limits the application of conventional ultrasound diagnosis, especially for early stage lesions where typical malignant features may be absent, leading to potential clinical misdiagnosis (21,22). Under the BI-RADS, most early lesions are classified as 4A or lower. Although the vast majority of BI-RADS 4A lesions are benign, these lesions may still be malignant in clinical practice, and missed diagnosis will have a huge impact on patients' quality of life, which is a controversial and noteworthy issue (23-25). Given the limitations of conventional ultrasound evaluation, there is a pressing need for more accurate diagnostic methods for distinguishing between benign and malignant breast lesions. In recent years, advancements in UE and CEUS technologies have provided promising solutions for more accurate breast cancer diagnoses. Using breast histopathology as the gold standard, this study aimed to evaluate the differential diagnostic value of UE, CEUS, and UE and CEUS combined for distinguishing between benign and malignant breast lesions.

UE is a new imaging technology that evaluates tissue hardness by measuring the displacement generated when tissue is compressed. By quantifying the displacement, UE calculates the tissue's stiffness, which is color-coded for the clinical differentiation of benign and malignant lesions. Malignant tumors typically exhibit higher stiffness than benign tumors and normal tissues (26,27). According to an international multicenter clinical trial, combining UE with conventional ultrasound for the reclassification of BI-RADS 4A lesions can help reduce unnecessary biopsies (28). This may be related to abnormal cell proliferation and the increase of fibrous tissue after malignant transformation.

In the present study, the malignant lesions were more commonly scored 4, while the benign lesions were more commonly scored 2. After cancerous tissue undergoes necrosis, normal tissue tends to proliferate into fibrous cells, which gather to repair the necrotic area, making the tissue

**Table 4** Comparison of UE scores with different pathological properties

Pathology	UE scores				
	1	2	3	4	5
Benign (n=27)	2	15	9	1	0
Malignant (n=25)	0	0	11	14	0

UE, ultrasound elastography.

**Table 5** Comparison of CEUS scores with different pathological properties

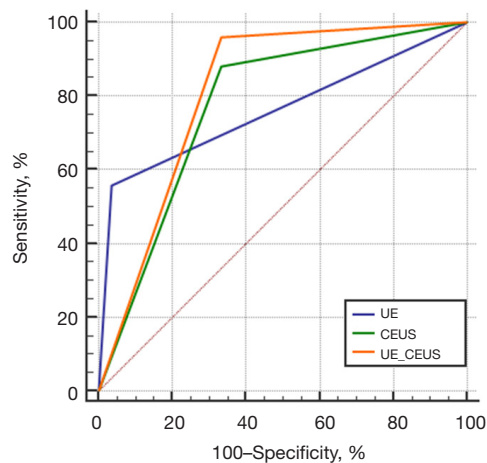
Pathology	CEUS scores				
	1	2	3	4	5
Benign (n=27)	0	4	14	7	2
Malignant (n=25)	0	0	3	9	13

CEUS, contrast-enhanced ultrasound.

**Table 6** Comparison of the diagnostic performance of the three inspection methods

Diagnostic methods	SE, %	SP, %	ACC, %	PPV, %	NPV, %	AUC (95% CI)
UE	56	96.3	76.9	93.3	70.3	0.761 (0.623 to 0.869)
CEUS	88	66.7	76.9	70.9	85.7	0.773 (0.636 to 0.878)
UE + CEUS	96	66.7	80.8	72.7	94.7	0.813 (0.681 to 0.908)

ACC, accuracy; AUC, area under the curve; CI, confidence interval; CEUS, contrast-enhanced ultrasound; NPV, negative predictive value; PPV, positive predictive value; SE, sensitivity; SP, specificity; UE, ultrasound elastography.



**Figure 1** ROC curves of diagnostic efficacy for UE, CEUS, and UE + CEUS. CEUS, contrast-enhanced ultrasound; ROC, receiver operating characteristic; UE, ultrasound elastography.

less elastic. However, the sensitivity of UE diagnosis was only 56%. This may be due to factors such as large lesion volume, insufficient blood supply, liquefaction necrosis, and heterogeneous tissue hardness, all of which can compromise the accuracy of UE scoring.

CEUS is a technique that uses harmonic imaging technology and contrast agents to visualize microcirculation and blood vessels within and around a tumor (29). Compared to color Doppler flow imaging (CDFI), CEUS has superior resolution, enabling the visualization of small blood vessels with low flow velocity and fine diameters. This provides valuable information for distinguishing between benign and malignant lesions. Additionally, CEUS can capture the time-intensity curve of blood flow, providing insights into microvascular generation within the lesion (29-31). Yu *et al.* reported that CEUS can significantly improve the diagnostic accuracy of BI-RADS 4A tumors, particularly those smaller than 2 cm, and has a diagnostic sensitivity and specificity of 90% and 86%, respectively, and an AUC of 0.904 (32).

In the present study, the malignant lesions generally exhibited uneven enhancement and irregular morphology, while the benign lesions showed the opposite characteristics. However, the specificity of CEUS was 66.7%, which was lower than that of UE. This could be due to the limited scanning area of CEUS that cannot capture full-layer images, including breast and axillary lymph nodes. Despite this, the sensitivity of CEUS was higher than that of UE. This is likely due to the rapid growth of malignant tumors that require increased blood flow and angiogenesis. This

results in more blood vessels in malignant tissue, allowing the contrast agent to enter faster, increasing the detection rate of malignant tumors (15).

In this study, in which pathological diagnosis was used as the gold standard, there were 11 cases of missed diagnosis and 12 cases of misdiagnosis in UE, 3 cases of missed diagnoses and 12 cases of misdiagnoses in CEUS, and 1 case of missed diagnosis and 10 cases of misdiagnoses with UE and CEUS combined testing. The accuracy rates for UE and CEUS were 72.39% and 78.36%, respectively. The ROC curve analysis revealed AUC values of 0.766 for UE, 0.818 for CEUS, and 0.896 for the UE and CEUS combined diagnosis, indicating that the combined approach has superior diagnostic performance. The accuracy of the combined UE and CEUS diagnosis was higher than that of either method alone, demonstrating the potential benefit of using both techniques together. Some lesions misdiagnosed by CEUS were correctly diagnosed by UE and vice versa. The combined approach provides a more comprehensive evaluation, improving the diagnostic accuracy and reducing the incidence of missed or misdiagnosed cases. Moreover, this study found that malignant nodules were generally larger in diameter and observed in older patients than benign nodules; thus, clinicians should consider these factors when evaluating BI-RADS 4A lesions.

This study had several limitations. The sample size was relatively small and did not include quantitative CEUS parameters or elastic strain values, which might have introduced bias in the collected data. The pathological subtypes were limited, and this lack of diversity could have also affected the results. Further, the absence of a unified CEUS classification standard might have led to subjective differences in the interpretation of results. A consensus was reached as to the interpretation of tumor morphological features, blood supply, and enhancement characteristics; however, some variability remained among the operators. The higher malignancy rate (48.1%) in our BI-RADS 4A cohort compared to the general population may reflect selection bias, as all lesions underwent surgical confirmation. Additionally, regional variations in breast cancer prevalence and diagnostic thresholds could contribute to this discrepancy. Future research will seek to address these issues, reduce misdiagnosis and missed diagnosis, and gather further evidence to support the findings of this study.

## Conclusions

UE and CEUS technologies demonstrate significant



diagnostic value for breast lesions, particularly for BI-RADS 4A lesions. Their combined application enhances diagnostic accuracy, helping clinicians better assess breast cancer and reduce unnecessary biopsies. Moreover, prospective evaluation of the combination of UE and CEUS might be a valuable next step. For BI-RADS 4A lesions, we recommend perform strain elastography (UE) to assess stiffness. If UE score  $\geq 4$ , proceed to CEUS for microvascular evaluation. Upgrade to BI-RADS 4B if both UE and CEUS suggest malignancy; downgrade to BI-RADS 3 if either is benign. Biopsy lesions upgraded to 4B. This approach balances diagnostic accuracy and reduces unnecessary procedures.

### Acknowledgments

None.

### Footnote

*Reporting Checklist:* The authors have completed the STARD reporting checklist. Available at <https://gs.amegroups.com/article/view/10.21037/gS-2025-93/rc>

*Data Sharing Statement:* Available at <https://gs.amegroups.com/article/view/10.21037/gS-2025-93/dss>

*Peer Review File:* Available at <https://gs.amegroups.com/article/view/10.21037/gS-2025-93/prf>

*Funding:* None.

*Conflicts of Interest:* All authors have completed the ICMJE uniform disclosure form (available at <https://gs.amegroups.com/article/view/10.21037/gS-2025-93/coif>). T.J.H. reports that there is unrelated research funding to her institution from Genentech, SkylineDX BV. The other authors have no conflicts of interest to declare.

*Ethical Statement:* The authors are accountable for all aspects of the work in ensuring that questions related to the accuracy or integrity of any part of the work are appropriately investigated and resolved. Written informed consent was obtained from all patients, and the study was approved by the Institutional Ethics Committee of the Suzhou Xiangcheng People's Hospital (No. 2016-014). The First Affiliated Hospital of Soochow University was informed and agreed with this study. The study was conducted in accordance with the Declaration of Helsinki (as

revised in 2013).

*Open Access Statement:* This is an Open Access article distributed in accordance with the Creative Commons Attribution-NonCommercial-NoDerivs 4.0 International License (CC BY-NC-ND 4.0), which permits the non-commercial replication and distribution of the article with the strict proviso that no changes or edits are made and the original work is properly cited (including links to both the formal publication through the relevant DOI and the license). See: <https://creativecommons.org/licenses/by-nc-nd/4.0/>.

### References

1. Coles CE, Earl H, Anderson BO, et al. The Lancet Breast Cancer Commission. *Lancet* 2024;403:1895-950.
2. Michaels E, Worthington RO, Rusiecki J. Breast Cancer: Risk Assessment, Screening, and Primary Prevention. *Med Clin North Am* 2023;107:271-84.
3. Britt KL, Cuzick J, Phillips KA. Key steps for effective breast cancer prevention. *Nat Rev Cancer* 2020;20:417-36.
4. Benitez Fuentes JD, Morgan E, de Luna Aguilar A, et al. Global Stage Distribution of Breast Cancer at Diagnosis: A Systematic Review and Meta-Analysis. *JAMA Oncol* 2024;10:71-8.
5. Wekking D, Porcu M, De Silva P, et al. Breast MRI: Clinical Indications, Recommendations, and Future Applications in Breast Cancer Diagnosis. *Curr Oncol Rep* 2023;25:257-67.
6. Wang Y, Li Y, Song Y, et al. Comparison of ultrasound and mammography for early diagnosis of breast cancer among Chinese women with suspected breast lesions: A prospective trial. *Thorac Cancer* 2022;13:3145-51.
7. Pathak P, Jalal AS, Rai R. Breast Cancer Image Classification: A Review. *Curr Med Imaging* 2021;17:720-40.
8. Penny SM. Sonography of Benign and Malignant Breast Lesions. *Radiol Technol* 2021;93:75M-91M.
9. Zhou Y, Wu J. Which combination of different ultrasonography modalities is more appropriate to diagnose breast cancer?: A network meta-analysis (a PRISMA-compliant article). *Medicine (Baltimore)* 2022;101:e29955.
10. Butler RS, Hooley RJ. Screening Breast Ultrasound: Update After 10 Years of Breast Density Notification Laws. *AJR Am J Roentgenol* 2020;214:1424-35.
11. Breast Imaging Reporting and Data System. BI-RADS: Ultrasound. 5th ed. Reston, VA: American College of Radiology (2013).

12. Tang L, Wang Y, Chen P, et al. Clinical use and adjustment of ultrasound elastography for breast lesions followed WFUMB guidelines and recommendations in the real world. *Front Oncol* 2022;12:1022917.
13. Tang L, Wang Y, Gong H, et al. Elastography Assisted BI-RADS in the Preoperative Breast Magnetic Resonance Imaging 4a Lesions in China. *J Ultrasound Med* 2023;42:453-61.
14. Tang L, Chen Y, Du Z, et al. A multicenter study of a contrast-enhanced ultrasound diagnostic classification of breast lesions. *Cancer Manag Res* 2019;11:2163-70.
15. Wen P, Liu L, Pan L, et al. Evaluating diagnostic significance: The utilization of elastography and contrast-enhanced ultrasound for differential diagnosis in breast lesions. *Clin Hemorheol Microcirc* 2024;88:81-95.
16. Weng L, Yu M. Diagnosis of Benign and Malignant BI-RADS 4 Breast Masses by Contrastenhanced Ultrasound Combined with Shear Wave Elastography. *Curr Med Imaging* 2023. [Epub ahead of print]. doi: 10.2174/0115734056257195231025072821.
17. Kim EK, Ko KH, Oh KK, et al. Clinical application of the BI-RADS final assessment to breast sonography in conjunction with mammography. *AJR Am J Roentgenol* 2008;190:1209-15.
18. Kwak JY, Kim EK, Park HL, et al. Application of the breast imaging reporting and data system final assessment system in sonography of palpable breast lesions and reconsideration of the modified triple test. *J Ultrasound Med* 2006;25:1255-61.
19. Itoh A, Ueno E, Tohno E, et al. Breast disease: clinical application of US elastography for diagnosis. *Radiology* 2006;239:341-50.
20. Xiao X, Ou B, Yang H, et al. Breast contrast-enhanced ultrasound: is a scoring system feasible? A preliminary study in China. *PLoS One* 2014;9:e105517.
21. Sedgwick E. The breast ultrasound lexicon: breast imaging reporting and data system (BI-RADS). *Semin Roentgenol* 2011;46:245-51.
22. Mohindra N, Jain N, Yadav S, et al. Utility of ultrasound Angio-PLUS imaging for detecting blood flow in breast masses and comparison with color Doppler for differentiating benign from malignant masses. *Acta Radiol* 2023;64:2087-95.
23. Gu Y, Tian JW, Ran HT, et al. The Utility of the Fifth Edition of the BI-RADS Ultrasound Lexicon in Category 4 Breast Lesions: A Prospective Multicenter Study in China. *Acad Radiol* 2022;29 Suppl 1:S26-34.
24. Lin X, Chang C, Wu C, et al. Confirmed value of shear wave elastography for ultrasound characterization of breast masses using a conservative approach in Chinese women: a large-size prospective multicenter trial. *Cancer Manag Res* 2018;10:4447-58.
25. Zhao Z, Hou S, Li S, et al. Application of Deep Learning to Reduce the Rate of Malignancy Among BI-RADS 4A Breast Lesions Based on Ultrasonography. *Ultrasound Med Biol* 2022;48:2267-75.
26. Gennisson JL, Deffieux T, Fink M, et al. Ultrasound elastography: principles and techniques. *Diagn Interv Imaging* 2013;94:487-95.
27. Sigrist RMS, Liao J, Kaffas AE, et al. Ultrasound Elastography: Review of Techniques and Clinical Applications. *Theranostics* 2017;7:1303-29.
28. Golatta M, Pfof A, Büsch C, et al. The Potential of Shear Wave Elastography to Reduce Unnecessary Biopsies in Breast Cancer Diagnosis: An International, Diagnostic, Multicenter Trial. *Ultraschall Med* 2023;44:162-8.
29. Baier J, Rix A, Kiessling F. Molecular Ultrasound Imaging. *Recent Results Cancer Res* 2020;216:509-31.
30. Tao Z, Qi H, Ma Y. Diagnostic efficacy of ultrasound elastography and dynamic contrast-enhanced MR in benign and malignant breast masses. *Am J Transl Res* 2023;15:2870-7.
31. Boca Bene I, Ducea SM, Ciurea AI. Contrast-Enhanced Ultrasonography in the Diagnosis and Treatment Modulation of Breast Cancer. *J Pers Med* 2021;11:81.
32. Yu MQ, Zhang LL, Jiang LP, et al. The value of contrast-enhanced ultrasound in the diagnosis of BI-RADS-US 4a lesions less than 2cm in diameter. *Clin Hemorheol Microcirc* 2023;83:195-205.

**Cite this article as:** Zhu Y, Jiang L, Chen YN, Wang M, Hieken TJ, Pan MF, Zhang D. The diagnostic value of real-time ultrasound elastography and contrast-enhanced ultrasound in BI-RADS 4A breast lesions. *Gland Surg* 2025;14(3):488-497. doi: 10.21037/gs-2025-93