

Enhancing breast projection in autologous reconstruction using the St Andrew's coning technique and 3D volumetric analysis

Michael P. Chae^{1,2}, Warren Matthew Rozen^{1,2,3}, Nakul Gamanlal Patel³, David J. Hunter-Smith^{1,2}, Venkat Ramakrishnan³

¹Department of Surgery, School of Clinical Sciences at Monash Health, Monash Medical Centre, Clayton, Victoria, Australia; ²Monash University Plastic and Reconstructive Surgery Group (Peninsula Clinical School), Peninsula Health, Frankston, Victoria, Australia; ³St Andrew's Centre for Plastic Surgery and Burns, Broomfield Hospital, Mid Essex Hospital Services NHS Trust, Chelmsford, UK

Contributions: (I) Conception and design: All authors; (II) Administrative support: WM Rozen, MP Chae; (III) Provision of study materials or patients: MP Chae, DJ Hunter-Smith, V Ramakrishnan; (IV) Collection and assembly of data: MP Chae, WM Rozen; (V) Data analysis and interpretation: MP Chae, WM Rozen; (VI) Manuscript writing: All authors; (VII) Final approval of manuscript: All authors.

Correspondence to: Warren Matthew Rozen, MBBS, BMedSc, MD, PhD, FRACS. Department of Plastic and Reconstructive Surgery, Frankston Hospital, Peninsula Health, 2 Hastings Road, Frankston, Victoria 3199, Australia. Email: warrenrozen@hotmail.com.

Background: An increasing number of women undergo mastectomy for breast cancer and post-mastectomy autologous breast reconstruction has been shown to significantly improve the psychosexual wellbeing of the patients. A goal of treatment is to achieve symmetry and projection to match the native breast, and/or the contralateral breast in the case of a unilateral reconstruction. Autologous reconstruction, particularly with the deep inferior epigastric artery perforator (DIEP) flap, is particularly advantageous as it can be manipulated to mimic the shape and turgor of the native breast. However, very few techniques of shaping the breast conus when inseting the DIEP flap to enhance aesthetic outcome have been reported to date. With the aid of three-dimension (3D) photography and 3D-printed mirrored image of the contralateral breast as a guide intraoperatively, we describe our St Andrew's coning technique to create a personalized flap projection.

Method: We report a prospective case series of 3 delayed unilateral breast reconstructions where symmetrization procedure to the contralateral breast was not indicated. Using a commercial 3D scanner (VECTRA XR, Canfield Scientific), the breast region was imaged. The mirrored image was 3D-printed in-house using a desktop 3D printer.

Results: In all cases, projection of the breast mound was able to be safely achieved, with a demonstrated central volume (or 'cone') able to be highlighted on imaging and a 3D printed breast. A 3D print of the contralateral breast was able to be used intraoperatively to guide the operative approach.

Conclusions: The St Andrew's coning technique is a useful aesthetic maneuver for achieving breast projection during DIEP flap breast reconstruction, with 3D imaging techniques able to assist in perioperative assessment of breast volume.

Keywords: Autologous breast reconstruction; deep inferior epigastric artery perforator (DIEP); shaping; coning technique; three-dimension photography (3D photography); three-dimension scanning (3D scanning)

Submitted May 15, 2017. Accepted for publication May 23, 2017.

doi: 10.21037/gs.2017.06.01

View this article at: <http://dx.doi.org/10.21037/gs.2017.06.01>

Introduction

The number of patients undergoing both prophylactic and therapeutic mastectomy has grown exponentially in the last decade due to the increased availability of genetic testing and breast cancer surveillance (1-4). For post-mastectomy patients, autologous breast reconstruction has shown to significantly improve their psychosexual well-being and has subsequently become an integral part of the breast cancer treatment (5-7). Using advanced imaging modalities, such as computed tomographic angiography (CTA), as a routine preoperative planning tool, deep inferior epigastric artery perforator (DIEP) free flap reconstruction has become a safe, reliable surgical technique, associated with enhanced clinical outcomes and patient satisfaction (8-13). In contrast to the vast number of studies investigating the vascular anatomy and imaging of the abdominal wall, the number of studies exploring various surgical techniques to enhance the aesthetic outcome of DIEP flaps is substantially fewer.

The influence of several preoperative factors on the aesthetic outcome of DIEP flaps has been documented, such as adjuvant radiotherapy, the timing of reconstruction, the choice of donor site, and the role of appropriate symmetrization procedure to the contralateral breast. However, an individual surgeon's ability to design a flap and manipulate it in three-dimension (3D) to fashion a patient-specific breast mound with appropriate shape and projection is ultimately one of the most important factors. To this effect, Blondeel *et al.* have outlined a "three-step" approach that can be applied systematically when shaping and inseting a DIEP flap in any clinical case: prepare the breast footprint, shape the conus, and cover the flap with appropriate skin envelope (14). Since then, a number of studies have published methods to improve the preparation of breast footprint and safe, reliable skin envelope by incorporating the breast aesthetic subunit principle and the "dual-plane" inseting techniques (15-20). In contrast, it is challenging to report in writing how a surgeon transforms a 2D flap into a 3D structure and only a small number of authors have described their technique of shaping the breast conus (14,21-23).

Blondeel *et al.* have outlined their "three-suture" technique for shaping DIEP flap, where the Scarpa's fascia is first sutured to the pectoralis fascia acing the flap under the pectoralis tendon, the second suture holds the lateral edge of the flap to the lateral inframammary fold (IMF) in tension, and the last suture is placed medially to form a smooth medial cleavage (14). In bilateral reconstruction,

Nahabedian describes a similar technique of ensuring appropriate flap projection with sutures at the medial and lateral edges, and additional superomedial, inferomedial or lateral sutures as required (21). However, in unilateral reconstruction, the author either "rolls" the flap into a cone or creates a lateral fold so that the zone 2 is placed under the zone 1 to provide projection (21). Using the conical folding technique in 126 unilateral reconstructions, Wang *et al.* demonstrated satisfactory projection and volume at 6-month follow-up (22).

Recently, Tomita *et al.* have exploited the growing accessibility and availability of imaging technologies, such as 3D photography, and 3D printing to assist preoperative planning and guide intraoperatively flap shaping and inseting in unilateral reconstructions (23). Using a commercial 3D scanner, the authors have scanned the breast region and created a mirrored image of the unaffected contralateral breast. This was 3D-printed as a mould and intraoperatively, the flap was placed inside it to trim and shape to fit. They report subjective assessment of satisfactory symmetrization and project at 2-month follow-up.

In recent times, reports using 3D photography, also known as 3D scanning or surface imaging, for volumetric analysis in breast reconstruction has been growing (24-37). Compared to the conventional imaging modalities, such as CT scans, 3D photography forgoes radiation exposure and a growing number of investigators have demonstrated its accuracy and reliability in breast application (26-28,32,35-37). Three types of 3D photography are most commonly utilized in medical application: laser imaging, structured light technique, and stereophotogrammetry. Based on passive stereophotogrammetry, VECTRA XR scanners (Canfield Scientific, Fairfield, NJ, USA) are arguably one of the most frequently investigated 3D scanners (35-37).

3D printing, also known as additive manufacturing or rapid prototyping, is a novel technology that can fabricate haptic biomodels of patient-specific anatomical structures using various imaging sources, such as 3D photography, CT scan, and magnetic resonance imaging (MRI) (38-40). In the last decade, 3D printers have become more affordable and convenient to use. In breast reconstruction, clinicians have used 3D printing to demonstrate breast volume differential both qualitatively and quantitatively for preoperative planning (41).

In the current study, we describe our St Andrew's coning technique for the first time, where circular rounds of suture are placed within the cutaneous layer of DIEP flaps to create projection. We have used a 3D-printed model of the

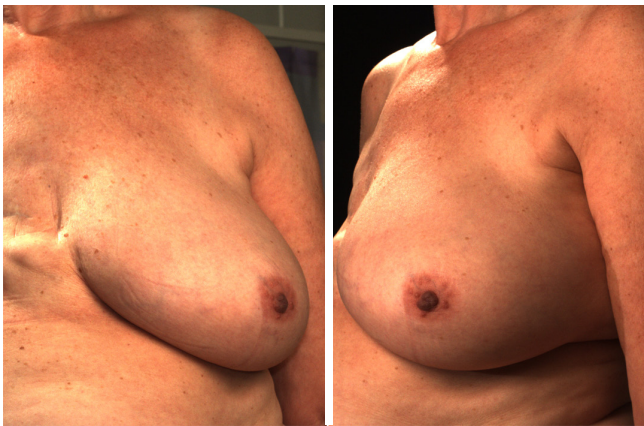

Figure 1 Standard preoperative photograph of a patient planned for breast reconstruction, with 2D images achieved using a commercial 3D scanner, VECTRA XR scanner (Canfield Scientific, Fairfield, NJ, USA).

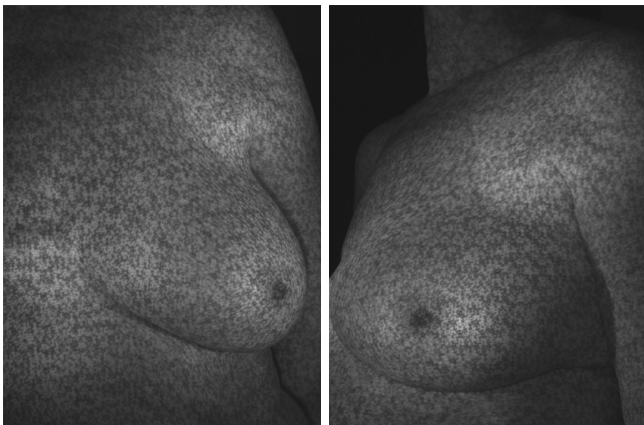

Figure 2 Pixelated photograph of the same patient as *Figure 1*, with contoured images achieved using a commercial 3D scanner, VECTRA XR scanner (Canfield Scientific, Fairfield, NJ, USA).

mirror image of the contralateral breast on the operating table to help determine desired flap projection prior to inseting the flap. We detail our suturing technique in a prospective case series of three delayed unilateral breast reconstructions where symmetrization to the contralateral breast was not indicated.

Methods

Patients

We describe the coning technique used on 1,000 consecutive

patients, with the volumetric analyses detailed having been performed in a prospective case series of 3 female patients who underwent delayed unilateral autologous breast reconstruction with DIEP flaps at St Andrew's Centre for Plastic Surgery and Burns, Chelmsford, UK. The mean age of the patients was 54 (range, 43 to 63) years. The inclusion criteria comprised unilateral reconstructions, in patients for who no contralateral symmetrisation procedure was planned, such as a reduction or augmentation mammoplasty. All procedures were performed by a single surgeon (VV).

3D photography

3D photography of the breast region was taken in all patients during the routine preoperative work-up using a commercial 3D scanner, VECTRA XR scanner (Canfield Scientific). Patients were asked to stand with their arms in varying positions and each scanning took approximately 1–2 seconds. Photographs were created in both standard format and pixelated format to highlight surface contour (see *Figures 1* and *2*). After waiting less than 5 minutes for image processing, a 3D image of the bilateral breasts was created (see *Figure 3*), able to manipulated in a multi-planar fashion as required, and exported from the proprietary software in a Standard Tessellation Language (STL) file format to be prepared for 3D printing.

3D printing

Firstly, the 3D image was cropped to isolate the contralateral breast and then, mirrored using the Magics software (Materialise NV, Leuven, Belgium). The file was exported and converted into a printer-friendly file using the MakerBot Desktop software (MakerBot Industries, New York, NY, USA). Subsequently, the mirrored images were 3D-printed using the MakerBot Z18 3D printer (MakerBot Industries), which took mean 10.5 hours per patient (range, 8.5–12 hours). The final products were immediately useful after removing from the printer's build plate (see *Figure 4*).

Coning technique

The surgical coning technique began after completion of flap harvest, after disconnection of the vascular pedicle. The breast base is transcribed onto the skin surface of the flap (see *Figure 5A*), in order to plan the central focus of coning for maximum projection. The non-projected flap can be highlighted at this point (see *Figure 5B*).

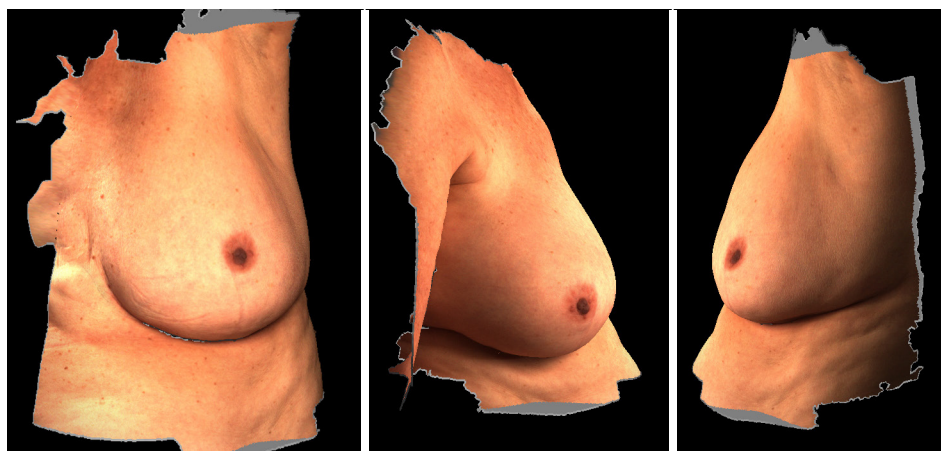


Figure 3 3D photograph of the same patient as *Figure 1*, with contoured images achieved using a commercial 3D scanner, VECTRA XR scanner (Canfield Scientific, Fairfield, NJ, USA).




Figure 4 3D-print using the MakerBot Z18 3D printer (MakerBot Industries), of the same patient as *Figure 1*.

The flap under-surface is used for placement of the coning sutures. A multi-filament, absorbable suture is placed through the sub-Scarpa's fat, and a continuous loose purse-string technique is used in this fashion to encircle the planned breast base, before tying the suture loosely (see *Figure 5C*). The sutures are placed superficially in order to avoid deep penetration which may occlude intra-flap vasculature. Two to three further such purse-string rings are created as needed, in increasing diameters from the initial purse-string, in order to create the desired amount of projection (see *Figure 5D*).

Results

In all cases, a demonstrable increase in central flap projection was achieved. The mean increase in central flap projection was 2.5 cm (range, 2–3.5 cm), achieving over 100% increases in central flap projection (see *Figure 2*).

There were no partial or complete flap failures, and no complications recorded attributed to the St Andrew's coning technique, or otherwise. In fact, no complications in the authors preceeding 1,000 cases of using this technique were attributable to the coning technique described.

Discussion

We describe the St Andrew's coning technique, where we supinate the DIEP flap after the flap harvest and place rounds of dissolvable sutures in the adipose tissue prior to the flap inset, in order to create an appropriate conus. We have individualized each flap to achieve optimal symmetrization by utilizing the 3D-printed haptic models of the mirrored image of the contralateral breast to adjust the suturing.

With increasing population, the rate of prevalence and incidence of breast cancer continues to rise and, in the

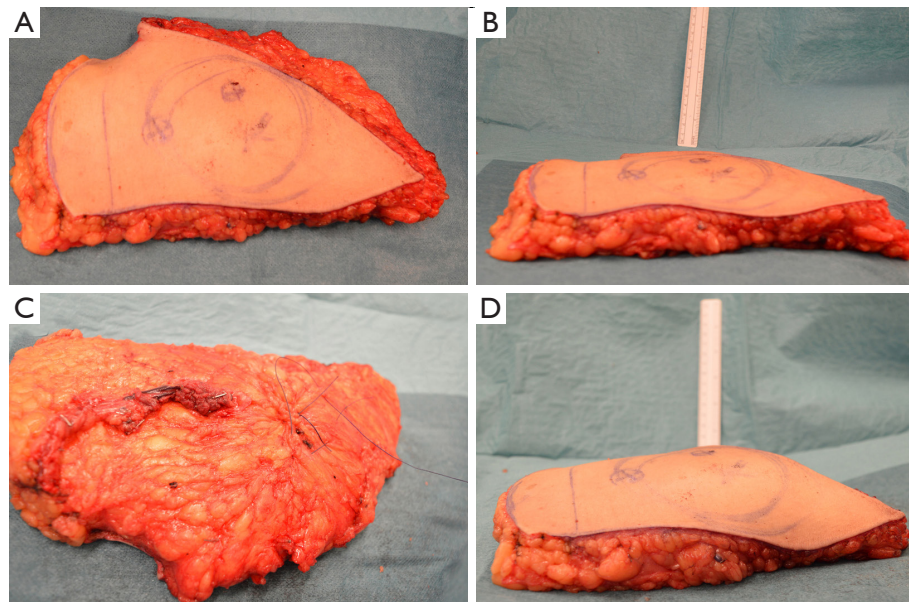


Figure 5 The surgical coning technique (same patient as other Figures). The breast base is transcribed onto the skin surface of the flap (A), in order to plan the central focus of coning for maximum projection. The non-projected flap is highlighted (B). The flap undersurface is used for placement of the coning sutures, placed through the sub-Scarpa's fat, and a continuous loose purse-string technique is used in this fashion to encircle the planned breast base, before tying the suture loosely (C). The sutures are placed superficially in order to avoid deep penetration which may occlude intra-flap vasculature. Two to three further such purse-string rings are created as needed, in increasing diameters from the initial purse-string, in order to create the desired amount of projection (D).

United States alone, one in eight women will be affected by the disease in their lifetime (42). Furthermore, an increasing number of women are receiving both therapeutic and prophylactic mastectomy for breast cancer, boosted by the increased availability of genetic testing (1-4). Encouragingly, post-mastectomy breast reconstruction has demonstrated to significantly improve the psychosexual wellbeing of patients and, as a result, it has become an integral part of the comprehensive treatment of breast cancer (5-7). Unlike synthetic implants, autologous reconstruction with abdominal wall as donor site yields a more natural-appearing and a longer-lasting outcome, without encountering the conventional prosthesis-related complications (43-46). Compared to the earlier TRAM flaps, DIEP flaps can provide adequate volume replacement, without significantly compromising the donor site to ventral bulge or hernia (47,48). Advancement of modern imaging technologies, especially the establishment of CTA as a routine preoperative planning tool in DIEP flap reconstruction, has enabled surgeons to select appropriate perforators and flap designs, leading to improved clinical outcomes (8-13).

In contrast to the studies investigating the vascular anatomy and imaging of the abdominal wall (12,24,49-55), there is a relative paucity of studies exploring surgical techniques to enhance aesthetic outcome in DIEP flap reconstructions. Several preoperative considerations are considered critical in order to ensure aesthetically satisfactory result, such as adjuvant radiotherapy, the timing of reconstruction, choice of donor site, and symmetrization of the contralateral breast via augmentation or reduction mammoplasty depending on the patient preference (21). However, the aesthetic outcome of DIEP flaps ultimately relies on an individual surgeon's technique and experience in flap shaping and inseting.

To this effect, Blondeel *et al.* have presented a systematic approach that reproducibly produces aesthetically-pleasing breast mound with DIEP flaps in any clinical situation: firstly, prepare the breast footprint; secondly, shape the conus; and lastly, cover the flap with suitable skin envelope (14). Creating the breast footprint and the skin envelope requires defining the IMF and replacing the mastectomy scar with aesthetic lines applying the breast aesthetic subunit principle (15). Initially, devised for planning nasal and facial

reconstructive surgeries (56-59), aesthetic subunit principle has also demonstrated to improve the cosmetic outcome and patient satisfaction when applied in autologous breast reconstructions (16-18). Recently, in a direct comparison study, Gravvanis *et al.* have reported that inseting DIEP flaps as a single aesthetic subunit, where the inferior mastectomy skin flap is deepithelialized and overlaid by the free flap so that a new IMF is defined using the edge of the free flap, yields a more natural shape and a satisfactory scar pattern than flap inseting as a double subunit, where the IMF is preserved (19). Similarly, when the mastectomy skin envelope is compromised due to radiation or is lacking in volume due to the reconstruction being delayed, this can be overcome by inseting the DIEP flap in “dual-plane”, below and above the pectoral muscle in the upper and lower pole respectively (20).

In contrast, only a few techniques of shaping the breast conus have been reported to date and the evidence is limited to sporadic case series and descriptive accounts (14,21-23). As Blondeel *et al.* points out this is likely attributable to the fact that describing how to manipulate a 2D structure (i.e., DIEP flap) into a 3D form (i.e., conus) is difficult to achieve in writing (14). Furthermore, the ability to think and handle tissue in 3D is considered a key skill of a well-trained plastic surgeon and the significance of its discussion may be overlooked (14). Nonetheless, the shape and the projection of an ideal conus is patient-specific and is critical towards achieving an aesthetically pleasing outcome and ensuring a high quality of life. Blondeel *et al.* describe a “three-suture” technique where the first key suture connects the Scarpa’s fascia to the pectoralis fascia and positions the DIEP flap underneath the pectoralis tendon. The second suture is used to affix the lateral edge of the flap to the most lateral edge of the IMF in tension. The last one is placed in the medial edge of the IMF to create a smooth medial cleavage (14). Similarly, Nahabedian reports his technique of securing medial and lateral edges of the free flap to the sternal border and the lateral chest wall respectively, in bilateral breast reconstructions, with superomedial, inferomedial and lateral sutures (21). In unilateral reconstructions, Nahabedian uses the contralateral breast as a template and folds the free flap either in a conical fashion or creates a lateral fold where the zone 2 is placed under the zone 1 and secured with a lateral suture (21). In 2015, Wang *et al.* report a retrospective case series of 126 unilateral DIEP reconstructions where the flap is folded into a cone before inseting (22). Regardless of the shape in which the flaps were harvested—fusiform, semi-circle, or crescent—the authors have noted satisfactory

breast projection and volume at 6-month follow-up. Interestingly, they have not reported patient satisfaction or quality of life data.

Recently, Tomita *et al.* have presented an algorithm incorporating the use of novel 3D scanning technology to guide surgeons shape patient-specific DIEP flaps in a prospective cohort of 11 delayed unilateral reconstructions (23). Preoperatively, the breast region is scanned with the patient sitting up, using a commercial 3D scanner, David Structured Light Scanner SLS-1 (David Vision Systems GmbH, Koblenz, Germany), from which the required flap volume is calculated. In addition, the scanned image of the contralateral breast is mirrored and 3D-printed as a mould. On the operating table, after the microvascular anastomosis, the flap is carefully placed inside the sterilized mould, from where it was trimmed to fit and the shape was secured with randomly-placed dissolvable sutures. The authors report good symmetrization and cosmetic effect at 2-month follow-up. One of the major limitations of this technique is that it is only applicable in unilateral reconstructions where the contralateral breast does not require a symmetrization procedure. Furthermore, the hard plastic mould does not account for postoperative swelling and facilitate “over-correction” of the volume of the reconstructed breast. Interestingly, the authors do not report the thickness of the breast mould, which may have led to further “under-correction” of the reconstruction. In comparison, the St Andrew’s coning sutures are readily reproducible and are flexible enough for the surgeon to tailor the technique to accommodate individual differences. In our series, none of our patients required a symmetrization procedure to the contralateral breast and we utilized the 3D-printed mirror image from 3D photography of the contralateral side to help surgeons guide placement of the St Andrew’s coning sutures.

3D photography captures the light reflected off a surface to construct a virtual 3D model (24). Originally used in automotive and aerospace industries, Galdino *et al.* first used the technology in plastic surgery to quantitatively assess breast symmetry (25). Similar to other medical imaging modalities, 3D surface imaging has advanced significantly in the last decade and is accurate, reliable, and simple to use (26-28). In clinical application for breast volumetric analysis and imaging, three 3D scanning techniques have been studied: laser imaging, structured light technique, and stereophotogrammetry. 3D laser imaging projects a particular pattern of laser (i.e., spot or stripe) and utilizes the triangulation calculation method to

determine a 3D coordinate (28,60). Konica Minolta 3D scanner (Konica Minolta Inc., Tokyo, Japan), one of the most extensively studied clinical laser scanner, has been utilized in planning implant breast reconstructions (30). However, its accuracy and validity has not yet been reported. Likewise, structured light technique projects an organised pattern of light (i.e. stripe, grid, or dots) and captures the distortion in the light pattern using multiple calibrated cameras to derive at 3D surface data (27,31). Axis Three Torso System (Axis Three, Miami, FL, USA) is the most frequently reported structured light 3D scanner and has demonstrated its accuracy and reliability in simulating breast augmentation outcomes (32). However, it has not been studied in autologous breast reconstructions. Based on the human eye physiology, stereophotogrammetry utilizes a stereo pair of cameras to derive 3D data from the points of light intersection (28,33,34). Depending on the presence of additional light being directly projected on to the object, stereophotogrammetry can be classified into: active, passive, and hybrid. Lacking the additional lighting to resist interference from the ambient light, passive stereophotogrammetry requires high-quality cameras in a carefully controlled environment. However, as a result, passive stereophotogrammetry scanners such as, our VECTRA XR scanners (Canfield Scientific), can capture high-resolution 3D photographs at fast speed and is one of the most extensively investigated commercial scanner in breast application (24). Several studies have demonstrated high accuracy and reliability of the VECTRA devices (35-37). However, its widespread use is limited by its high cost, relatively slow image-processing speed, and lack of portability.

3D printing describes a technology where haptic biomodels are fabricated in a layer-by-layer fashion using CAD files derived from routine medical imaging sources, such as 3D photography, CT and MRI scans (38-40). In contrast to the current medical imaging techniques, clinicians are able to interact hands-on with the 3D-printed biomodels, which enables a superior understanding of visuospatial relationship between the patient-specific anatomical structures. In clinical application, 3D printing is useful for preoperative planning, building intraoperative guidance devices, education of patients and junior doctors, and designing customized prosthesis. To date, investigators have utilized routine preoperative CTA scans in breast reconstructions to 3D-print accurate models that enables both qualitative and quantitative appreciation of the breast volume differential (41). In the current case

series, 3D-printed biomodels of mirrored image of the contralateral breast are brought into the operating theatre to help guide surgeons when performing the described St Andrew's coning sutures.

One of the major limitations of our study was that none of the patients required secondary corrective surgery, such as reduction mammoplasty, augmentation or mastopexy, to the contralateral side. It may be useful in the future utilize the Canfield Scientific's Breast Sculptor[®] software that reliably simulates breast procedure outcomes (37) in order to create the 3D image of an ideal reconstructed breast in each case that could be 3D-printed for use intraoperatively. Furthermore, assessment of outcome at long-term follow-up may have been useful to demonstrate clinical utility of the St Andrew's coning suture technique. In order to demonstrate the accuracy and reliability of our 3D scanning technique, the current study needs to be replicated in a larger, comparative study.

Conclusions

The St Andrew's coning technique is a useful aesthetic maneuver for achieving breast projection during DIEP flap breast reconstruction, with 3D imaging techniques able to assist in perioperative assessment of breast volume.

Acknowledgements

None.

Footnote

Conflicts of Interest: The authors have no conflicts of interest to declare.

Ethical Statement: The authors declare that the study obtained ethics approval for the use of 3D printing (Peninsula Health Human Research Ethics Committee, Reference/Approval number LRR/14/PH/33). Participants gave informed consent before taking part.

References

1. Kurian AW, Lichtensztajn DY, Keegan TH, et al. Use of and mortality after bilateral mastectomy compared with other surgical treatments for breast cancer in California, 1998-2011. *JAMA* 2014;312:902-14.
2. Kummerow KL, Du L, Penson DF, et al. Nationwide

- trends in mastectomy for early-stage breast cancer. *JAMA Surg* 2015;150:9-16.
3. Tuttle TM, Habermann EB, Grund EH, et al. Increasing use of contralateral prophylactic mastectomy for breast cancer patients: a trend toward more aggressive surgical treatment. *J Clin Oncol* 2007;25:5203-9.
 4. Wong SM, Freedman RA, Sagara Y, et al. Growing Use of Contralateral Prophylactic Mastectomy Despite no Improvement in Long-term Survival for Invasive Breast Cancer. *Ann Surg* 2017;265:581-9.
 5. Shons AR, Mosiello G. Postmastectomy breast reconstruction: current techniques. *Cancer Control* 2001;8:419-26.
 6. Elder EE, Brandberg Y, Bjorklund T, et al. Quality of life and patient satisfaction in breast cancer patients after immediate breast reconstruction: a prospective study. *Breast* 2005;14:201-8.
 7. Ng SK, Hare RM, Kuang RJ, et al. Breast Reconstruction Post Mastectomy: Patient Satisfaction and Decision Making. *Ann Plast Surg* 2016;76:640-4.
 8. Masia J, Clavero JA, Larranaga JR, et al. Multidetector-row computed tomography in the planning of abdominal perforator flaps. *J Plast Reconstr Aesthet Surg* 2006;59:594-9.
 9. Rozen WM, Anavekar NS, Ashton MW, et al. Does the preoperative imaging of perforators with CT angiography improve operative outcomes in breast reconstruction? *Microsurgery* 2008;28:516-23.
 10. Gill PS, Hunt JP, Guerra AB, et al. A 10-year retrospective review of 758 DIEP flaps for breast reconstruction. *Plast Reconstr Surg* 2004;113:1153-60.
 11. Bui DT, Cordeiro PG, Hu QY, et al. Free flap reexploration: indications, treatment, and outcomes in 1193 free flaps. *Plast Reconstr Surg* 2007;119:2092-100.
 12. Masia J, Kosutic D, Clavero JA, et al. Preoperative computed tomographic angiogram for deep inferior epigastric artery perforator flap breast reconstruction. *J Reconstr Microsurg* 2010;26:21-8.
 13. Macadam SA, Zhong T, Weichman K, et al. Quality of Life and Patient-Reported Outcomes in Breast Cancer Survivors: A Multicenter Comparison of Four Abdominally Based Autologous Reconstruction Methods. *Plast Reconstr Surg* 2016;137:758-71.
 14. Blondeel PN, Hijjawi J, Depypere H, et al. Shaping the breast in aesthetic and reconstructive breast surgery: an easy three-step principle. *Plast Reconstr Surg* 2009;123:455-62.
 15. Restifo RJ. The "aesthetic subunit" principle in late TRAM flap breast reconstruction. *Ann Plast Surg* 1999;42:235-9.
 16. Spear SL, Davison SP. Aesthetic subunits of the breast. *Plast Reconstr Surg* 2003;112:440-7.
 17. Song AY, Fernstrom MH, Scott JA, et al. Assessment of TRAM aesthetics: the importance of subunit integration. *Plast Reconstr Surg* 2006;117:15-24.
 18. Pulzl P, Schoeller T, Wechselberger G. Respecting the aesthetic unit in autologous breast reconstruction improves the outcome. *Plast Reconstr Surg* 2006;117:1685-91; discussion 1692-3.
 19. Gravvanis A, Smith RW. Shaping the breast in secondary microsurgical breast reconstruction: single- vs. two-esthetic unit reconstruction. *Microsurgery* 2010;30:509-16.
 20. Gravvanis A, Samouris G, Galani E, et al. Dual plane diep flap inset: Optimizing esthetic outcome in delayed autologous breast reconstruction. *Microsurgery* 2015;35:432-40.
 21. Nahabedian MY. Achieving ideal breast aesthetics with autologous reconstruction. *Gland Surg* 2015;4:134-44.
 22. Wang T, He J, Xu H, et al. Achieving Symmetry in Unilateral DIEP Flap Breast Reconstruction: An Analysis of 126 Cases over 3 Years. *Aesthetic Plast Surg* 2015;39:63-8.
 23. Tomita K, Yano K, Hata Y, et al. DIEP Flap Breast Reconstruction Using 3-dimensional Surface Imaging and a Printed Mold. *Plast Reconstr Surg Glob Open* 2015;3:e316.
 24. Chae MP, Rozen WM, Spychal RT, et al. Breast volumetric analysis for aesthetic planning in breast reconstruction: a literature review of techniques. *Gland Surg* 2016;5:212-26.
 25. Galdino GM, Nahabedian M, Chiamonte M, et al. Clinical applications of three-dimensional photography in breast surgery. *Plast Reconstr Surg* 2002;110:58-70.
 26. Tzou CH, Artner NM, Pona I, et al. Comparison of three-dimensional surface-imaging systems. *J Plast Reconstr Aesthet Surg* 2014;67:489-97.
 27. Olesen OV, Paulsen RR, Hojgaard L, et al. Motion tracking in narrow spaces: a structured light approach. *Med Image Comput Assist Interv* 2010;13:253-60.
 28. Lane C, Harrell W Jr. Completing the 3-dimensional picture. *Am J Orthod Dentofacial Orthop* 2008;133:612-20.
 29. Thoma A, Veltri K, Khuthaila D, et al. Comparison of the deep inferior epigastric perforator flap and free transverse rectus abdominis myocutaneous flap in postmastectomy reconstruction: a cost-effectiveness analysis. *Plast Reconstr Surg* 2004;113:1650-61.
 30. Tepper OM, Karp NS, Small K, et al. Three-dimensional imaging provides valuable clinical data to aid in unilateral tissue expander-implant breast reconstruction. *Breast J* 2008;14:543-50.
 31. Geng J. Structured-light 3D surface imaging: a tutorial. *Adv Opt Phot* 2011;3:128-60.

32. Mailey B, Freel A, Wong R, et al. Clinical accuracy and reproducibility of Portrait 3D Surgical Simulation Platform in breast augmentation. *Aesthet Surg J* 2013;33:84-92.
33. Halazonetis DJ. Acquisition of 3-dimensional shapes from images. *Am J Orthod Dentofacial Orthop* 2001;119:556-60.
34. Moyer HR, Carlson GW, Styblo TM, et al. Three-dimensional digital evaluation of breast symmetry after breast conservation therapy. *J Am Coll Surg* 2008;207:227-32.
35. de Menezes M, Rosati R, Ferrario VF, et al. Accuracy and reproducibility of a 3-dimensional stereophotogrammetric imaging system. *J Oral Maxillofac Surg* 2010;68:2129-35.
36. Rosati R, De Menezes M, Rossetti A, et al. Digital dental cast placement in 3-dimensional, full-face reconstruction: a technical evaluation. *Am J Orthod Dentofacial Orthop* 2010;138:84-8.
37. Roostaeian J, Adams WP Jr. Three-Dimensional Imaging for Breast Augmentation: Is This Technology Providing Accurate Simulations? *Aesthet Surg J* 2014;34:857-75.
38. Kamali P, Dean D, Skoracki R, et al. The Current Role of Three-Dimensional (3D) Printing in Plastic Surgery. *Plast Reconstr Surg* 2016. [Epub ahead of print].
39. Chae MP, Rozen WM, McMenamin PG, et al. Emerging Applications of Bedside 3D Printing in Plastic Surgery. *Front Surg* 2015;2:25.
40. Gerstle TL, Ibrahim AM, Kim PS, et al. A plastic surgery application in evolution: three-dimensional printing. *Plast Reconstr Surg* 2014;133:446-51.
41. Chae MP, Hunter-Smith DJ, Spychal RT, et al. 3D volumetric analysis for planning breast reconstructive surgery. *Breast Cancer Res Treat* 2014;146:457-60.
42. DeSantis C, Ma J, Bryan L, et al. Breast cancer statistics, 2013. *CA Cancer J Clin* 2014;64:52-62.
43. Kroll SS. Why autologous tissue? *Clin Plast Surg* 1998;25:135-43.
44. Pomahac B, Recht A, May JW, et al. New trends in breast cancer management: is the era of immediate breast reconstruction changing? *Ann Surg* 2006;244:282-8.
45. Saulis AS, Mustoe TA, Fine NA. A retrospective analysis of patient satisfaction with immediate postmastectomy breast reconstruction: comparison of three common procedures. *Plast Reconstr Surg* 2007;119:1669-76; discussion 1677-8.
46. Brinkman JN, Timman R, Gopie JP, et al. Aesthetic outcome after implant and DIEP flap breast reconstruction: An exploratory, prospective comparison of 25 cases. *J Plast Reconstr Aesthet Surg* 2015;68:1018-9.
47. Koshima I, Soeda S. Inferior epigastric artery skin flaps without rectus abdominis muscle. *Br J Plast Surg* 1989;42:645-8.
48. Allen RJ, Treece P. Deep inferior epigastric perforator flap for breast reconstruction. *Ann Plast Surg* 1994;32:32-8.
49. Moon HK, Taylor GI. The vascular anatomy of rectus abdominis musculocutaneous flaps based on the deep superior epigastric system. *Plast Reconstr Surg* 1988;82:815-32.
50. Losken A, Fishman I, Denson DD, et al. An objective evaluation of breast symmetry and shape differences using 3-dimensional images. *Ann Plast Surg* 2005;55:571-5.
51. Campaigne BN, Katch VL, Freedson P, et al. Measurement of breast volume in females: description of a reliable method. *Ann Hum Biol* 1979;6:363-7.
52. Chang JB, Small KH, Choi M, et al. Three-dimensional surface imaging in plastic surgery: foundation, practical applications, and beyond. *Plast Reconstr Surg* 2015;135:1295-304.
53. Losken A, Seify H, Denson DD, et al. Validating three-dimensional imaging of the breast. *Ann Plast Surg* 2005;54:471-6; discussion 477-8.
54. Kim H, Mun GH, Wiraatmadja ES, et al. Preoperative magnetic resonance imaging-based breast volumetry for immediate breast reconstruction. *Aesthetic Plast Surg* 2015;39:369-76.
55. Holm C, Mayr M, Hoffer E, et al. Perfusion zones of the DIEP flap revisited: a clinical study. *Plast Reconstr Surg* 2006;117:37-43.
56. Menick FJ. Artistry in aesthetic surgery. Aesthetic perception and the subunit principle. *Clin Plast Surg* 1987;14:723-35.
57. Burget GC, Menick FJ. The subunit principle in nasal reconstruction. *Plast Reconstr Surg* 1985;76:239-47.
58. Gonzalez-Ulloa M. Restoration of the face covering by means of selected skin in regional aesthetic units. *Br J Plast Surg* 1956;9:212-21.
59. Warpeha RL. Resurfacing the burned face. *Clin Plast Surg* 1981;8:255-67.
60. Hill DL, Berg DC, Raso VJ, et al. Evaluation of a laser scanner for surface topography. *Stud Health Technol Inform* 2002;88:90-4.

Cite this article as: Chae MP, Rozen WM, Patel NG, Hunter-Smith DJ, Ramakrishnan V. Enhancing breast projection in autologous reconstruction using the St Andrew's coning technique and 3D volumetric analysis. *Gland Surg* 2017;6(6):706-714. doi: 10.21037/g.s.2017.06.01