



Salmonella thyroid abscess—two case reports

Kah Seng Khoo¹, Peng Soon Koh², Khoon Leong Ng³

¹Surgical Resident, Department of Surgery, Faculty of Medicine, University of Malaya, Kuala Lumpur, Malaysia; ²General & Hepato-biliary Surgeon, Department of Surgery, Faculty of Medicine, University of Malaya, Kuala Lumpur, Malaysia; ³General & Endocrine Surgeon, Department of Surgery, Faculty of Medicine, University of Malaya, Kuala Lumpur, Malaysia

Correspondence to: Dr. Khoon Leong Ng, General & Endocrine Surgeon, Department of Surgery, Faculty of Medicine, University of Malaya, 50603 Kuala Lumpur, Malaysia. Email: ngkl@um.edu.my.

Abstract: Acute suppurative thyroiditis account for <1% of thyroid diseases and is uncommon because of the gland's encapsulation, iodine-rich environment, good vascular supply and extensive lymphatic drainage. It has been reported in patients with underlying goiters, thyroid cancers and in immuno-compromised patients. The usual causative organisms are *Staphylococci spp.* and *Streptococci spp.* Rarer organisms include *Klebsiella spp.* and *Salmonella spp.* Due to its rarity (as there have been only 28 cases of *Salmonella* thyroid abscess being reported in the literature till 2020), only case reports are available to guide management. We report two cases of thyroid abscess due to *Salmonella enteritidis* in our institution that may herald the re-emergence of this uncommon infection of the thyroid gland and to raise awareness for all clinicians. Both patients presented with neck swelling, dysphagia and sepsis. Surgical intervention was warranted in both patients due to the severity of the disease and failed medical therapy. Recovery was uneventful following adequate surgical intervention and antibiotic therapy according to the culture and sensitivity report of the pathogen. This case report highlights that both patients were immunocompromised, and they contracted *Salmonella* thyroid abscess without any gastrointestinal involvement. Thus, a high index of suspicion for *Salmonella* thyroid abscess in immunocompromised patients can expedite the diagnosis and appropriate management can be commenced such as antibiotic therapy, percutaneous aspiration and surgical drainage in the event of failed medical therapy.

Keywords: Infection; Salmonella; thyroid abscess; case report

Submitted Apr 27, 2020. Accepted for publication Nov 18, 2020.

doi: 10.21037/gs-20-474

View this article at: <http://dx.doi.org/10.21037/gs-20-474>

Introduction

Bacterial infections of the thyroid gland rarely occur due to its extensive vascular and lymphatic supply, the iodine-rich environment, the gland's encapsulation and its separation from other neck structures by fascial planes. Most bacterial thyroid abscesses are caused by Gram-positive organisms, particularly *Staphylococcus* and *Streptococcus* species.

Rarer organisms such as Gram-negative organisms, fungi and *Tuberculosis* have been reported in thyroid abscesses but these cases have been uncommon. We report two cases of *Salmonella* thyroid abscess which presented in our institution within a period of three months. *Salmonella* thyroid abscess is extremely rare and only 28 cases have been reported until

the year 2020 (1). In this report, we review the presentation of this rare infection and the subsequent management of the patients who presented to us. This case report is presented in accordance with the CARE reporting checklist (available at <http://dx.doi.org/10.21037/gs-20-474>) (2).

Case presentation

Patient A

A 41-year-old man with newly diagnosed diabetes mellitus presented with a 3-week history of a progressively enlarging right neck swelling. The neck swelling was associated with fever, pain and dysphagia. There was no history of

other significant medical conditions, thyroid disease or neck trauma. On examination, he was febrile at 38.4 °C and tachycardic with a pulse rate of 105 beats per minute. Other hemodynamic parameters were otherwise normal. Examination revealed a tender, warm, fluctuant and erythematous swelling in the right anterior neck. There were no signs of trauma to the neck. Examination of the oral cavity was normal. Systemic review was otherwise unremarkable.

Blood investigation revealed leucocytosis at $13.9 \times 10^9/L$ with neutrophil predominance. The random blood glucose and glycated hemoglobin (HbA1c) levels were both elevated at 19.5 mmol/L and 9.70% respectively. Other blood investigations were unremarkable. An urgent ultrasound scan of the neck revealed a large irregular collection at the anterior aspect right side of the neck measuring 5.8 cm (AP) \times 6.7 cm (W) with the contents showing heterogenous echogenicity. The right thyroid lobe and isthmus could not be visualized. There was no evidence of retrosternal extension. Cervical lymphadenopathy was also noted bilaterally.

A fine-needle aspiration of the swelling was performed on the same day and pus was obtained. Pus cultures grew *Salmonella enteritidis*, sensitive to ampicillin, ciprofloxacin and Piperacillin-Tazobactam. The diagnosis of right thyroid abscess was made and the patient was started on intravenous Piperacillin-Tazobactam after consultation with the infectious disease team. The patient's diabetes mellitus was also controlled with an insulin infusion.

The patient's condition did not improve even after 24 hours of intravenous antibiotic therapy and the swelling and fever persisted. Neck exploration was subsequently performed on day 2 of hospital admission. Intra-operatively, a right-sided thyroid abscess was confirmed. The right strap muscles were eroded and the right thyroid lobe was necrotic with loss of normal anatomical features (*Figure 1A*). The abscess was drained of 100 mL of pus (*Figure 1B*) and wound debridement performed. Pus samples sent for culture grew *Salmonella enteritidis*. A corrugated drain was inserted and daily irrigation with saline and povidone-iodine was instituted (*Figure 1C*). The patient was maintained on intravenous Piperacillin-Tazobactam 4.5 gms thrice a day for 5 days and therapy de-escalated to oral Ciprofloxacin 200 mg twice a day as his condition improved. Histopathological analysis of tissue excised during surgery revealed features consistent with an abscess.

Post-operatively, the patient recovered well with normalization of the leucocyte count. A post-operative

computed tomography (CT) scan of the neck on day 5 of admission showed abscess resolution and right thyroid lobe erosions (*Figure 1D*). The wound was subsequently allowed to close via secondary intention. He was discharged well after a week of hospital stay. During his out-patient follow-up, the patient remained in good health and his wound had healed. A timeline of the treatment is shown in *Figure 1*.

Patient B

A 48-year-old man with a long-standing multi-nodular goiter and HIV disease since 2005 presented with 2-week history of dysphagia and odynophagia where he could only tolerate small amounts of food and fluids. This was associated with hoarseness of voice and a left anterior neck swelling which was painful and progressively enlarging. There was no significant past history of surgery, neck trauma or thyroid disease. On examination, the patient had a high-grade fever but other hemodynamic parameters were otherwise normal. There was a large left-sided tender and warm neck swelling with erythematous overlying skin (*Figure 2A*).

Blood investigations revealed leucocytosis at $18.9 \times 10^9/L$ and a normal thyroid function test. Other blood investigations were unremarkable. An urgent ultrasound scan of the neck showed a large left thyroid mass with multiple cervical lymph nodes present. A computer tomography (CT) scan was subsequently performed and it showed an enlarged left thyroid lobe that was cystic, measuring 11.8 \times 9.9 \times 11.3 cm, suggestive of a thyroid abscess. The trachea and esophagus were displaced to the right.

The patient was initially started on intravenous Cefuroxime. However, the infection worsened and the antibiotics were switched to Piperacillin-Tazobactam. A neck exploration was subsequently performed on day 1 of hospital admission. Intra-operatively, an enlarged left thyroid lobe, consisting of a large abscess was found. The abscess ruptured during mobilisation and 500 mLs of pus was drained. The remnant rim of thyroid tissue was found to be adherent to the left sternocleidomastoid and strap muscles and the trachea. The decision was then made to perform a left hemi-thyroidectomy (*Figure 2B*). The left recurrent laryngeal nerve and left parathyroid glands were preserved during surgery. Pus cultures from the abscess grew *Salmonella enteritidis*.

Post-operatively, intravenous Piperacillin-Tazobactam was continued for a week and the patient improved. He was

Timeline of patient A (January 2017)

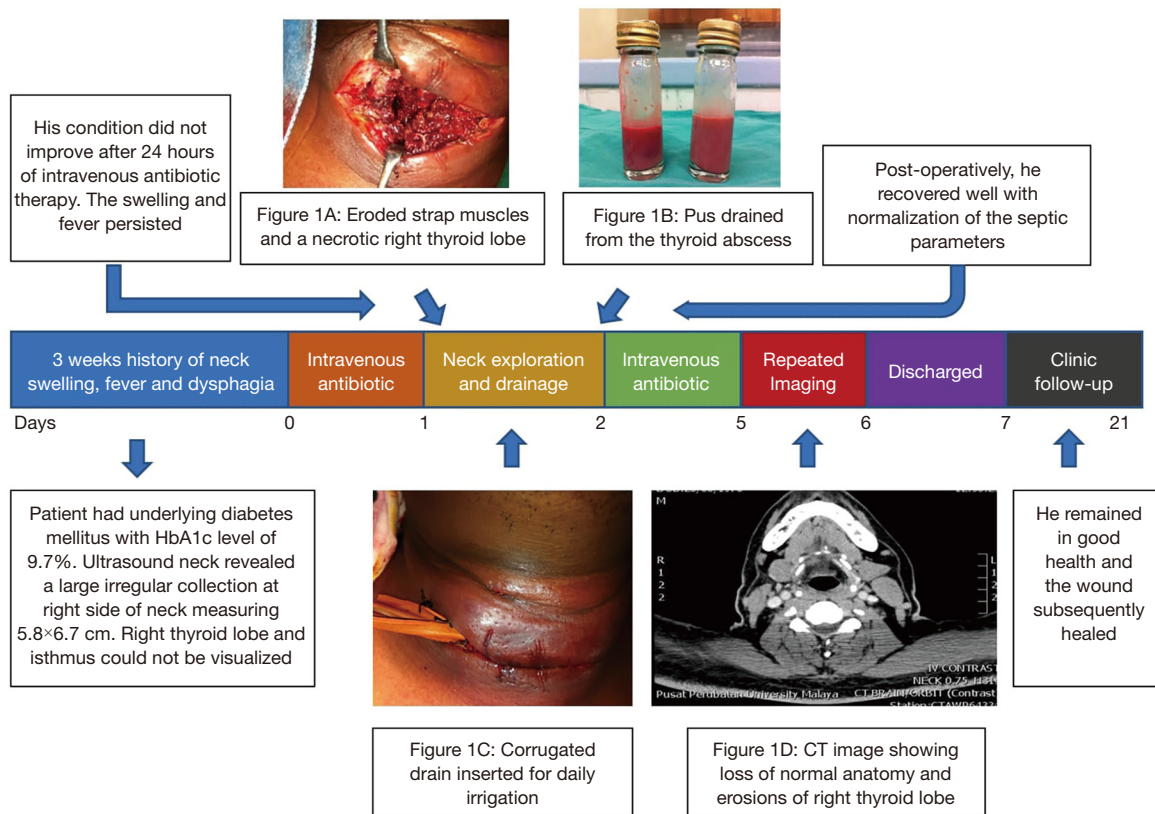


Figure 1 Timeline of patient A.

discharged well ten days after surgery with regular alginate wound dressing. During a scheduled outpatient follow-up visit, his wound had healed and a thyroid function test showed euthyroid status. No further imaging was indicated during this and subsequent follow-up. A timeline of the treatment is shown in *Figure 2*.

All procedures performed in studies involving human participants were in accordance with the ethical standards of the institutional research committee and with the Helsinki Declaration (as revised in 2013). Written informed consent was obtained from the patient for the publication of this study and any accompanying images.

Discussion

Acute infection of the thyroid gland is uncommon as it is inherently protected. Thyroid abscesses are uncommon owing to the gland’s encapsulation, extensive vascular supply, lymphatic drainage as well as the iodine-rich environment.

However, this diagnosis needs to be considered in patients who present with a tender neck swelling, especially in immunocompromised patients. Majority of the pathogens are *Staphylococcus* and *Streptococcus* species in about 35–40% of cases. Gram-negative organisms account for about 25% cases, whereas anaerobes make up 12% of cases. Fungal and tuberculosis are rare infections (3,4). In 1893, Bruns reported the first case of tuberculous thyroiditis. Since then, relatively few cases have been reported, and most have been associated with tubercular foci elsewhere in the body (5). *Helicobacter cinaedi* have also been reported as a causative organism by Takehara *et al.* (6). Complications of thyroid abscesses include trachea or esophageal perforation, descending necrotizing mediastinitis and extension into the deep spaces of neck (7).

Salmonella enteritidis is one of the commoner serovars of the *Salmonella enterica* group, the others being *Salmonella typhi* and *Salmonella typhimurium*. It is a pathogen, causing disease involving the GI tract. Infection often occurs

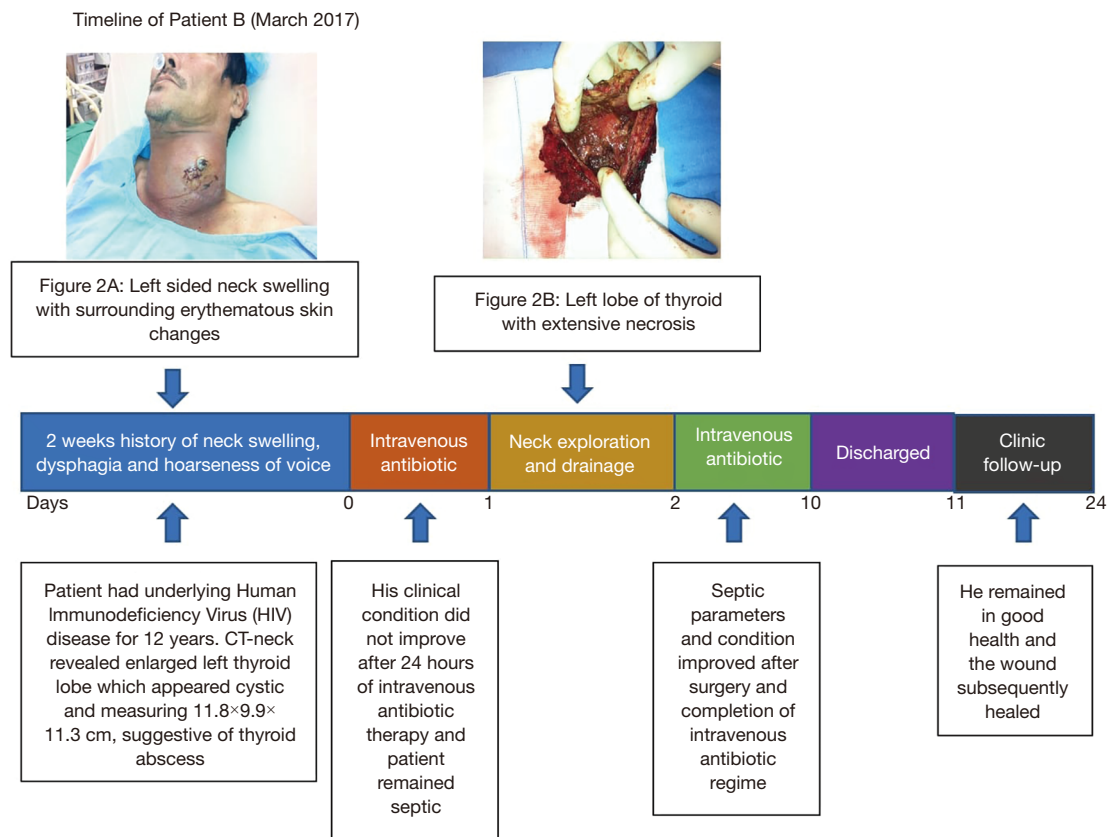


Figure 2 Timeline of patient B.

following food poisoning. Hematogenous spread may lead to abscess formation in the liver and spleen although other sites like the thyroid gland have been reported previously.

Salmonella enteritidis was detected in both our cases. This is a rare infection of the thyroid gland; thyroid abscesses have been reported with other salmonella serotypes such as *Salmonella brandenburg* and *Salmonella typhimurium* (8,9). Although *Salmonella enteritidis* is often associated with gastrointestinal symptoms, none were present in both our patients. In a review by Berger *et al.* covering the period 1900–1980, 40 cases were reported with *Salmonella spp.* as the causative organism. Subsequent reviews by Jacobs *et al.* and Yu *et al.* covering the period 1980–2000 showed a significant drop, with only 8 cases reported (4,10).

An underlying cause may not be identified in all cases of thyroid abscesses, but piriform sinus fistulae, foreign bodies such as chicken or fish bones, immuno-suppression, goiters, thyroid cancers and previous fine needle aspiration have been reported as probable causes (11,12). In both our patients, the most likely predisposing cause was immuno-

suppression due to underlying co-morbid conditions, diabetes mellitus in Patient A and HIV in Patient B. Few thyroid abscesses in diabetic patients have been reported previously (13). In a review of Kazi *et al.* *Salmonella* thyroid abscess had been reported in a HIV positive man (14).

Treatment options of thyroid abscesses vary. It is dependent on the size of the abscess, severity and response to initial management. Frequently, conservative treatment alone with appropriate antibiotics is sufficient, where regression of the abscess may be monitored by serial ultrasound scans (15). Repeat aspiration or percutaneous drainage of thyroid abscess combined with antibiotics may be required to control the sepsis and avoid surgical intervention as reported by Falhammar *et al.* and Vengathajalam *et al.* (16,17). Frequent monitoring and early detection of clinical deterioration is needed. Surgical drainage is the next option and may be appropriate for a large abscess (18). If there is concomitant extensive tissue necrosis, thyroidectomy at the same sitting should be considered. In Patient B, the decision to proceed with

a hemi-thyroidectomy was due to a large abscess and extensive tissue necrosis with little remaining thyroid tissue. The decision to proceed with hemi-thyroidectomy should not be taken lightly as the complication rate may be high in the face of infection and inflammation. Both patients were satisfied with the treatment provided.

Salmonella thyroid abscess is a rare disease and the occurrence of 2 cases within 3 months in our center could be due to the immunocompromised state of both patients and the relatively common occurrence of *Salmonella* infections in our country. Due to the rarity of *Salmonella* thyroid abscess, we have only documented these 2 cases over the past 10 years in our center. Clinicians should be alerted to the possibility of *Salmonella* thyroid abscess in immunocompromised patients who present with acute onset of neck swelling and dysphagia without any gastrointestinal manifestations. Favorable outcomes were observed in both these patients in our center due to early diagnosis and timely management although there are no clear guidelines or treatment algorithms available from the literature.

In conclusion, *Salmonella* thyroid abscess is a rare infection of the thyroid gland and is frequently associated with immuno-compromised patients. The hematogenous route remains the most likely mechanism of spread when no other local cause can be identified. The recent cases in our institution alerts us to the possibility of the re-emerging virulence of *Salmonella* infection, especially in immuno-compromised patients. Antibiotics and surgical drainage remain the mainstay of treatment although thyroidectomy may be considered if extensive necrosis is present.

Acknowledgments

Funding: None.

Footnote

Reporting Checklist: The authors have completed the CARE reporting checklist. Available at <http://dx.doi.org/10.21037/gs-20-474>

Conflicts of Interest: All authors have completed the ICMJE (International Committee of Medical Journal Editors) uniform disclosure form (available at <http://dx.doi.org/10.21037/gs-20-474>). The authors have no conflicts of interest to declare.

Ethical Statement: The authors are accountable for all

aspects of the work in ensuring that questions related to the accuracy or integrity of any part of the work are appropriately investigated and resolved. All procedures performed in studies involving human participants were in accordance with the ethical standards of the institutional research committee and with the Helsinki Declaration (as revised in 2013). Written informed consent was obtained from both patients for publication of this study and any accompanying images. A copy of the written consent is available for review by the Editor-in-Chief of this journal.

Open Access Statement: This is an Open Access article distributed in accordance with the Creative Commons Attribution-NonCommercial-NoDerivs 4.0 International License (CC BY-NC-ND 4.0), which permits the non-commercial replication and distribution of the article with the strict proviso that no changes or edits are made and the original work is properly cited (including links to both the formal publication through the relevant DOI and the license). See: <https://creativecommons.org/licenses/by-nc-nd/4.0/>.

References

1. AlYousef MK, Al-Sayed AA, Al Affif A, et al. A pain in the neck: *Salmonella* spp. as an unusual cause of a thyroid abscess. A case report and review of the literature. *BMC Infect Dis* 2020;20:436.
2. Riley DS, Barber MS, Kienle GS, et al. CARE 2013 explanations and elaborations: Reporting guidelines for case reports. *J Clin Epidemiol* 2017;89:218-35.
3. Yedla N, Pirela D, Manzano A, et al. Thyroid Abscess: Challenges in Diagnosis and Management. *J Investig Med High Impact Case Rep* 2018;6:2324709618778709.
4. Jacobs A, Gros DA, Gradon JD. Thyroid abscess due to *Acinetobacter calcoaceticus*: case report and review of the causes of and current management strategies for thyroid abscesses. *South Med J* 2003;96:300-7.
5. Bahgat M, Bahgat Y, Bahgat A, et al. Acute tuberculous abscess of the thyroid gland. *BMJ Case Rep* 2012;2012:bcr2012006906.
6. Takehara T, Tani T, Yajima K, et al. First case report of thyroid abscess caused by *Helicobacter cinaedi* presenting with thyroid storm. *BMC Infect Dis* 2019;19:166.
7. Brown J, Nguyen HH, Cohen SH. A pain in the neck: thyroid abscess. *Am J Med* 2014;127:e5-6.
8. Su DH, Huang TS. Acute suppurative thyroiditis caused by *Salmonella typhimurium*: a case report and review of the literature. *Thyroid* 2002;12:1023-7.

9. Chiovato L, Canale G, Maccherini D, et al. *Salmonella* brandenburg: a novel cause of acute suppurative thyroiditis. *Acta Endocrinol (Copenh)* 1993;128:439-42.
10. Yu EH, Ko WC, Chuang YC, et al. Suppurative *Acinetobacter baumannii* thyroiditis with bacteremic pneumonia: case report and review. *Clin Infect Dis* 1998;27:1286-90.
11. Barton GM, Shoup WB, Bennett WG, et al. Combined *Escherichia coli* and *Staphylococcus aureus* thyroid abscess in an asymptomatic man. *Am J Med Sci* 1988;295:133-6.
12. Cawich SO, Hassranah D, Naraynsingh V. Idiopathic thyroid abscess. *Int J Surg Case Rep* 2014;5:484-6.
13. Ambroziak U, Pachucki J, Bednarczuk T, et al. Suppurative thyroiditis caused by *Salmonella enteritidis*. *Endokrynol Pol* 2011;62:466-70.
14. Kazi S, Liu H, Jiang N, et al. *Salmonella* thyroid abscess in human immunodeficiency virus-positive man: a diagnostic pitfall in fine-needle aspiration biopsy of thyroid lesions. *Diagn Cytopathol* 2015;43:36-9.
15. Igler C, Zahn T, Muller D. Thyroid abscess caused by *Salmonella enteritidis*. *Dtsch Med Wochenschr* 1991;116:695-8.
16. Falhammar H, Wallin G, Calissendorff J. Acute suppurative thyroiditis with thyroid abscess in adults: clinical presentation, treatment and outcomes. *BMC Endocr Disord* 2019;19:130.
17. Vengathajalam S, Retinasekharan S, Mat Lazim N, et al. *Salmonella* Thyroid Abscess Treated by Serial Aspiration: Case Report and Literature Review. *Indian J Otolaryngol Head Neck Surg* 2019;71:823-6.
18. van Bon AC, Krudop W, van Eeden S, et al. Pain in the throat due to acute suppurative thyroiditis caused by *Salmonella*. *Ned Tijdschr Geneeskd* 2008;152:2084-7.

Cite this article as: Khoo KS, Koh PS, Ng KL. *Salmonella* thyroid abscess—two case reports. *Gland Surg* 2020;9(6):2198-2203. doi: 10.21037/gs-20-474