



# Hypercalcemic crisis caused by primary hyperparathyroidism in a 11-year-old boy: a rare case report and review of the literature

Shigeki Hayashi<sup>1</sup>, Takaaki Oba<sup>1</sup>, Kanami Ichikawa<sup>2</sup>, Chizuko Nakamura<sup>2</sup>, Yosuke Hara<sup>2</sup>, Toshiharu Kanai<sup>1</sup>, Yoshinori Sato<sup>3</sup>, Takeshi Uehara<sup>3</sup>, Ken-Ichi Ito<sup>1</sup>

<sup>1</sup>Division of Breast and Endocrine Surgery, Department of Surgery, Shinshu University School of Medicine, Matsumoto, Japan; <sup>2</sup>Department of Pediatrics, Shinshu University School of Medicine, Matsumoto, Japan; <sup>3</sup>Department of Laboratory Medicine, Shinshu University School of Medicine, Matsumoto, Japan

Correspondence to: Takaaki Oba. Division of Breast and Endocrine Surgery, Department of Surgery, Shinshu University School of Medicine, Matsumoto, Japan. Email: takaoba@shinshu-u.ac.jp.

**Background:** Hypercalcemic crisis caused by primary hyperparathyroidism (PHPT) in pediatric patients is very rare, and appropriate treatment approach for this condition has not been well demonstrated. Here, we report a case of PHPT-induced hypercalcemic crisis in a boy.

**Case Description:** An 11-year-old boy visited the clinic with abdominal pain and nausea that lasted for 3 months, but the cause of his symptoms could not be identified. As these symptoms worsened after 1 month, he was referred to a nearby hospital. The boy's albumin-corrected serum calcium level was very high (14.3 mg/dL). Treatment was immediately started with the administration of normal saline, furosemide, and calcitonin to lower his serum calcium levels. Based on elevated intact-parathyroid hormone (i-PTH) (405 pg/mL) level and enlargement of the right superior parathyroid on diagnostic imaging, he was diagnosed with hypercalcemic crisis due to PHPT. As his albumin-corrected serum calcium level increased to 16.5 mg/dL and he could not take almost any foods due to severe nausea, he was transferred to our hospital and treated with pamidronate. Although his albumin-corrected serum calcium level decreased to 14.0 mg/dL, his symptoms did not improve completely. Therefore, 2 days after transfer to our hospital, he underwent emergency surgery to resect the enlarged right superior parathyroid gland. Fifteen minutes after removal of the enlarged parathyroid gland, the serum intact-PTH level decreased to 41.7 pg/mL. The histopathological diagnosis of the enlarged parathyroid gland was adenoma. The boy became asymptomatic, and his albumin-corrected serum calcium level was maintained within the normal limits for 6 months post operatively. Genetic testing performed after the surgery did not detect any pathogenic mutations in the *MEN1* and *CDC73* genes, and no genetic predisposition has been identified to date.

**Conclusions:** Emergency focused parathyroidectomy prior to genetic testing might be an appropriate strategy when the pediatric patient presents with a PHPT-induced hypercalcemic crisis.

**Keywords:** Hypercalcemic crisis; primary hyperparathyroidism (PHPT); pediatric patients; case report

Submitted Feb 17, 2022. Accepted for publication May 18, 2022.

doi: 10.21037/gs-22-92

View this article at: <https://dx.doi.org/10.21037/gs-22-92>

## Introduction

Primary hyperparathyroidism (PHPT) is a common endocrine disorder among adults (1). However, PHPT in pediatric patients is rare, with an estimated incidence of 1 case per 300,000 pediatric patients (2). To date, only approximately 200 cases of PHPT among pediatric patients

and adolescents have been reported worldwide (3).

One of the unique characteristics of PHPT in pediatric patients is that affected patients tend to have symptoms of PHPT before the diagnosis of hypercalcemia (2), which is in contrast to the dominance of asymptomatic PHPT in adults. This PHPT feature in adults is considered to attribute

to the increased frequency of serum calcium level checks in a health screening (4). Meanwhile, delayed diagnosis of PHPT in pediatric patients until the patient becomes symptomatic, could be partly because blood examination is not routinely performed in health screening for school-age children. Furthermore, in general, the symptoms caused by hypercalcemia may not be specific, such as abdominal pain, nausea, or fatigue. Due to the rarity of PHPT in pediatric patients and these non-specific symptoms, making an early diagnosis of PHPT may be difficult in pediatric practice.

Hypercalcemic crisis is defined as an albumin-corrected serum calcium level of  $>14$  mg/dL associated with multiorgan dysfunction and severe symptoms, including coma, mental alteration, anorexia, and nausea (5). Hypercalcemic crisis is a serious complication of PHPT. Delayed diagnosis of PHPT sometimes causes this endocrinology emergency that may even result in fatal consequences if not adequately treated (6). However, because PHPT is likely to be symptomatic in pediatric patients, even if the symptoms are vague, it is usually diagnosed before hypercalcemic crisis is developed. Indeed, there are only six reports of PHPT-induced hypercalcemic crisis in pediatric patients (7-11). Thus, an appropriate treatment approach for this condition has not been demonstrated. In pediatric patients with PHPT, there is the possibility of hereditary diseases that affect the choice of surgical procedure (total parathyroidectomy and auto-transplantation or focused parathyroidectomy). Hence, it would be reasonable that genetic testing is performed prior to surgery. However, in case of a hypercalcemic crisis, we may not have enough time to wait for the results of genetic testing. Therefore, emergency focused parathyroidectomy without the results of genetic testing may be allowed for pediatric patients with a PHPT-induced hypercalcemic crisis.

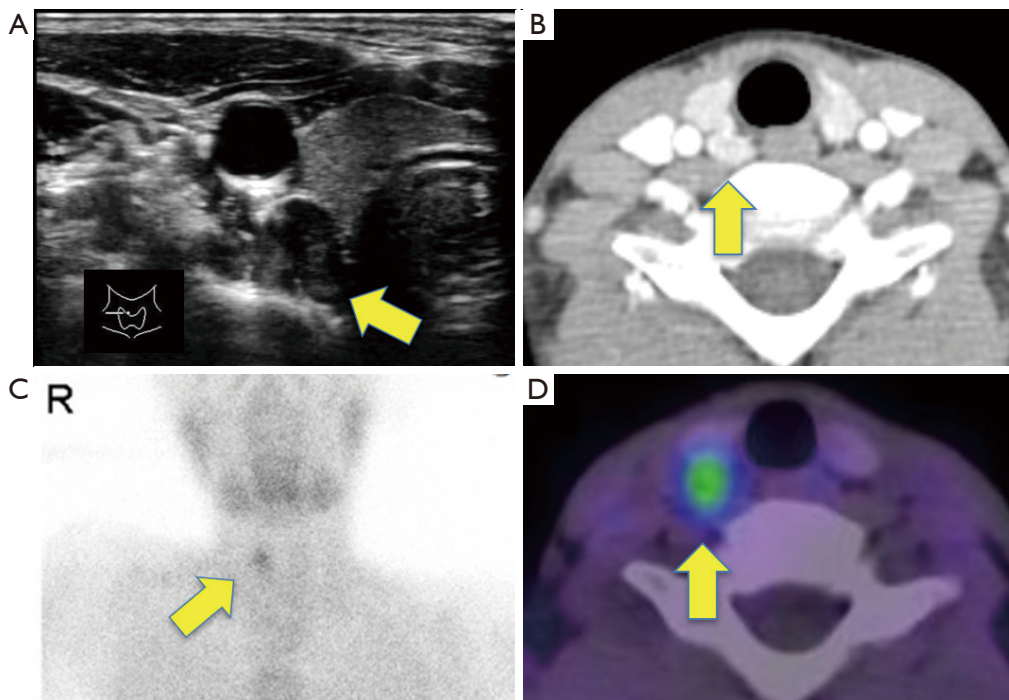
Here, we report a case of a hypercalcemic crisis caused by PHPT in an 11-year-old boy, review the literature, and discuss the treatment strategy for PHPT-induced hypercalcemic crisis in pediatric patients. We present the following case in accordance with the CARE reporting checklist (available at <https://gs.amegroups.com/article/view/10.21037/gs-22-92/rc>).

## Case presentation

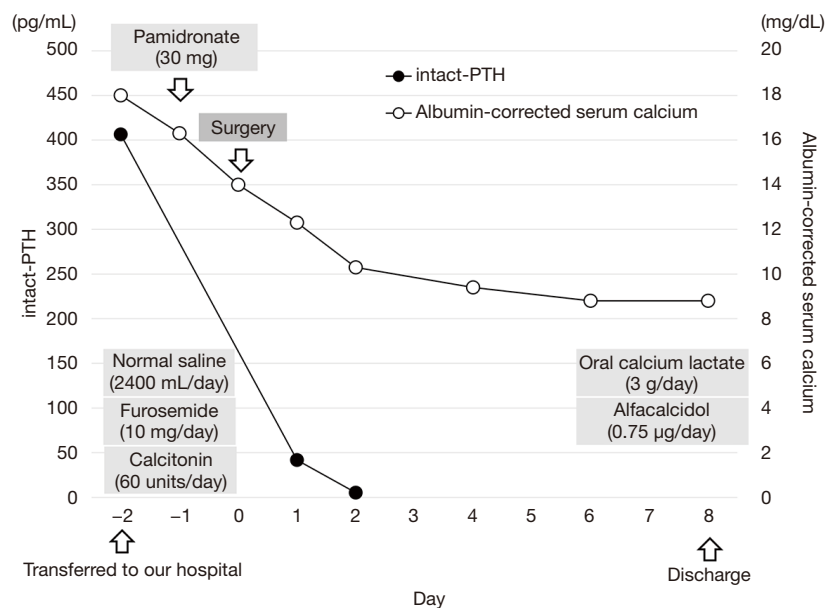
An 11-year-old boy with no history of serious disease or family history of endocrine disorder had abdominal pain and nausea for 3 months for which he visited a clinic. Physical examination and blood tests were performed. As serum calcium was not tested, hypercalcemia was not

noticed. Subsequently, symptomatic treatment was initiated. However, his symptoms worsened. Then, the boy was referred to a nearby hospital for further examination. A blood chemistry test showed a markedly raised albumin-corrected serum calcium level (14.3 mg/dL) (normal range, 8.7–10.2 mg/dL) and an increased intact-parathyroid hormone (PTH) level (405 pg/mL) (normal range, 10.0–65.0 pg/mL). Neck ultrasonography revealed a well-defined mass of 15×9 mm in size on the dorsal side of the right lobe of the thyroid gland, which was considered an enlarged right superior parathyroid gland (*Figure 1A*). Contrast enhanced computed tomography also demonstrated an enlarged upper right parathyroid gland (*Figure 1B*), which was thought to be an enlarged right superior parathyroid gland. Renal stones were not detected. Tc-99m sestamibi scintigraphy showed an accumulation consistent with this mass, with no other accumulation suggestive of the parathyroid was detected (*Figure 1C,1D*). His lumbar bone mineral density was 0.682 g/cm<sup>2</sup>, which was relatively low for his age (normal range for a 11-year-old Japanese boy: 0.694–0.706 g/cm<sup>2</sup>). Based on these findings, he was diagnosed with hypercalcemia due to PHPT. Treatment for hypercalcemia was initiated immediately with intravenous transfusion of normal saline (2,400 mL/day) along with furosemide (60 mg/day) to facilitate calcium excretion. The patient also received calcitonin (40 units/day). However, hypercalcemia worsened (16.5 mg/dL) and he developed hypercalcemic crisis with severe nausea and general fatigue 2 days after admission. He could not take almost any foods due to these symptoms and became lethargic.

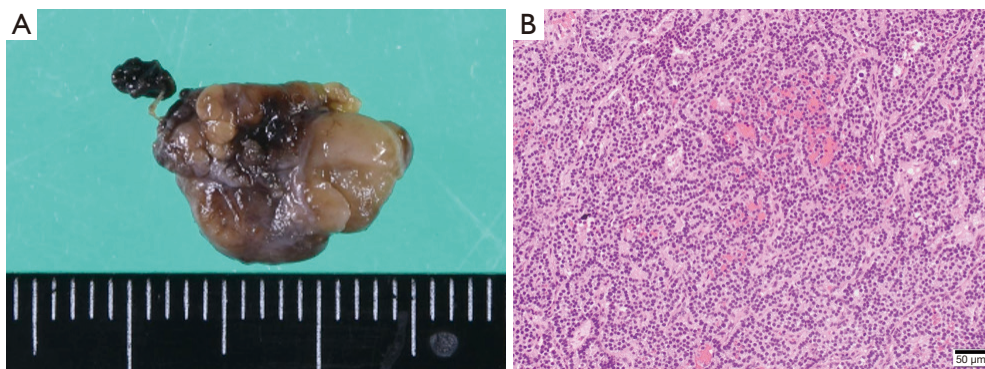
The child was then transferred to our hospital and received intensive care. On the transfer day, his albumin-corrected serum calcium level further increased to 18.0 mg/dL (*Figure 2*). Meanwhile, his serum phosphorus level was low (1.6 mg/dL) (normal range, 3.9–5.8 mg/dL). The other data was as follows, magnesium 1.4 mg/dL (normal range, 1.8–2.3 mg/dL), alkaline phosphatase 325 U/L (normal range, 154–431 U/L), 25-hydroxyvitamin D 25.5 ng/mL (normal range: more than 20.0 ng/mL), 1,25-dihydroxyvitamin D<sub>3</sub> 113 pg/mL (normal range, 20–70 pg/mL), calcitonin 3.38 pg/mL (normal range: less than 9.52 pg/mL), PTH-related peptide  $<1.0$  pmol/L (normal range: less than 1.1 pmol/L), prolactin 2.0 ng/mL (normal range, 3.6–16.3 ng/mL), adrenocorticotrophic hormone (ACTH) 43.4 pg/mL (normal range, 7.2–63.3 pg/mL), and insulin 9.4  $\mu$ U/mL (normal range, 5.0–25.0  $\mu$ U/mL). The calcium level in his urine was 15.5 mg/dL, and calcium/creatinine clearance ratio in urine was 1.67. Renal tubular reabsorption



**Figure 1** Ultrasonography (A), contrast enhanced computed tomography (B), and Tc-99m sestamibi scintigraphy (C,D) findings. (A,B) A 15×9-mm mass (arrows) was detected behind the upper pole of the right lobe of the thyroid gland, which suggested an enlarged right superior parathyroid gland. (C,D) Tc-99m sestamibi was uptaken in this tumor (arrows).



**Figure 2** Albumin-corrected serum calcium (mg/dL) and intact-PTH (pg/mL) level during the clinical course. PTH, parathyroid hormone.



**Figure 3** Gross appearance (A) and histopathological findings (B) of the resected parathyroid gland. (A) An oval-shaped mass measuring 15×10 mm in size. (B) Chief cells were proliferated with a solid pattern without lymphovascular invasion, which was compatible with parathyroid adenoma. HE ×20, scale bar, 50 µm.

of phosphate was low as 61.0% (normal range, 80.0–94.0%), whereas fractional excretion of calcium was high 0.08 (normal range, 0.02–0.04). As it was necessary to lower the serum calcium level, a single dose of pamidronate (30 mg) was administered in addition to intravenous transfusion of normal saline (70–150 mL/hour adjusted according to the urine output), furosemide (10 mg/day), and calcitonin (60 units/day). Two days later, the albumin-corrected serum calcium level decreased to 14.0 mg/dL (Figure 2). However, his symptoms did not completely improve and he still could not take any foods. Therefore, we performed an emergency parathyroidectomy 2 days after the transfer to our hospital. The enlarged right superior parathyroid gland was resected. We also aimed to resect the right inferior normal parathyroid gland in consideration of the possibility of hereditary disease. However, we could not detect the right inferior parathyroid gland. Considering the possible presence of right inferior parathyroid glands in the right paratracheal adipose tissue and right upper pole of the thymus (12), we resected these tissues as well. Fifteen minutes after the resection of the right superior parathyroid gland, the intact-PTH level decreased to 41.7 pg/dL. Albumin-corrected serum calcium level decreased to 12.3 mg/dL the next day (Figure 2). The size and weight of the right superior parathyroid gland was 15×10 mm and 320 mg, respectively. Histopathological examination revealed that the enlarged gland was as an adenoma (Figure 3), and neither the excised adipose tissue nor the thymus contained any parathyroid tissue. The postoperative course was uneventful, and the symptoms caused by PHPT immediately improved. The albumin-corrected serum calcium level gradually decreased to 8.8 mg/dL on postoperative day 6 (Figure 2). To prevent hypocalcemia,

oral calcium lactate (3 g/day) and alfacalcidol (0.75 µg/day) were administered, and their doses were gradually decreased according to the serum calcium level. Six months after surgery, he continued to receive alfacalcidol (0.25 µg/day), and his albumin-corrected serum calcium and intact-PTH levels were maintained within normal limits. As his lumbar bone mineral density improved to 0.774 g/cm<sup>2</sup> 6 months after surgery, alfacalcidol will be stopped in the near future. Since PHPT occurred at a young age, the possibility of genetic disease was considered. Therefore, we performed genetic testing for multiple endocrine neoplasia type 1 (MEN1) and hyperparathyroidism-jaw tumor syndrome (HPT-JT) after the operation. However, we did not detect any pathogenic mutations in the *MEN1* gene, a causative gene for MEN1, by Sanger sequencing and multiplex ligation-dependent probe amplification. In addition, we did not detect any pathogenic mutations in the *CDC73* gene, which is responsible for HPT-JT, by next-generation sequencing. To date, although the serum calcium levels of his parents has not been checked, no genetic predisposition has been identified in this family.

All procedures performed in this study were in accordance with the ethical standards of the institutional and/or national research committee(s) and with the Helsinki Declaration (as revised in 2013). Written informed consent was obtained from the patient's legal guardian/parent for publication of this case report and accompanying images. A copy of the written consent is available for review by the editorial office of this journal.

## Discussion

Herein, we report a case of PHPT-induced hypercalcemic

crisis that occurred in an 11-year-old boy who had been treated with emergency parathyroidectomy following failed medical treatment. Previous reports showed that PHPT rarely developed hypercalcemic crisis in pediatric patients (2,13-15). Together with the rarity of PHPT in pediatric patients itself, hypercalcemic crisis caused by PHPT in pediatric patients has been considered an even rarer entity. PHPT-induced hypercalcemic crisis in pediatric patients has been described in a relatively large number of patient cohort studies (2,13-15), but few cases have been reported with detailed clinicopathological characteristics or clinical courses. After extensive literature research, we found six English reports of hypercalcemic crisis caused by PHPT in patients aged  $\leq 18$  years with detailed clinicopathological characteristics and clinical courses (7-11) (*Table 1*).

Because it is necessary to lower serum calcium levels, the initial treatment consisting of normal saline infusion and/or furosemide was immediately started for all six patients shown in *Table 1*. However, bisphosphonate (etidronate, pamidronate, or zoledronate) was used to decrease serum calcium levels in four out of six cases (7,9-11), while in one case, denosumab, a human monoclonal antibody of the receptor activator of nuclear factor kappa-B ligand, was administered (8). In addition, calcitonin was used in one case (7). In our case, both a bisphosphonate (pamidronate) and calcitonin were used to suppress bone resorption. As the bones are involved in the elevation of the serum calcium level in our case, a bisphosphonate and calcitonin would have some effect on decreasing the serum calcium level. With regard to other anti-bone resorption agents, cinacalcet, which is currently used to treat secondary hyperparathyroidism and parathyroid carcinoma, can be an option in the future. Although serum calcium levels were decreased by these medical treatments to some extent, parathyroidectomy was performed as radical treatment soon after hospitalization (1-5 days after admission) in five out of six patients (7,9-11). Another patient (case 6) underwent surgery 22 days after admission. This case had family history of PHPT, and hence genetic testing was performed before surgery (8). Emergency surgeries after initial treatment might be imperative because a hypercalcemic crisis can result in fatal consequences in cases where prompt and proper treatment cannot be provided, and surgery is the only curative treatment for PHPT (6). In our case, the boy was diagnosed with a hypercalcemic crisis with a highly elevated albumin-corrected serum calcium level (18.0 mg/dL) and associated severe nausea. However, emergency surgery prevented a possible fatal consequence.

Although emergency surgery for hypercalcemic crisis is necessary to prevent fatal outcomes, surgical procedures should be chosen carefully because the possibility of hereditary diseases such as MEN1, MEN2A, HPT-JT, and familial isolated PHPT is higher in pediatric patients with PHPT than in adults (16). When genetic testing confirms pathogenic mutations in *MEN1*, *RET*, or *CDC73*, which are genes responsible for MEN1, MEN2A, or HPT-JT, respectively, total parathyroidectomy and auto-transplantation with bilateral neck exploration should be performed. However, as it takes a couple of weeks to obtain the results of genetic testing, we need to decide on a treatment strategy without information on gene mutations in a patient with hypercalcemic crisis that requires emergency surgery. Therefore, we consider a focused parathyroidectomy as an appropriate treatment to promptly lower the serum calcium level with minimal invasion in pediatric patients with a hypercalcemic crisis caused by PHPT. Indeed, all six previously reported cases of hypercalcemic crisis in pediatric patients (shown in *Table 1*) underwent removal of one enlarged parathyroid gland, which resulted in a favorable decrease in serum calcium levels. Our patient also underwent resection of the enlarged parathyroid gland, and serum calcium level decreased to the normal range. In two cases (cases 4 and 5), bilateral neck exploration was performed, but the glands other than the responsible one were preserved because they were of normal size. The serum intact-PTH levels decreased to normal levels soon after the surgery (9). Furthermore, in all the cases shown in *Table 1*, the resected gland was histopathologically diagnosed with adenoma.

Among hereditary diseases associated with PHPT, MEN1 is the most prevalent; the reported frequency of MEN1 in pediatric patients diagnosed with PHPT is approximately 13% (17). Clinical presentation of MEN1-associated PHPT has been reported to be mild or asymptomatic, with mild elevation of serum calcium and intact PTH levels (18). Shariq *et al.* (19) reported the clinical features of 60 patients with MEN1 aged under 18 years old, and none of the patients presented with hypercalcemic crisis. Thus, hypercalcemic crisis seems less likely to occur in pediatric patients with MEN1. HPT-JT is another hereditary disease that can present with PHPT in pediatric patients. Among seven cases of hypercalcemic crisis in pediatric patients shown in *Table 1*, one case (case 6) was diagnosed as HPT-JT, as evidenced by a pathogenic mutation in *CDC73* (8). A single parathyroid tumor is usually responsible for the development of PHPT in patients with HPT-JT.

**Table 1** Clinicopathological features of reported PHPT-induced hypercalcemic crisis in patients aged under 20

Case	Authors	Age/ sex	FH of PHPT	Serum Ca (mg/dL)	i-PTH (pg/mL)	Symptoms	Culprit parathyroid gland	Initial treatment	Days to the surgery	Operation procedure	Pathological diagnosis	i-PTH after surgery (pg/mL)	Postoperative course	Genetic mutation test	Results
1	Choudhry <i>et al.</i> (7)	13/f	None	18.5	1,198	Severe abdominal pain	Lt inferior	Normal saline; furosemide; calcitonin pamidronate	2 days	Lt inferior parathyroidectomy (unilateral neck exploration)	Adenoma	51.0	Symptom free, Ca and alfacalcidol supplementation	MEN1	No mutation
2	Walczyk <i>et al.</i> (11)	15/m	None	14.5	880	Gait disturbance	Rt inferior	Normal saline; furosemide; pamidronate	N.D	Rt inferior parathyroidectomy (unilateral neck exploration)	Adenoma	N.D	Symptom free, Ca and alfacalcidol supplementation	N.D	N.D
3	Sala <i>et al.</i> (10)	16/f	None	14.9	184	Severe nausea; altered mental status	Rt inferior	Normal saline; furosemide; pamidronate	N.D	Rt inferior parathyroidectomy (unilateral neck exploration)	Adenoma	N.D	Symptom free, Ca and alfacalcidol supplementation	N.D	N.D
4	Palet <i>et al.</i> (9)	12/m	None	14.1	203	GTCS; severe abdominal pain; severe nausea	Lt inferior	Normal saline; furosemide	N.D	Lt inferior parathyroidectomy (bilateral neck exploration)	Adenoma	28.0	Symptom free, no supplementation	MEN1	No mutation
5	Pal <i>et al.</i> (9)	16/m	None	14.5	2,491	GTCS; paresthesia; decreased alertness	Lt inferior	Normal saline; furosemide; zoledronate	5 days	Lt inferior parathyroidectomy (bilateral neck exploration)	Adenoma	43.0	Symptom free, no supplementation	MEN1	No mutation
6	Mamedova <i>et al.</i> (8)	16/f	Yes	16.7	2,207	Pathologic fracture; severe nausea; progressive weight loss	Rt inferior	Normal saline; denosumab	22 days	Rt inferior parathyroidectomy (unilateral neck exploration)	Adenoma	6.7	Symptom free, Ca and alfacalcidol supplementation	CDC73	Exon 2 176C>T
7	Our case	11/m	None	18.0	406	Severe nausea; severe general fatigue	Rt superior	Normal saline; furosemide; calcitonin pamidronate	2 days	Rt superior parathyroidectomy (unilateral neck exploration)	Adenoma	41.7	Symptom free, Ca and alfacalcidol supplementation	MEN1, CDC73	No mutation

FH, family history; PHPT, primary hyperparathyroidism; Ca, calcium; i-PTH, intact-parathyroid hormone; N.D, not described; GTCS, generalized tonic-clonic convulsion.

Furthermore, the resected parathyroids in a patient with HPT-JT are likely to be pathologically adenomas or carcinomas, but not hyperplasia (20). Hence, focused parathyroidectomy may be a feasible option for HPT-JT. Altogether, we consider that focused parathyroidectomy is a reasonable strategy for pediatric patients with PHPT-induced hypercalcemic crisis. Meanwhile, hypercalcemic crisis due to PHPT could be a consequence of the delayed diagnosis of PHPT. The symptoms of PHPT are heterogeneous, as shown in *Table 1*, and are expected to be vague and non-specific. Therefore, early diagnosis of PHPT may be difficult. However, when treating pediatric patients with non-specific symptoms, serum calcium levels should be considered because it can help us recognize the possibility of PHPT before the onset of hypercalcemic crisis. The important differential diagnosis for hypercalcemia in pediatric patients is familial hypocalciuric hypercalcemia (FHH), which shows hypercalcemia with low fractional excretion of calcium ( $\leq 0.01$ ). In our case, because fractional excretion of calcium was high as 0.08, FHH was ruled out.

PHPT-induced hypercalcemic crisis is a rare condition in pediatric patients. Although a genetic test should be generally considered for a child with PHPT, emergency focused parathyroidectomy prior to genetic testing is an appropriate strategy when the patient presents with a hypercalcemic crisis caused by PHPT. A serum calcium level check is important to differentiate PHPT before the onset of hypercalcemic crisis when pediatric patients present with non-specific symptoms.

### Acknowledgments

We would like to thank Editage (<https://www.editage.com>) for English language editing.

*Funding:* None.

### Footnote

*Reporting Checklist:* The authors have completed the CARE reporting checklist. Available at <https://gs.amegroups.com/article/view/10.21037/gS-22-92/rc>

*Peer Review File:* Available at <https://gs.amegroups.com/article/view/10.21037/gS-22-92/prf>

*Conflicts of Interest:* All authors have completed the ICMJE uniform disclosure form (available at <https://gs.amegroups.com/article/view/10.21037/gS-22-92/coif>). The authors

have no conflicts of interest to declare.

*Ethical Statement:* The authors are accountable for all aspects of the work in ensuring that questions related to the accuracy or integrity of any part of the work are appropriately investigated and resolved. All procedures performed in this study were in accordance with the ethical standards of the institutional and/or national research committee(s) and with the Helsinki Declaration (as revised in 2013). Written informed consent was obtained from the patient's legal guardian/parent for publication of this case report and accompanying images. A copy of the written consent is available for review by the editorial office of this journal.

*Open Access Statement:* This is an Open Access article distributed in accordance with the Creative Commons Attribution-NonCommercial-NoDerivs 4.0 International License (CC BY-NC-ND 4.0), which permits the non-commercial replication and distribution of the article with the strict proviso that no changes or edits are made and the original work is properly cited (including links to both the formal publication through the relevant DOI and the license). See: <https://creativecommons.org/licenses/by-nc-nd/4.0/>.

### References

1. Bilezikian JP, Bandeira L, Khan A, et al. Hyperparathyroidism. *Lancet* 2018;391:168-78.
2. Mallet E; Working Group on Calcium Metabolism. Primary hyperparathyroidism in neonates and childhood. The French experience (1984-2004). *Horm Res* 2008;69:180-8.
3. Alagaratnam S, Kurzawinski TR. Aetiology, Diagnosis and Surgical Treatment of Primary Hyperparathyroidism in Children: New Trends. *Horm Res Paediatr* 2015. [Epub ahead of print]. doi: 10.1159/000381622.
4. Liu Y, Guo S, Wu J, et al. Changes in clinical patterns of Chinese patients with primary hyperparathyroidism in the past 12 years: a single-center experience. *Endocr Connect* 2021;10:1428-34.
5. Ahmad S, Kuraganti G, Steenkamp D. Hypercalcemic crisis: a clinical review. *Am J Med* 2015;128:239-45.
6. Cannon J, Lew JI, Solórzano CC. Parathyroidectomy for hypercalcemic crisis: 40 years' experience and long-term outcomes. *Surgery* 2010;148:807-12; discussion 812-3.
7. Choudhry KS, Malik MZ, Buggs-Saxton C. Hypercalcemic crisis due to primary hyperparathyroidism in systemic

- lupus erythematosus (SLE). *Lupus* 2013;22:847-50.
8. Mamedova E, Kolodkina A, Vasilyev EV, et al. Successful Use of Denosumab for Life-Threatening Hypercalcemia in a Pediatric Patient with Primary Hyperparathyroidism. *Horm Res Paediatr* 2020;93:272-8.
  9. Pal R, Dutta A, Agrawal K, et al. Primary Hyperparathyroidism Presenting as Posterior Reversible Encephalopathy Syndrome: A Report of Two Cases *J Clin Res Pediatr Endocrinol* 2020;12:432-8.
  10. Sala TD, Mureşan S, Roman R, et al. Hypercalcaemic Crisis Due to Primary Hyperparathyroidism: Report of Two Cases. *J Crit Care Med (Targu Mures)* 2019;5:34-9.
  11. Walczyk A, Szalecki M, Kowalska A. Primary hyperparathyroidism: a rare endocrinopathy in children. Two case reports. *Endokrynol Pol* 2011;62:346-50.
  12. Reitz RJ 3rd, Dreimiller A, Khil A, et al. Ectopic and supernumerary parathyroid glands in patients with refractory renal hyperparathyroidism. *Surgery* 2021;169:513-8.
  13. Cronin CS, Reeve TS, Robinson B, et al. Primary hyperparathyroidism in childhood and adolescence. *J Paediatr Child Health* 1996;32:397-9.
  14. Sharanappa V, Mishra A, Bhatia V, et al. Pediatric Primary Hyperparathyroidism: Experience in a Tertiary Care Referral Center in a Developing Country Over Three Decades. *World J Surg* 2021;45:488-95.
  15. Wang W, Kong J, Nie M, et al. Primary hyperparathyroidism in Chinese children and adolescents: A single-centre experience at Peking Union Medical College Hospital. *Clin Endocrinol (Oxf)* 2017;87:865-73.
  16. Fraser WD. Hyperparathyroidism. *Lancet* 2009;374:145-58.
  17. Kollars J, Zarroug AE, van Heerden J, et al. Primary hyperparathyroidism in pediatric patients. *Pediatrics* 2005;115:974-80.
  18. Lamas C, Navarro E, Casterás A, et al. MEN1-associated primary hyperparathyroidism in the Spanish Registry: clinical characteristics and surgical outcomes. *Endocr Connect* 2019;8:1416-24.
  19. Shariq OA, Lines KE, English KA, et al. Multiple endocrine neoplasia type 1 in children and adolescents: Clinical features and treatment outcomes. *Surgery* 2022;171:77-87. Erratum in: *Surgery* 2022;171:1708-11.
  20. DeLellis RA, Mangray S. Heritable forms of primary hyperparathyroidism: a current perspective. *Histopathology* 2018;72:117-32.

**Cite this article as:** Hayashi S, Oba T, Ichikawa K, Nakamura C, Hara Y, Kanai T, Sato Y, Uehara T, Ito KI. Hypercalcemic crisis caused by primary hyperparathyroidism in a 11-year-old boy: a rare case report and review of the literature. *Gland Surg* 2022;11(7):1279-1286. doi: 10.21037/gs-22-92