

Emerging therapies for pancreas neuroendocrine cancers

Ali R. Mahjoub¹, Eileen M. O'Reilly²

¹Department of Medicine, New York Methodist Hospital, Brooklyn, NY 11215, USA; ²Gastrointestinal Oncology Service, Department of Medicine, Memorial Sloan-Kettering Cancer Center, New York, NY 10065, USA

Corresponding to: Eileen M. O'Reilly, M.D. Memorial Sloan-Kettering Cancer Center, 300 East 66th Street, Office 1021, New York, NY 10065, USA. Email: oreilly@mskcc.org.

Abstract: Neuroendocrine tumors (NET) are rare malignancies, with the most common site of origin being from the gastrointestinal tract, particularly the pancreas, small bowel and appendix. Pancreatic neuroendocrine tumors can be functional, i.e., hormone secreting tumors, e.g., insulinoma, gastrinoma or VIPoma, and can have distinctive symptoms leading to the diagnosis. In contrast nonfunctional tumors, the majority of PNET's, usually present later either incidentally or due to tumor bulk symptoms. The recent WHO classification system in 2010 classified PNET's into different stages and grades depending on the mitotic activity and Ki-67 labeling index. PNET's have a broad range of prognoses depending on the histologic grade, differentiation and biologic behavior. Computerized tomographic scanning (CT), magnetic resonance imaging (MRI) and octreoscan are imaging tools used to diagnose PNET, in addition to a confirmatory tissue diagnosis with immunohistochemical stains, typically obtained by either cytologic or histologic assessment. Symptomatic advanced PNET's can be treated with a long-acting somatostatin analogue for those tumors with somatostatin receptor positivity and which may also have antiproliferative activity. Another treatment modality is peptide receptor radionucleotide therapy (PRRT) in somatostatin receptor-positive tumors, albeit as yet with limited availability in the United States. Systemic therapies with combination cytotoxic agents e.g., streptozocin, anthracyclines, and capecitabine and temozolomide, all have established activity in PNET's. Biologic agents targeting the VEGF and mTOR signaling pathways, e.g., sunitinib, bevacizumab or everolimus are becoming integrated as treatments for PNET's. Poorly differentiated, high grade PNETs with a very high mitotic rate are treated with platinum-based chemotherapy regimens similar to treatment paradigms for small cell carcinoma of the lung. For liver confined or predominant disease, strategies such as cytoreductive surgery, hepatic artery embolization or radioembolization are treatment modalities to effect locoregional tumor control. The next generation of studies in PNET will help define optimal sequencing strategies of available therapies and also will attempt to use biomarker-guided approaches to select therapies.

Keywords: Pancreas neuroendocrine; somatostatin; everolimus; sunitinib; peptide receptor radionucleotide therapy (PRRT)



Submitted Jun 10, 2013. Accepted for publication Jun 12, 2013.

doi: 10.3978/j.issn.2304-3865.2013.06.01

Scan to your mobile device or view this article at: <http://www.thecco.net/article/view/2805/3668>

Introduction

Neuroendocrine tumors (NET) are relatively rare malignancies, albeit with a rising incidence, which originate widely throughout the body. The incidence of NET has steadily increased in the last several decades, from 1.09/100,000 in 1974 to 5.25/100,000 in 2004, and the recent prevalence of NET was estimated to be 35/100,000 in the

US population (1). These malignancies can arise in most organs (2), with the most common sites of NET origin being the gastrointestinal system followed by the lung/bronchus and the pancreas (3). Pancreas NET's (PNET), or in older terminology, islet cell tumors, are usually considered as biologically more aggressive malignancies in comparison with NET from other sites and may produce more complex

Table 1 Clinical presentations of pancreas neuroendocrine tumors

Tumor	Symptoms or signs
Nonfunctioning	Mass effect
Insulinoma	Hypoglycemia resulting in intermittent confusion, sweating, weakness and/or nausea (neuroglycopenic symptoms). Loss of consciousness in severe cases
Glucagonoma	Rash (necrotizing migratory erythema), cachexia, diabetes, deep vein thrombosis
VIPoma	Profound secretory diarrhea, electrolyte imbalance (e.g., hypokalemia)
Gastrinoma	Acid hypersecretion, refractory peptic ulcer disease, abdominal pain, diarrhea

symptomatology related to hormone production depending on the cell of origin, e.g., insulinoma (insulin), glucagonoma (glucagon), VIPoma (vasoactive intestinal polypeptide), somatostatinoma (somatostatin), etc. (4). Typically nonfunctional PNET's are larger than the functional tumors and are usually non-hormone-producing (5) (*Table 1*).

Molecular biology

Blood vessel growth and formation (neoangiogenesis) and expansion play an important role in different vital pathological processes, especially in tumor growth. Vascular endothelial growth factor (VEGF) is the main growth factor responsible for angiogenesis by initiating the process of neovascularization and by interacting with specific transmembrane receptors that are expressed on the surface of endothelial cells (6). Several studies have described the overexpression of cellular growth factors and their receptors in NETs, including basic fibroblast growth factor (bFGF), VEGF, platelet derived growth factor (PDGF), insulin-like growth factor type 1 (IGF-1), epidermal growth factor (EGF), stem cell factor (KIT) and their related receptors (7). Based on these findings, several medications have been investigated to target this mechanism of action, including direct monoclonal antibody targeting VEGF, such as bevacizumab, and multiple tyrosine kinase inhibitors targeting VEGFR and other related receptors such as sunitinib, sorafenib and pazopanib (8).

The mammalian Target of Rapamycin (mTOR) is a serine-threonine kinase that has a role in cell growth, proliferation and apoptosis and also mediates downstream signaling in a number of pathways that are implicated in NETs growth, including VEGF, insulin receptor growth factor (IGF) and phosphoinositol 3-kinase (PI3K)-AKT signaling (6,9). Rarely PNET can arise in the setting of MEN-1, tuberous sclerosis, von Hippel Landau (VHL) syndrome and neurofibromatosis, however the vast majority

of PNET's are sporadic, and studies have shown that gene alterations of MEN-1, DAXX/ATRX and mTOR pathway are common in sporadic PNET. Additionally the role of the PI3K/AKT/mTOR pathway in these types of tumors (10) supports the development of mTOR inhibitors as a treatment for PNET.

Pathology, classification and grading

Gross examination of a neuroendocrine malignancy can demonstrate a nodular, infiltrative or fungated mass, typically grayish or yellow to white in color; however these macroscopic feature are not specific and have no role in diagnosis (11). Typical microscopic histopathological features of NET's include cells which have round or oval nuclei with chromatin and eosinophilic cytoplasm, and are usually arranged in trabecular or sheet-like pattern (12). Immunohistochemical studies are the best method to confirm the diagnosis of NETs. The most common stains include chromogranin and synaptophysin. Other commonly used but less specific stains include, CDX2 (which may indicate small bowel origin), neuron specific endolase and CD56 (13).

According to the 2010 WHO classification of GEP-NET, well-differentiated tumors are separated into low grade (G1) and intermediate grade (G2) categories, while all poorly differentiated NET are high grade (G3) (14) (*Table 2*). The grading system of NET depends mainly on the proliferation rate, which includes the mitotic activity and/or Ki-67 labeling index. Low grade (G1) includes mitotic counts of less than 2 per 2 mm² and/or Ki-67 index of $\leq 2\%$; intermediate grade (G2) has mitotic count of 2 to 20 per 2 mm² and/or Ki-67 index of 3-20%; and high grade (G3) shows mitotic count of ≥ 20 per 2 mm² and/or Ki-67 $\geq 20\%$ (12). Other pathologic characteristics such as lymphovascular and perineural invasion, and lymph node involvement are adjudicated as either positive or negative (15). A proposed TNM staging system for PNET may be helpful in the determination of

Table 2 Histologic classification of pancreatic neuroendocrine tumors

Differentiation	Grade	Mitotic count (per 2 mm ²)	Ki-67 Index (%)	WHO
Well-differentiated	Low grade (G1)	<2	≤2	NET, Grade 1
Well-differentiated	Intermediate grade (G2)	2-20	3-20	NET, Grade 2
Poorly differentiated	High grade (G3)	>20	>20	NET, Grade 3

Table 3 TNM classification for PNETs (17)

T	Primary tumor
Tx	Primary tumor cannot be assessed
T0	No evidence of primary tumor
T1	Tumor limited to the pancreas and size <2 cm
T2	Tumor limited to the pancreas and size 2-4 cm
T3	Tumor limited to the pancreas and size >4 cm or invading duodenum or bile duct
T4	Tumor invading adjacent organs (stomach, spleen, colon, adrenal gland) or the wall of large vessels (celiac axis or superior mesenteric artery) For any T, add (m) for multiple tumors
N	Regional lymph node
Nx	Regional lymph node cannot be assessed
N0	No regional lymph node metastasis
N1	Positive lymph node metastasis
M	Distant metastasis
Mx	Distant metastasis cannot be assessed
M0	No distant metastases
M1	Distant metastasis

Table 4 PNETs staging based on TNM system

Stage	TNM system
I	T1 N0 M0
IIa	T2 N0 M0
IIb	T3 N0 M0
IIIa	T4 N0 M0
IIIb	Any T N1 M0
IV	Any T Any N M1

patient's prognosis and influences management plans (16) (Tables 3,4, Figure 1).

Diagnosis and imaging

Functional PNETs, especially insulinoma and gastrinoma can manifest hormonal symptoms even though the primary tumor may be very small (Table 1), and the localization of the primary lesion can be quite difficult (18). When a hormonal syndrome is identified, computed tomography

(CT) or magnetic resonance imaging (MRI) are usually the initial imaging techniques to be used because of availability and speed. As NET's are rich with blood vessels and radiologically hypervascular, the use of contrast, especially with multiphasic imaging (arterial and venous phases) is very helpful, while nonfunctioning PNET are most commonly found incidentally on CT or MRI when a patient is being evaluated for mass-related symptoms (19).

Conventional CT or MRI radiologic techniques usually detect about 70% of tumors larger than 3 cm, however they detect less than 50% of PNETs that are less than 1 cm in size, which leads to frequently missing primary PNETs and/or small liver metastases (20). As about 80% of PNETs express somatostatin receptors (SSTR), mainly SSTR-2 and SSTR-5, the use of somatostatin receptor scintigraphy (SRS) with indium¹¹¹-labeled somatostatin analogue [(¹¹¹In-DTPA⁰) octreotide] gives relatively high sensitivity and specificity as an imaging technique for PNETs and their metastases, although the resolution may be lower than CT or MRI. Several factors are limitations for somatostatin imaging, like the necessity of a background ratio of at

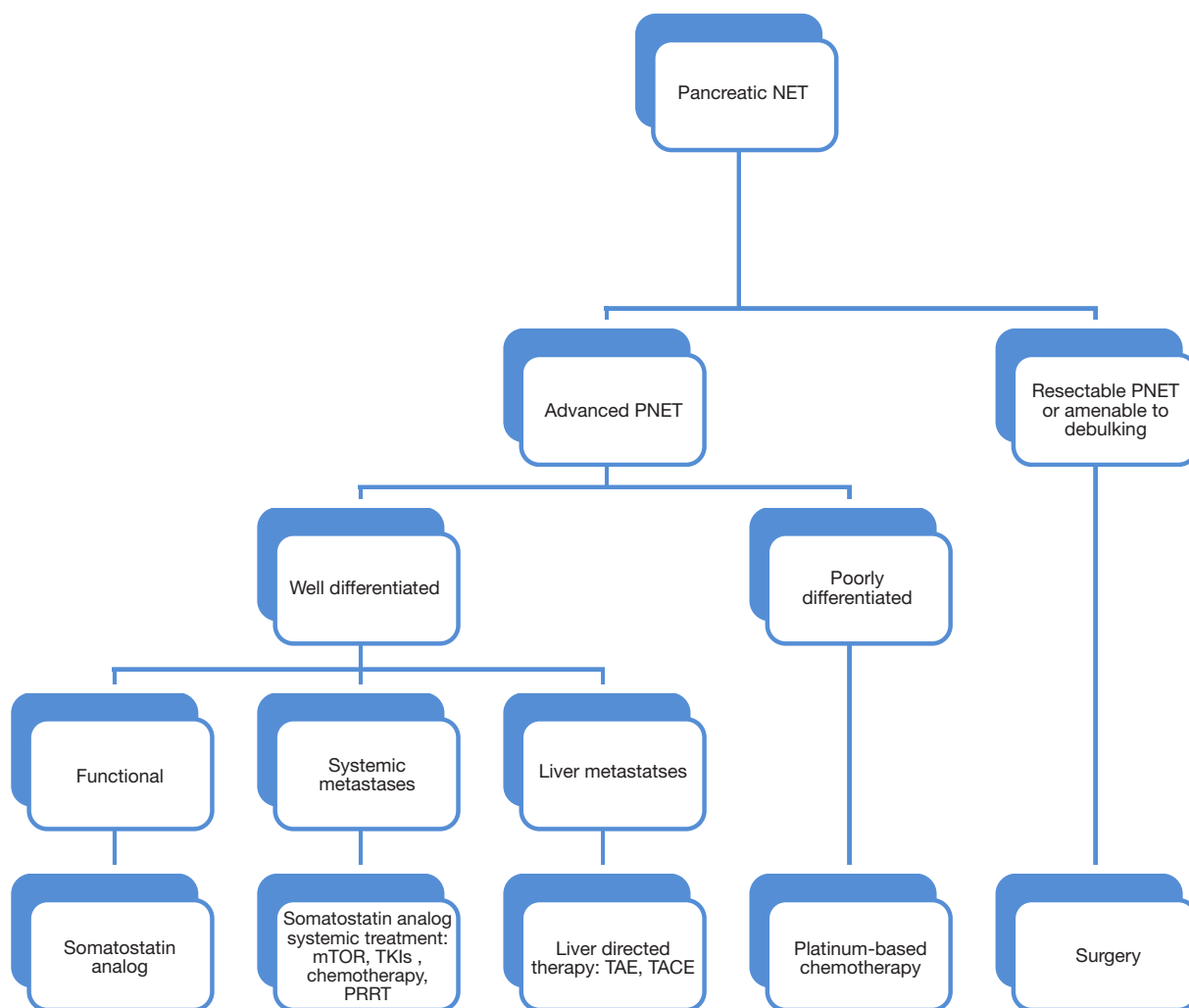


Figure 1 Selective treatment algorithm for pancreatic neuroendocrine tumors (PNET).

least 2:1, and the low spatial resolution especially for small tumors, which have been overcome by the ^{68}Ga -PET scan, and also a combination of positron emission tomography (PET)/CT which is able to provide additional anatomical information in respect to the localization and the boundaries of the lesions (4). Somatostatin scintigraphy has not been formally evaluated in the assessment of treatment response to therapy, and typically CT or MRI would be more helpful tests in such setting (21).

Endoscopic ultrasound (EUS) is a technique used for diagnosis and staging of many gastrointestinal tumors. The proximity of the echoscope to the pancreas offers a detailed view of the pancreas and an ability to identify small size PNETs, particularly insulinoma and gastrinomas, and can

detect lesions as small as 2 to 5 mm. Thus EUS is quite sensitive in the detection of PNETs with a sensitivity of 82% and a specificity of 95% (22). EUS is also helpful in obtaining tissue confirmation for a diagnosis of PNET by EUS-guided fine needle aspiration (EUS-FNA). The aspirate is then evaluated by a cytopathologist, and a confirmed diagnosis usually determined by the immunohistochemical studies.

Treatment options

Somatostatin analogues

PNETs are characterized by high expression of somatostatin receptors (SSTR). Five different G-Protein-coupled SSRT subtypes have been recognized, SSRT 1 to 5. Among these,

SSRT2 is expressed in almost 80% of PNET, and plays a major role in the management of this type of tumors (23).

Somatostatin is a 14-amino-acid peptide that inhibits the secretion of various hormones (including insulin, glucagon, growth hormone and gastrin) by binding to somatostatin receptors (24). Somatostatin analogues are a first line of treatment approved to control the symptoms resulting from functional PNET. Octreotide with its high affinity to SSRT-2 and less so to SSRT-5, was the first somatostatin analogue to be used clinically, when it was found to inhibit the secretion of growth hormone, glucagon and insulin more powerfully than somatostatin itself (25). Octreotide is a short-acting medication, which is given 2 to 3 times a day as a subcutaneous injection. Long-acting forms of somatostatin analogues were developed later, like octreotide LAR (long-acting-repeatable) and lanreotide with similar high affinity to SSRT-2 and SSRT-5. Octreotide LAR is given once every 4 weeks, while lanreotide is administered every 2-4 weeks intramuscularly (26).

One of the first studies of a somatostatin analogue included 25 patients with NETs, treated with subcutaneous dosing of octreotide three times a day. Eighty-eight per cent of patients had control of symptoms (diarrhea and flushing), and 72% had a decrease in urinary 5-hydroxydoacetic acid (5-HIAA) levels of 50% or more (27). It has been observed that somatostatin analogue administration resulted in tumor response in about 5-10% and stable disease in about 50% (23).

A prospective trial, the PROMID study, was designed as a placebo-controlled, double-blind, randomized study to evaluate the effect of octreotide LAR in the control of tumor growth in patients with metastatic midgut NET's (28). Inclusion criteria included metastatic or locally inoperable disease, midgut primary tumor or tumor of unknown origin, well-differentiated NET by pathology, measurable disease by CT scan on MRI, more than 60% Karnofsky performance status and no curative treatment options available for the patient. Eighty-five patients were randomized to either octreotide 30 mg LAR (42 patients) or placebo (43 patients). The primary endpoint of time-to-tumor progression was 14.3 months in the octreotide group versus 6 months in the placebo group [95% confidence interval (CI), 0.20-0.59; P=0.000072]. The PROMID study secondary end points included overall survival, which was not reported in the initial study analysis, however was presented at the American Society of Clinical Oncology (ASCO) annual meeting in 2013. As of January 2013, 41 of the 85 patients enrolled had died, 19 in the octreotide group and 22 in the placebo group. The final results

showed that octreotide LAR extends overall survival in patients with metastatic midgut NETs and a low hepatic tumor load ($\leq 10\%$ at study entry); (I) 10 patients in the octreotide group died versus 16 in the placebo group (total of 26 of 64 patients), while patient with a hepatic tumor load $>10\%$ had no survival benefits (29); (II) quality of life, was comparable in both groups, and (III) response rate which showed that stable disease was achieved in 66.7% in octreotide LAR group *vs.* 37.2% in placebo after 6 months of treatment (28).

In many countries, including the United States octreotide is not approved for asymptomatic or nonfunctional NETs, but it is frequently used as anti-neoplastic treatment to stop or slow the growth of metastatic disease (26). However, in the case of a negative somatostatin scintigraphy test, octreotide should not be administered, especially in insulinoma where octreotide can prevent the compensatory effect of glucagon and lead to worsening hypoglycemia (21).

Peptide receptor radionuclide therapy

The mechanism of action of peptide receptor radionuclide therapy (PRRT) depends mainly on the overexpression of somatostatin receptors (SSTR) in NETs over the surrounding normal tissue. PRRT can be used in patients with unresectable PNET, with or without metastases and expressing high level of SSTRs. Radiopeptides bind to the SSRTs on the cell surface and are internalized to deliver localized radiotherapy to the tumor cell with little effect on surrounding tissue. The most frequently used radionuclides for targeted radiotherapy include yttrium (^{90}Y), lutetium (^{177}Lu) or indium (^{111}In) linked to a somatostatin analogue. The greater the expression of SSRTs by the tumor cell potentially the more effective PRRT may be and thus an octreotide or gallium scan can be useful to predict the potential benefits of the PRRT (the higher uptake, the more effect) (7).

In a single center analysis from the University Hospital Basel, Basel, Switzerland, 1,109 patients with metastatic NETs were treated between October 1997 and February 2010, and received somatostatin-based radiopeptide therapy with ^{90}Y -labeled tetraazacyclododecane-tetraacetic acid modified Tyr³-octreotide (^{90}Y -DOTATOC) (30). Of the 1,109 patients, 378 (34.1%) had morphological response, 172 (15.5%) had biochemical response and 329 (29.7%) had clinical response. Tumor response was associated with longer survival compared to disease progression. Adverse events included grade 3 and 4 transient hematological toxicity in 142 patients (12.8%), including leucopenia,

anemia and thrombocytopenia. Two patients developed myeloproliferative disease, two patients developed tumor lysis syndrome with reversible renal failure, and 102 (9.2%) patients developed severe permanent renal toxicity (grade 4 and 5) (30).

In another study, a single-arm multicenter review that included patients from five European countries and the United States, 90 patients with NETs with symptoms refractory to octreotide were enrolled between July 2001 and August 2002 with last follow up in 2004. All 90 patients received ^{90}Y -edotreotide (31), and in this series 4 patients (4.4%; 95% CI, 0.2% to 8.6%) had a partial response, and 63 (70%) had stable disease. Of the 90 patients, 54 (60%) had grade 3 to 4 adverse events mainly as lymphopenia, nausea and vomiting, and three patients (3.3%) had grade 3 to 4 renal toxicity, which was transient (31). The main gastrointestinal side effects including nausea and vomiting were likely related to the co-infusion of amino acids that were administered as organ protectants (32).

PRRT has been largely used in Europe. It has limited availability in the United States for several reasons, including the absence of controlled, randomized multicenter clinical trials, along with the restricted access to several radionuclide peptides due to the regulations in the U.S., otherwise PRRT might be more frequently considered as a first line management strategy in unresectable somatostatin-positive disease (33).

Targeted therapies

Multi-targeted tyrosine kinase inhibitors and anti-angiogenic agents, e.g., Sunitinib, have activity in inhibiting all types of VEGFR and other tyrosine kinase receptors (6). One of the initial clinical trials in NET's evaluating sunitinib was a phase II study in NET's in 107 patients who received sunitinib at a dose of 50 mg daily for 4 weeks of every 6 weeks. Of the 66 patients with advanced PNETs, 11 (16.7%) had a partial response and 45 patients (68%) had stable disease (34).

A key phase III, multi-national, randomized, double-blinded, placebo-controlled study, compared sunitinib (37.5 mg daily) with placebo in 171 patients with progressive PNET (35). Patients were recruited between June 2007 and April 2009. The study was discontinued because of the difference in the progression-free survival favoring the sunitinib group and the greater number of deaths in the placebo group. Progression-free survival, the primary endpoint, in the sunitinib group was 11.4 versus 5.5 months in the placebo group (95% CI, 0.26 to 0.66;

$P < 0.001$). The objective tumor response rate, a secondary end point, was 9.3% in the sunitinib group versus 0% in the placebo group (35). Based on this study, the US Food and Drug Administration (FDA) approved sunitinib in May 2011 for the treatment of advanced PNET and it was also approved few months later in Europe and other countries around the world.

A recent small multicenter, phase II trial evaluated sunitinib in Japanese patients with well-differentiated PNET. Twelve patients received sunitinib dosed at 37.5 mg daily, of which six patients had a partial response and three had stable disease, for a clinical benefit response rate of 75% (95% CI, 43-94%). Progression-free survival was 91% (95% CI, 54-99%) at 6 months and 71% (95% CI, 34-90%) at 12 months (36).

Sunitinib has become integrated into the treatment of progressive well-differentiated pancreatic NET. The most common grade 1 and 2 side effects associated with sunitinib from the phase III experience are, diarrhea, nausea, asthenia, vomiting and fatigue, each occurring in more than 30% of patients. Other side effects include hand-foot syndrome (in about 23%), while grade 3 and 4 adverse effects included neutropenia (12%) and hypertension (10%) (35).

Sorafenib and pazopanib are other tyrosine kinase inhibitors, which have been evaluated in NET's. Sorafenib targets VEGFR-2, PDGFR-beta and raf kinase, and was initially evaluated in the treatment of advanced renal cell carcinoma and hepatocellular carcinoma (37). In a phase II trial of sorafenib in NET's, 93 patients were enrolled, 43 with PNET and 50 with carcinoid tumors. Ten percent of the patients (8 patients) had a partial response and 12.9% (12 patients) had a minor response (20-29% decrease in target lesion) for an overall response rate of 32% in PNET and 17% in carcinoid tumors. Six months progression-free survival was 60.8% in the PNET group and 40% in carcinoid tumors for evaluable patients (38).

A phase II trial evaluated the combination of sorafenib and bevacizumab in patients with advanced NET. Forty-four patients were enrolled and the overall response rate was 9.8% and the disease control rate was 95.1%. The estimated progression-free survival was 12.4 months (95% CI: 9.4-16.2 months) (39).

Pazopanib, which also inhibits both VEGFR and PDGFR, has been assessed in a phase II clinical trial in which 51 patients with NET on stable octreotide LAR doses were treated with pazopanib. Of the 46 patients who completed 12 weeks of treatment and were evaluable for response, 30 patients had PNET and the response rate was

17% (5/30). The progression-free survival rate was 80% after 24 weeks, and median PFS times were 11.7 months in PNET patients (40).

Bevacizumab, a monoclonal antibody that binds to VEGF in the blood and inhibits the binding of VEGF to its receptors in the endothelial cells, and thus inhibiting angiogenesis (41). Forty-four patients on a stable dose of octreotide were enrolled in a phase II clinical trial to receive 18 weeks of either bevacizumab or pegylated-interferon alpha-2b. At the end of 18 weeks or progression of disease (whichever first) patients received the combination of both therapies along with continued octreotide. The results revealed that only 5% of patients in the bevacizumab group had progression of disease while 27% of the pegylated-interferon alpha-2b group had progression of disease, and the corresponding progression-free survivals were 95% in the bevacizumab versus 68% in the pegylated interferon alpha-2b group after 18 weeks of monotherapy (42). There are several ongoing trials investigating the efficacy and safety of bevacizumab in combination with other agents in the treatment of PNETs (Table 5).

Overall, the collective experience evaluating anti-angiogenic and tyrosine kinase inhibitors in NET's and PNET's in particular, has yielded encouraging results with one approved drug in PNET's (sunitinib) and several others in late stage development.

mTOR inhibitors

mTOR is a serine-threonine kinase that regulates cell growth and proliferation. Several cancer-promoter ligands such as EGFR, AKT, PI3K, HER2 and BCR-ABL, can activate mTOR and stimulate cell growth, proliferation and survival. The mTOR signaling pathway is one of the major pathways that are found to be dysregulated in many neoplasms and play a big role in cancer growth and pathogenesis (43).

Everolimus is an mTOR inhibitor which is orally bioavailable and which binds to its intracellular receptor with high affinity and interacts with mTOR to inhibit the downstream signaling pathway and prevent cancer cell proliferation (44). Everolimus was initially evaluated for NETs in a phase II study in combination with octreotide LAR (45). Sixty patients were enrolled and received 5 or 10 mg of everolimus daily in combination with octreotide LAR. Twenty-two per cent of patients had a partial response and 70% had stable disease and the median progression-free survival was 60 weeks (45).

A phase III, international, multicenter, double-blind, randomized trial (RADIANT-3) assigned 410 patients with advanced low grade or intermediate grade PNET from 18 countries between July 2007 and May 2009, to receive everolimus 10 mg daily or placebo along with best supportive care (46). Eligibility criteria included adults with low-grade or intermediate-grade advanced PNET with disease progression in the last 12 months. Patients were excluded if they had prior treatment with mTOR inhibitor, had hepatic artery embolization in the last 6 months, cryoablation or radiofrequency ablation in the last 2 months or were receiving long-term treatment with immunosuppressants. The primary endpoint, median PFS, was 11 months (95% CI, 8.4 to 13.9 months) for patients treated with everolimus versus 4.6 months for patients treated with placebo (95% CI, 3.1 to 5.4 months). The percentage of patients with PFS at 18 months was 34% (95% CI, 26% to 43%) in the everolimus group versus 9% (95% CI, 4% to 16%) in the placebo group (46). Grade 1 and 2 side effects included stomatitis (64%), rash (49%), diarrhea (34%), fatigue (31%), infection (23%) and pneumonitis (12%), while grade 3 and 4 side effects included hyperglycemia (5%), anemia (6%), stomatitis (7%), and thrombocytopenia (4%) (46).

Other evaluations of everolimus have been undertaken, e.g., in a phase II clinical trial where everolimus was given in combination with bevacizumab. Results showed an overall response rate of 26% and stable disease in 69% of patients. The progression-free survival rate at 6-month was 92% and the median progression-free survival was 14.4 months (95% CI, 12.7-16.1 months) (47). These data suggest that the combination of octreotide and everolimus may have clinical utility.

Temsirolimus, another mTOR inhibitor, which is given intravenously, has been evaluated as monotherapy in a phase II study that enrolled 37 patients to receive temsirolimus 25 mg intravenously weekly. The objective response rate was 5.6% (95% CI, 0.6-18.7%) while 63.9% (95% CI, 46.2-79.2%) of patients had disease control (stable disease or partial response), with a reported survival rate of 91.6% (95% CI, 82.9-100%) at 6 months and 71.5% (95% CI, 57.1-89.5%) at 1-year (48). Further evaluation of temsirolimus (25 mg intravenously weekly) in combination with bevacizumab (10 mg/kg every two weeks) was studied in a phase II clinical trial for which preliminary results were presented at the 2012 Gastrointestinal Cancers symposium (49). Data from 35 patients with progressive PNET had a partial response in 52% of patients and the 6-month progression-

Table 5 Selected ongoing clinical trials for neuroendocrine cancers

Sponsor, NCT #	Phase	N	Drug(s)	Title/design	Primary endpoint
Sarah Cannon Research Institute NCT01121939	2	43	Bevacizumab Pertuzumab Sandostatin LAR	Combination of bevacizumab, pertuzumab and sandostatin for patients with advanced NET	Response rate
Dana-Farber Cancer Institute NCT00137774	2	34	Bevacizumab Temozolomide	Bevacizumab in combination with temozolomide in patients with advanced NET	Response rate
University of California, SF NCT00227617	2/3	70	Bevacizumab 5-fluorouracil Leucovorin Oxaliplatin	FOLFOX in combination with Bevacizumab in patients with advanced NET	Safety, response rate
Stanford University NCT01525082	2	30	Bevacizumab Capecitabine Temozolomide	Capecitabine, temozolomide and bevacizumab for metastatic or unresectable PNET	Response rate
National Cancer Institute (NCI) NCT01010126	2	299	Bevacizumab Temsirrolimus	Temsirrolimus and bevacizumab in patients with endometrial, ovarian, hepatocellular carcinoma, carcinoid or islet cell cancer	Response rate
National Cancer Institute (NCI) NCT01229943	2	138	Everolimus Octreotide Bevacizumab	Everolimus and octreotide with or without bevacizumab in patients with advanced PNET	Progression-free survival
Novartis Pharmaceuticals NCT00363051	2	160	Everolimus	Safety/efficacy of everolimus in adults with PNET who have progressed on chemotherapy	Objective response rate
National Cancer Institute (NCI) NCT01229943	2	138	Everolimus Octreotide Bevacizumab	Everolimus and octreotide with or without bevacizumab in patients with advanced PNET	Progression-free survival
Pfizer NCT01121562	2	12	Sunitinib	Sunitinib in PNET	Clinical benefit response rate
Pfizer NCT01525550	4	80	Sunitinib	The efficacy and safety of sunitinib malate in patients with progressive metastatic well-differentiated PNET	Progression-free survival
Novartis Pharmaceuticals NCT01374451	2	150	Pasireotide Everolimus	Efficacy of everolimus alone or in combination with pasireotide LAR in advanced PNET	Progression-free survival
National Cancer Institute (NCI) NCT00131911	2	90	Sorafenib tosylate	Sorafenib in progressive metastatic neuroendocrine tumors	Confirmed response rate (CR or PR)
Grupo Espanol de Tumores Neuroendocrinos NCT01280201	2	44	Pazopanib	Pazopanib in advanced NETs	Clinical benefit rate at six months
Massachusetts General Hospital NCT01466036	2	70	Cabozantinib	Cabozantinib in advanced PNET and carcinoid tumors	Response rate

free survival was 84% in evaluable patients (49). The major side effects of this treatment combination were hypertension, leucopenia, lymphopenia, hyperglycemia, mucositis, hypokalemia and fatigue (49). *Table 5* summarizes trials that are ongoing evaluating targeted therapies in NET's.

Cytotoxic therapies

Pancreatic NET's typically can respond to cytotoxic chemotherapy, with traditionally alkylating agents being utilized. Streptozocin-based treatment was one of the early cytotoxic regimens to be evaluated in patients with advanced PNET. In a multicenter randomized trial, streptozocin plus doxorubicin was demonstrated to be superior to doxorubicin plus 5-fluorouracil in regard to response rate (69% *vs.* 45%, $P=0.05$) and median survival (2.2 *vs.* 1.4 years, $P=0.04$) (50). A large retrospective study evaluated 84 patients with either locally advanced or metastatic NET that received streptozocin, 5-FU and doxorubicin. Activity was demonstrated with a response rate of 39% (95% CI, 27% to 50%), median progression-free survival of 18 months and 2-year progression-free survival was 41% (95% CI, 26% to 56%). The median overall survival was 37 months and the 2-year overall survival was 74% (95% CI, 61% to 87%) (51).

Temozolomide, another alkylating agent with activity against NET, was evaluated as a monotherapy in a retrospective study of 36 patients. A partial response was observed in 14% of patients and stable disease in 53%. The median overall time to progression was 7 months (95% CI, 3 to 10 months) (52). Subsequently, temozolomide was given in combination with other agents. In one study 34 patients were treated with temozolomide combined with bevacizumab. The response rate in PNET patients was 33%, and the median progression-free survival was 14.3 months and median overall survival was 41.7 months (53). A further trial evaluated the combination of temozolomide with everolimus in a phase I/II clinical trial of 24 patients with advanced PNET. Thirty-five per cent had a partial response and 53% had stable disease (54).

Emerging data has demonstrated the utility of temozolomide combined with capecitabine in NET's. Specifically in a retrospective study of 30 patients with metastatic PNET treated with temozolomide in combination with capecitabine, an overall response rate of 70% (95% CI, 54-86%) was observed and the overall survival at two years was 92% (95% CI, 72-98%) and the median progression free survival was 18 months (95%

CI, 9-31 months) (55). An ongoing phase II clinical trial is being conducted to evaluate the efficacy and safety of temozolomide and capecitabine combination in progressive differentiated NETs (NCT00869050). A planned phase II study by the Eastern Cooperative Oncology Group (ECOG) and National Cancer Institution (NCI) will randomize patients to temozolomide with or without capecitabine to evaluate the survival and response rate in advanced PNET (NCT01824875).

Alkylating agents, such as temozolomide, have the ability to induce cell death and apoptosis by the methylation of DNA at the O^6 position of guanine. Subsequently the methylation of guanine will lead to DNA mismatch and apoptosis of tumor cells (56). A DNA repair enzyme, O_6 -methylguanine-DNA methyltransferase (MGMT), has the ability to restore the damaged DNA to its original form and prevent cell death, and so the availability of this enzyme will determine the sensitivity of tumor cells to alkylating agents (57), in other words, the deficiency of MGMT enzyme is associated with better response to temozolomide-based treatment and better survival, while the availability of this enzyme can contribute to resistance to temozolomide as well as other alkylating drugs such as streptozocin and dacarbazine (56).

Oxaliplatin-containing regimens have recently been evaluated in NET's. A phase II trial of FOLFOX (oxaliplatin, 5-fluorouracil and leucovorin) and bevacizumab revealed a partial response in 33% and stable disease in 67% of patients with pancreatic NETs (58). Another phase II trial assessing the activity of oxaliplatin in combination with capecitabine and bevacizumab in patients with advanced NETs reported 23% of the patients as having a partial response and 71% had stable disease. The one-year progression-free survival was 52% and the median progression-free survival was 13.7 months (59).

Poorly differentiated PNETs tend to be more responsive to cytotoxic chemotherapy than well-differentiated PNET's. For these former patients, particularly the high grade poorly differentiated PNET's cytotoxic therapy is likely the mainstay with treatment options including cisplatin and etoposide, streptozocin-based therapies, and emerging options of capecitabine and temozolomide and oxaliplatin/fluoropyrimidine and bevacizumab combinations. One study of cisplatin and etoposide, a commonly used combination regimen for small cell lung cancer, was used to treat 45 patients with neuroendocrine carcinoma (60). The treatment was associated with a 67% response rate in the 18 patients with poorly differentiated NETs, while it had

little effect on well-differentiated NETs. In another study, 36 patients with advanced NET (poorly differentiated or rapidly progressing NET) were treated with cisplatin and etoposide. The overall response rate for PNET was 36% and median survival time was 13 months (61). In a phase II prospective study, 78 patients with poorly differentiated NETs (exact type not specified) were treated with carboplatin, etoposide and paclitaxel. The response rate was 53% and the overall survival was 14.5 months (95% CI, 9.5 to 18.5 months). However this three-drug regimen was moderately toxic and did not have an efficacy advantage when compared to the standard platinum plus etoposide regimens (62).

To summarize, cytotoxic therapy has an established mainstay for the treatment of PNET's, albeit with few randomized trials to guide therapy. Specifically, for high grade poorly differentiated PNET's, a platinum and etoposide combination remains a reference standard. For well-intermediate differentiated PNET's, capecitabine and temozolomide is an emerging standard and it remains to be seen whether routine evaluation of MGMT promoter methylation status will be validated for refining therapy.

Regional and liver directed therapies

Cytoreductive surgery, or debulking surgery, defined as the removal of >90% of the tumor volume including the primary tumor if present, is usually conducted in functional NETs to reduce symptoms when medical treatment has been maximized, and this type of intervention is occasionally justified as a palliative measure (63). Debulking surgery typically refers to debulking of hepatic metastases when the liver is the predominant site of spread with mainly intrahepatic tumor growth, slowly growing tumors and in settings when the primary tumor and its metastases are amenable for resection (64). As reported in the literature in retrospective series of highly selected patients, a significant percentage of patients, 88%, can achieve effective symptom control and the 5-year survival rate approaches 60-70% after debulking surgery (64).

Hepatic artery embolization (HAE) is considered in patients with liver predominant disease and disease typically not amenable for surgical resection. Studies have shown HAE to be effective in slowing tumor growth and alleviating symptoms caused by the tumor. Hepatic artery embolization can be performed with bland trans-catheter arterial embolization (TAE), trans-catheter arterial chemoembolization (TACE) or

chemoembolization with drug-eluting beads (65). At this time, there is no consensus as to which modality is preferable. The chemotherapy agent used in chemoembolization (TACE) is usually doxorubicin or streptozocin in combination with lipiodol, and the response rate in one series was 67% of the treated patients (66). Side effects can develop after the embolization due to post-embolization syndrome such as nausea and vomiting (50-70%), upper quadrant abdominal pain (50-60%), fever (30-60%), and transaminitis (100%), all of which are usually mild and transient, while major complications are rare but can include liver failure, renal failure, bleeding, infection (higher risk following prior biliary reconstruction) and even death. The relative to absolute contraindications to this type of treatment include, complete portal vein thrombosis, hepatic failure and previous biliary anastomosis (67), where the latter can dramatically increase the risk of liver abscesses, which in one series occurred in up to 33% of such patients (68).

Radioembolization is another embolization technique that is gaining traction in the treatment of NET's and uses radioactive isotopes such as yttrium 90 (⁹⁰Y). These isotopes are infused through a catheter via the hepatic artery to reach tumor arteriolar level where high dose radiation is delivered and results in tumor necrosis (69). In several studies, the response rate was about 42-63% (69-71). Grade 1 and 2 toxicities included fatigue (56%), abdominal pain (26%), nausea (23%) and fever (6%) (69). Grade 3 toxicities were fatigue (6.5%), nausea (3.2%) and pain (2.7%) (71).

There are no randomized studies to compare among TAE, TACE or radioembolization; thus, any one of these three techniques is considered an appropriate palliative treatment for patients with NET with liver metastases. However, the field of locoregional therapies for NET's would greatly benefit from carefully designed prospective randomized trials to better understand the oncologic impact, selection criteria and other considerations which would identify one approach as being superior to another for selected subgroups of patients.

Conclusions

Significant progress has been made in understanding the changing epidemiology and molecular biology and classification of PNET's. Treatment options are varied and include surgery, regional approaches, targeted therapies and systemic cytotoxic therapies. The broad range of therapeutic considerations requires careful multi-disciplinary assessment

to determine which approach is best for a given patient at a given time point in the disease course and this point underscores an urgent need in the field to study sequencing of therapies and combinations of approaches.

Systemic treatment options for pancreatic neuroendocrine tumors include somatostatin analogues as first line treatment if patients have somatostatin receptors positive tumors, and are recommended for control of hormonal production and for anti-proliferative effects in low grade well-differentiated PNET's. Cytotoxic combination therapy such as temozolomide and capecitabine is an emerging combination and may be an initial step for a subset of patients with symptomatic, SSR negative, intermediate to high grade, or progressing disease. Several recent studies have demonstrated that tyrosine kinase inhibitors such as sunitinib and mTOR inhibitors such as everolimus both improve progression-free survival in patients with advanced well-differentiated PNETs and both have become established regulatory authority approved therapies. In poorly differentiated pancreatic NET with very high mitotic rates (e.g., small cell type), combination systemic chemotherapy with platinum-based therapies similar to the regimens used for small cell lung carcinoma, are typically considered as a first step. For poorly differentiated, grade 3 NET's with mitotic rates >20% but not with proliferative rates akin to small cell type NET's, there is no consensus as to what is the best initial therapy. Regionally directed therapies with bland embolization, TACE or radioembolization may alleviate symptoms and give palliation for patients with liver confined or predominant disease. Peptide receptor radionucleotide therapy (PRRT) is a treatment modality that has shown significant promise but requires further rigorous investigation with carefully designed dosimetry studies to determine the optimal dose of the radio-isotope and to more fully evaluate the short and longer-term side effects along with evaluation as to when in the sequence of the range of available therapies for NET's it should best fit.

To summarize, PNET's traditionally a disease with limited treatment options, has become an entity with several newly approved therapies and for which investigators and the pharmaceutical industry alike have a newfound interest in drug development, research and clinical trials. The next decade of research is bright in PNET's and should provide new insights into the molecular underpinnings of this disease, therapy selection and sequencing of the available therapies.

Acknowledgements

Disclosure: The authors declare no conflict of interest.

References

1. Yao JC, Hassan M, Phan A, et al. One hundred years after "carcinoid": epidemiology of and prognostic factors for neuroendocrine tumors in 35, 825 cases in the United States. *J Clin Oncol* 2008;26:3063-72.
2. Öberg K, Knigge U, Kwekkeboom D, et al. Neuroendocrine gastro-entero-pancreatic tumors: ESMO Clinical Practice Guidelines for diagnosis, treatment and follow-up. *Ann Oncol* 2012;23 Suppl 7:vii124-30.
3. Maggard MA, O'Connell JB, Ko CY. Updated population-based review of carcinoid tumors. *Ann Surg* 2004;240:117-22.
4. Frilling A, Akerström G, Falconi M, et al. Neuroendocrine tumor disease: an evolving landscape. *Endocr Relat Cancer* 2012;19:R163-85.
5. Kazanjian KK, Reber HA, Hines OJ. Resection of pancreatic neuroendocrine tumors: results of 70 cases. *Arch Surg* 2006;141:765-9; discussion 769-70.
6. Naraev BG, Strosberg JR, Halfdanarson TR. Current status and perspectives of targeted therapy in well-differentiated neuroendocrine tumors. *Oncology* 2012;83:117-27.
7. Demirkan BH, Eriksson B. Systemic treatment of neuroendocrine tumors with hepatic metastases. *Turk J Gastroenterol* 2012;23:427-37.
8. De Dosso S, Grande E, Barriuso J, et al. The targeted therapy revolution in neuroendocrine tumors: in search of biomarkers for patient selection and response evaluation. *Cancer Metastasis Rev* 2013. [Epub ahead of print].
9. Missiaglia E, Dalai I, Barbi S, et al. Pancreatic endocrine tumors: expression profiling evidences a role for AKT-mTOR pathway. *J Clin Oncol* 2010;28:245-55.
10. Bergsland EK. The evolving landscape of neuroendocrine tumors. *Semin Oncol* 2013;40:4-22.
11. Stoica-Mustafa E, Pechianu C, Iorgescu A, et al. Pathological characteristics and clinical specifications in gastroenteropancreatic neuroendocrine tumors: a study of 68 cases. *Rom J Morphol Embryol* 2012;53:351-5.
12. Hirabayashi K, Zamboni G, Nishi T, et al. Histopathology of gastrointestinal neuroendocrine neoplasms. *Front Oncol* 2013;3:2.
13. Kim MK. Endoscopic ultrasound in gastroenteropancreatic neuroendocrine tumors. *Gut Liver* 2012;6:405-10.

14. Klimstra DS, Modlin IR, Coppola D, et al. The pathologic classification of neuroendocrine tumors: a review of nomenclature, grading, and staging systems. *Pancreas* 2010;39:707-12.
15. Cho MY, Kim JM, Sohn JH, et al. Current trends of the incidence and pathological diagnosis of gastroenteropancreatic neuroendocrine tumors (GEP-NETs) in Korea 2000-2009: multicenter study. *Cancer Res Treat* 2012;44:157-65.
16. Pape UF, Jann H, Müller-Nordhorn J, et al. Prognostic relevance of a novel TNM classification system for upper gastroenteropancreatic neuroendocrine tumors. *Cancer* 2008;113:256-65.
17. Rindi G, Klöppel G, Alhman H, et al. TNM staging of foregut (neuro)endocrine tumors: a consensus proposal including a grading system. *Virchows Arch* 2006;449:395-401.
18. Kulke MH, Bendell J, Kvols L, et al. Evolving diagnostic and treatment strategies for pancreatic neuroendocrine tumors. *J Hematol Oncol* 2011;4:29.
19. Halperin DM, Kulke MH. Management of pancreatic neuroendocrine tumors. *Gastroenterol Clin North Am* 2012;41:119-31.
20. Kulke MH, Anthony LB, Bushnell DL, et al. NANETS treatment guidelines: well-differentiated neuroendocrine tumors of the stomach and pancreas. *Pancreas* 2010;39:735-52.
21. Reidy DL, Tang LH, Saltz LB. Treatment of advanced disease in patients with well-differentiated neuroendocrine tumors. *Nat Clin Pract Oncol* 2009;6:143-52.
22. Rösch T, Lightdale CJ, Botet JF, et al. Localization of pancreatic endocrine tumors by endoscopic ultrasonography. *N Engl J Med* 1992;326:1721-6.
23. Toumpanakis C, Caplin ME. Update on the role of somatostatin analogs for the treatment of patients with gastroenteropancreatic neuroendocrine tumors. *Semin Oncol* 2013;40:56-68.
24. Kulke MH, Mayer RJ. Carcinoid Tumors. *N Engl J Med* 1999;340:858-68.
25. Lamberts SW, van der Lely AJ, de Herder WW, et al. Octreotide. *N Engl J Med* 1996;334:246-54.
26. Wolin EM. The expanding role of somatostatin analogs in the management of neuroendocrine tumors. *Gastrointest Cancer Res* 2012;5:161-8.
27. Kvols LK, Moertel CG, O'Connell MJ, et al. Treatment of the malignant carcinoid syndrome. Evaluation of a long-acting somatostatin analogue. *N Engl J Med* 1986;315:663-6.
28. Rinke A, Müller HH, Schade-Brittinger C, et al. Placebo-controlled, double-blind, prospective, randomized study on the effect of octreotide LAR in the control of tumor growth in patients with metastatic neuroendocrine midgut tumors: a report from the PROMID Study Group. *J Clin Oncol* 2009;27:4656-63.
29. Arnold R, Wittenberg M, Rinke A, et al. *J Clin Oncol* 2013;31:abstr 4030. 2013 ASCO Annual Meeting.
30. Imhof A, Brunner P, Marincek N, et al. Response, survival, and long-term toxicity after therapy with the radiolabeled somatostatin analogue [90Y-DOTA]-TOC in metastasized neuroendocrine cancers. *J Clin Oncol* 2011;29:2416-23.
31. Bushnell DL Jr, O'Dorisio TM, O'Dorisio MS, et al. 90Y-edotreotide for metastatic carcinoid refractory to octreotide. *J Clin Oncol* 2010;28:1652-9.
32. Cwikla JB, Sankowski A, Seklecka N, et al. Efficacy of radionuclide treatment DOTATATE Y-90 in patients with progressive metastatic gastroenteropancreatic neuroendocrine carcinomas (GEP-NETs): a phase II study. *Ann Oncol* 2010;21:787-94.
33. Graham MM, Menda Y. Radiopeptide imaging and therapy in the United States. *J Nucl Med* 2011;52 Suppl 2:56S-63S.
34. Kulke MH, Lenz HJ, Meropol NJ, et al. Activity of sunitinib in patients with advanced neuroendocrine tumors. *J Clin Oncol* 2008;26:3403-10.
35. Raymond E, Dahan L, Raoul JL, et al. Sunitinib malate for the treatment of pancreatic neuroendocrine tumors. *N Engl J Med* 2011;364:501-13.
36. Ito T, Okusaka T, Nishida T, et al. Phase II study of sunitinib in Japanese patients with unresectable or metastatic, well-differentiated pancreatic neuroendocrine tumor. *Invest New Drugs* 2013;31:1265-74.
37. Llovet JM, Ricci S, Mazzaferro V, et al. Sorafenib in advanced hepatocellular carcinoma. *N Engl J Med* 2008;359:378-90.
38. Hobday TJ, Rubin J, Holen K, et al. MC044h, a phase II trial of sorafenib in patients (pts) with metastatic neuroendocrine tumors (NET): A Phase II Consortium (P2C) study. *J Clin Oncol* 2007;25:abstr 4504.
39. Castellano DE, Capdevila J, Salazar R, et al. Sorafenib and bevacizumab combination targeted therapy in advanced neuroendocrine tumor: A phase II study of the Spanish Neuroendocrine Tumor Group (GETNE0801). *Journal of Clinical Oncology 2011 ASCO Annual Meeting Proceedings (Post-Meeting Edition)*, 2011:29.
40. Phan AT, Yao JC, Fogelman DR, et al. A prospective, multi-institutional phase II study of GW786034

- (pazopanib) and depot octreotide (sandostatin LAR) in advanced low-grade neuroendocrine carcinoma (LGNEC). *J Clin Oncol* 2012;28:abstr 4001.
41. Kasuya K, Nagakawa Y, Suzuki M, et al. Anti-vascular endothelial growth factor antibody single therapy for pancreatic neuroendocrine carcinoma exhibits a marked tumor growth-inhibitory effect. *Exp Ther Med* 2011;2:1047-52.
 42. Yao JC, Phan A, Hoff PM, et al. Targeting vascular endothelial growth factor in advanced carcinoid tumor: a random assignment phase II study of depot octreotide with bevacizumab and pegylated interferon alpha-2b. *J Clin Oncol* 2008;26:1316-23.
 43. Zhang YJ, Duan Y, Zheng XF. Targeting the mTOR kinase domain: the second generation of mTOR inhibitors. *Drug Discov Today* 2011;16:325-31.
 44. O'Donnell A, Faivre S, Burris HA 3rd, et al. Phase I pharmacokinetic and pharmacodynamic study of the oral mammalian target of rapamycin inhibitor everolimus in patients with advanced solid tumors. *J Clin Oncol* 2008;26:1588-95.
 45. Yao JC, Phan AT, Chang DZ, et al. Efficacy of RAD001 (everolimus) and octreotide LAR in advanced low- to intermediate-grade neuroendocrine tumors: results of a phase II study. *J Clin Oncol* 2008;26:4311-8.
 46. Yao JC, Shah MH, Ito T, et al. Everolimus for advanced pancreatic neuroendocrine tumors. *N Engl J Med* 2011;364:514-23.
 47. Yao JC, Phan AT, Fogleman D, et al. Randomized run-in study of bevacizumab and everolimus in low- to intermediate-grade neuroendocrine tumors using perfusion CT as functional biomarker. 2010 ASCO Annual Meeting, *J Clin Oncol* 2012;28:abstr 4002.
 48. Duran I, Kortmansky J, Singh D, et al. A phase II clinical and pharmacodynamic study of temsirolimus in advanced neuroendocrine carcinomas. *Br J Cancer* 2006;95:1148-54.
 49. Hobday TJ, Qin R, Reidy DL, et al. Multicenter phase II trial of temsirolimus and bevacizumab in pancreatic neuroendocrine tumor: Results of a planned interim efficacy analysis. *J Clin Oncol* 2012;30:abstr 4047.
 50. Moertel CG, Lefkopoulo M, Lipsitz S, et al. Streptozocin-doxorubicin, streptozocin-fluorouracil or chlorozotocin in the treatment of advanced islet-cell carcinoma. *N Engl J Med* 1992;326:519-23.
 51. Kouvaraki MA, Ajani JA, Hoff P, et al. Fluorouracil, doxorubicin, and streptozocin in the treatment of patients with locally advanced and metastatic pancreatic endocrine carcinomas. *J Clin Oncol* 2004;22:4762-71.
 52. Ekeblad S, Sundin A, Janson ET, et al. Temozolomide as monotherapy is effective in treatment of advanced malignant neuroendocrine tumors. *Clin Cancer Res* 2007;13:2986-91.
 53. Chan JA, Stuart K, Earle CC, et al. Prospective study of bevacizumab plus temozolomide in patients with advanced neuroendocrine tumors. *J Clin Oncol* 2012;30:2963-8.
 54. Kulke M, Blaszkowsky LS, Zhu AX, et al. Phase I/II study of everolimus (RAD001) in combination with temozolomide in patients with advanced pancreatic neuroendocrine tumors. 2010 ASCO Gastrointestinal Cancers Symposium. Abstract No. 223.
 55. Strosberg JR, Fine RL, Choi J, et al. First-line chemotherapy with capecitabine and temozolomide in patients with metastatic pancreatic endocrine carcinomas. *Cancer* 2011;117:268-75.
 56. Kulke MH, Hornick JL, Fraunhoffer C, et al. O6-methylguanine DNA methyltransferase deficiency and response to temozolomide-based therapy in patients with neuroendocrine tumors. *Clin Cancer Res* 2009;15:338-45.
 57. Kulke MH, Siu LL, Tepper JE, et al. Future directions in the treatment of neuroendocrine tumors: consensus report of the National Cancer Institute Neuroendocrine Tumor clinical trials planning meeting. *J Clin Oncol* 2011;29:934-43.
 58. Venook AP, Ko AH, Tempero MA, et al. Phase II trial of FOLFOX plus bevacizumab in advanced, progressive neuroendocrine tumors. *J Clin Oncol* 2008;26:abstr 15545.
 59. Kunz PL, Kuo T, Kaiser HL, et al. A phase II study of capecitabine, oxaliplatin, and bevacizumab for metastatic or unresectable neuroendocrine tumors: Preliminary results. *J Clin Oncol* 2008;26:abstr 15502.
 60. Moertel CG, Kvols LK, O'Connell MJ, et al. Treatment of neuroendocrine carcinomas with combined etoposide and cisplatin. Evidence of major therapeutic activity in the anaplastic variants of these neoplasms. *Cancer* 1991;68:227-32.
 61. Fjällskog ML, Granberg DP, Welin SL, et al. Treatment with cisplatin and etoposide in patients with neuroendocrine tumors. *Cancer* 2001;92:1101-7.
 62. Hainsworth JD, Spigel DR, Litchy S, et al. Phase II trial of paclitaxel, carboplatin, and etoposide in advanced poorly differentiated neuroendocrine carcinoma: a Minnie Pearl Cancer Research Network Study. *J Clin Oncol* 2006;24:3548-54.
 63. Steinmüller T, Kianmanesh R, Falconi M, et al. Consensus guidelines for the management of patients with liver metastases from digestive (neuro)endocrine

- tumors: foregut, midgut, hindgut, and unknown primary. *Neuroendocrinology* 2008;87:47-62.
64. Sarmiento JM, Que FG. Hepatic surgery for metastases from neuroendocrine tumors. *Surg Oncol Clin N Am* 2003;12:231-42.
 65. Mayo SC, Herman JM, Cosgrove D, et al. Emerging approaches in the management of patients with neuroendocrine liver metastasis: role of liver-directed and systemic therapies. *J Am Coll Surg* 2013;216:123-34.
 66. Gupta S, Yao JC, Ahrar K, et al. Hepatic artery embolization and chemoembolization for treatment of patients with metastatic carcinoid tumors: the M.D. Anderson experience. *Cancer J* 2003;9:261-7.
 67. O'Toole D, Maire F, Ruzsiewicz P. Ablative therapies for liver metastases of digestive endocrine tumours. *Endocr Relat Cancer* 2003;10:463-8.
 68. Mezhir JJ, Fong Y, Fleischer D, et al. Pyogenic abscess after hepatic artery embolization: a rare but potentially lethal complication. *J Vasc Interv Radiol* 2011;22:177-82.
 69. Sato KT, Lewandowski RJ, Mulcahy MF, et al. Unresectable chemorefractory liver metastases: radioembolization with 90Y microspheres--safety, efficacy, and survival. *Radiology* 2008;247:507-15.
 70. King J, Quinn R, Glenn DM, et al. Radioembolization with selective internal radiation microspheres for neuroendocrine liver metastases. *Cancer* 2008;113:921-9.
 71. Kennedy AS, Dezarn WA, McNeillie P, et al. Radioembolization for unresectable neuroendocrine hepatic metastases using resin 90Y-microspheres: early results in 148 patients. *Am J Clin Oncol* 2008;31:271-9.

Cite this article as: Mahjoub AR, O'Reilly EM. Emerging therapies for pancreas neuroendocrine cancers. *Chin Clin Oncol* 2013;2(3):23. doi: 10.3978/j.issn.2304-3865.2013.06.01