

# 3D laparoscopic anatomical hepatectomy guided by 2D real-time indocyanine green fluorescence imaging for hepatocellular carcinoma

Feng Tian, Li Cao, Jian Chen, Shuguo Zheng, Jianwei Li

Department of Hepatobiliary Surgery, Southwest Hospital, Army Medical University (Third Military Medical University), Chongqing, China

Correspondence to: Jianwei Li, PhD, MD. Department of Hepatobiliary Surgery, Southwest Hospital, Army Medical University (Third Military Medical University), No.30 Gaotanyan Street, Shapingba District, Chongqing 400038, China. Email: ljianwei1015@yeah.net.

**Abstract:** Laparoscopic anatomical hepatectomy (LAH) for patients with hepatocellular carcinoma (HCC) has been advocated by many surgeons in the hope of producing better oncological outcomes. Two recent techniques, 3D laparoscopic system and 2D real-time indocyanine green fluorescence imaging guidance (r-ICG), are benefit for improving the operative precision of LAH in different aspects. However, these two techniques cannot be applied concomitantly because of the technical limitation. Although a new modern laparoscopic system with both 3D and indocyanine green (ICG) imaging mode has been designed, it has not been listed in many countries including China. Thus, we design a new procedure to perform the 3D LAH with 2D r-ICG guidance for HCCs with conventional laparoscopic systems. In this procedure, both 3D and 2D laparoscopic systems were used. A total of 11 patients with HCC received 3D laparoscopic right posterior sectionectomy (LRPS) with 2D r-ICG guidance. The right posterior Glissonian pedicle was clamped under the 3D vision. Then ICG solution was then intravenously administrated. The liver parenchyma was transected under the 3D vision and guided by 2D ICG vision simultaneously. There was no severe complications (Clavien-Dindo  $\geq$ III) and operation related death. The 90-day mortality was also nil. By using this procedure, the advantages of two techniques, 3D laparoscopic system and 2D r-ICG guidance, were combined so that LAH could be performed with more precision. However, it should be validated in more studies.

**Keywords:** Laparoscopic anatomical hepatectomy (LAH); ICG fluorescence imaging; 3D laparoscopy; 2D laparoscopic ICG fluorescence imaging

Submitted Dec 03, 2022. Accepted for publication Apr 06, 2023. Published online Jun 07, 2023.

doi: 10.21037/hbsn-22-587

View this article at: <https://dx.doi.org/10.21037/hbsn-22-587>

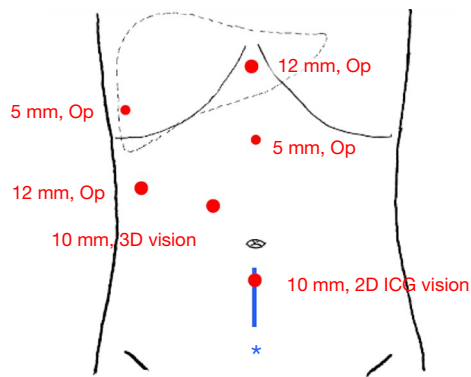
## Introduction

### Background

Hepatocellular carcinoma (HCC) accounts for 75–85% of primary liver cancer, which is the sixth common malignancy and the third leading cause of tumor-related death, thereby posing a significant threat to the life and health of the people around the world (1). Liver resection (LR) remains the mainstay of curative treatment for HCC. As a minimally invasive technique, the application of laparoscopic hepatectomy (LH) has increased rapidly

and is recommended by the international consensus (2). Compared with non-anatomic hepatectomy, laparoscopic anatomical hepatectomy (LAH) for patients with HCC has been advocated by many surgeons in the hope of producing better oncological outcomes (3,4).

The progress of LAH has always been largely depending on the development of equipment and technique. At first, LAH was performed using the 2D laparoscopic system. Two recent techniques are reported to facilitate the performance of LAH in different aspects. 3D laparoscopic system, which offers the surgeon binocular vision and depth perception,



**Figure 1** Diagram of trocar distribution for 3D laparoscopic right posterior sectionectomy with 2D r-ICG guidance. \*, the incision for the removal of the resected liver section. Op, operation; ICG, indocyanine green; r-ICG, real-time indocyanine green fluorescence imaging guidance.

could be an advantage in LAH compared with 2D system (5,6). By using the real-time indocyanine green fluorescence imaging (r-ICG) guidance under 2D laparoscopic system, the parenchymal transection of LAH could be performed with more precision (7,8). However, these two techniques cannot be used concomitantly in one surgery because of the technical limitation, which is also the hot pot of the technical research. Although a new modern laparoscopic system with both 3D and

indocyanine green (ICG) imaging mode has been designed, it has not been listed in many countries including China.

### Rationale

We designed a new procedure, 3D LAH with 2D r-ICG guidance. By using this procedure, both the techniques of 3D laparoscopy and 2D r-ICG guidance could be used concomitantly in one surgery. It showed fascinating prospect for LAH performance with more precision compared with precious techniques, and might be benefit for HCC treatment.

### Objective

The objective of this study was to evaluate the feasibility and safety of this new procedure, 3D LAH with 2D r-ICG guidance, in a small series of HCC patients. We present the following article in accordance with the SUPER reporting checklist (available at <https://hbsn.amegroups.com/article/view/10.21037/hbsn-22-587/rc>).

### Preoperative preparations and requirements

A total of 11 patients with HCC received 3D laparoscopic right posterior sectionectomy (LRPS) with 2D r-ICG guidance in our center between January 2021 and October 2022. All procedures performed in this study involving human participants were in accordance with the ethical standards of Southwest Hospital of Army Medical University and with the Helsinki Declaration (as revised in 2013). Written informed consent was obtained from the patient for publication of this case report and accompanying images. A copy of the written consent is available for review by the editorial office of this journal.

In this procedure, both 3D and 2D laparoscopic systems were used (Storz, Germany). Besides, four surgeons were needed in this procedure: chief surgeon, assistant surgeon and two scopists. One scopist operate the 3D scope and another scopist operate the 2D scope.

### Step-by-step description

The patient was placed in the supine position. Carbon dioxide pneumoperitoneum was established with a pressure of 11–13 mmHg. Six trocars were used (*Figure 1*): one 10-mm-port for 3D vision, one 10-mm-port for 2D vision, two 12-mm-ports and two 5-mm-ports for operation. The

#### Highlight box

##### Surgical highlights

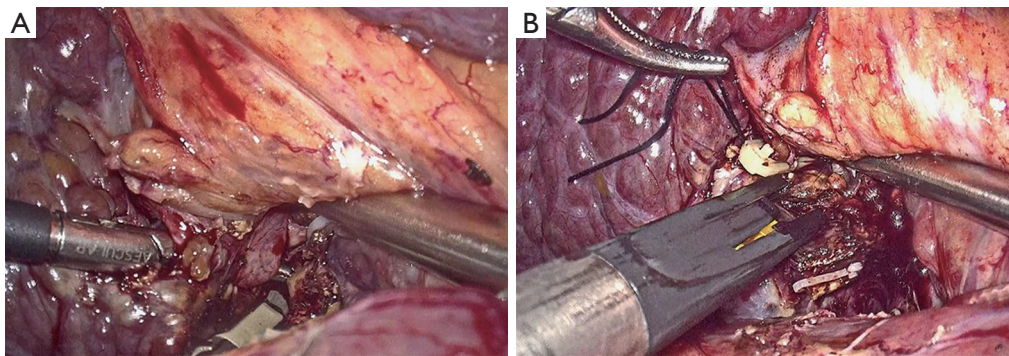
- We design a new procedure of 3D LAH with 2D r-ICG guidance for LAH performance in patients with HCC. The advantages of two previous techniques, 3D laparoscopic system and 2D r-ICG guidance, were combined so that LAH could be performed with more precision.

##### What is conventional and what is novel/modified?

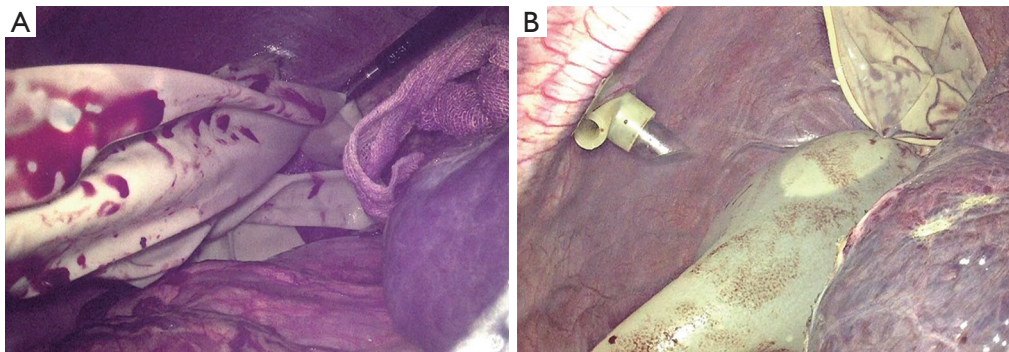
- Two recent techniques, 3D laparoscopic system and 2D r-ICG guidance, are reported to facilitate the performance of LAH in different aspects. However, these two techniques could not be used concomitantly in one surgery.
- In the new procedure, both 3D and 2D laparoscopic systems were used, and thus the above problems were solved. Our data showed that this procedure was feasible and safe for HCC treatment.

##### What is the implication, and what should change now?

- The new procedure showed fascinating prospect for LAH performance with more precision compared with precious techniques, and is benefit for HCC treatment.



**Figure 2** The right posterior Glissonian pedicle was isolated (A) and clamped (B) under the 3D vision.



**Figure 3** A glove was filled with water (A) and put in the right subphrenic position (B) so that the right posterior section was displaced towards the left anterior inferior direction.

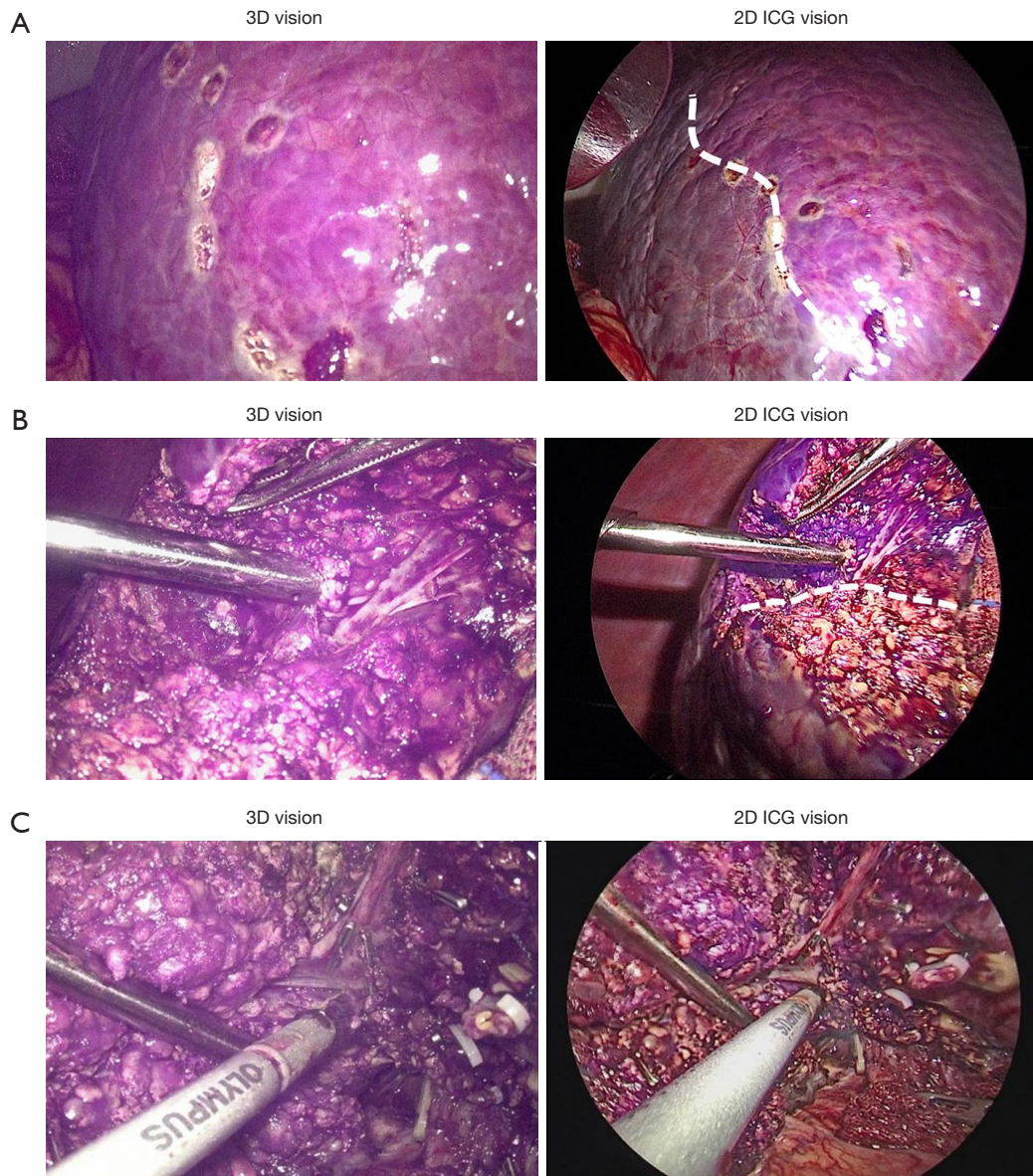
liver ligaments were severed under the 3D vision. The right posterior Glissonian pedicle was isolated and then clamped under the 3D vision (*Figure 2*, *Video S1*). A water-filled glove was put in the right subphrenic position so that the right posterior section was displaced towards the left anterior inferior direction (*Figure 3*, *Video S1*). Then 10 mL ICG solution (0.025 mg/mL) was intravenously administered. The preserved sections turned to purple within ten minutes after ICG administration under 2D ICG vision, and while the right posterior section was still dark, showing the appropriate resection line (*Figure 4A*). The liver parenchyma was transected by the ultrasonic dissector under both 3D and 2D vision concomitantly (*Figure 4B*, *Video S2*). The complicated operative skills, including Glissonian pedicle dissection, hepatic vein dissection and bleeding point suture placation, were performed under the 3D vision, while the parenchymal transected plane was guided by the r-ICG imaging under the 2D vision. The

intraparenchymal vascular and biliary structures ( $\geq 3$  mm) were ligated by titanium clips or Hem-o-lock clips. The right hepatic vein was exposed on the cut surface of the preserved liver parenchyma (*Figure 4C*). At last, the 2D vision port was extended for the removal of the resected section.

### Postoperative considerations and tasks

The operative parameters were shown in *Table 1*. The median age of the patients was 61 years, and all of them were complicated with hepatitis B virus (HBV) infection. The median operation time was 230 minutes. The median blood loss was 280 mL and none of the patients required transfusion. Besides, all patients got the negative surgical margin. There was no operation-related death. The postoperative complication rate was 9.1%. Only one patient suffered ascites after the operation. There was no severe complications (Clavien-Dindo  $\geq$ III). The median postoperative hospital stay





**Figure 4** The parenchymal transection in 3D laparoscopic right posterior sectionectomy with 2D r-ICG guidance. (A) The resection line on the surface under the 3D vision and 2D ICG vision simultaneously. (B) The parenchymal transected plane under the 3D vision and 2D ICG vision. (C) The right hepatic vein was exposed under the 3D vision and 2D ICG vision. r-ICG, real-time indocyanine green fluorescence imaging guidance; ICG, indocyanine green.

was 7 days. The 90-day mortality was nil.

### Tips and pearls

The data indicated that the 3D LRPS with 2D r-ICG guidance could be a feasibility and safety procedure for HCCs. This procedure showed fascinating prospect for

LAH with more precision in HCC treatment.

### Discussion

#### *Surgical highlights*

LAH has been advocated for HCC treatment worldwide.

**Table 1** The parameters of HCC patients received 3D laparoscopic right posterior sectionectomy with 2D r-ICG guidance

Parameters	Data (N=11)
Age (years)	61 [38–71]
Sex (male/female)	7/4
HBV infection	11
Operative time (min)	230 [200–293]
Intraoperative blood loss (mL)	280 [150–450]
Intraoperative blood transfusion	Nil
Positive surgical margin status	Nil
Postoperative complications (Clavien-Dindo)	1 (9.1%)
I–II	1 (9.1%)
III–IV (severe complications)	Nil
Postoperative hospital stays (days)	7 [5–10]
Perioperative mortality	Nil
The 90-day mortality	Nil

Data are presented as median [range], number, or n (%). HCC, hepatocellular carcinoma; r-ICG, real-time indocyanine green fluorescence imaging guidance; HBV, hepatitis B virus.

Two recent techniques, 3D laparoscopic system and 2D r-ICG guidance, are reported to facilitate the performance of LAH in different aspects. However, up to date, the above two techniques could not be used concomitantly in one surgery. Thus we designed a new procedure to perform the 3D LAH with 2D r-ICG guidance by using both conventional 3D and 2D laparoscopic systems, and the above problem was solved. This was the major highlight of our procedure.

In this procedure, we chose ICG negative staining in which the preserved liver parenchyma was stained by ICG. The timing for ICG staining is important. The preserved parenchyma turned to bright within ten minutes after ICG administration, and kept bright more than four hours. The time was enough for the parenchymal transection.

### ***Strengths and limitations***

This procedure showed fascinating prospect for LAH performance with more precision compared with conventional techniques. Besides, this procedure could be extended to perform most types of LAH besides LRPS. Moreover, it is easy to be extended in many countries.

However, there were several limitations. Firstly, two laparoscopic systems were used. Secondly, the extra length of the wound of 10-mm port were needed. Thirdly, one more scopist was need. Fourthly, the clinical benefit of this procedure needed to be validated in more studies.

### ***Comparison with other surgical techniques and researches***

The application of 2D r-ICG guidance is suggested for LAH with the advantage of the precise direction and course of parenchymal transection (2,7,8). 3D laparoscopy offers the surgeon binocular vision and depth perception, which facilitates the laparoscopic skills (9). Besides, 3D laparoscopy is reported to be associated with lower postoperative complications and shorter postoperative hospital stays compared with 2D system (5,10). However, the two techniques could not be used concomitantly in one surgery. By using our new procedure, both the above two techniques could be used concomitantly in one surgery, and thus the above advantages could be combined for LAH performance.

### ***Implications and actions recommended***

Our data indicated that this new procedure was feasible and safe for HCC treatment. In theory, it showed prospect for LAH with more precision compared with previous techniques and might be benefit for HCC treatment. We will validate it further in more studies.

### **Conclusions**

In conclusion, we proposed a new procedure of 3D LAH with 2D r-ICG guidance for patients with HCC. However, it should be assessed in more clinical studies.

### **Acknowledgments**

*Funding:* None.

### **Footnote**

*Reporting Checklist:* The authors have completed the SUPER reporting checklist. Available at <https://hbsn.amegroups.com/article/view/10.21037/hbsn-22-587/rc>

*Conflicts of Interest:* All authors have completed the ICMJE

uniform disclosure form (available at <https://hbsn.amegrouppublishing.com/article/view/10.21037/hbsn-22-587/coif>). The authors have no conflicts of interest to declare.

**Ethical Statement:** The authors are accountable for all aspects of the work in ensuring that questions related to the accuracy or integrity of any part of the work are appropriately investigated and resolved. All procedures performed in this study involving human participants were in accordance with the ethical standards of Southwest Hospital of Army Medical University and with the Helsinki Declaration (as revised in 2013). Written informed consent was obtained from the patient for publication of this case report and accompanying images. A copy of the written consent is available for review by the editorial office of this journal.

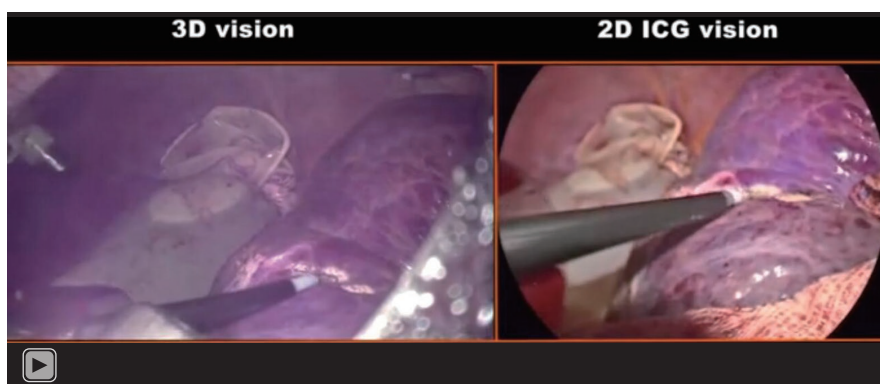
**Open Access Statement:** This is an Open Access article distributed in accordance with the Creative Commons Attribution-NonCommercial-NoDerivs 4.0 International License (CC BY-NC-ND 4.0), which permits the non-commercial replication and distribution of the article with the strict proviso that no changes or edits are made and the original work is properly cited (including links to both the formal publication through the relevant DOI and the license). See: <https://creativecommons.org/licenses/by-nc-nd/4.0/>.

## References

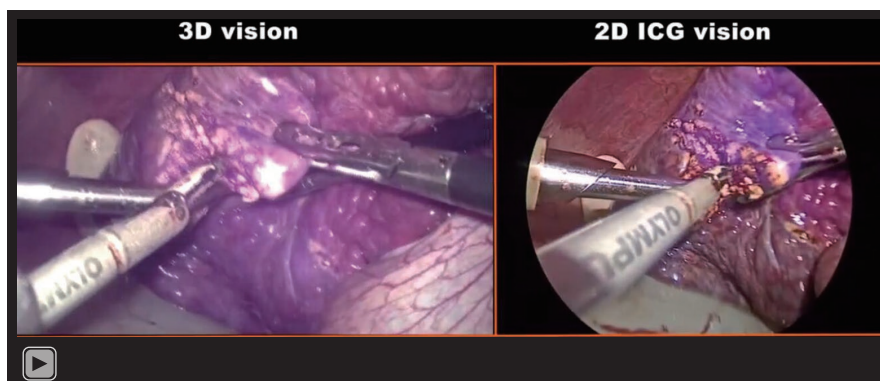
1. Sung H, Ferlay J, Siegel RL, et al. Global Cancer Statistics 2020: GLOBOCAN Estimates of Incidence and Mortality Worldwide for 36 Cancers in 185 Countries. *CA Cancer J Clin* 2021;71:209-49.
2. Cheung TT, Han HS, She WH, et al. The Asia Pacific Consensus Statement on Laparoscopic Liver Resection for Hepatocellular Carcinoma: A Report from the 7th Asia-Pacific Primary Liver Cancer Expert Meeting Held in Hong Kong. *Liver Cancer* 2018;7:28-39.
3. Shindoh J, Makuuchi M, Matsuyama Y, et al. Complete removal of the tumor-bearing portal territory decreases local tumor recurrence and improves disease-specific survival of patients with hepatocellular carcinoma. *J Hepatol* 2016;64:594-600.
4. Liao K, Yang K, Cao L, et al. Laparoscopic Anatomical Versus Non-anatomical hepatectomy in the Treatment of Hepatocellular Carcinoma: A randomised controlled trial. *Int J Surg* 2022;102:106652.
5. Au KP, Chan MY, Chu KW, et al. Impact of Three-Dimensional (3D) Visualization on Laparoscopic Hepatectomy for Hepatocellular Carcinoma. *Ann Surg Oncol* 2022;29:6731-44.
6. Buia A, Stockhausen F, Filmann N, et al. 3D vs. 2D imaging in laparoscopic surgery-an advantage? Results of standardised black box training in laparoscopic surgery. *Langenbecks Arch Surg* 2017;402:167-71.
7. Xu Y, Chen M, Meng X, et al. Laparoscopic anatomical liver resection guided by real-time indocyanine green fluorescence imaging: experience and lessons learned from the initial series in a single center. *Surg Endosc* 2020;34:4683-91.
8. Funamizu N, Ozaki T, Mishima K, et al. Evaluation of accuracy of laparoscopic liver mono-segmentectomy using the Glissonian approach with indocyanine green fluorescence negative staining by comparing estimated and actual resection volumes: A single-center retrospective cohort study. *J Hepatobiliary Pancreat Sci* 2021;28:1060-8.
9. Lai ECH. Assessing the Role of 3D Vision Technology for Laparoscopy. *Ann Surg Oncol* 2022;29:6522-3.
10. Arezzo A, Vettoretto N, Francis NK, et al. The use of 3D laparoscopic imaging systems in surgery: EAES consensus development conference 2018. *Surg Endosc* 2019;33:3251-74.

**Cite this article as:** Tian F, Cao L, Chen J, Zheng S, Li J. 3D laparoscopic anatomical hepatectomy guided by 2D real-time indocyanine green fluorescence imaging for hepatocellular carcinoma. *Hepatobiliary Surg Nutr* 2023. doi: 10.21037/hbsn-22-587





**Video S1** The Video One of 3D laparoscopic right posterior sectionectomy guided by 2D real-time ICG fluorescence imaging.



**Video S2** The Video Two of 3D laparoscopic right posterior sectionectomy guided by 2D real-time ICG fluorescence imaging.