

Single-organ cutaneous metastasis of rectal signet ring cell carcinoma

Wenqing Jia^{1,2#}, Zichao Guo^{1,2#^}, Xi Cheng^{1,2^}, Ren Zhao^{1,2^}

¹Department of General Surgery, Ruijin Hospital, Shanghai Jiao Tong University School of Medicine, Shanghai, China; ²Shanghai Institute of Digestive Surgery, Ruijin Hospital, Shanghai Jiao Tong University School of Medicine, Shanghai, China

#These authors contributed equally to this work.

Correspondence to: Xi Cheng, MD, PhD; Ren Zhao, MD, PhD. Department of General Surgery, Ruijin Hospital, Shanghai Jiao Tong University School of Medicine, 197 Ruijin 2nd Road, Shanghai 200025, China; Shanghai Institute of Digestive Surgery, Ruijin Hospital, Shanghai Jiao Tong University School of Medicine, Shanghai, China. Email: drchengxi@126.com; rjzhaoren@139.com.

Submitted Sep 01, 2023. Accepted for publication Oct 19, 2023. Published online Nov 09, 2023.

doi: 10.21037/hbsn-23-451

View this article at: <https://dx.doi.org/10.21037/hbsn-23-451>

Description of clinical issue

A 30-year-old man was admitted to the general surgery clinic with a 16-month history of two lumps located on his back (*Figure 1A*). Physical examination revealed solid components and scattered rashes without ulceration or palpable lymph nodes. He reported a history of rectal mucinous adenocarcinoma (pT4N2M0) and had undergone

Hartmann's procedure 8 months prior when the left lump progressed during postoperative FOLFIRI (folinic acid + fluorouracil + irinotecan) with cetuximab adjuvant therapy. Laboratory investigation showed abnormal elevation of serum carcinoembryonic antigen (27.2 ng/mL). Computed tomography revealed two low-density masses on his back but no abnormality in the lungs, liver, or bone. Pelvis magnetic resonance imaging revealed no

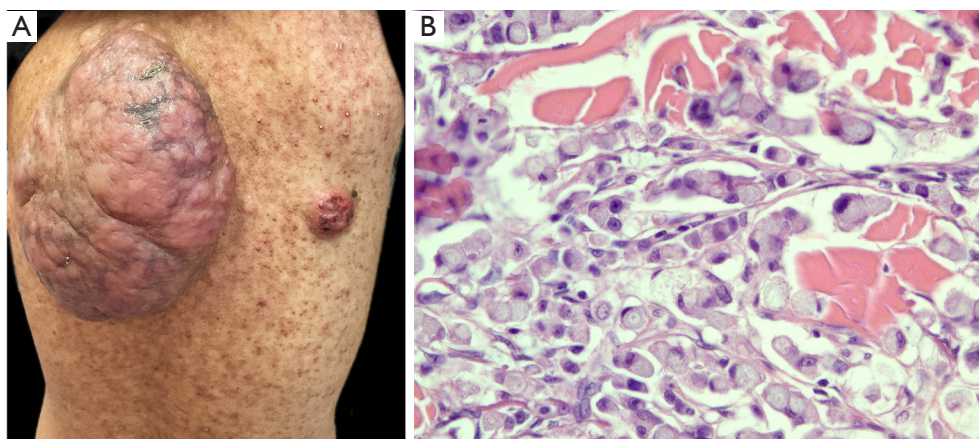


Figure 1 The macro- and microscopic pathologies of cutaneous metastasis of rectal cancer. (A) Two soft tissue lumps with acne-like rashes scattered on the back. (B) Postoperative pathology of resection specimen showing various irregularly arranged heteromorphic cells full of mucous (hematoxylin and eosin staining, $\times 40$).

[^] ORCID: Zichao Guo, 0000-0003-2669-2431; Xi Cheng, 0000-0002-0009-8189; Ren Zhao, 0000-0003-1978-5912.

local recurrence foci, while positron emission tomography revealed no hypermetabolic lesions. The biopsy of the left lump revealed malignant mucus-rich adenocarcinoma cells (Figure 1B), which indicated a diagnosis of rectal signet ring cell carcinoma metastasis. The finding of initial single-organ cutaneous metastasis supported a comprehensive physical examination for colorectal malignancy. The patient received wide local excision and skin reconstruction.

Acknowledgments

Funding: None.

Footnote

Provenance and Peer Review: This article was a standard submission to the journal. The article did not undergo external peer review.

Conflicts of Interest: All authors have completed the ICMJE uniform disclosure form (available at <https://hbsn.amegroups.com/article/view/10.21037/hbsn-23-451/coif>).

The authors have no conflicts of interest to declare.

Ethical Statement: The authors are accountable for all aspects of the work in ensuring that questions related to the accuracy or integrity of any part of the work are appropriately investigated and resolved. This study was conducted in accordance with the Declaration of Helsinki (as revised in 2013). Consent for use of images in this study was obtained from the patient.

Open Access Statement: This is an Open Access article distributed in accordance with the Creative Commons Attribution-NonCommercial-NoDerivs 4.0 International License (CC BY-NC-ND 4.0), which permits the non-commercial replication and distribution of the article with the strict proviso that no changes or edits are made and the original work is properly cited (including links to both the formal publication through the relevant DOI and the license). See: <https://creativecommons.org/licenses/by-nc-nd/4.0/>.

Cite this article as: Jia W, Guo Z, Cheng X, Zhao R. Single-organ cutaneous metastasis of rectal signet ring cell carcinoma. *HepatoBiliary Surg Nutr* 2023;12(6):1001-1002. doi: 10.21037/hbsn-23-451