

Spontaneous bilateral adrenal hemorrhage following cholecystectomy

Meryl Dahan¹, Chetana Lim^{1,2}, Chady Salloum¹, Daniel Azoulay^{1,3}

¹Henri Mondor Hospital, Department of Hepato-Pancreato-Biliary and Liver transplantation, Créteil, France; ²INSERM U965, Paris, France;

³INSERM U955, Créteil, France

Correspondence to: Daniel Azoulay, MD, PhD. Henri Mondor Hospital, 51 avenue De Lattre De Tassigny, 94010 Créteil, France.

Email: daniel.azoulay@hmn.aphp.fr.

Abstract: Postoperative bilateral adrenal hemorrhage is a rare but potentially life-threatening complication. This diagnosis is often missed because the symptoms and laboratory results are usually nonspecific. We report a case of bilateral adrenal hemorrhage associated with acute primary adrenal insufficiency following laparoscopic cholecystectomy. The knowledge of this uncommon complication following any abdominal surgery allows timely diagnosis and rapid treatment.

Keywords: Bilateral adrenal hemorrhage; laparoscopic cholecystectomy; primary adrenal insufficiency

Submitted Oct 13, 2015. Accepted for publication Nov 10, 2015.

doi: 10.21037/hbsn.2015.12.09

View this article at: <http://dx.doi.org/10.21037/hbsn.2015.12.09>

A 45-year-old obese woman underwent an uncomplicated laparoscopic cholecystectomy for acute cholecystitis. Because of past history of a deep lower limb venous thrombosis during pregnancy, she was under prophylactic low-molecular-weight heparin during the perioperative period. The postoperative course was uneventful and she was discharged on postoperative day 7, only because of wound infection. On postoperative day 9, the patient was readmitted to our department for abdominal pain, fever, nausea and vomiting. Physical examination showed diffuse abdominal pain and tenderness. There was no guarding or rebound and her wounds were healing normally. Laboratory results showed

the following: white blood cell count $17 \times 10^9/L$, hemoglobin 10.4 g/dL, platelet count $850 \times 10^9/L$, natremia 132 mmol/L, and kaliemia 4.9 mmol/L. Liver tests were within the normal range and prothrombin time was more than 80%.

Computed tomography and magnetic resonance imaging revealed bilateral adrenal hemorrhage (Figure 1). Laboratory results revealed a low serum cortisol of 54 nmol/L (normal values between 171 and 536 nmol/L). The antiphospholipid antibodies revealed the presence of significant lupus anticoagulant. A diagnosis of bilateral adrenal hemorrhage associated with primary adrenal insufficiency was made.

Postoperative adrenal hemorrhage is a rare but

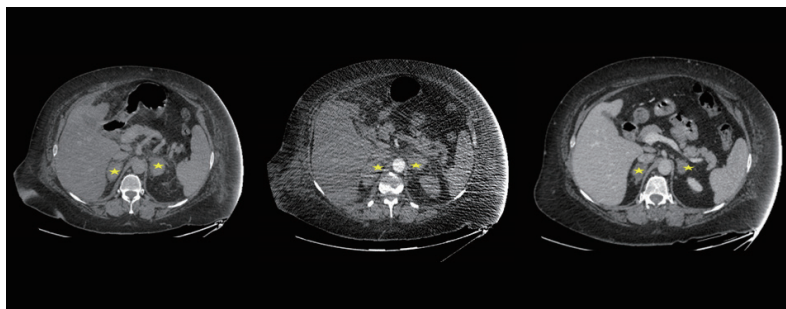


Figure 1 Computed tomography revealed bilateral adrenal hemorrhage (yellow star) complicating laparoscopic cholecystectomy.

potentially life-threatening complication if the condition is bilateral with a risk of adrenal failure. This diagnosis of often missed because the symptoms and laboratory results are usually nonspecific. Bilateral adrenal hemorrhages have been mostly described to be associated with heparin-induced thrombocytopenia (1), antiphospholipid syndrome (2) and sepsis (3). The diagnosis of adrenal hemorrhage can be made by a computed tomography showing adrenal gland enlargement with high attenuation without contrast enhancement. Our patient was treated with fludrocortisone treatment and curative anticoagulation. She's going well 6 months after.

Acknowledgements

None.

Footnote

Conflicts of Interest: The authors have no conflicts of interest

to declare.

Informed Consent: Written informed consent was obtained from the patient for publication of this case report and any accompanying images. A copy of the written consent is available for review by the editor-in-chief of this journal.

References

1. Ramon I, Mathian A, Bachelot A, et al. Primary adrenal insufficiency due to bilateral adrenal hemorrhage-adrenal infarction in the antiphospholipid syndrome: long-term outcome of 16 patients. *J Clin Endocrinol Metab* 2013;98:3179-89.
2. Warkentin TE, Sayfan EL, Linkins LA. Heparin-induced thrombocytopenia presenting as bilateral adrenal hemorrhages. *N Engl J Med* 2015;372:492-4.
3. Hiroi N, Ishimori H, Kaneko Y, et al. Bilateral adrenal hemorrhage due to sepsis resulting in acute adrenal crisis. *Intern Med* 2005;44:1017-8.

Cite this article as: Dahan M, Lim C, Salloum C, Azoulay D. Spontaneous bilateral adrenal hemorrhage following cholecystectomy. *HepatoBiliary Surg Nutr* 2016;5(3):263-264. doi: 10.21037/hbsn.2015.12.09