

Case Report**Cervical Adenosarcoma: Report of A Case and Literature Review**

Kun Zhang, Jin-song Han*, Fidelia Mbi,

*Department of Obstetrics and Gynecology, Peking University Third Hospital, Beijing 100191, China***CLC number: R737.33 Document code: A Article ID: 1000-9604(2010)03-0235-04****DOI: 10.1007/s11670-010-0235-0**

© Chinese Anti-Cancer Association and Springer-Verlag Berlin Heidelberg 2010

ABSTRACT

Cervical adenosarcoma was an extremely rare kind of Mullerian mixed tumor, and there was no optimal method of treatment. The aim of this article was to approach the better treatment method for this kind of disease. In this paper, the vaginal touch, the MRI image, and biopsy were used for diagnosis. And a conservative surgery was performed, followed by 4 cycles of VAC (VCR+KSM+CTX) chemotherapy. No evidence of recurrence was seen during follow-up till now. The conservative surgery and VAC chemotherapy in this patient was effective.

Key words: Cervical adenosarcoma**INTRODUCTION**

The cervical adenosarcoma is a Mullerian mixed tumor. These tumors have both benign adeno-epithelial and malignant interstitial components. At present, there exists no optimal method of treatment. In the present paper we reported a young case of cervical adenosarcoma, and discuss the issues of its diagnosis and best treatment strategy.

Case Report

A 12 years old female patient, without history of menstruation or sexual activity, presented with vaginal bleeding and discharge for 7 months, with the feeling of a mass protruding from the vagina for 6 months, and was admitted into our hospital on March 11, 2008. The patient experienced bloody discharge of varying amounts from the vagina since August 2007. The light reddish protrusion from the vagina was prominent especially after standing up for long periods of time or increasing abdominal pressure, with no tenderness or other complications. After consultation at another hospital

where Chinese herbal treatment and antibiotics were administered, patient experienced no relief. Seven days before admission, a biopsy of the vaginal mass was done, pathological examination revealed (Vaginal) paramesonephric duct papilloma. No similar family history existed; patient's mother denied any drug abuse or poisonous chemical products exposure during pregnancy.

On physical examination, the growth and development of the patient were normal, vulva was childlike, moist. A light yellowish-brown mass was seen at vaginal orifice, protruding from the vagina, grapelike. Upon exertion the mass slightly protruded beyond the hymen (Figure 1). Vaginal touch revealed the vagina was filled with nodular tumor tissue, the vaginal walls were smooth, and the cervix was impalpable.

Gynecological ultrasound revealed a mass within the cervix, about 7.6 cm×3.8 cm in size, with rich blood flow, RI=0.56. MRI showed an intravaginal leaf shaped mixed long T1, long T2 signal mass, and the base protruding into the cervical canal, about 6.4 cm×4.7 cm×7.2 cm in size, with clear borders, no vaginal walls invasion was detected (Figure 2).

Surgical treatment included colposcopy, resection of cervical canal tumor and hysteroscopy was performed on March 13, 2008, under local

Received 2010-03-23; Accepted 2009-05-22

*Corresponding author.

E-mail: hanjinsong353@sina.com

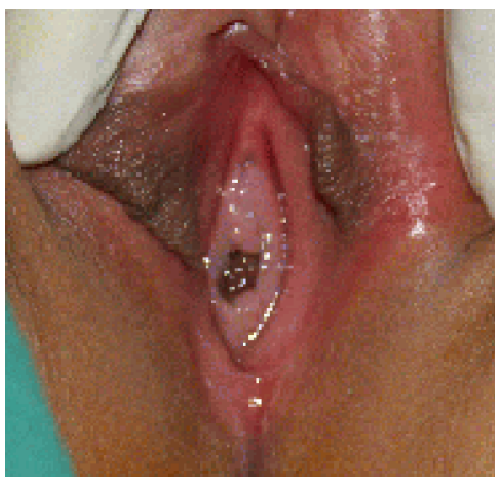


Figure 1. Examination of the patient prior to surgery, yellowish-brown tumor could be seen in the vagina.

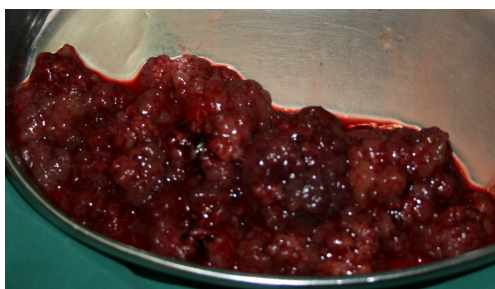

Figure 3. Gross tumor specimen.

anesthesia. The vagina was full of irregular papillary-like tissue, similar to decomposing meat (Figure 3). Oval forceps were used to retrieve most of the tumor, a cloth was used to apply pressure to the vaginal orifice, a low-pressure filling apparatus was used to swell up the vaginal cavity, during the hysteroscopy we noted the structure of the cervix to be normal, the stem of the mass protruding from the cervical canal could be identified, about 0.4 cm in diameter, its root was found on the lower posterior wall of the cervical canal, at a distance of about 0.5 cm from the external cervical os. A total resection of the mass was done, no abnormality was found upon re-examination of the uterine cavity, and bilateral tubal orifices were clearly seen. Post-operation recovery of the patient was satisfactory, and she was discharged 2 days later. The pathological diagnosis is (cervix) Mullerian-

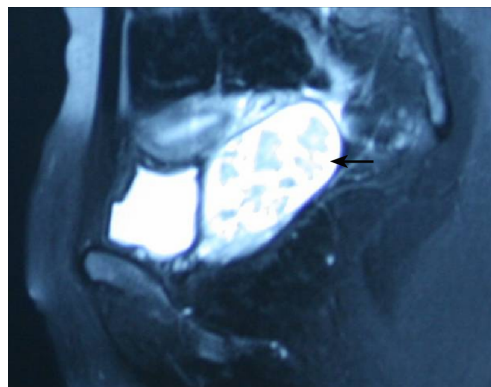


Figure 2. MRI image prior to surgery showing intravaginal tumor (as indicated by the arrow), but vaginal wall is smooth, and uterine structure is normal.

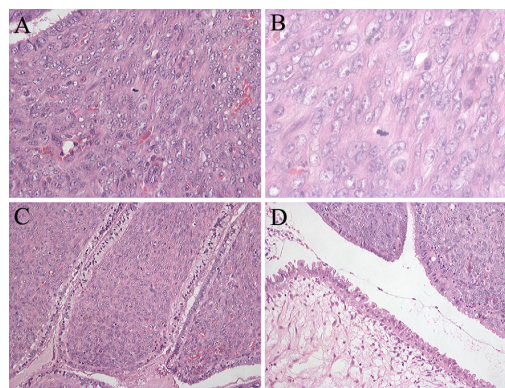


Figure 4. Pathologic examination of cervical adenosarcoma showing benign adeno-epithelial and malignant interstitial components (A, B: H& E, $\times 200$; C, D: H& E, $\times 50$).

originating adenosarcoma, total size of tumor 10 cm \times 8 cm \times 1 cm, cell rich, with obvious heteromorphism, mitosis 6/10 HPF (Figure 4). Immunohistochemical staining: CK7 (+), Desmin (+), SMA (+), CD10 (+), ER (+), PR (+++), CK20 (-), P53 (-), Ki-67: about 1%–2% (+). Considering the age of the patient, following profound discussion with the patient and her family, we planned a uterus sparing transvaginal local mass resection. On April 10, 2008, under lumbar anesthesia we conducted a hysteroscopy and partial cervix resection; during the surgery we found the vagina was normal, the structure of the cervix was normal with mild lesions. During the hysteroscopy both cervical canal and endometrium were found to be smooth and thin. The cervical mucosa at 1/3 of the cervicovaginal mid-external region was cut open, it was pushed upward about 2 cm, the cervix was

incised laterally, and the cut was sutured, then the cut with 1/3 of the external cervical mucosa was enveloped; after suturing, examination of the cervical canal revealed it to be patent. Post-operation pathological examination report revealed that Mullerian-originating adenosarcoma remnants could be seen in the cervical tissue, neutral cervical invasion depth was less than 1/2 the thickness of the cervix. No tumor was found in the borders of the cervix. Considering the patient's age, the massive size of the tumor, and its invasion of interstitial tissue, the family members requested that the patient's uterus must be spared, On April 11 2008, the patient begun to receive VAC chemotherapy (VCR 1-1.5 mg/m² d1 + KSM 5-7 μg/kg d2-6 + CTX 5-7 mg/kg d2-6), with 28 days intervals. And altogether 4 cycles were given. Four months post-operation, after the 3rd cycle of chemotherapy, a colposcopy was conducted and the cervix was smooth, of normal coloring, the cervical canal mucosa was normal, without new mass; Biopsies of the cervix from 3, 6, 9, 12 o'clock were done, and pathological results showed chronic cervicitis. Three months after the final cycle of chemotherapy, the patient experienced menarche, and her menstrual cycle is regular, 4-5 days/26 days. Seventeen months after the first operation, a vaginal examination was done and no mass was found in the vagina, the structure of the cervix was normal, and pelvic ultrasound showed the uterus and cervix was normal. On August 6, 2009, the vaginal examination revealed the smooth vaginal mucosa and the mild erosion cervix, without any mass found, biopsies of the cervix at 2, 3, 6, 11, 12 o'clock were done. The pathological results showed chronic cervicitis. A strict follow-up of the patient continues hitherto, and with no signs of tumor recurrence detected.

DISCUSSION

The cervical adenosarcoma is a Mullerian mixed tumor. These tumors have both adeno-epithelial and interstitial components, of which the adeno-epithelial components are benign and interstitial components are malignant sarcomas, the cells usually feature atypical hyperplasia. In 1974, Clement^[1] stipulated that the diagnosis criteria of adeno-sarcomas is interstitial cell mitosis equal to or greater than 4/10 HPF, implying that large amounts of interstitial cells and atypical interstitial cells appear, and cell mitosis greater than 2/10 HPF can confirm a diagnosis. When this co-exists with excessive growth of the sarcoma tissue, immuno-

staining showed strong expression of Ki-67 and P53^[2].

Verschraegen^[3] during his research discovered that most adenosarcoma originate from the endometrium (about 71%), and others originate from the ovary (15%), the pelvic cavity (12%), the cervix (2%). Endometrial Sarcomas mainly occur in post-menopausal women, whereas cervical sarcomas are common in child-bearing age women. Jones^[4] reported the average age to be 37 years (13 to 67 years), amongst which 1/3 of the patients are less than 15 years old. Since the age of occurrence is quite young, most patients have no sexual history, out-patient clinic check-ups usually don't involve vaginal or cervical manual examinations, missed diagnoses are common. However, many reports show that in children or patients with no sexual history that have abnormal manifestations, after communication the use of one finger to examine the vagina, assisted by anal examination can be really helpful to the early diagnosis of the disease. Hysteroscopies can be used for vaginal examination and biopsy in patients with no sexual history, thus aiding in the early diagnosis and treatment of the disease.

Since uterine or cervical sarcomas are rare, at present, there exists no optimal method of treatment, and also the malignant potential is unknown, most scholars encourage a hysterectomy, usually coupled with bilateral salpingo-oophorectomy^[5]. However, in the treatment of cervical sarcomas, since the disease is common in women of child-bearing age, fertility sparing or hormonal functions have to be taken into consideration. For young women where the tumor has a root, with no invasion, a simple tumor resection can be done, thus preserving reproductive function. But all the borders of the root have to be removed and valid histological examinations have to be done, to confirm the complete removal of the tumor. If the report indicates that the tissue borders still have the tumor, a second more invasive surgery is required^[6].

For patients with only superficial invasion, after a total hysterectomy and bilateral salpingo-oophorectomy, no adjuvant therapy is required. But in cases with deeper invasion, since there is a high rate of recurrence after surgery, some scholars advise that high-dose pelvic radiotherapy should be conducted after surgery, but there is no confirmation on the administration of chemotherapy^[7].

Long-term follow-up after treatment is very important, and articles have reported^[4, 5, 7] that the recurrence rate 5 years post-treatment is very low,

local recurrence rate after a total hysterectomy and bilateral salpingo-oophorectomy is 24%–38%, distal recurrence is 5%, with the time of recurrence being 0.5–9.5 years. However, there have been stipulations that adjuvant chemotherapy and radiotherapy can decrease local recurrence, but the efficacy is uncertain^[8]. Factors affecting prognosis include cervical adenosarcoma co-existing with excessive growth, if the adenosarcoma has heterologous elements, invasion of deep muscle layer or extrauterine invasion, and all these are related to recurrence^[9], also including tumor invasion of lymph ducts or towards rhabdomyosarcoma differentiation, all affect prognosis.

In the diagnosis and treatment of the case of cervical adenosarcoma discussed in this article, vaginal examination was pivotal, which can play a key role in locating the origin of the tumor and involvement of surrounding tissue. Using hysteroscope during surgery, especially in patients with no sexual history, will not only reduce the injury to the hymen caused by traditional surgery methods, but also can provide a clear view of the vagina, cervix, cervical canal, and the uterine cavity, enabling biopsy and resection of the tumor.

Since cervical adenosarcomas are rare, there is no clearly defined treatment for the disease. We opted for a conservative treatment which included uterus-sparing and partial cervical resection, thus preserving reproductive functions of the patient. After the surgery 4 cycles of VAC chemotherapy were included to the treatment, as well as many follow-up examinations which included cervical biopsy pathology examination, no recurrence of the

tumor was detected, and long-term outcome requires regular follow-up.

REFERENCES

- [1] Clement PB, Scully RE. Müllerian adenosarcoma of the uterus. A clinicopathologic analysis of ten cases of a distinctive type of Mullerian mixed tumor[J]. *Cancer* 1974; 34:1138–49.
- [2] Gallardo A, Prat J. Mullerian adenosarcoma: a clinicopathologic and immunohistochemical study of 55 cases challenging the existence of adenofibroma[J]. *Am J Surg Pathol* 2009; 33:278–88.
- [3] Verschraegen CF, Vasuratna A, Edwards C, et al. Clinicopathologic analysis of mullerian adenosarcoma: the MD Anderson Cancer Center experience[J]. *Oncol Rep* 1998; 5:939–44.
- [4] Jones MW, Lefkowitz M. Adenosarcoma of the uterine cervix: a clinicopathological study of 12 cases[J]. *Int J Gynecol Pathol* 1995; 14:223–9.
- [5] Clement PB, Scully RE. Mullerian adenosarcoma of the uterus: a clinicopathologic analysis of 100 cases with a review of the literature[J]. *Hum Pathol* 1990; 21:363–81.
- [6] Michener CM, Simon NL. Ovarian conservation in a woman of reproductive age with müllerian adenosarcoma[J]. *Gynecol Oncol* 2001; 83: 424–7.
- [7] Zaloudek CJ, Norris HJ. Adenofibroma and adenosarcoma of the uterus: a clinicopathologic study of 35 cases[J]. *Cancer* 1981; 48:354–66.
- [8] Manoharan M, Azmi MA, Soosay G, et al. Mullerian adenosarcoma of uterine cervix: report of three cases and review of literature[J]. *Gynecol Oncol* 2007; 105:256–60.
- [9] Kaku T, Silverberg SG, Major FJ, et al. Adenosarcoma of the uterus: a Gynecologic Oncology Group clinicopathologic study of 31 cases[J]. *Int J Gynecol Pathol* 1992; 11:75–88.