



# Synchronous duodenal neuroendocrine neoplasm and congenital factor XIII deficiency: case report and review of the literature

Lei Shen<sup>1#</sup>, Lu Kong<sup>2#</sup>, Qi Zhuo<sup>3</sup>, Roberta Elisa Rossi<sup>4</sup>, Renata D'Alpino Peixoto<sup>5</sup>, Nikolaos Tsoukalas<sup>6</sup>, Xiaomei Zhang<sup>1</sup>, Xinye Jin<sup>7</sup>

<sup>1</sup>Department of Gastroenterology, the First Medical Center of Chinese PLA General Hospital, Beijing, China; <sup>2</sup>Department of Patient Management, the Fourth Medical Center of Chinese PLA General Hospital, Beijing, China; <sup>3</sup>Department of Orthopaedics, the Fourth Medical Center of Chinese PLA General Hospital, Beijing, China; <sup>4</sup>Gastroenterology and Endoscopy Unit, Humanitas Clinical and Research Center IRCCS, Rozzano, Milan, Italy; <sup>5</sup>Centro Paulista de Oncologia (Grupo Oncoclínicas), São Paulo, Brazil; <sup>6</sup>Department of Oncology, 401 General Military Hospital of Athens, Athens, Greece; <sup>7</sup>Department of Nephrology, Department of Endocrinology, Hainan Hospital of Chinese PLA General Hospital, the Hainan Academician Team Innovation Center, Sanya, China

<sup>#</sup>These authors contributed equally to this work.

*Correspondence to:* Xiaomei Zhang. Department of Gastroenterology, the First Medical Center of Chinese PLA General Hospital, Beijing, China. Email: 531457866@qq.com; Xinye Jin. Department of Nephrology, Department of Endocrinology, Hainan Hospital of Chinese PLA General Hospital, the Hainan Academician Team Innovation Center, Sanya, China. Email: jinxinye301@163.com.

**Background:** Neuroendocrine neoplasms (NENs) are uncommon, with duodenal NENs (dNENs) being particularly rare in clinical practice. Congenital factor XIII deficiency (FXIID) is also an extremely rare hematological disease in which poor wound healing may occur due to coagulopathy. The concurrent occurrence of these two rare diseases has not been reported before, which increases the difficulty of diagnosis and treatment. This is the first report of dNEN concomitant with Congenital FXIID, which can present as a reference for clinicians who may encounter similar situations in the future.

**Case Description:** We report a 33-year-old woman with bleeding diathesis since childhood who complained of digestive tract bleeding for 7 years. She was finally diagnosed as duodenal neuroendocrine neoplasm combined with congenital factor XIII deficiency. The patient underwent surgery, and pathological findings confirmed neuroendocrine tumor. After surgery she received cryoprecipitate and fresh frozen plasma (FFP) therapy. No tumor recurrence has been observed nor recurrence of digestive tract bleeding during the 2-year follow-up.

**Conclusions:** Our report suggests when gastrointestinal bleeding is difficult to explain, more general examinations in addition to gastroscopy should be performed. In situations where digestive tract bleeding cannot be fully explained by a single disease, the possibility of concomitant disease, such as hematological disorders, should be considered to avoid the missed diagnosis of rare co-morbidities.

**Keywords:** Duodenal neuroendocrine tumor (dNEN); bleeding disorders; factor XIII deficiency (FXIID); pancreaticoduodenectomy (PD); case report

Submitted May 17, 2022. Accepted for publication Aug 05, 2022.

doi: 10.21037/atm-22-3628

View this article at: <https://dx.doi.org/10.21037/atm-22-3628>

## Introduction

Neuroendocrine neoplasms (NENs) are uncommon, with duodenal NENs (dNENs) being a rare in clinical practice as they represent up to 3% of all duodenal tumors (1). According to whether secrete hormones NENs can be

divided into functional and non-functional, the non-functional majority, non-functional NENs mainly for the tumor oppression causing symptoms. Non-functional dNENs can present as obstruction, chronic abdominal pain, abdominal distention, diarrhea, abdominal mass

and obstructive jaundice, or as asymptomatic. The manifestations of dNENs are diverse, and patients may exhibit non-specific symptoms or a lack of symptoms depending on tumor location, which makes the diagnosis challenging. In the latest guideline, treatment for dNENs is similar to gastric/pancreatic NENs (1). However, the unique characteristic of clinical manifestation for dNENs is still unknown (2).

Factor XIII (FXIII) circulates in blood as plasmatic factor and acts at the end step of the classic coagulation cascade; it plays a key role in tissue remodeling and wound healing (3). FXIIID deficiency (FXIIID), a serious bleeding disorder, is an extremely rare condition that can be congenital or acquired. Congenital FXIIID affects approximately 1–3 per million individuals and has a higher prevalence in areas where consanguineous marriages are common (4). Spontaneous hematoma, mucosal hemorrhage and poor wound healing are common consequence of the disease, which is life-threatening in severe cases. Early diagnosis followed by long-term prophylactic treatment reduces the rate of morbidity and mortality remarkably (5).

In the present paper, we report a case of a young woman with bleeding diathesis since childhood who had sought medical attention for digestive tract bleeding to no avail and concomitant incidental diagnosis of a dNEN. This is the first report of dNEN concomitant with Congenital FXIIID. We submit this case as a reference for clinicians who may encounter similar situations in the future, to prevent similar cases from being treated improperly due to delayed diagnosis. We present the following article in accordance with the CARE reporting checklist (available at <https://atm.amegroups.com/article/view/10.21037/atm-22-3628/rc>).

## Case presentation

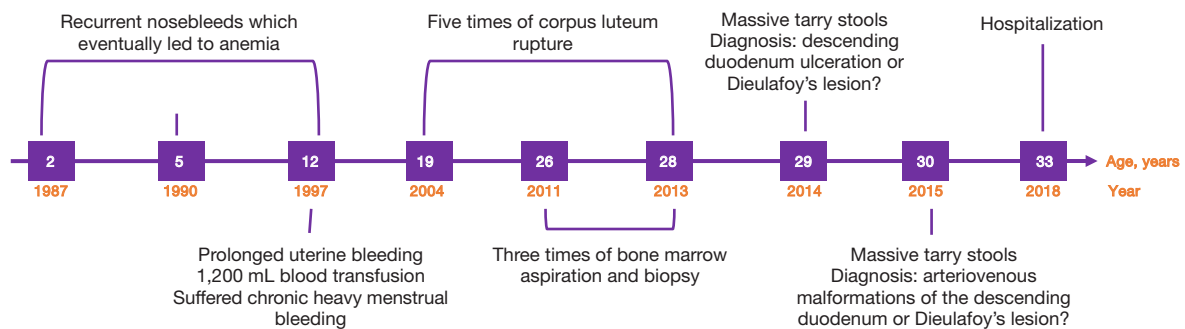
### *Past medical history and examinations*

The patient, a 33-year-old woman without family history, had bleeding diathesis since childhood with consequent recurrent gastrointestinal bleeding for 7 years (*Figure 1*). Between 2 and 12 years of age, she suffered recurrent nosebleeds which eventually led to anemia, and at the age of 5 years, received a transfusion of 200 mL of blood for anemia. During her first menstrual period at the age of 12 years, she experienced prolonged uterine bleeding which was treated by dilation and curettage and a transfusion of 1,200 mL of blood. Thereafter, she suffered chronic heavy menstrual bleeding. Between 19 and 28 years of age, she

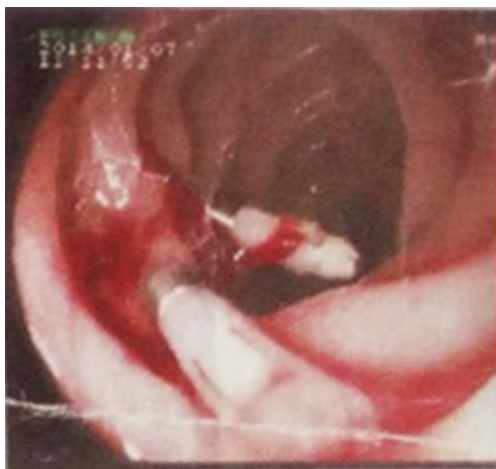
had five occurrences of corpus luteum rupture treated twice by laparoscopy and three times conservatively. To identify the underlying mechanism of chronic recurrent anemia and bleeding diathesis, she underwent bone marrow aspiration and biopsy three times between 26 to 28 years of age, the results of which all indicated active bone marrow proliferation. Iron-deficiency anemia was then suspected, and long-term iron supplementation was adopted for treatment. The patient's hemoglobin level reached as low as 38 g/L when most severe with black stools, which, however, were overlooked by the patient and doctors due to the use of iron supplements. At the age of 29 years, she had a sudden onset of massive tarry stools and was admitted to the emergency department where a gastroscopy was performed for the first time and revealed a 0.4 cm × 0.4 cm ring-shaped ulcer that oozed blood on the surface in the descending duodenum. According to the patient's recollection, although she could not remember the accurate hemoglobin level of that time, she had severe anemia. Diagnoses of descending duodenum ulceration or Dieulafoy's lesion were considered by the attending gastroenterologist as causes of bleeding, and titanium clips were used for hemostasis (*Figure 2*). Biopsy was not performed considering the active phase of bleeding. Helicobacter Pylori test was negative. After the patient's condition improved, she was discharged and continued taking proton pump inhibitors afterward, but the stools remained black even if with normal steady hemoglobin levels. At the age of 30 years old, a massive digestive tract bleeding reoccurred, and a second gastroscopy showed erosive lesions in the descending duodenum as the hemorrhagic foci. Again, arteriovenous malformations of the descending duodenum or Dieulafoy's lesion were considered by the attending doctor as causes of bleeding, and laurumacrogol injection was administered for the treatment of angiosclerosis. Despite temporary improvement of bleeding after treatment, black stools soon recurred and caused severe anemia, which brought the patient to the Department of Gastroenterology of Chinese PLA General Hospital in August 2018.

### *Post-admission examinations*

Upon admission, the past medical history of the patient was reviewed. She went through a series of tests and treatments (*Figure 3*). Gastroscopic re-examination indicated the presence of two lesions in the duodenal bulb and descending duodenum which measured approximately 2 cm × 3 cm (*Figure 4A*) and 1 cm × 1 cm (*Figure 4B*), respectively, and



**Figure 1** Timeline of disease history.



**Figure 2** Gastrosopic views of duodenal lesions. Image from gastroscopy performed in 2014: fresh blood traces could be seen in the post-bulbar mucosa of the duodenum; active oozing of blood could be observed across the papilla of the descending duodenum. Rinsing revealed the presence of a 0.4 cm × 0.4 cm ring-shaped ulcer that oozed blood on the surface, and local ulcer closure was performed with four titanium clips.

manifested irregular lumpy protuberances, rough surfaces, and erosion. Considering the recent bleeding, no biopsy was taken.

Further examination by endoscopic ultrasonography (EUS) showed uneven hypoechoic masses, one at the duodenal bulb-descending duodenum junction and the other at the descending duodenum. The lesions were contiguous with the duodenal wall (*Figure 5A,5B*). A relatively hypoechoic mass with a length of approximately 3.4 cm was also found in the uncinata process of the pancreatic head (*Figure 5C*).

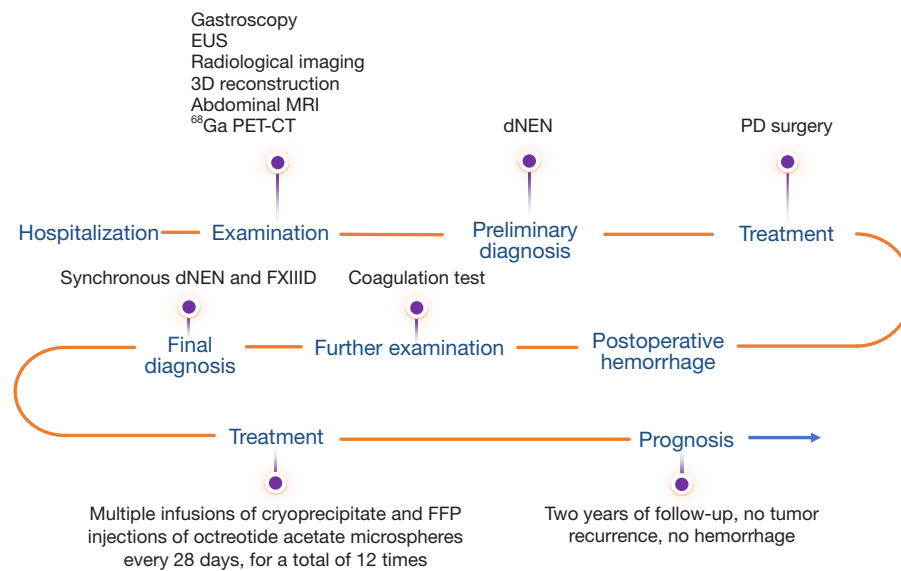
Taken into account the possibility that the lesion in the descending duodenum might be neoplastic, further

imaging examinations were performed, the results of which confirmed our hypothesis. Interventional radiological imaging of the abdominal aorta (*Figure 6A*), three-dimensional reconstruction of abdominal vasculature (*Figure 6B*), abdominal magnetic resonance imaging (MRI) (*Figure 6C,6D*), and positron emission tomography (PET)/computed tomography (CT) with <sup>68</sup>Ga-DOTA-peptides (*Figure 6E,6F*) all pointed to the presence of a neoplastic lesion suggestive of a NEN considered the positivity at the Gallium-68 scan, whereas vascular malformations were excluded. Biopsy was not performed neither because of the repeated massive bleeding recently.

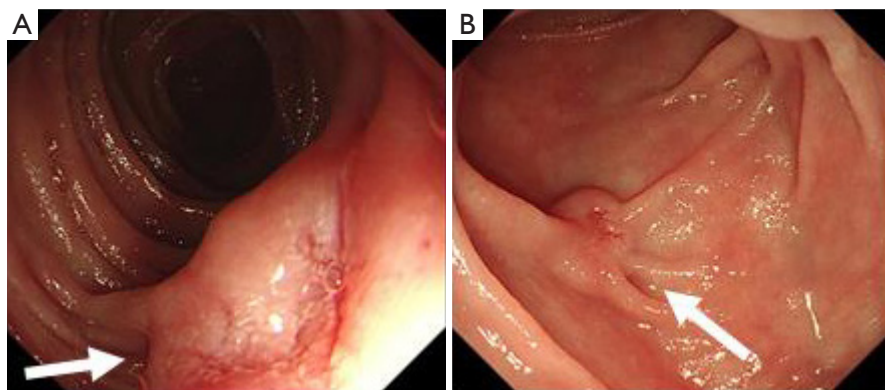
### Treatment

#### Surgery and pathological examination

The patient was transferred to the Department of Hepatobiliary Surgery and underwent pancreaticoduodenectomy (PD) on September 2, 2018, during which the uncinata process of the pancreatic head, gallbladder, common bile duct, distal stomach, duodenum, pancreatic head, and lymph nodes were resected. On September 5, 2018, the patient received interventional embolization of the left gastric artery after developing hematemesis. On September 11, 2018, after another episode of hematemesis, emergency superior mesenteric artery branch embolization was performed with no benefit on the bleeding. On September 14, 2018, the patient underwent emergency exploratory laparotomy, during which oozing of blood from the gastrointestinal anastomosis was observed and treated by re-suturing. However, hematemesis occurred again on September 15, 2018, resulting in hypotensive shock with hemoglobin level as low as 50 g/L. Interventional embolization was performed for the third time, with the superior mesenteric artery branches selectively embolized. According to the opinion of hematologist, the coagulation examination was performed



**Figure 3** Diagnosis and treatment of the patient after hospitalization. EUS, endoscopic ultrasonography; 3D Reconstruction, three-dimensional reconstruction; MRI, magnetic resonance imaging; <sup>68</sup>Ga PET/CT, positron emission tomography/computed tomography with <sup>68</sup>Ga-DOTA-peptides; dNEN, duodenal neuroendocrine neoplasm; PD, pancreaticoduodenectomy; FXIIID, congenital factor XIII deficiency; FFP, fresh frozen plasma.



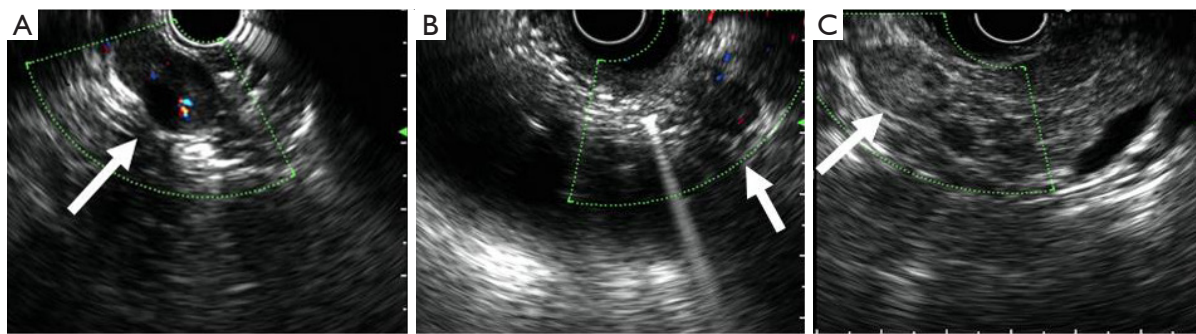
**Figure 4** Gastroscopic views of duodenal lesions. (A) image from gastroscopy performed in 2018: a 2 cm × 3 cm lamellar protruding lesion (white arrow) with rough surfaces and erosion at the duodenal bulb-descending duodenum; (B) image from gastroscopy performed in 2018: a 1 cm × 1 cm lamellar protruding lesion (white arrow) with rough surfaces and erosion in the descending duodenum.

Plasma FXIII: 24.7%, with normal prothrombin time (PT), activated partial thromboplastin time (APTT), fibrinogen level, and platelet count. Considering the patient's bleeding diathesis from childhood, after a multidisciplinary consultation, congenital FXIIID was believed to be the underlying disorder. The bleeding eventually stopped after multiple infusions of cryoprecipitate and fresh frozen plasma (FFP), because FXIII concentrate were not available in the hospital.

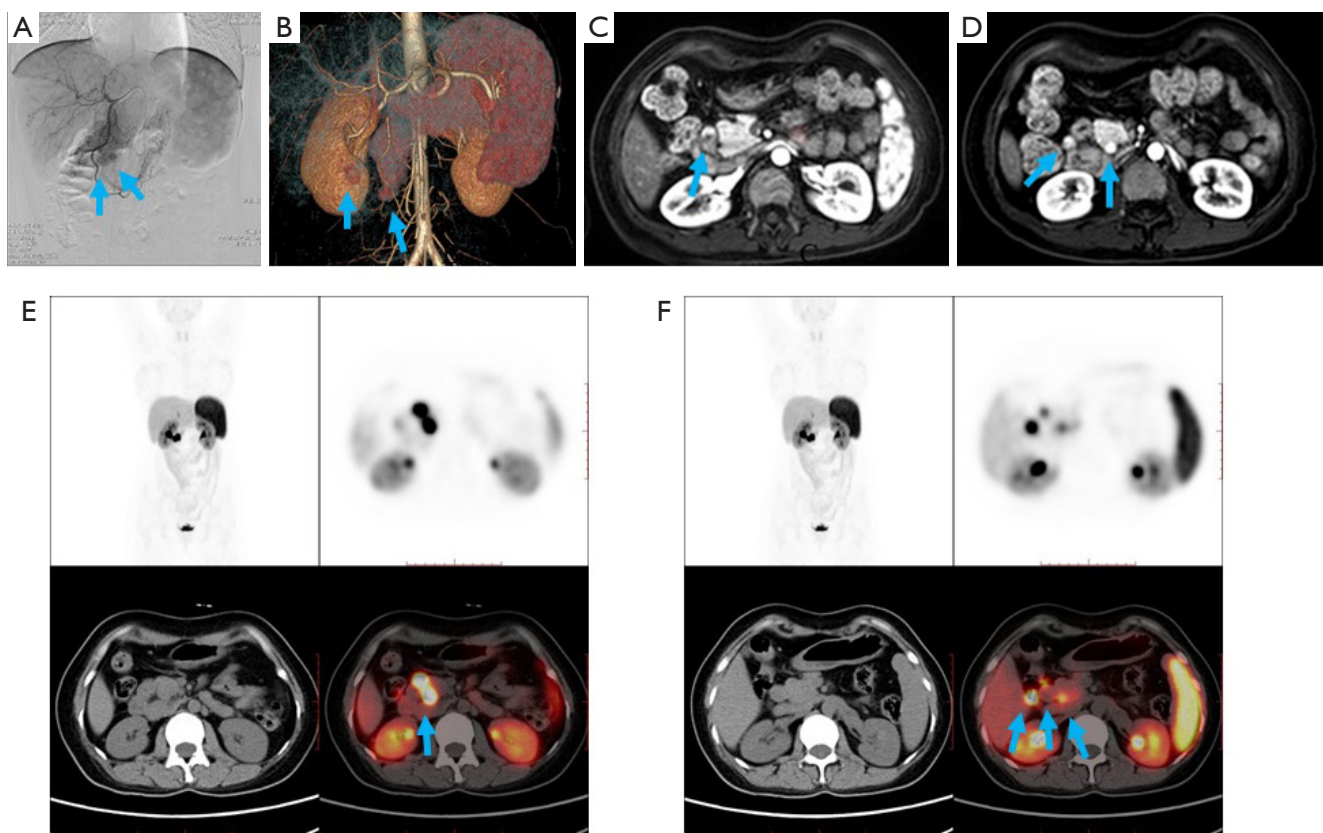
#### Clinical outcomes

Postoperative pathological examination revealed an intermediate-grade (G2) dNEN measuring 1.5 cm × 1.4 cm × 0.5 cm. The tumor cells exhibited an infiltrative growth pattern in the mucosa, submucosa, and intramural region, but did not invade the gastric wall, common bile duct wall, or pancreas. Resection margins were free, while metastases were present in the peripancreatic lymph nodes (3/3) and absent in the perigastric lymph nodes (0/2). Results





**Figure 5** Endoscopic ultrasonographic images of the lesion. (A) 18.8 mm × 12.2 mm uneven hypoechoic mass (white arrow) at the duodenal bulb-descending duodenum junction; (B) 13.1 mm × 7.6 mm uneven hypoechoic mass (white arrow) in the descending duodenum; (C) a hypoechoic mass (white arrow) with a length of 34.3 mm and no blood flow signal in the uncinate process of the pancreatic head.



**Figure 6** Imageological examination of the lesion. (A) Radiological imaging revealed thickening and disorderly paths of gastroduodenal artery branches, with multiple patch-like contrast agent stains (blue arrows); (B) three-dimensional reconstruction of abdominal vasculature; arrows indicate two abnormally enhanced nodes (blue arrows) measuring 13 mm × 11 mm and 7 mm × 12 mm on the outer wall of the descending duodenum, with clear boundaries and seemingly connected to the superior mesenteric artery branches; (C) abdominal MRI: a lesion (blue arrow) fed by multiple vessels in the outer wall of the descending duodenum; (D) abdominal MRI: lesions (blue arrows) fed by multiple vessels in the uncinate process of the pancreas; (E) PET-CT using a  $^{68}\text{Ga}$ -labeled tracer: Multiple focal hypermetabolic lesions (blue arrow) in the descending duodenum,  $^{68}\text{Ga}$ -labelled PET-positive; (F)  $^{68}\text{Ga}$  PET-CT using a  $^{68}\text{Ga}$ -labeled tracer: Multiple focal hypermetabolic lesions (blue arrows) in the pancreatic head region,  $^{68}\text{Ga}$ -labelled PET-positive. MRI, magnetic resonance imaging; PET, positron emission tomography; CT, computed tomography.

**Table 1** Clinical characteristics in two patients with postoperative complications following PD due to FXIIID

Case No.	Year	First author	Country	Age	Sex	Diagnosis	Postoperative complication	Treatment	Outcomes
1	2013	Nishino H	Japan	78	Male	Gastric cancer	Pancreatic fistula	FXIII	Stable
2	2008	Weber CF	Germany	NA	NA	NA	Diffuse bleeding	1,250 IU of FXIII concentrate	Stable

PD, pancreaticoduodenectomy; FXIIID, factor XIII deficiency; NA, not available.

of immunohistochemical testing were as follows: Ki-67 (+3%), Syn (+), CgA (focal weak +), CD56 (+), and CK (+). Considering the presence of 3 peripancreatic lymph node metastases, the future trend of metastasis cannot be completely predicted. Therefore, as per multidisciplinary discussion, despite a clear-cut recommendation from available guidelines, somatostatin analogs were started after radical surgery. Two months postoperatively, the patient continued to receive intramuscular injections of octreotide acetate microspheres once every 28 days, and a total of 12 injections were administered. After two years of follow-up, no tumor recurrence has been observed nor recurrence of digestive tract bleeding.

### Literature review

Literature searches were conducted in PubMed, Medline, EMBASE, Wanfang (old.g.wanfangdata.com.cn), and China National Knowledge Infrastructure (www.cnki.net) databases using the following search terms: (neuroendocrine tumor[Title/Abstract]) OR (NEN[Title/Abstract]) OR (neuroendocrine neoplasms[Title/Abstract]) OR (neuroendocrine carcinoma[Title/Abstract]) AND (factor XIII deficiency), (Whipple's operation) OR (Roux-en-Y reconstruction) OR (pancreaticoduodenectomy) AND (factor XIII). Information including the first author, year of study, country, age, sex, diagnosis, postoperative complications, treatment, and outcomes was extracted from relevant papers.

### General characteristics

Literature searches revealed no published case reports of concomitant dNEN and congenital FXIIID occurrence, making the present case the first of its kind to our knowledge. Two cases of poor postoperative recovery following PD due to FXIIID were found in the literature: (I) Japanese researchers Nishino *et al.* (6) reported the case of a 78-year-old man with early gastric cancer who underwent

total gastrectomy with Roux-en-Y reconstruction. The patient developed pancreatic fistula postoperatively due to FXIIID, and fistula closure was achieved after the administration of FXIII for 5 days; (II) German researchers Weber *et al.* (7) reported a case of diffuse bleeding after Whipple's operation (PD) which ceased after FXIII replacement therapy. A postoperative investigation confirmed the presence of FXIIID (52%) (Table 1).

All procedures performed in this study were in accordance with the ethical standards of the institutional and/or national research committee(s) and with the Declaration of Helsinki (as revised in 2013). Written informed consent was obtained from the patient for publication of this case report and accompanying images. A copy of the written consent is available for review by the editorial office of this journal.

### Discussion

NENs are a rare disease accounting for approximately 2% of all malignancies, and have an incidence of <1/200,000 in the United States (8). There is a continuous increase in the number of NEN diagnoses around the world (9) and a current lack of statistical data on their incidence in China. NENs most commonly occur in the gastrointestinal tract (48%), lungs (25%), and pancreas (9%), but may also occur in many other organs such as the breast, prostate, thymus, and skin (10). In particular, those located in duodenum account for approximately 3% of gastroenteropancreatic NENs (11).

They include functioning and non-functioning forms. Non-functioning dNENs do not cause clinical manifestations, but may produce symptoms due to obstruction and bleeding from local space occupation effects during the later stages. Therefore, the early discovery of dNENs might be challenging. The most commonly presented symptoms are: pain, jaundice, nausea/vomiting, bleeding, anemia, diarrhea and duodenal obstruction (2).

Gastroscopy/duodenoscopy are the methods of choice for the diagnosis of dNENs. However, missed diagnoses may

occur with endoscopy when the NEN beneath the mucosa has not yet caused protrusions on the mucosal surface or invaded the duodenal mucosa. In addition, biopsy specimens are usually too small to provide a definitive histopathological diagnosis. While EUS may enhance the diagnostic rate and diagnostic accuracy, this is largely determined by operator experience. Conventional imaging (i.e., ultrasound, CT, MRI) and somatostatin receptor scintigraphy (SRS) (especially PET/CT  $^{68}\text{Ga}$ -DOTA-peptides) should be performed to fully assess the extent of the disease and detect any possible distant metastases; still, misdiagnosis is possible due to the small diameter of dNEN (2). In our case, endoscopic biopsy was not performed due to bleeding, so the cause was not found despite multiple gastroscopic examinations was taken. The diagnosis of dNEN was confirmed finally after a variety of imaging examination methods.

In terms of treatment, endoscopic resection is gradually taking the place of surgery, despite there is no uniform standard in the guideline. However, dNENs have a high metastasis ratio up to 55%, even at a small size, which lead to a variable prognosis (12). Therefore, because of the potential aggressive behavior, and taken into account that dNENs tend to spread or probably even rise to the submucosal layer and that the duodenal wall is thinner than the gastric wall, for lesions >2 cm and/or when dNENs invade the submucosal layer surgical resection is superior to endoscopic treatment. Furthermore, considered the poor detection rate of conventional imaging for loco-regional nodes and micrometastases, caution should be applied when endoscopy or local surgical excision are considered and EUS should be always performed in the preoperative setting for a more accurate local staging (13). In G1/G2 dNENs patients with metastatic/unresectable tumors, systemic therapy [including somatostatin analogs (SSA), targeted therapy, peptide receptor radionuclide therapy (PRRT) or chemotherapy] is the treatment of choice, as well as for more advanced forms (14). In this case, the patient benefited from surgical treatment, which effectively removed the tumor, did not recur during follow-up, and was free from gastrointestinal bleeding.

Due to the rarity, FXIID is not routinely considered by clinicians in the presence of hemorrhagic disease at the begin time. Classical coagulation tests [e.g., PT, APTT and thrombin time (TT)] cannot detect the action of FXIII due to fibrin is already polymerized at the final step of coagulation cascade (15).

Severe congenital FXIID manifests early in life and

can occur in neonates and present as umbilical stump hemorrhage. Intradermal, intramuscular and intracranial hemorrhages are also the most common clinical manifestations of congenital FXIII deficiency (16). A systematic review of literature on congenital FXIID in women indicated ovulation bleeding was reported in 8% in this specific population. FXIII-deficient women also experience significant bleeding complications, such as menorrhagia and ovulation bleeding (17). Our patient had bleeding diathesis from childhood, and experienced multiple severe uterine bleeding and corpus luteum rupture, which is consistent with this description.

FXIII deficiency should be suspected while the patient has normal standard coagulation test, reduced maximum clot firmness (MCF), and bleeding cannot be explained by any other cause, with a compatible medical history (3). Because the standard coagulation test was normal, the coagulation dysfunction of our patient was not considered at the first time, resulting in the delay of diagnosis.

The mainstay for the management of FXIID remains the administration of FFP in a dose of 10 mL/kg every 4–6 weeks and cryoprecipitate in a dose of one bag/10 kg at the same intervals as FFP, because those possible to the only treatment available for many districts of the world sometimes (18). In recent 10 years, replacing FFP and cryoprecipitate, prophylaxis with FXIII Cluvot<sup>®</sup> concentrate or Corifact<sup>®</sup> (CSLBehring, Melbourne, Australia) and NovoThirteen<sup>®</sup> recombinant FXIII Subunit A concentrate (rFXIII-A2 concentrate) or Tretten<sup>®</sup> (Novo Nordisk, Bagsvaerd, Denmark) gained popularity gradually. The dosage of FXIII concentrate is 10–26 IU/kg every 4–6 weeks, depending on the patient's clinical situation, while the replace therapy of rFXIII-A2 concentrate is 35 IU/kg per month (3). Although definitive diagnosis is sometimes a challenge and concentrates are not available, the use of FFP and cryoprecipitate is still important should not be delay. The therapeutic results of this patient confirmed the effectiveness of cryoprecipitate and FFP on FXIID.

The concurrent occurrence of dNEN and congenital FXIID in one patient is extremely rare, both of which can cause bleeding, leading to an easy misdiagnosis or missed diagnosis and poor hemostatic effects as a result. Systematic searches of the literature revealed no published case reports of concomitant dNEN and congenital FXIID, making the present case the first of its kind. It is unclear whether such concurrent occurrence of a rare digestive disease and a rare hematological disease was purely coincidental, or homology may exist between the two conditions. Our patient sought

medical attention for digestive tract bleeding, and both endoscopy and imaging indicated the presence of neoplastic lesions in the duodenal and peripancreatic regions. However, recurrent digestive tract bleeding persisted after surgical tumor resection, and both the surgery and interventional embolization resulted in poor hemostatic effects. Upon further investigation, we found the postoperative bleeding was primarily related to FXIID, and digestive tract bleeding ceased after the administration of FXIII replacement therapy. Therefore, FXIID was deemed as the main cause of digestive tract bleeding.

We may be the first to report a case with concurrent occurrence of dNEN and congenital FXIID. The message here is that in situations where digestive tract bleeding cannot be explained by a single disease, the possibility of co-morbidities, such as hematological disorders, should be considered to avoid missed diagnoses or misdiagnosis of obscure diseases.

#### *Questions to be further discussed and considered*

(I) Was it a coincidence that the patient had recurrent gastrointestinal bleeding for 7 years, but the bleeding stopped during pregnancy, or did hormonal fluctuations during pregnancy alleviate her bleeding symptoms?

Nikolaos Tsoukalas: Maybe it was coincidence but also some hormonal fluctuations during pregnancy may influence her bleeding symptoms.

(II) Is it a coincidence that two rare diseases appeared in one patient at the same time, or is there some as-yet-undiscovered link, such as a genetic deficiency?

Roberta Elisa Rossi: Duodenal NENs originate from aberrant neuroendocrine duodenal cell proliferation; in this microenvironment, complex interactions take place. The recognition of the molecular mechanisms participating in neoplastic transformation could increase the challenging management of this disease. However, at present, little is known about the risk factors of these neoplasms (19).

To my knowledge there is no a genetic background of dNEN occurrence, thus the concomitant occurrence might be purely coincidental.

Renata D'Alpino Peixoto: According to a French case series of pregnant women with factor XIII deficiency, miscarriage was the most common manifestation, while no bleeding happened when factor XIII was supplemented. I'm not aware where

the patient had received factor XIII supplementation during pregnancy.

It is highly unlikely that a genetic alteration justifies both diseases. So far, no relationship has been found between cancer risk and factor XIII deficiency.

Nikolaos Tsoukalas: Possibly it is a coincidence but a yet-undiscovered link could be a rare possibility as well.

(III) The bleeding eventually stopped after multiple infusions of cryoprecipitate and FFP. Is there a better treatment option to help patients prevent recurrence of bleeding?

Renata D'Alpino Peixoto: Other treatments include factor XIII concentrates and recombinant factor XIII, which are sometimes available as treatment options depending on the jurisdiction (20). In some cases, immunosuppressive therapy may also be warranted for some cases of acquired factor XIII deficiency (21).

Nikolaos Tsoukalas: This is a challenging clinical condition. Maybe somatostatin analogs could help as well.

#### **Acknowledgments**

The authors appreciate the academic support from the AME Gastroenterology Collaborative Group.

*Funding:* This study was funded by the Specialized Scientific Program of the Hainan Province Academician Innovation Platform (YSPTZX202026) and the Scientific and Technological Innovation Program of Sanya (2016YW31).

#### **Footnote**

*Reporting Checklist:* The authors have completed the CARE reporting checklist. Available at <https://atm.amegroups.com/article/view/10.21037/atm-22-3628/rc>

*Conflicts of Interest:* All authors have completed the ICMJE uniform disclosure form (available at <https://atm.amegroups.com/article/view/10.21037/atm-22-3628/coif>). The authors have no conflicts of interest to declare.

*Ethical Statement:* The authors are accountable for all aspects of the work in ensuring that questions related to the accuracy or integrity of any part of the work are appropriately investigated and resolved. All procedures performed in this study were in accordance with the ethical



standards of the institutional and/or national research committee(s) and with the Declaration of Helsinki (as revised in 2013). Written informed consent was obtained from the patient for publication of this case report and accompanying images. A copy of the written consent is available for review by the editorial office of this journal.

*Open Access Statement:* This is an Open Access article distributed in accordance with the Creative Commons Attribution-NonCommercial-NoDerivs 4.0 International License (CC BY-NC-ND 4.0), which permits the non-commercial replication and distribution of the article with the strict proviso that no changes or edits are made and the original work is properly cited (including links to both the formal publication through the relevant DOI and the license). See: <https://creativecommons.org/licenses/by-nc-nd/4.0/>.

## References

- Delle Fave G, O'Toole D, Sundin A, et al. ENETS Consensus Guidelines Update for Gastroduodenal Neuroendocrine Neoplasms. *Neuroendocrinology* 2016;103:119-24.
- Rossi RE, Rausa E, Cavalcoli F, et al. Duodenal neuroendocrine neoplasms: a still poorly recognized clinical entity. *Scand J Gastroenterol* 2018;53:835-42.
- Guilbert P, Asmis L, Cortina V, et al. Factor XIII and surgical bleeding. *Minerva Anestesiologica* 2022;88:156-65.
- Naderi M, Haghpanah S, Miri-Aliabad G, et al. A large case series on surgical outcomes in congenital factor XIII deficiency patients in Iran. *J Thromb Haemost* 2017;15:2300-5.
- Dorgalaleh A, Naderi M, Shamsizadeh M. Morbidity and mortality in a large number of Iranian patients with severe congenital factor XIII deficiency. *Ann Hematol* 2016;95:451-5.
- Nishino H, Kojima K, Oshima H, et al. A case of pancreatic and duodenal fistula after total gastrectomy successfully treated with coagulation factor XIII. *Gan To Kagaku Ryoho* 2013;40:2304-6.
- Weber CF, Jambor C, Marquardt M, et al. Thrombelastometric detection of factor XIII deficiency. *Anaesthesist* 2008;57:487-90.
- Boyce M, Thomsen L. Gastric neuroendocrine tumors: prevalence in Europe, USA, and Japan, and rationale for treatment with a gastrin/CCK2 receptor antagonist. *Scand J Gastroenterol* 2015;50:550-9.
- Das S, Dasari A. Epidemiology, Incidence, and Prevalence of Neuroendocrine Neoplasms: Are There Global Differences? *Curr Oncol Rep* 2021;23:43.
- Yao JC, Hassan M, Phan A, et al. One hundred years after "carcinoid": epidemiology of and prognostic factors for neuroendocrine tumors in 35,825 cases in the United States. *J Clin Oncol* 2008;26:3063-72.
- Sandvik OM, Søreide K, Gudlaugsson E, et al. Epidemiology and classification of gastroenteropancreatic neuroendocrine neoplasms using current coding criteria. *Br J Surg* 2016;103:226-32.
- Massironi S, Campana D, Partelli S, et al. Heterogeneity of Duodenal Neuroendocrine Tumors: An Italian Multi-center Experience. *Ann Surg Oncol* 2018;25:3200-6.
- Rossi RE, Milanetto AC, Andreasi V, et al. Risk of preoperative understaging of duodenal neuroendocrine neoplasms: a plea for caution in the treatment strategy. *J Endocrinol Invest* 2021;44:2227-34.
- Kaliszewski K, Ludwig M, Greniuk M, et al. Advances in the Diagnosis and Therapeutic Management of Gastroenteropancreatic Neuroendocrine Neoplasms (GEP-NENs). *Cancers (Basel)* 2022;14:2028.
- Schroeder V. Laboratory Assessment of Coagulation Factor XIII. *Hamostaseologie* 2020;40:467-71.
- Bouttefroy S, Meunier S, Milien V, et al. Congenital factor XIII deficiency: comprehensive overview of the FranceCoag cohort. *Br J Haematol* 2020;188:317-20.
- Ichinose A. Hemorrhagic acquired factor XIII (13) deficiency and acquired hemorrhaphilia 13 revisited. *Semin Thromb Hemost* 2011;37:382-8.
- Dorgalaleh A, Rashidpanah J. Blood coagulation factor XIII and factor XIII deficiency. *Blood Rev* 2016;30:461-75.
- Massironi S, Rossi RE, Milanetto AC, et al. Duodenal Gastric Metaplasia and Duodenal Neuroendocrine Neoplasms: More Than a Simple Coincidence? *J Clin Med* 2022;11:2658.
- Weise M, Bielsky MC, De Smet K, et al. Biosimilars: what clinicians should know. *Blood* 2012;120:5111-7.
- Farzam K. A Rare Case of Factor XIII Deficiency in the Setting of Cancer Immunotherapy. *Cureus* 2021;13:e15299.

(English Language Editor: B. Draper)

**Cite this article as:** Shen L, Kong L, Zhuo Q, Rossi RE, Peixoto RD, Tsoukalas N, Zhang X, Jin X. Synchronous duodenal neuroendocrine neoplasm and congenital factor XIII deficiency: case report and review of the literature. *Ann Transl Med* 2022;10(16):913. doi: 10.21037/atm-22-3628