



Evaluation of the safety and effectiveness of neoadjuvant combined chemoimmunotherapy in the treatment of locally advanced esophageal squamous cell carcinoma: a retrospective single-arm cohort study

Pinghui Xia^{1#}, Pan Li^{2#}, Simeng Wu³, Yiqing Wang¹, Peng Ye¹, Chong Zhang¹, Jian Hu¹, Biniam Kidane⁴, Savvas Lampridis⁵, Jeffrey B. Velotta⁶, Connor J. Wakefield⁷, Linhai Zhu¹, Luming Wang¹

¹Department of Thoracic Surgery, The First Affiliated Hospital, Zhejiang University School of Medicine, Hangzhou, China; ²Zhejiang Provincial Key Laboratory of Pancreatic Disease, The First Affiliated Hospital, Zhejiang University School of Medicine, Hangzhou, China; ³Department of Cardiothoracic Surgery, The Shaoxing Second Hospital, Shaoxing, China; ⁴Section of Thoracic Surgery, University of Manitoba, Winnipeg, MB, Canada; ⁵Department of Thoracic Surgery, Guy's Hospital, Guy's and St Thomas' NHS Foundation Trust, London, UK; ⁶Department of Thoracic Surgery, Kaiser Permanente Oakland Medical Center, Kaiser Permanente Northern California, Oakland, CA, USA; ⁷Department of Internal Medicine, Brooke Army Medical Center, Fort Sam Houston, TX, USA

Contributions: (I) Conception and design: P Xia, P Li, L Zhu, L Wang; (II) Administrative support: J Hu, L Wang, L Zhu; (III) Provision of study materials or patients: P Xia, Y Wang, P Ye, C Zhang; (IV) Collection and assembly of data: P Li, L Zhu, S Wu; (V) Data analysis and interpretation: P Li, L Zhu, S Wu; (VI) Manuscript writing: All authors; (VII) Final approval of manuscript: All authors.

[#]These authors contributed equally to this work.

Correspondence to: Linhai Zhu, PhD; Luming Wang, PhD. Department of Thoracic Surgery, The First Affiliated Hospital, Zhejiang University School of Medicine, No. 79 Qingchun Road, Hangzhou 310003, China. Email: Linhai_zhu@zju.edu.cn; 1507144@zju.edu.cn.

Background: Transforming potentially resectable advanced esophageal squamous cell carcinoma (ESCC) into resectable ESCC through preoperative induction therapy is an important component of ESCC comprehensive treatment. Immune checkpoint inhibitor (ICI) therapy has been shown to have significant effects in the treatment of advanced ESCC, but its role in the neoadjuvant treatment of potentially resectable ESCC is unclear. This study aims to investigate the safety and effectiveness of camrelizumab combined with chemotherapy in the neoadjuvant treatment of ESCC.

Methods: We recruited consecutive patients with potentially resectable ESCC who received preoperative camrelizumab in combination with chemotherapy. Data including demographic data, clinicopathological characteristics, neoadjuvant treatment regimens, lesion changes observed by imaging, and surgical details were retrospectively collected through specially designed forms. Toxic effects of neoadjuvant therapy on hematology, gastrointestinal tract, liver, kidney, skin, and thyroid were also collected. Imaging assessments were performed every 1–2 treatment cycles. Follow-up is based on the patient's regular admission to the hospital for examination and treatment, at least 3 months after surgery.

Results: A total of 66 patients with locally advanced ESCC were included in this study, including 8 patients with stage II, 29 patients with stage III, and 29 patients with stage IVA. The objective response rate (ORR) of the neoadjuvant immunotherapy combined with chemotherapy was 75.76% (50/66), and no one developed disease progression. A total of 60 patients underwent surgery, and the R0 resection rate was 98.3% (59/60). The pathological complete remission (pCR) rate and the major pathological response (MPR) rate was 6.7% (4/60) and 20% (12/60), respectively. There were 14 cases of treatment-related adverse reactions >3, but no perioperative deaths occurred.

Conclusions: Neoadjuvant immunotherapy combined with chemotherapy followed by surgical resection may be an available treatment for patients with locally advanced ESCC.

Keywords: Esophageal squamous cell carcinoma (ESCC); locally advanced; neoadjuvant therapy; immunotherapy; camrelizumab

Submitted Jun 30, 2022. Accepted for publication Sep 08, 2022.

doi: 10.21037/atm-22-4268

View this article at: <https://dx.doi.org/10.21037/atm-22-4268>

Introduction

Esophageal cancer is the 6th leading cause of cancer related mortality worldwide and accounted for 1 of every 18 cancer-related deaths in 2020 (1). Esophageal cancer is mainly divided into 2 histologic subtypes; that is, esophageal squamous cell carcinoma (ESCC), and esophageal adenocarcinoma (2). Today, ESCC represents the major burden of esophageal cancer and is most common in Eastern Asia and Central Asia (3,4).

More than 80% of patients with esophageal cancer are diagnosed with middle to advanced stage when they first present (5). Among them, nearly half of the patients with esophageal cancer are diagnosed with locally advanced disease which require varying treatment regimens, including surgical resection and/or chemoradiation therapy (6,7). The radical resection of esophageal cancer, including esophagectomy and extensive lymph node dissection, is the standard surgical treatment for non-metastatic esophageal cancer (8). And adjuvant treatment has been demonstrated to reduce the postoperative recurrence of esophageal cancer (9). van Hagen *et al.* compared surgery after chemoradiotherapy to surgery alone in patients with esophageal cancer and found that preoperative chemoradiotherapy improved the survival of patients with potentially resectable esophageal cancer (10). The NEOCRTEC5010 study also showed that patients with locally advanced ESCCs who received neoadjuvant chemoradiotherapy (nCRT) plus surgery had better survival than those who received surgery alone (11). Currently, trimodality therapy involving neoadjuvant chemotherapy (nCT) or nCRT followed by esophagectomy and postoperative adjuvant therapy has become the preferred treatments for locally advanced ESCCs (12,13).

Immune checkpoint inhibitors (ICIs) have gradually become an indispensable part of the treatment of advanced esophageal cancer due to their remarkable therapeutic effects, and have also shown significant efficacy in adjuvant therapy for esophageal cancer (14). The ONO-4538-07 (15), CheckMate-032 (16), KEYNOTE-028 (17), and KEYNOTE-180 (18) studies revealed that the objective response rates (ORRs) of immunotherapy for advanced esophageal cancer were 17%, 12%, 30% and 9.9%, respectively. The KEYNOTE-181 (19) and ESCORT (20)

studies have shown that immunotherapy administered as a 2nd-line treatment significantly improved the overall survival (OS) of patients with advanced esophageal cancer compared to chemotherapy. Immunotherapy combined with chemotherapy has been studied by CheckMate 649 (21), KEYNOTE-590 (22), and ESCORT-1st (23) as the 1st-line treatment for advanced esophageal cancer, and was found to significantly improved OS compared to chemotherapy alone. CheckMate 577 study results show that nivolumab can significantly prolong disease-free survival (DFS) in adjuvant treatment of esophageal cancer after surgery (24). Based on the above clinical trial results, we speculate that ICIs combined with chemotherapy will also have reliable safety and efficacy in the neoadjuvant treatment of ESCC. However, the role of immunotherapy in the neoadjuvant treatment of ESCCs has not been reported. Therefore, this study attempted to explore the role of neoadjuvant ICIs combined chemotherapy in the treatment of ESCC.

As one of the PD-1 inhibitors, camrelizumab has shown stable anti-cancer effects and is also the most commonly used immunotherapy drug in our department (25). In this study, we aimed to investigate the safety and effectiveness of camrelizumab combined with chemotherapy as a neoadjuvant regimen in the treatment of locally advanced ESCC. We present the following article in accordance with the TREND reporting checklist (available at <https://atm.amegroups.com/article/view/10.21037/atm-22-4268/rc>).

Methods

Patients

This study was designed as a retrospective single-arm cohort study, which consecutively included all locally advanced ESCC patients who received preoperative camrelizumab combined with chemotherapy at the Thoracic Surgery Department of The First Affiliated Hospital, Zhejiang University School of Medicine from May 2019 to May 2021. The reported objective response rate (ORR) of immunotherapy combined with chemotherapy for the first-line treatment of advanced ESCC was 45% (22). We estimate that the ORR of immunotherapy combined with chemotherapy for ESCC neoadjuvant treatment is about 75%, taking $\alpha = 0.05$ (bilateral), $1 - \beta = 0.80$, resulting

in an estimated sample size of 20. We obtained informed consent to use each patient's medical record information upon admission, and the study was approved by the Clinical Research Ethics Committee of The First Affiliated Hospital, Zhejiang University School of Medicine (2021 IIT No. 742). The study was conducted in accordance with the Declaration of Helsinki (as revised in 2013) (26).

All diagnoses were made after pathological analysis of tissue biopsies obtained with esophagogastroduodenoscopy (EGD). Patients were excluded if they met any of the following criteria: (I) had not undergone a pretreatment imaging evaluation; (II) had undergone serial imaging evaluation <2 times; (III) had previously received surgical or endoscopic interventional treatment for ESCC; (IV) had previously received radiotherapy or systemic anti-cancer therapy; (V) suffered from active tuberculosis; (VI) had an esophageal fistula before treatment; and/or (VII) had distant metastases. The electronic medical records of the Hospital contained the medical history, laboratory examination results, imaging examination results, medication details, surgical records, and pathological results of the inpatients and outpatients.

The primary endpoint of this study was the pathological remission rate of ESCC after neoadjuvant therapy, and the secondary endpoints were ORR, surgical resection rate and adverse reactions. Follow-up data was obtained at the patients' routine hospital admission for examinations or treatments. If a patient was not admitted according to the treatment plan, the patient was contacted by telephone. Follow-up was performed for at least 3 months after surgery.

Neoadjuvant therapy

The neoadjuvant treatment strategy comprised 2–4 cycles of camrelizumab combined with platinum-containing dual-drug chemotherapy (platinum + paclitaxel), which was administered intravenously by ward nurses, with a cycle every 3 weeks. The dose of camrelizumab was 200 mg each time. The platinum-based chemotherapy regimen was 75 mg/m² of cisplatin, area under the curve (AUC) of the plasma concentration-time curve after a single dose =5 of carboplatin, or 80 mg/m² of nedaplatin. The paclitaxel regimen was 260 mg/m² of albumin-bound paclitaxel.

After 2 cycles of treatment, the patients were evaluated by computed tomography (CT) or positron emission tomography (PET)-CT to determine resectability of the ESCC. If the tumor regression was not significant,

neoadjuvant therapy was continued, and the possibility of surgery was evaluated again after 1–2 cycles.

Tumor response evaluation

Within 1 week of the initial treatment, we performed systematic imaging evaluations of the patients using the baseline data, including PET-CT, CT of the esophagus, endoscopic ultrasound, cranial magnetic resonance imaging, and abdominal ultrasound. Next, we performed imaging evaluations by CT of the esophagus every 2 treatment cycles until the patient underwent surgery or changed treatment. Tumor location, degree of differentiation, clinical TNM (cTNM), cTNM staging after neoadjuvant therapy (ycTNM), and pathological TNM staging after neoadjuvant therapy (ypTNM) were determined according to the TNM staging system of the American Joint Committee on Cancer (8th edition) (27). Tumor treatment response was evaluated according to the Response Evaluation Criteria in Solid Tumor version 1.1 (RECIST 1.1) (28). Complete response (CR) was defined as the disappearance of all target lesions; partial remission (PR) was defined as a reduction in the total diameter of target lesions by at least 30%; progressive disease (PD) was defined as an increase in the total diameter of target lesions by at least 20% or the appearance of new lesions; stable disease (SD) was defined as neither CR, PR, nor PD. Patients who achieved CR or PR were defined as responders, while those who had SD and PD were non-responders.

Neoadjuvant therapy-related adverse events

During neoadjuvant therapy, routine hematological and serum biochemical tests were performed every week and included myocardial enzyme spectrum, thyroid function, and coagulation function tests performed every 3 weeks. Gastrointestinal reactions and skin reactions were evaluated during the examinations.

Surgical treatment

The surgical treatment of inferior and medialis ESCC after neoadjuvant therapy included open or video-assisted thoracoscopic Ivor-Lewis esophagectomy with at least a two-field lymphadenectomy. If a tumor was located in the upper esophagus, McKeown esophagectomy and neck lymph node dissection were performed. These operations are performed by the same medical team, usually four

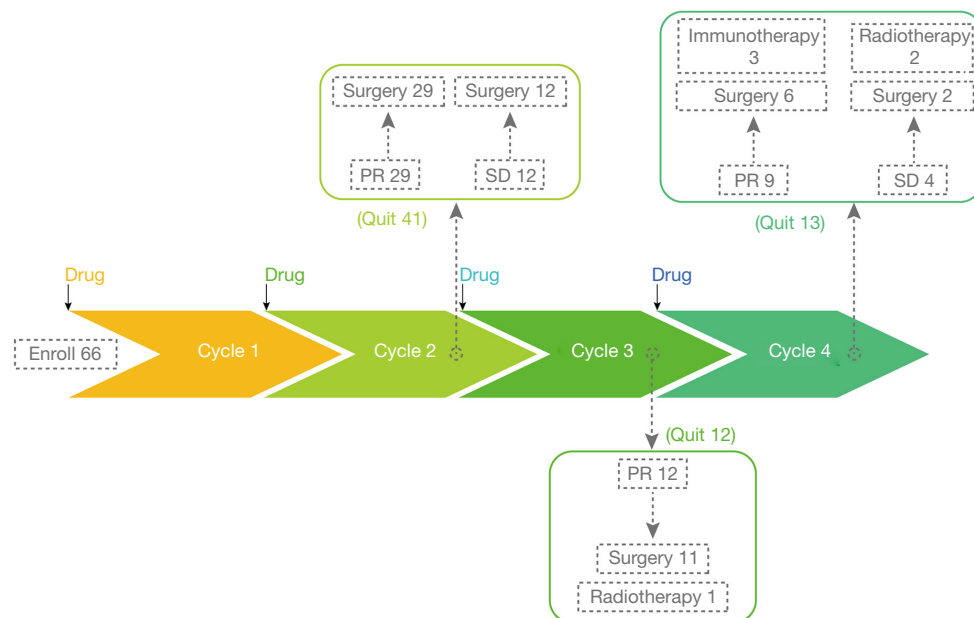


Figure 1 Overview of neoadjuvant treatment process and outcomes. PR, partial remission; SD, stable disease.

surgeons per operation. The length of the surgery, estimated blood loss, and postoperative complications were recorded.

Pathological examination

The original pathology report described the macroscopic and microscopic appearance of the tumor, including the pathological type, degree of differentiation, depth of invasion, resection margins, lymph nodes, and tumor regression grade (TRG). According to the College of American Pathologists (CAP) and the National Comprehensive Cancer Network (NCCN) guidelines, the TRG was determined by the estimated percentage of residual viable tumor cells relative to the original tumor area and was then be classified into the following 4 categories: TRG 0 (no surviving cancer cells), TRG 1 (residual cancer cells $\leq 10\%$), TRG 2 ($10\% <$ residual tumor cells $\leq 50\%$), and TRG 3 (residual cancer cells $> 50\%$). The major pathological response (MPR) was defined as the residual tumor cells not exceeding 10%, which includes TRG 0 and TRG 1.

Statistical analysis

The categorical variables are presented as frequencies and percentages and the continuous variables are presented as the median and interquartile range (IQR). In this

study, most of the analyses are descriptive. To explore clinicopathological factors associated with treatment response, we divided patients into PR and SD groups according to treatment response. The differences between PR and SD groups were compared using the chi-square test or the paired chi-square test. For continuous variables, the differences between PR and SD groups were compared using the *t*-test or the Wilcoxon test. All the analyses were performed using R software version 4.1.2 (R Project for Statistical Computing, Vienna, Austria). A two-tailed P value < 0.05 was considered significant.

Results

Patients and treatment process

A total of 66 patients were included in this study with an overview of the neoadjuvant treatment process demonstrated in *Figure 1*. All cases completed follow-up. The operation rate was approximately 90.91% (60/66); 3 patients with a PR response did not wish to undergo surgery and chose radiotherapy instead. At the end of the 4th cycle, 1 patient had a PR response, but as the thoracoscopy showed that the tumor was in close contact with the adjacent trachea and could not be completely removed, radiotherapy was performed. In another 3 patients, the downstaging was not obvious, and radiotherapy was selected.

Response to neoadjuvant therapy

Among the 66 patients, there were no clinical CR or PD patients; however, there were 50 (75.76%) PR patients; and 16 (24.24%) SD patients. The ORR was 75.76% (50/66). Based on their treatment responses, the patients were divided into the following 2 groups: PR and SD. The clinicopathological characteristics of the patients are summarized in *Table 1*. There were no significant differences between the PR and SD groups in terms of age, sex, Eastern Cooperative Oncology Group (ECOG) performance status, smoking status, drinking status, comorbidities, pathological grade, tumor location, clinical stage, immunotherapy regimens, or treatment cycles.

With the baseline tumor size as a reference, the maximum tumor diameter change was presented using “waterfall plot” (*Figure 2*). To evaluate the relationship between the number of treatment cycles and the average change in the diameter of the lesions, we compared the diameter of the lesions in each treatment cycle. As *Figure 3* shows, the average tumor diameter at the end of cycles 2 (*Figure 3A*), 3 (*Figure 3B*), and 4 (*Figure 3C*) was significantly smaller than that at baseline. The average tumor diameter at the end of cycles 3 (*Figure 3D*) and 4 (*Figure 3E*) was also significantly reduced compared to that at the end of the 2nd cycle.

The changes in the cTNM stage before (cTNM stage) and after (ycTNM stage) neoadjuvant treatment are summarized in *Table 2*. There was a significant difference in T stage before and after treatment ($P < 0.001$). After treatment, the proportion of patients with T4a (10.6% before treatment *vs.* 4.5% after treatment) and T4b (33.3% before treatment *vs.* 7.6% after treatment) decreased, the proportion of patients with T3 (43.9% before treatment *vs.* 40.9% after treatment) remained approximately the same, and the proportion of patients with T1 (0.0% before treatment *vs.* 3.0% after treatment) and T2 (12.1% before treatment *vs.* 43.9% after treatment) increased. In relation to the N stage, we observed a decrease in the proportion of patients with N2 (53.0% before treatment *vs.* 50.0% after treatment) and N3 (3.0% before treatment *vs.* 0.0% after treatment), and an increase in the proportion of patients with N0 (13.6% before treatment *vs.* 15.2% after treatment) and N1 (30.3% before treatment *vs.* 34.8% after treatment). The changes in N stage before and after treatment differed significantly ($P < 0.001$). The changes in TNM stage manifested as a decrease in the proportion of patients with stage IVA (43.9% before treatment *vs.* 12.1% after treatment) ESCC, and an increase in the proportion

of patients with stages I (0% before treatment *vs.* 1.5% after treatment), II (12.1% before treatment *vs.* 28.8% after treatment), or III (43.9% before treatment *vs.* 12.1% after treatment). There was a significant difference in the TNM stage between the two groups before and after treatment ($P < 0.001$).

Surgery and pathological response

Of the 66 patients, 60 patients ultimately underwent surgery. The surgical and pathological results are summarized in *Table 3*. The median time from last treatment to the date of surgery was 30.0 (IQR, 28.8–33.0) days. There were 26 patients who underwent open surgery, and 33 patients who underwent minimally invasive surgery. In addition, there was 1 conversion from minimally-invasive to open surgery due to dense adhesions between the tumor and surrounding tissues. The median operation time was 280.0 (IQR, 248.5–316.5) min. The median estimated intraoperative blood loss was 100 (IQR, 50–100) mL. The median number of lymph nodes removed during the operation was 24 (IQR, 14–32), excluding the lymph nodes evaluated by the pathologist in the esophagectomy specimen. There were 59 patients with R0 resection, and tumor cells were observed in the upper and lower margins of the esophagus in 1 patient (R1 resection). The median length of hospital stay was 21.0 (IQR, 17.0–24.0) days, and there was no significant difference between the open and minimally invasive groups (open: median 21.0, IQR, 14.8–22.8 days *vs.* minimally invasive: median 20.5, IQR, 17.3–24.0 days, $P = 0.461$). Postoperative complications included anastomotic leaks in 6 cases, of which 1 case underwent secondary surgery. Aspiration pneumonia occurred in 5 cases, all of which were treated with mechanical ventilation. One case of anastomotic stenosis underwent endoscopic treatment. One case of gastroparesis was improved after symptomatic treatment. One case of chylous leakage was treated with thoracic duct ligation. One case of intestinal obstruction was improved after gastrointestinal decompression. No perioperative deaths occurred. The pathological evaluation revealed that the incidences of TRG 0, TRG 1, TRG 2, and TRG 3 were 6.7%, 13.3%, 60.0%, and 20.0%, respectively. Of the 60 patients, 12 (20.0%) achieved an MPR.

Toxicity

The toxicities of neoadjuvant immunotherapy combined with chemotherapy are summarized in *Table 4*. No immune

Table 1 Characteristics of the patients at the baseline according to the treatment responses

Characteristics	Total (n=66)	PR (n=50)	SD (n=16)	P value
Age (years), median age (IQR)	67.5 (59.0–71.0)	67.0 (59.0–70.8)	67.5 (62.0–72.3)	0.494
Sex, n (%)				0.586
Male	60 (90.9)	46 (92.0)	14 (87.5)	
Female	6 (9.1)	4 (8.0)	2 (12.5)	
ECOG performance status, n (%)				0.319
0	36 (54.5)	29 (58.0)	7 (43.8)	
1	30 (45.5)	21 (42.0)	9 (56.3)	
Smoking status, n (%)				0.566
Never	33 (50.0)	26 (52.0)	7 (43.8)	
Ever	33 (50.0)	24 (48.0)	9 (56.3)	
Drinking status, n (%)				0.566
Never	33 (50.0)	26 (52.0)	7 (43.8)	
Ever	33 (50.0)	24 (48.0)	9 (56.3)	
Comorbidities, n (%)				
Pulmonary disease	10 (15.2)	7 (14.0)	3 (18.8)	0.645
Cardiac disease	12 (18.2)	9 (18.0)	3 (18.8)	0.946
Kidney disease	3 (4.5)	2 (4.0)	1 (6.3)	0.707
Diabetes mellitus	3 (4.5)	2 (4.0)	1 (6.3)	0.707
Hypertension	19 (28.8)	14 (28.0)	5 (31.3)	0.803
Pathological grade, n (%)				0.425
G1	3 (4.5)	3 (6.0)	0 (0.0)	
G2	36 (54.5)	28 (56.0)	8 (50.0)	
G3	16 (24.2)	10 (20.0)	6 (37.5)	
Unknown	11 (16.7)	9 (18.0)	2 (12.5)	
Tumor location, n (%)				0.544
Locus superior	12 (18.2)	9 (18.0)	3 (18.8)	
Locus medialis	32 (48.5)	26 (52.0)	6 (37.5)	
Locus inferior	22 (33.3)	15 (30.0)	7 (43.8)	
Clinical stage, n (%)				0.466
II	8 (12.1)	7 (14.0)	1 (6.3)	
III	29 (43.9)	20 (40.0)	9 (56.3)	
IVA	29 (43.9)	23 (46.0)	6 (37.5)	
Treatment cycle, n (%)				0.095
2	41 (62.1)	29 (58.0)	12 (75.0)	
3	12 (18.2)	12 (24.0)	0 (0.0)	
4	13 (19.7)	9 (18.0)	4 (25.0)	

IQR, interquartile range; ECOG, Eastern Cooperative Oncology Group; PR, partial remission; SD, stable disease.

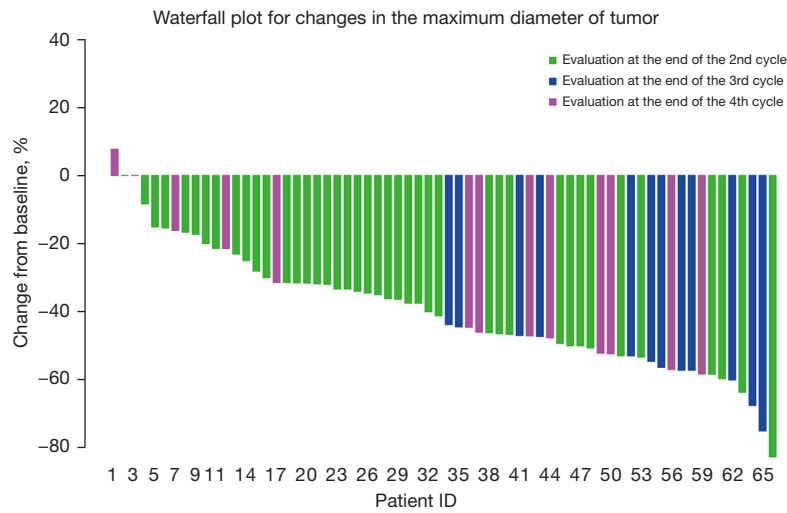


Figure 2 The change in the maximum transverse diameter of the tumor from the baseline to the end of the last neoadjuvant treatment cycle.

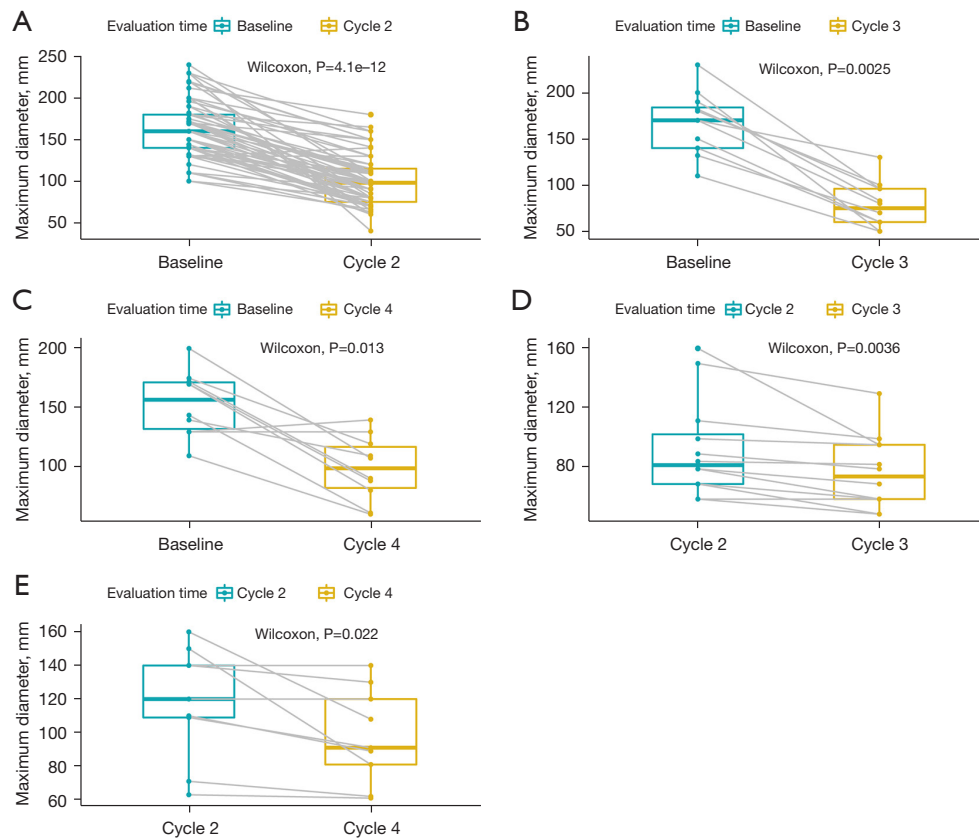


Figure 3 The relationship between different treatment cycles and changes in lesion diameter. (A) The change in the maximum transverse diameter of the tumor from the baseline to the end of the 2nd cycle of neoadjuvant therapy. (B) The change in the maximum transverse diameter of the tumor from the baseline to the end of the 3rd cycle of neoadjuvant treatment. (C) The change in the maximum transverse diameter of the tumor from the baseline to the end of the 4th cycle of neoadjuvant therapy. (D) The change in the maximum transverse diameter of the tumor from the end of the 2nd cycle to the end of the 3rd cycle of neoadjuvant therapy. (E) The change of the maximum transverse diameter of the tumor from the end of the 2nd cycle to the end of the 4th cycle of neoadjuvant therapy.

Table 2 Changes in the clinical stages of ESCC patients before (cTNM stage) and after (ycTNM stage) neoadjuvant treatment

Characteristics	cTNM stage (n=66)	ycTNM stage (n=66)	P value
T stage, n (%)			<0.001
T1	0 (0.0)	2 (3.0)	
T2	8 (12.1)	29 (43.9)	
T3	29 (43.9)	27 (40.9)	
T4a	7 (10.6)	3 (4.5)	
T4b	22 (33.3)	5 (7.6)	
N stage, n (%)			<0.001
N0	9 (13.6)	10 (15.2)	
N1	20 (30.3)	23 (34.8)	
N2	35 (53.0)	33 (50.0)	
N3	2 (3.0)	0 (0.0)	
Stage, n (%)			<0.001
I	0 (0.0)	1 (1.5)	
II	8 (12.1)	19 (28.8)	
III	29 (43.9)	38 (57.6)	
IVA	29 (43.9)	8 (12.1)	

ESCC, esophageal squamous cell carcinoma; cTNM, clinical TNM; ycTNM, cTNM staging after neoadjuvant therapy.

pneumonia or myocarditis occurred during the treatment. There were 2 cases of grade 4 adverse reactions, including 1 case of agranulocytosis and 1 case of anemia. Grade 3 adverse reactions occurred in 12 patients, including anemia in 7 patients, liver damage in 2 patients, agranulocytosis in 1 patient, skin reaction in 1 patient, and anemia and skin reaction in 1 patient. These adverse reactions improved after symptomatic treatment, and no patient had to discontinue treatment due to adverse reactions.

Discussion

The treatment options for locally advanced ESCCs usually include surgical resection, radiotherapy, chemotherapy, or a combined chemoradiotherapy (12). nCT has a significant advantage in improving the survival of ESCC patients compared to surgery alone (14). More recently,

Table 3 Outcomes for ESCC patients undergoing surgery

Outcomes	Value (n=60)
Time from last neoadjuvant therapy to surgery (days)	30.0 (28.8–33.0)
Surgical approach	
Open	26 (43.3)
Minimally invasive	33 (55.0)
Minimally invasive to open	1 (1.7)
Operating time (min)	280.0 (248.5–316.5)
Estimated blood loss (mL)	100.0 (50.0–100.0)
Total number of dissected lymph nodes	24.0 (14.0–32.0)
Resection margin	
R0 complete resection	59 (98.3)
R1 microscopic incomplete resection	1 (1.7)
Length of hospital stay (days)	21.0 (17.0–24.0)
Postoperative complication	
Anastomotic leak	6 (10.0)
Aspiration pneumonia	5 (8.3)
Anastomotic stenosis	1 (1.7)
Gastroparesis	1 (1.7)
Chyle leak	1 (1.7)
Intestinal obstruction	1 (1.7)
None	45 (75.0)
ypTNM stage	
I	17 (28.3)
II	8 (13.3)
IIIA	6 (10.0)
IIIB	25 (41.7)
IVA	4 (6.7)
Pathological response	
TRG 0	4 (6.7)
TRG 1	8 (13.3)
TRG 2	36 (60.0)
TRG 3	12 (20.0)

Numbers are in median (IQR) or n (%). ESCC, esophageal squamous cell carcinoma; IQR, interquartile range; ypTNM, pathological TNM staging after neoadjuvant therapy; TRG, tumor regression grade.

Table 4 Neoadjuvant therapy toxicities

Toxicity	None	Grade 1	Grade 2	Grade 3	Grade 4
Hematologic					
Leukopenia	52	1	11	2	0
Agranulocytosis	52	9	3	1	1
Anemia	18	21	17	9	1
Thrombocytopenia	57	3	6	0	0
Gastrointestinal					
Nausea	50	20	12	4	0
Emesis	51	14	1	0	0
Diarrhea	55	9	2	0	0
Constipation	58	3	5	0	0
Hepatic injury	56	5	3	2	0
Renal injury	47	13	6	0	0
Skin reaction	24	35	5	2	0
Hypothyroidism	65	1	0	0	0

the tolerability and efficacy of ICIs has been verified in the treatment of advanced ESCCs (15-23). Preoperative chemotherapy combined with immunotherapy can theoretically achieve satisfactory anti-tumor effects with tolerable side effects. In this study, we found that the ORR of neoadjuvant immunotherapy combined with chemotherapy was 75.76%, which was significantly higher than that of immunotherapy alone as the 2nd-line treatment for esophageal cancer (9.9–30%) (15-18). Our neoadjuvant treatment process was set to 2–4 cycles. If the tumor regression at the end of the 2nd cycle was not satisfactory, the patient would be treated for a 3rd or 4th cycle. The imaging results show that the tumor continued to shrink after the 3rd–4th cycle of treatment. Thus, our findings suggest that for patients who have no obvious remission after 2nd cycle, the treatment can be continued up to 3rd–4th cycle of treatment.

Klebrebro *et al.* (29) used nCT for patients with esophageal cancer and found that for those with ESCC, the pathological complete remission (pCR) rate after nCT was 9%, and the MPR rate was approximately 15%. In our study, the pCR rate was approximately 6.7%, which was lower than the 9% rate of chemotherapy alone, but the MPR rate was approximately 20.0%, which was higher than the 15% rate of chemotherapy alone (29). The postoperative complication rate of patient undergoing

treatment for ESCC in our study was approximately 25.0%, while the postoperative complication rate in the neoadjuvant immunotherapy combined with radiotherapy and chemotherapy group reported by Sihag *et al.* was approximately 88% (22/25). The discrepancy in the results may be explained by Sihag *et al.* reported use of immunotherapy combined with radiotherapy and chemotherapy, while we used immunotherapy combined with chemotherapy alone (30).

In terms of drug safety, the ESCORT-1st study used a treatment regimen similar to our study; that is, camrelizumab combined with paclitaxel plus platinum chemotherapy for patients with advanced ESCC (23). The ESCORT-1st study observed that during the administration of immunotherapy combined with chemotherapy to treat advanced ESCCs, the incidence of adverse reactions > grade 3 was 63.4% (189/298), and the treatment-related mortality rate was 3% (9/298) (23). In our study, we found that the incidence of grade 3–4 adverse reactions caused by neoadjuvant immunotherapy combined with chemotherapy was 21.2% (14/66), and there were no treatment-related deaths. A reason for the inconsistent results may be that the ESCC patients included in the ESCORT-1st study were all advanced or metastatic. The treatment period of the ESCORT-1st study was 6 cycles, which is longer than the 2–4 cycles of our study, and may also be a reason for

the difference in safety. Overall, the toxicity of neoadjuvant immunotherapy combined with chemotherapy is acceptable.

Our study had notable limitations which included its retrospective nature, small sample size, short follow-up time, and the heterogeneity of the patients. To reduce the selection bias, this study included all patients diagnosed with ESCC at our center who met inclusion criteria. Neoadjuvant concurrent chemoradiotherapy represented by the CROSS study (31) has shown a clear curative effect, but in the context of the immune era, neoadjuvant concurrent chemoradiotherapy is increasingly challenged by immunotherapy (32). Due to the lack of randomized controlled trials specifically targeting neoadjuvant immunotherapy combined with chemotherapy in patients with ESCC, we believe that our findings provide valuable insights that can be used to assist in the choice of clinical treatments.

In conclusion, our results from these preliminary analyses suggest that neoadjuvant immunotherapy combined with chemotherapy followed by surgical resection may be a safe, feasible, and effective treatment option for patients with locally-advanced ESCC. However, randomized controlled trials on larger scales are required to confirm our results. The question of whether this neoadjuvant treatment regimen can produce a survival benefit needs to be confirmed by future follow-up studies with larger sample sizes.

Acknowledgments

The authors appreciate the academic support from the AME Thoracic Surgery Collaborative Group.

Funding: This research was supported by the Zhejiang Province Major Science and Technology Special Program Project (grant No. 2020C03058), the Zhejiang Province Lung Tumor Diagnosis and Treatment Technology Research Supported by the Center (grant No. JBZX-202007), the Zhejiang Provincial Traditional Chinese Medicine (Integrated Traditional Chinese and Western Medicine) Key Discipline (grant No. 2017-XK-A33), and the Zhejiang Provincial Natural Science Foundation (grant No. LY19H160039).

Footnote

Reporting Checklist: The authors have completed the TREND reporting checklist. Available at <https://atm.amegroups.com/article/view/10.21037/atm-22-4268/rc>

Data Sharing Statement: Available at <https://atm.amegroups.com/article/view/10.21037/atm-22-4268/dss>

Conflicts of Interest: All authors have completed the ICMJE uniform disclosure form (available at <https://atm.amegroups.com/article/view/10.21037/atm-22-4268/rc>). The authors have no conflicts of interest to declare.

Ethical Statement: The authors are accountable for all aspects of the work in ensuring that questions related to the accuracy or integrity of any part of the work are appropriately investigated and resolved. The study was conducted in accordance with the Declaration of Helsinki (as revised in 2013). We obtained informed consent to use each patient's medical record information upon admission, and the study was approved by the Clinical Research Ethics Committee of The First Affiliated Hospital, Zhejiang University School of Medicine (2021 IIT No. 742).

Open Access Statement: This is an Open Access article distributed in accordance with the Creative Commons Attribution-NonCommercial-NoDerivs 4.0 International License (CC BY-NC-ND 4.0), which permits the non-commercial replication and distribution of the article with the strict proviso that no changes or edits are made and the original work is properly cited (including links to both the formal publication through the relevant DOI and the license). See: <https://creativecommons.org/licenses/by-nc-nd/4.0/>.

References

1. Sung H, Ferlay J, Siegel RL, et al. Global Cancer Statistics 2020: GLOBOCAN Estimates of Incidence and Mortality Worldwide for 36 Cancers in 185 Countries. *CA Cancer J Clin* 2021;71:209-49.
2. Arnold M, Soerjomataram I, Ferlay J, et al. Global incidence of oesophageal cancer by histological subtype in 2012. *Gut* 2015;64:381-7.
3. Grille VJ, Campbell S, Gibbs JF, et al. Esophageal cancer: the rise of adenocarcinoma over squamous cell carcinoma in the Asian belt. *J Gastrointest Oncol* 2021;12:S339-49.
4. Arnold M, Lavrsanne M, Brown LM, et al. Predicting the Future Burden of Esophageal Cancer by Histological Subtype: International Trends in Incidence up to 2030. *Am J Gastroenterol* 2017;112:1247-55.
5. Wang J, Yu L, Sun Y, et al. Development and Evaluation of Serum CST1 Detection for Early Diagnosis of

- Esophageal Squamous Cell Carcinoma. *Cancer Manag Res* 2021;13:8341-52.
6. DiSiena M, Perelman A, Birk J, et al. Esophageal Cancer: An Updated Review. *South Med J* 2021;114:161-8.
 7. Zeng H, Ran X, An L, et al. Disparities in stage at diagnosis for five common cancers in China: a multicentre, hospital-based, observational study. *Lancet Public Health* 2021;6:e877-87.
 8. Igaki H, Tachimori Y, Kato H. Improved survival for patients with upper and/or middle mediastinal lymph node metastasis of squamous cell carcinoma of the lower thoracic esophagus treated with 3-field dissection. *Ann Surg* 2004;239:483-90.
 9. Ando N, Iizuka T, Ide H, et al. Surgery plus chemotherapy compared with surgery alone for localized squamous cell carcinoma of the thoracic esophagus: a Japan Clinical Oncology Group Study--JCOG9204. *J Clin Oncol* 2003;21:4592-6.
 10. van Hagen P, Hulshof MC, van Lanschot JJ, et al. Preoperative chemoradiotherapy for esophageal or junctional cancer. *N Engl J Med* 2012;366:2074-84.
 11. Yang H, Liu H, Chen Y, et al. Neoadjuvant Chemoradiotherapy Followed by Surgery Versus Surgery Alone for Locally Advanced Squamous Cell Carcinoma of the Esophagus (NEOCRTEC5010): A Phase III Multicenter, Randomized, Open-Label Clinical Trial. *J Clin Oncol* 2018;36:2796-803.
 12. Kelly RJ. Emerging Multimodality Approaches to Treat Localized Esophageal Cancer. *J Natl Compr Canc Netw* 2019;17:1009-14.
 13. Urba S. Esophageal cancer: preoperative or definitive chemoradiation. *Ann Oncol* 2004;15 Suppl 4:iv93-6.
 14. Hou S, Pan Z, Hao X, et al. Recent Progress in the Neoadjuvant Treatment Strategy for Locally Advanced Esophageal Cancer. *Cancers (Basel)* 2021;13:5162.
 15. Kudo T, Hamamoto Y, Kato K, et al. Nivolumab treatment for oesophageal squamous-cell carcinoma: an open-label, multicentre, phase 2 trial. *Lancet Oncol* 2017;18:631-9.
 16. Janjigian YY, Bendell J, Calvo E, et al. CheckMate-032 Study: Efficacy and Safety of Nivolumab and Nivolumab Plus Ipilimumab in Patients With Metastatic Esophagogastric Cancer. *J Clin Oncol* 2018;36:2836-44.
 17. Doi T, Piha-Paul SA, Jalal SI, et al. Safety and Antitumor Activity of the Anti-Programmed Death-1 Antibody Pembrolizumab in Patients With Advanced Esophageal Carcinoma. *J Clin Oncol* 2018;36:61-7.
 18. Shah MA, Kojima T, Hochhauser D, et al. Efficacy and Safety of Pembrolizumab for Heavily Pretreated Patients With Advanced, Metastatic Adenocarcinoma or Squamous Cell Carcinoma of the Esophagus: The Phase 2 KEYNOTE-180 Study. *JAMA Oncol* 2019;5:546-50.
 19. Kojima T, Shah MA, Muro K, et al. Randomized Phase III KEYNOTE-181 Study of Pembrolizumab Versus Chemotherapy in Advanced Esophageal Cancer. *J Clin Oncol* 2020;38:4138-48.
 20. Huang J, Xu J, Chen Y, et al. Camrelizumab versus investigator's choice of chemotherapy as second-line therapy for advanced or metastatic oesophageal squamous cell carcinoma (ESCOR): a multicentre, randomised, open-label, phase 3 study. *Lancet Oncol* 2020;21:832-42.
 21. Janjigian YY, Shitara K, Moehler M, et al. First-line nivolumab plus chemotherapy versus chemotherapy alone for advanced gastric, gastro-oesophageal junction, and oesophageal adenocarcinoma (CheckMate 649): a randomised, open-label, phase 3 trial. *Lancet* 2021;398:27-40.
 22. Sun JM, Shen L, Shah MA, et al. Pembrolizumab plus chemotherapy versus chemotherapy alone for first-line treatment of advanced oesophageal cancer (KEYNOTE-590): a randomised, placebo-controlled, phase 3 study. *Lancet* 2021;398:759-71.
 23. Luo H, Lu J, Bai Y, et al. Effect of Camrelizumab vs Placebo Added to Chemotherapy on Survival and Progression-Free Survival in Patients With Advanced or Metastatic Esophageal Squamous Cell Carcinoma: The ESCORT-1st Randomized Clinical Trial. *JAMA* 2021;326:916-25.
 24. Kelly RJ, Ajani JA, Kuzdzal J, et al. Adjuvant Nivolumab in Resected Esophageal or Gastroesophageal Junction Cancer. *N Engl J Med* 2021;384:1191-203.
 25. Song H, Liu X, Jiang L, et al. Current Status and Prospects of Camrelizumab, A Humanized Antibody Against Programmed Cell Death Receptor 1. *Recent Pat Anticancer Drug Discov* 2021;16:312-32.
 26. World Medical Association. World Medical Association Declaration of Helsinki: ethical principles for medical research involving human subjects. *JAMA* 2013;310:2191-4.
 27. Rice TW, Ishwaran H, Ferguson MK, et al. Cancer of the Esophagus and Esophagogastric Junction: An Eighth Edition Staging Primer. *J Thorac Oncol* 2017;12:36-42.
 28. Eisenhauer EA, Therasse P, Bogaerts J, et al. New response evaluation criteria in solid tumours: revised RECIST guideline (version 1.1). *Eur J Cancer* 2009;45:228-47.
 29. Klevebro F, Alexandersson von Döbeln G, Wang N, et al. A randomized clinical trial of neoadjuvant chemotherapy versus neoadjuvant chemoradiotherapy for cancer of the

- oesophagus or gastro-oesophageal junction. *Ann Oncol* 2016;27:660-7.
30. Sihag S, Ku GY, Tan KS, et al. Safety and feasibility of esophagectomy following combined immunotherapy and chemoradiotherapy for esophageal cancer. *J Thorac Cardiovasc Surg* 2021;161:836-43.e1.
31. Eyck BM, van Lanschot JJB, Hulshof MCCM, et al. Ten-Year Outcome of Neoadjuvant Chemoradiotherapy Plus Surgery for Esophageal Cancer: The Randomized

Cite this article as: Xia P, Li P, Wu S, Wang Y, Ye P, Zhang C, Hu J, Kidane B, Lampridis S, Velotta JB, Wakefield CJ, Zhu L, Wang L. Evaluation of the safety and effectiveness of neoadjuvant combined chemoimmunotherapy in the treatment of locally advanced esophageal squamous cell carcinoma: a retrospective single-arm cohort study. *Ann Transl Med* 2022;10(18):991. doi: 10.21037/atm-22-4268

- Controlled CROSS Trial. *J Clin Oncol* 2021;39:1995-2004.
32. Yang Y, Zhu L, Cheng Y, et al. Three-arm phase II trial comparing camrelizumab plus chemotherapy versus camrelizumab plus chemoradiation versus chemoradiation as preoperative treatment for locally advanced esophageal squamous cell carcinoma (NICE-2 Study). *BMC Cancer* 2022;22:506.

(English Language Editor: L. Huleatt)