



# Raltitrexed as a substitute for capecitabine in metastatic gastric cancer: a case report and literature review

Imran Ladak<sup>1</sup>^, Beatrice Preti<sup>1</sup>, Bryan Dias<sup>1,2</sup>, Daniel Adam Breadner<sup>1,3</sup>^

<sup>1</sup>Schulich School of Medicine and Dentistry, Western University, London, ON, Canada; <sup>2</sup>Division of Cardiology, Department of Medicine, London Health Sciences Centre, London, ON, Canada; <sup>3</sup>Department of Oncology, London Health Sciences Centre, London, ON, Canada

Correspondence to: Daniel Adam Breadner. London Health Sciences Centre, 800 Commissioners Rd. E, London, ON N6A 5W9, Canada. Email: daniel.breadner@lhsc.on.ca.

**Background:** 5-Fluorouracil and its oral prodrug, capecitabine, are frequently used in the treatment of gastrointestinal cancers—including gastric cancer—but carry a cardiotoxicity risk. Raltitrexed (brand name Tomudex), a direct inhibitor of thymidylate synthase, has been successfully used as an alternative to fluoropyrimidines in patients with 5-fluorouracil-induced cardiac events. We report the first case, to our knowledge, of raltitrexed used with trastuzumab and platinum-based chemotherapy as a substitute for fluoropyrimidines following cardiotoxicity in a 78-year-old male patient with metastatic gastric cancer.

**Case Description:** The patient experienced a myocardial infarction 3 days after beginning treatment with capecitabine, carboplatin, and trastuzumab for metastatic HER2<sup>+</sup> gastric adenocarcinoma. Capecitabine was replaced with raltitrexed, and the patient ultimately received seven cycles of chemotherapy, five of which included raltitrexed. There were no cardiotoxic events attributable to raltitrexed, although the patient did experience hypotensive episodes, premature ventricular contractions, myelosuppression, and anemia. Progression-free survival was 4.5 months, within the expected range achieved with the ToGA regimen (trastuzumab, cisplatin, 5-fluorouracil chemotherapy). At time of writing, the patient has been alive for 48 weeks since diagnosis.

**Conclusions:** In summary, raltitrexed appears to be a safe alternative to fluoropyrimidines when combined with trastuzumab and platinum, although more data is needed to determine its relative effectiveness.

**Keywords:** Case report; cardiotoxicity; gastric cancer; capecitabine; fluoropyrimidine; raltitrexed

Submitted Sep 29, 2022. Accepted for publication Oct 19, 2022.

doi: 10.21037/atm-2022-69

View this article at: <https://dx.doi.org/10.21037/atm-2022-69>

## Introduction

5-Fluorouracil (5-FU) and its oral prodrug, capecitabine, are frequently used in the treatment of gastrointestinal cancers, including gastric cancer. Their active metabolite inhibits thymidylate synthase, which is involved in DNA synthesis (1,2). These chemotherapeutic agents, termed “fluoropyrimidines”, carry a mean cardiotoxicity risk of approximately 5% (3). Cardiotoxicity most often occurs after their first administration, and can present with chest pain, arrhythmia, or myocardial infarction thought to be

caused by coronary vasospasm (3,4). Raltitrexed (brand name Tomudex), which directly inhibits thymidylate synthase without the use of an active metabolite, has been used as an alternative to fluoropyrimidines in gastrointestinal cancer (5), and is a common substitute in patients with a history of cardiotoxicity from 5-FU or capecitabine or in those with significant coronary artery disease (3). We report the first case, to our knowledge, of raltitrexed successfully replacing a fluoropyrimidine combined with platinum and trastuzumab after a 78-year-old man with metastatic gastric cancer experienced a non-ST

^ ORCID: Imran Ladak, 0000-0002-2629-0371; Daniel Adam Breadner, 0000-0001-5379-7621.

elevation myocardial infarction (NSTEMI) 3 days after beginning treatment. We present the following case in accordance with the CARE reporting checklist (available at <https://atm.amegroups.com/article/view/10.21037/atm-2022-69/rc>).

## Case presentation

In December 2020, a 78-year-old man was referred to general surgery with a 2-month history of epigastric pain exacerbated by meals. Bloating, a ten-pound weight loss, and mild scleral icterus were also noted. A liver lesion was identified on abdominal ultrasound, and a follow-up computed tomography (CT) scan also found a thickened gastric wall. Gastroscopy revealed a fungating mass at the lesser curvature of the stomach. On biopsy, this mass was determined to be a HER2 overexpressing (HER2<sup>+</sup>), IHC 3<sup>+</sup> (immunohistochemistry high, with  $\geq 10\%$  of tumour cells showing membranous staining for the receptor), moderately-differentiated adenocarcinoma (6).

The patient's past medical history was significant for papillary urothelial carcinoma treated with transurethral resection of bladder tumour, medically-managed hypertension, mild to moderate aortic stenosis, and stable chronic kidney disease with a creatinine clearance of 45 to 50 mL/min.

An imaging workup of CT head, CT thorax-abdomen-pelvis, and magnetic resonance imaging (MRI) of the liver with gadolinium did not reveal any metastases beyond the solitary liver lesion. Dihydropyrimidine dehydrogenase (DYPD) genetic testing, done to ensure expected 5-FU metabolism, indicated normal enzymatic activity (7).

The patient was scheduled for first-line treatment consisting of capecitabine ( $800 \text{ mg/m}^2$ ) twice a day for 2 weeks on, 1 week off; carboplatin (4 area under the curve, or AUC); and trastuzumab (6 mg/kg after a first cycle at 8 mg/kg) every 3 weeks. The capecitabine and carboplatin were moderately dose-reduced by 20% each (from standard dosing at  $2,000 \text{ mg/m}^2$  total daily for capecitabine and 5 AUC for carboplatin) given the patient's age.

Three days after beginning the first cycle of treatment, the patient experienced a new and sudden retrosternal chest pain, accompanied by dyspnea and diaphoresis. He received nitroglycerin from paramedics before being brought to the emergency department. He then received two more doses of nitroglycerin, and his pain decreased before dissipating altogether.

In the hospital, the patient underwent a workup for an

acute coronary syndrome. His troponin levels increased from 13 to 118 ng/L over 5.5 hours (the upper limit of normal is 14 ng/L). He was diagnosed with a NSTEMI and admitted to the hospital. His baseline electrocardiogram (ECG) showed sinus rhythm with a left anterior hemiblock. One ECG showed widespread ST segment elevation that was transient. Echocardiography showed a decrease in his left ventricular ejection fraction (LVEF) from 60–65% to 50% with new wall motion abnormalities noted in the anterior and anterolateral walls. Repeat echocardiograms that were done as an outpatient after discharge from hospital showed normalization of the LVEF.

The patient declined cardiac catheterization due to the risks of the procedure. Medical management consisted of dual antiplatelet therapy (DAPT) with acetylsalicylic acid 81 mg daily and clopidogrel 75 mg daily, anticoagulation with low molecular weight heparin (fondaparinux) while in hospital, and beta-blockade with bisoprolol 5 mg daily. The patient was already on an angiotensin-converting enzyme inhibitor (perindopril 4 mg daily) and was started on appropriate lipid lowering medication with atorvastatin 40 mg daily. The diagnosis of NSTEMI was attributed to capecitabine cardiotoxicity based on the timing of the infarct after the capecitabine as well as the ST changes that were seen on one of the ECGs.

During the second cycle of treatment, 24 days after the first cycle and 21 days after the NSTEMI, the patient received carboplatin and trastuzumab. The medical oncologist and patient discussed raltitrexed as a potential substitution for capecitabine on account of 5-FU toxicity, to which the patient was agreeable. Since the patient noted increased fatigue, it was decided to trial the second cycle with carboplatin and trastuzumab, with raltitrexed to be included thereafter. Therefore, beginning with the third cycle, the patient received raltitrexed, carboplatin, and trastuzumab. He received five cycles with these three agents, ultimately receiving seven cycles of chemotherapy. Throughout the treatment cycles, raltitrexed was dose reduced by 30–40% from a standard dose of  $3 \text{ mg/m}^2$ ; carboplatin was dose reduced by 20–25% from a standard dose of 5 AUC.

The patient did not experience any cardiotoxicity attributable to raltitrexed. After the fifth cycle, he began experiencing paroxysmal hypotensive episodes in the morning: the first such episode presented with a blood pressure of 70/40 mmHg and heart rate of 39 beats per minute, both of which were measured at home. A cardiologist was consulted who felt that the bradycardia was

**Table 1** Historical timeline of first-line treatment and cardiotoxicity

Day	Event
0	1st cycle (capecitabine, carboplatin, trastuzumab); solitary right hepatic lobe mass on MR gadolinium
3	NSTEMI; capecitabine continued
5	Capecitabine stopped
24	2nd cycle (carboplatin, trastuzumab)
45	3rd cycle (ralitrexed, carboplatin, trastuzumab)
66	4th cycle (ralitrexed, carboplatin, trastuzumab)
77	Decreased gastric thickening and interval stability of liver metastasis on CT
87	5th cycle (ralitrexed, carboplatin, trastuzumab)
108	6th cycle (ralitrexed, carboplatin, trastuzumab)
129	7th cycle (ralitrexed, carboplatin, trastuzumab)
137	3 of 6 liver lesions increased in size on CT

MR, magnetic resonance; NSTEMI, non-ST-elevation myocardial infarction; CT, computed tomography.

secondary to the beta blockade in the setting of depressed renal function. The hypotension was partially attributed to poor oral intake. ECG showed new premature ventricular complexes, but this was attributed by the consulting cardiologist to electrolyte imbalance, and not to the chemotherapy or trastuzumab. A Holter monitor study was ordered to assess for significant arrhythmias, but the patient did not attend the appointment. The patient did not show up for the appointment. Other treatment side effects included fatigue, myelosuppression (after the fourth cycle, with a white blood cell count of  $3.4 \times 10^9/L$  and grade 2 neutropenia of  $1.2 \times 10^9/L$ ), and grade 2 anemia (after the seventh cycle, with a hemoglobin reading of 97 g/L) as per the Common Terminology Criteria for Adverse Events (CTCAE). The patient was treated once with pegylated filgrastim for his myelosuppression.

After four cycles of treatment, the patient received a CT scan, which showed that the gastric wall thickening signifying the primary tumour was “no longer conspicuously evident”. The CT scan also found the solitary liver metastasis to be stable in size. After the fifth cycle of treatment, the patient received an MRI of the liver with Primovist. This scan measured the previously-seen liver metastasis at 4.1 cm × 2.8 cm and visualized five other liver lesions.

The patient received two more cycles of chemotherapy and trastuzumab, for a total of seven cycles, before another CT scan was done. The CT thorax-abdomen-pelvis showed that 3 of the 6 liver lesions had increased in size, including

the first-identified lesion (to 4.8 cm × 4 cm). This marked a progression-free survival (PFS) of 4.5 months. Thereafter, the patient received radiotherapy to the primary tumour (20 gray in 5 fractions). All procedures performed in this study were in accordance with the ethical standards of the institutional and/or national research committee(s) and with the Helsinki Declaration (as revised in 2013). The patient provided verbal consent to disseminate his experience with this novel chemotherapy regimen.

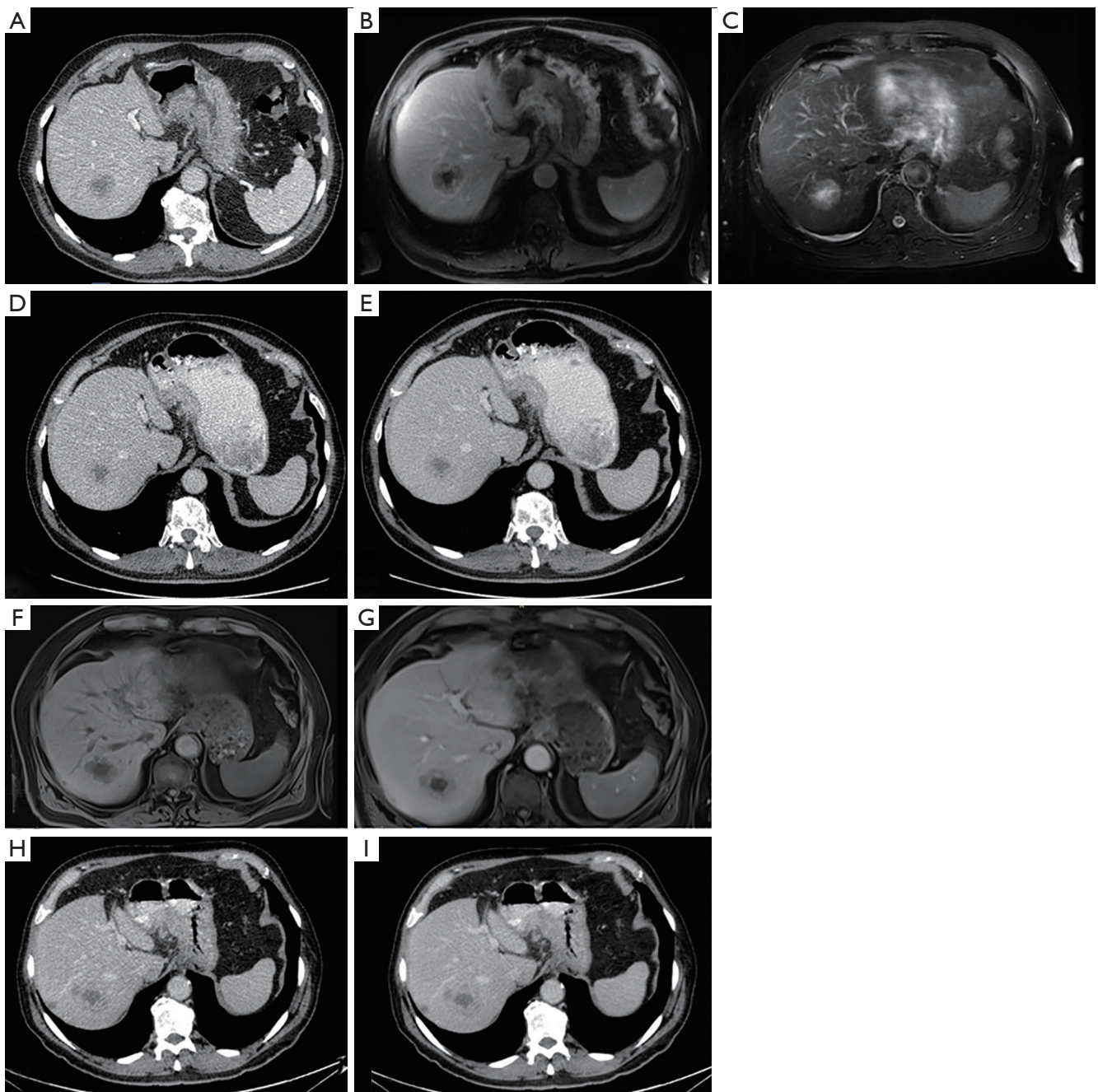
*Table 1* and *Figure 1* summarizes the timeline of clinical events and imaging findings.

## Literature review

Two independent authors conducted a review of English language reports on PubMed containing the terms “ralitrexed” and “gastric adenocarcinoma” from January 1<sup>st</sup>, 2000 to June 30<sup>th</sup>, 2021. Prospective and retrospective clinical trials and case series and reports were reviewed regardless of line of therapy.

## Discussion

In summary, the patient’s capecitabine-induced cardiotoxicity led to the fluoropyrimidine being replaced with raltitrexed, which did not cause similar cardiotoxic symptoms. The patient’s PFS of 4.5 months compares to the median PFS of 6.7 months for patients with advanced gastric or gastroesophageal cancer similarly treated with trastuzumab



**Figure 1** Longitudinal computed tomography and magnetic resonance images of liver lesion(s). (A) The solitary liver lesion on baseline CT (day 13). (B,C) The liver lesion on gadolinium enhanced MRI (day 0). (D,E) Stable disease of the liver lesion on day 77. (F,G) Three of the 6 lesions detected by MR liver enhanced with Gadoxetate disodium (Primovist®) on day 95. (H,I) Day 137 CT confirmed progressive disease showing new disease, within the same imaging modality. CT, computed tomography, MRI, magnetic resonance imaging.

and chemotherapy in the ToGA trial (8). While this is numerically reduced compared to the ToGA trial median PFS, it is within the expected duration of therapy, and the

patient required an initial dose reduction due to his age and comorbidities. To date, the patient has been alive for 48 weeks since diagnosis, compared to an overall survival

**Table 2** Review of raltitrexed use in gastric cancers in previous trials

Authors	Phase	Study details	Findings
Bjarnason <i>et al.</i>	I	Raltitrexed and doxorubicin dose-finding study 20 patients had gastric cancer	Response rate of 20% in gastric cancer patients Median overall survival of 6.8 months Recommended dose of raltitrexed 3 mg/m <sup>2</sup> and doxorubicin 60 mg/m <sup>2</sup> q3w Hematological toxicities were dose-limiting
Eatock <i>et al.</i>	I	ECT (epirubicin, cisplatin, raltitrexed) dose-finding study 14/24 patients had gastric cancer	Overall response rate of 38% Diarrhea, stomatitis, neutropenia toxicities
Ferrari <i>et al.</i>	II	ECT: epirubicin 60 mg/m <sup>2</sup> q3w, cisplatin 60 mg/m <sup>2</sup> q3w, raltitrexed 1 mg/m <sup>2</sup> on day 1 and 8 q3w 20/32 patients had gastric cancer	Gastric cancer response rate of 35% Median gastric cancer response duration of 19 weeks
Mackay <i>et al.</i>	II	ECT: epirubicin 50 mg/m <sup>2</sup> q3w, cisplatin 60 mg/m <sup>2</sup> q3w, raltitrexed 2.5 mg/m <sup>2</sup> q3w 5/21 patients had gastric cancer	Overall response rate of 29% Combined response rate (with Eatock <i>et al.</i> data) of 31% Median time to progression of 19 weeks Median overall survival of 18 weeks Trial ended early due to toxicity; 3 toxic deaths
Meropol <i>et al.</i>	II	Raltitrexed 3 mg/m <sup>2</sup> q3w 33 patients had gastric cancer 45% of patients received chemotherapy previously	0% response rate (no partial or complete responses) Toxicities were reversible
Schmid <i>et al.</i>	II	Raltitrexed 3 mg/m <sup>2</sup> , oxaliplatin 130 mg/m <sup>2</sup> q3w 21 patients had gastric cancer Second-line chemotherapy	5% response rate (partial response in 1 patient)

q3w, every 3 weeks.

of 32–37 weeks with chemotherapy and 9 weeks without chemotherapy (9). To our knowledge, this is the first case report of raltitrexed being used in gastric cancer treatment as a replacement for fluoropyrimidine on account of cardiotoxicity.

The specific pathophysiology of fluoropyrimidine cardiotoxicity has not been elucidated. Coronary vasospasm has been proposed as one such mechanism, as has direct myocardial toxicity (10–12). A literature review of fluoropyrimidine cardiotoxicity found a 5% mean incidence of cardiotoxicity (3,13). At two United Kingdom centres, 111 gastrointestinal cancer patients, 104 of whom either had cardiovascular risk factors/history prior to chemotherapy or cardiotoxic reactions attributed to fluoropyrimidines, were treated with raltitrexed (3). Five of the 111 patients (4.5%)

had cardiovascular or cerebrovascular complications while on raltitrexed, representing a low rate of vascular events in patients who would otherwise be at risk of fluoropyrimidine cardiotoxicity (3). The ARCTIC study similarly found that, of 42 patients with gastrointestinal cancers who experienced cardiotoxicity on 5-FU/capecitabine, none experienced cardiotoxicity when switched to raltitrexed (4).

While not used in the context of fluoropyrimidine intolerance, raltitrexed has previously been studied in gastric cancer. A literature search of raltitrexed use in gastric cancer was conducted and revealed six results for English-language papers using raltitrexed for gastric cancer. The results have been summarized in *Table 2*. There were two phase I studies (14,15) and four phase II studies (16–19), although two contain patients in the second-line of

treatment. The phase I studies combined raltitrexed, at 3 mg/m<sup>2</sup> every three weeks, with an anthracycline; one study also included cisplatin (14). Mackay reported a phase II study with 21 patients with inoperable and chemotherapy-naïve gastric, esophageal, or gastro-esophageal junction adenocarcinoma with a response rate of 29%, with a median time to progression of 19 weeks and median overall survival of 18 weeks (17). There were three toxic deaths due to sepsis and enteritis and 11 incidents of grade 3 or 4 toxicity (nine of which were neutropenia), prompting the study to be discontinued (17).

The other first-line phase II study enrolled 32 patients with advanced, chemotherapy-naïve gastric or hepatobiliary carcinoma (18). Patients received epirubicin (60 mg/m<sup>2</sup>) and cisplatin (60 mg/m<sup>2</sup>) with raltitrexed—at an increased frequency but ultimately reduced dose compared to other trials—at 1 mg/m<sup>2</sup> on day 1 and 8 of a 3-week cycle. Of the 18 patients with gastric cancer who were assessable, seven had a partial response (35%), with a median duration of 19 weeks (18). There were no toxic deaths or severe infections, with the authors attributing the decreased toxicity to the different dosing used in this regimen (18).

To our knowledge, the case we present is the first report of raltitrexed used as a substitute for fluoropyrimidines following cardiotoxicity in gastric cancer. It is also the first report of raltitrexed being used with trastuzumab for cancer treatment. The PFS was 4.5 months, and the patient did not experience any further cardiotoxicity. Side effects included CTCAE grade 2 myelosuppression, grade 2 anemia, and fatigue. Hypotensive episodes and premature ventricular contractions were not attributed to the chemotherapy or trastuzumab. A limitation of this report is that the pathophysiology of the NSTEMI was not confirmed by cardiac angiography. Progression was seen on imaging with the identification of new metastases in the liver and growth of the previously-imaged lesion. PFS was reduced compared to the ToGA trial median time of 6.7 months with chemotherapy and trastuzumab; however, this outcome is well within the range achieved with the ToGA regimen (trastuzumab, cisplatin, 5-FU chemotherapy).

In summary, raltitrexed appears to be a safe substitute for fluoropyrimidines following cardiotoxicity and can be used with trastuzumab, although further data is needed to comment on its relative effectiveness as part of a regimen involving platinum-based neoplastic agents and, where appropriate, trastuzumab.

## Acknowledgments

*Funding:* None.

## Footnote

*Reporting Checklist:* The authors have completed the CARE reporting checklist. Available at <https://atm.amegroups.com/article/view/10.21037/atm-2022-69/rc>

*Conflicts of Interest:* All authors have completed the ICMJE uniform disclosure form (available at <https://atm.amegroups.com/article/view/10.21037/atm-2022-69/coif>). DAB has provided advisory board participation or received honoraria from Amgen Canada, Bristol-Myers-Squibb, AstraZeneca, Merck and Takeda. The other authors have no conflicts of interest to declare.

*Ethical Statement:* The authors are accountable for all aspects of the work in ensuring that questions related to the accuracy or integrity of any part of the work are appropriately investigated and resolved. All procedures performed in this study were in accordance with the ethical standards of the institutional and/or national research committee(s) and with the Helsinki Declaration (as revised in 2013). The patient provided verbal consent to disseminate his experience with this novel chemotherapy regimen.

*Open Access Statement:* This is an Open Access article distributed in accordance with the Creative Commons Attribution-NonCommercial-NoDerivs 4.0 International License (CC BY-NC-ND 4.0), which permits the non-commercial replication and distribution of the article with the strict proviso that no changes or edits are made and the original work is properly cited (including links to both the formal publication through the relevant DOI and the license). See: <https://creativecommons.org/licenses/by-nc-nd/4.0/>.

## References

1. Capecitabine monograph. BC Cancer Drug Manual. British Columbia, Canada: BC Cancer; 2001-2021:1-9.
2. Fluorouracil monograph. BC Cancer Drug Manual. British Columbia, Canada: BC Cancer; 1994-2021:1-14.
3. Kelly C, Bhuvana N, Harrison M, et al. Use of raltitrexed as an alternative to 5-fluorouracil and capecitabine in

- cancer patients with cardiac history. *Eur J Cancer* 2013;49:2303-10.
4. Ransom D, Wilson K, Fournier M, et al. Final results of Australasian Gastrointestinal Trials Group ARCTIC study: an audit of raltitrexed for patients with cardiac toxicity induced by fluoropyrimidines. *Ann Oncol* 2014;25:117-21.
  5. Kerr DJ. Clinical efficacy of 'Tomudex' (raltitrexed) in advanced colorectal cancer. *Anticancer Drugs* 1997;8 Suppl 2:S11-5.
  6. Birkman EM, Mansuri N, Kurki S, et al. Gastric cancer: immunohistochemical classification of molecular subtypes and their association with clinicopathological characteristics. *Virchows Arch* 2018;472:369-82.
  7. Wörmann B, Bokemeyer C, Burmeister T, et al. Dihydropyrimidine Dehydrogenase Testing prior to Treatment with 5-Fluorouracil, Capecitabine, and Tegafur: A Consensus Paper. *Oncol Res Treat* 2020;43:628-36.
  8. Bang YJ, Van Cutsem E, Feyereislova A, et al. Trastuzumab in combination with chemotherapy versus chemotherapy alone for treatment of HER2-positive advanced gastric or gastro-oesophageal junction cancer (ToGA): a phase 3, open-label, randomised controlled trial. *Lancet* 2010;376:687-97.
  9. Bernards N, Creemers GJ, Nieuwenhuijzen GA, et al. No improvement in median survival for patients with metastatic gastric cancer despite increased use of chemotherapy. *Ann Oncol* 2013;24:3056-60.
  10. Kanduri J, More LA, Godishala A, et al. Fluoropyrimidine-Associated Cardiotoxicity. *Cardiol Clin* 2019;37:399-405.
  11. Mosseri M, Fingert HJ, Varticovski L, et al. In vitro evidence that myocardial ischemia resulting from 5-fluorouracil chemotherapy is due to protein kinase C-mediated vasoconstriction of vascular smooth muscle. *Cancer Res* 1993;53:3028-33.
  12. Matsubara I, Kamiya J, Imai S. Cardiotoxic effects of 5-fluorouracil in the guinea pig. *Jpn J Pharmacol* 1980;30:871-9.
  13. Lakkunarajah S, Breadner DA, Zhang H, et al. The Influence of Adjuvant Chemotherapy Dose Intensity on Five-Year Outcomes in Resected Colon Cancer: A Single Centre Retrospective Analysis. *Curr Oncol* 2021;28:4031-41.
  14. Eatock MM, Anthony DA, El-Abassi M, et al. A dose-finding study of raltitrexed (tomudex) with cisplatin and epirubicin in advanced gastro-oesophageal adenocarcinoma. *Br J Cancer* 2000;82:1925-31.
  15. Bjarnason GA, Charpentier D, Wong R, et al. Phase I study of Tomudex and Doxorubicin in patients with locally advanced, inoperable or metastatic cancer (IND.98). *Invest New Drugs* 2005;23:51-6.
  16. Meropol NJ, Pazdur R, Vincent M, et al. Phase II study of ZD1694 in patients with advanced gastric cancer. *Am J Clin Oncol* 1996;19:628-30.
  17. Mackay HJ, McInnes A, Paul J, et al. A phase II study of epirubicin, cisplatin and raltitrexed combination chemotherapy (ECT) in patients with advanced oesophageal and gastric adenocarcinoma. *Ann Oncol* 2001;12:1407-10.
  18. Ferrari VD, Amoroso V, Valcamonico F, et al. Epirubicin, cisplatin, and raltitrexed in patients with advanced gastric and hepatobiliary carcinoma: a phase II study. *Am J Clin Oncol* 2004;27:445-8.
  19. Schmid KE, Kornek GV, Schüll B, et al. Second-line treatment of advanced gastric cancer with oxaliplatin plus raltitrexed. *Onkologie* 2003;26:255-8.

**Cite this article as:** Ladak I, Preti B, Dias B, Breadner DA. Raltitrexed as a substitute for capecitabine in metastatic gastric cancer: a case report and literature review. *Ann Transl Med* 2022;10(23):1285. doi: 10.21037/atm-2022-69