



A study on the correlation between patellofemoral joint morphology and early patella malacia in young adults: quantitative analysis based on magnetic resonance

Yuefeng Kong, Hanhua Yu

Radiology Department, Wuhan Fourth Hospital, Wuhan, China

Contributions: (I) Conception and design: H Yu; (II) Administrative support: H Yu; (III) Provision of study materials or patients: H Yu; (IV) Collection and assembly of data: Y Kong; (V) Data analysis and interpretation: Y Kong; (VI) Manuscript writing: Both authors; (VII) Final approval of manuscript: Both authors.

Correspondence to: Hanhua Yu. Wuhan Fourth Hospital, Wuhan, China. Email: yuhanhua777@163.com.

Background: The aim of this study was to quantitatively measure the morphology of the patellofemoral joint by magnetic resonance imaging (MRI) in young adults, to investigate the relationship between the morphology of the patellofemoral joint and chondromalacia patellae (CP), and to provide an imaging reference for early clinical diagnosis of CP.

Methods: A total of 57 cases of CP and 138 cases of normal knees were retrospectively collected and assigned to the CP group and control group, respectively. The morphological parameters of the patellofemoral joint were measured systematically. The statistical software SPSS 22.0 was used in correlation analysis. Logistic regression was used for univariate analysis. A P value <0.05 was defined as statistically significant.

Results: Wiberg index, patellar depth, and the lateral angle of the patella in the CP group were significantly lower than those in the control group (P=0.043, 0.001, 0.040, respectively). The width of the medial side of the trochlea, the ratio of the internal and external articular surfaces of the trochlea, the depth of the trochlea, and the inclination angle of the lateral trochlea in the CP group were significantly lower than those in the control group (P=0.003, 0.020, 0.000, 0.040, respectively), whereas the angle of the trochlea in the CP group was significantly higher than that in the control group (P=0.010). The lateral patellofemoral angle (LPA) and lateral patellofemoral contact width in the CP group were significantly lower than those in the control group (P=0.010, 0.010, respectively). In the CP group, with gender as a covariate, there were significant statistical differences between male and female in patellar depth, lateral patellar inclination angle, lateral trochlear inclination (LTI) angle, and lateral patellar contact surface width (P<0.05), whereas in the control group, there were significant differences in Wiberg index, patellar depth, medial trochlear width, and lateral patellofemoral contact surface width between male and female gender (P<0.05).

Conclusions: The prevalence of CP in women was significantly higher than that in men and the reduction of trochlea width and the patella depth is an important factor for the incidence of female CP. Morphological characteristics of the patellofemoral joint are significantly correlated with the occurrence of CP in young adults.

Keywords: Patellofemoral morphological parameters; magnetic resonance (MR); early patella malacia

Submitted Nov 21, 2022. Accepted for publication Jan 03, 2023. Published online Jan 13, 2023.

doi: 10.21037/atm-22-6200

View this article at: <https://dx.doi.org/10.21037/atm-22-6200>

Introduction

Chondromalacia patellae (CP) is one of the most common and important causes of pain syndrome in the anterior region of the knee joint, which was first proposed by Alemen in 1928 according to Ye's report (1). Most patients visit the clinic because they have experienced chronic pain and discomfort in the knee joint area. They are often accompanied by sudden onset of weak legs, false meniscus strangulation, and other symptoms. After exercise, the above symptoms are prone to worsen, especially in young and middle-aged people (18–45 years old) (note: defined by the World Health Organization). The pathological characteristics are mainly degenerative changes such as swelling, cartilage softening, degeneration, fragmentation, and shedding of patellar cartilage caused by various causes (2). As the largest sesamoid bone in our body, the patella plays a key role in the movement function of the knee joint. The biological function of the patella greatly depends on the compatibility of the patellofemoral joint, which is closely related to the morphology and biological performance of the patellofemoral joint (3–5). Although many studies have been conducted on the individual indexes of patella high position and trochlear, they have not been sufficiently systematic. At present, there are few studies on patellofemoral morphology in young adults. Magnetic resonance imaging (MRI) is a non-invasive tool for detecting high soft tissue contrast patellar chondromalacia. At present, the technology is mature. It can display change at the early stage of cartilage degeneration, including irregular signal, fissure, and cartilage thinning. Therefore, it is often used in the early diagnosis of CP (6,7), with an accuracy of 69–97% (8). The need for MRI, an expensive

piece of equipment, and the need for radiologists who specialize in skeletal muscle disease diagnosis contribute to the threshold for diagnosing chondromalacia patellae.

Since the irreversibility of patellar malacia, it is of great clinical significance to focus on how to find out the risk factors and find preventive measures in young adults. The purpose of this study is to systematically and quantitatively measure the morphological parameters of the patellofemoral joint in young and middle-aged people by using MRI technology. We expect to explore the internal relationship between the morphology of the patellofemoral joint and CP through big data analysis, so as to provide reliable imaging reference for the early clinical diagnosis of CP in young and middle-aged people. Different from previous similar reports, with various detailed patellofemoral joint morphology parameters, our research used logistic regression to find out significant risk factors of patellofemoral joint morphology for early patella malacia. We present the following article in accordance with the MDAR reporting checklist (available at <https://atm.amegroups.com/article/view/10.21037/atm-22-6200/rc>).

Methods

Human participants

We retrospectively collected the data of young and middle-aged patients who underwent knee joint MRI examination in the Department of Radiology, Wuhan Fourth Hospital from 30 June 2017 to 31 December 2019. The inclusion criteria of the control group were as follows (9): (I) no history of obvious metabolic immune disease, history of traumatic surgery, and history of space occupying disease of the knee joint; (II) no obvious positive signs and knee joint discomfort; (III) MRI examination showed no obvious lesions, no obvious changes in bone, ligament, cartilage, tendon, and muscle structures around the knee joint, and patellar cartilage was intact. The exclusion criteria were as follows: (I) there were infectious diseases (such as tuberculosis, suppurative bacteria, etc.), metabolic and immune diseases (such as gout, rheumatoid arthritis, lupus erythematosus, etc.), idiopathic diseases, knee surgery history, knee fracture history, or arthroscopy history, and so on; (II) imaging examination showed that there were space occupying lesions, patella dislocation, knee joint trauma, ligament injury, or a large amount of fluid in the joint cavity, and patella softening stage III–IV; (III) we define young adults according to WHO criteria that 'Youth' as the

Highlight box

Key findings

- Reduction of trochlea width and the patella depth is an important factor for the incidence of female patelomalacia.

What is known and what is new?

- Chondromalacia patellae (CP) is one of the most common and important causes of pain syndrome in the anterior region of the knee joint.
- We measured the morphological parameters of patellofemoral joint in young and middle-aged people by using MRI technology.

What is the implication, and what should change now?

- Morphological characteristics of the patellofemoral joint are significantly correlated with the occurrence of CP in young adults.

18–45 year age group. patients aged <18 and >45 years were also excluded. Finally, 57 effective standard cases (n=57) were obtained, including 19 females and 38 males, with an average age of 36.91 ± 5.64 years from 18 to 45 years. We minimized selection bias by trying to use case-matched controls in terms of age, sex, and body mass index (BMI). Finally, 138 cases were included in the control group (n=138), including 58 females and 80 males. The age range was 18 to 45 years, and the average age was 27.07 ± 5.30 years. We carefully analyzed the MRI findings of these cases and measured the relevant parameters reflecting the shape of the patellofemoral joint, focusing on the relationship between the patellofemoral shape and CP. The study was conducted in accordance with the Declaration of Helsinki (as revised in 2013). The study was approved by institutional ethics committee of Wuhan Fourth Hospital (No. KY2022-042-01) and informed consent was taken from all the patients.

Clinical diagnostic criteria and magnetic resonance (MR) staging criteria of CP

The clinical diagnostic criteria of CP were as follows: (I) clinical history: there is usually a history of knee joint injury during semi squatting exercise or after multiple fatigue exercises. (II) Clinical symptoms: (i) knee joint pain or knee joint weakness that is obvious when walking, ascending and descending stairs, and exercising, and can be relieved after rest. The symptoms gradually worsen with the progress of time. In the instance of sudden intense exercise or increased activity, such as running or rapid squatting, patients may even show symptoms such as lameness; (ii) false interlocking: when the human knee joint is in flexion and extension, the knee joint can emit a snapping sound and a feeling of being “stuck”. This symptom is easily mistaken for “meniscus strangulation”; (iii) half squatting pain: the pain is obvious when the knee joint is subject to a half squat, and most of the pain is significantly reduced or even disappears when the knee joint is in a full squat or standing position; (iv) at present, hyperextension pain is generally considered due to the long-term sports-induced wear of the knee joint’s subpatellar fat pad, which leads to reactive thickening of the subpatellar fat pad. (III) clinical physical examination: (i) one foot squat test (100.0%) is positive; (ii) positive patellofemoral compression test (90.4%); (iii) knee extension resistance test is positive (78.0%); (iv) the joint surface friction sound is positive (45.6%); (v) fat pad symptoms (18.6%); (vi) quadriceps femoris atrophy (14.9%);

(vii) joint cavity effusion (12.0%). MR outerbridge staging criteria of CP: (I) in stage I, abnormal changes in signal intensity appear in the local cartilage of patella, but do not extend to the surface of articular cartilage; (II) in phase II, the patellar cartilage becomes thin, the signal changes are uneven, the shape is slightly irregular, and the low signal shadow could extend to the surface of the articular bone; (III) in stage III, there may be brush-like changes on the surface layer of the patellar cartilage or defect-like changes on the cartilage surface. The obvious low signal in the focus area extends to the joint surface, and the subchondral bone may or may not have cystic changes; (IV) in stage IV, there is a full-thickness defect of the patellar cartilage, and the subchondral bone is exposed, with or without abnormal signal changes of the bone at the defect, and there may be bone marrow edema locally. According to Outerbridge staging, patella malacia can be divided into 4 levels, and early patella malacia is defined as level 1–2.

MR technology and image acquisition

We used a 3.0T MR (Magnetom Trio Tim system, Siemens Healthineers, Erlangen, Germany) for scanning, and an 8-channel flexible surface coil for imaging of the knee joint. Cases were scanned in the supine position, with the knee joint fully extended. In principle, the quadriceps femoris of the examinee should be in a relaxed state, and the knee joint should be in a straight position. The scanning range was from 5 cm above the patella to 5 cm below the tibial plateau, including the patella, the corresponding femoral trochlear, and the tibial tubercle. All relevant parameters of this study were measured on the axial map of MR T2 fat pressure sequence of the knee joint. Each parameter data was measured by two attending physicians (including the author) with rich experience in skeletal muscle imaging diagnosis at the same time. Before the measurement, the examinee was not aware of the presence or absence of CP or the related medical history. The average of the two measurements was taken when the measured values were entered. For some data with objection, after negotiation, the third attending physician repeated the measurement several times and took the mean of similar data.

Measurement parameters and methods

For the patella morphological parameters, when the MR axial phase of the knee joint presented the maximum transverse diameter of the patella, the following indexes

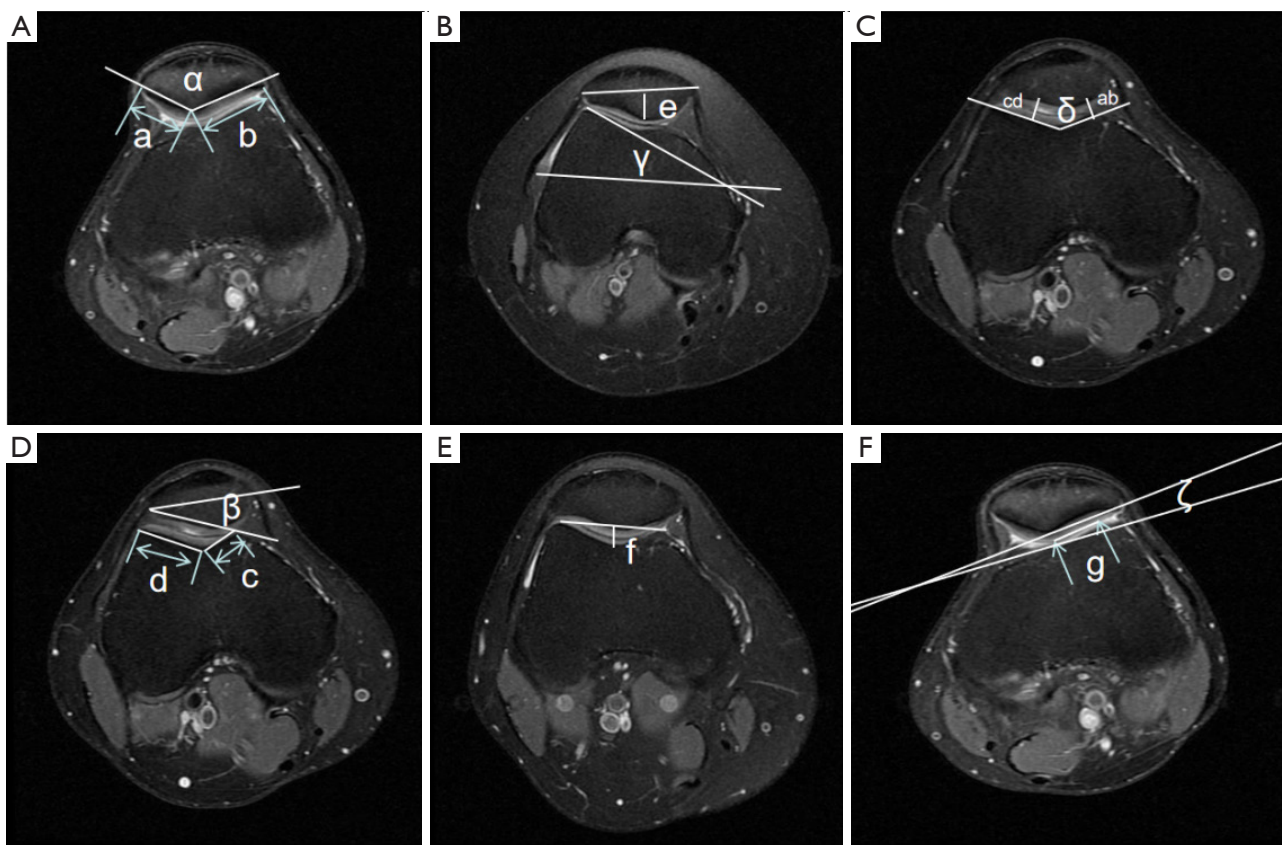


Figure 1 Measurement method of patellofemoral parameters. a: medial articular surface of patella; b: lateral articular surface of patella; c: medial articular surface of trochlea; d: lateral articular surface of trochlea; e: patella depth; f: trochlear depth; g: length of the lateral contact surface of the patellofemoral joint; ab: distance between the narrowest part of the medial surface of patellofemoral joint; cd: distance between the narrowest part of the lateral patellofemoral joint; α : patellar facet angle; β : angle of lateral tilt of patella; γ : lateral trolley inclination; δ : sulcus angle; ζ : lateral patellofemoral angle.

were measured in strict accordance with the following standards. The Wiberg index measures the width (a, b) of the inner and outer articular surfaces of the patella, and a/b is the Wiberg index (see *Figure 1A* for details). Patella depth (PD) refers to the vertical distance e from the inferior pole of the patella to the axis of the maximum transverse diameter of the patella (see *Figure 1B* for details). Patellar face angle (α) refers to the angle a between the inner and outer sides of the patella (see *Figure 1A* for details). The sulcus angle (SA) was the included angle δ between the inner articular surface and the outer articular surface of the trochlear of the femur (see *Figure 1C* for details). Angle of lateral tilt of patella (ALTP) was the included angle β between the maximum transverse diameter axis of patella and the lateral articular surface of patella (see *Figure 1D* for details).

As for the morphological parameters of the trochlear of the femur, in the MR axial phase of the knee joint, the trochlear plane at the proximal level of the trochlear of the femur where the cartilage was completely covered was taken as the baseline, and the subchondral bone plate (low signal) was taken as the baseline. The medial lateral facet ratio of femoral trochlea (MLRT) is the width ratio between the medial facet (c) and lateral facet (d) of the trochlea (see *Figure 1D* for details). Trochlear depth (TD) comprised a vertical line from the lowest point of the trochlear of the femur to the highest point of the medial and lateral condyles of the anterior condyle of the femur. The distance length of the vertical line is the TD (f) (see *Figure 1E* for details). The lateral trochlear inclination (LTI) indicated a straight line from the medial and lateral condyles of the posterior condyle of the femur. The included angle between the joint

Table 1 Comparison of prevalence rates by genders

Gender	CP	Total	Positive rate (%)
Male	19	99	19.19
Female	38	96	39.58
Total	57	195	29.23

$\chi^2=9.797$, $Pr=0.002$. CP, chondromalacia patellae.

surface of the lateral trochlear of the femur and the straight line was the angle γ (see *Figure 1B* for details).

For the morphological parameters related to both the patella and femur, the lateral patellofemoral angle (LPA) was the included angle ζ formed by the line from the highest point of the anterior and lateral condyles of the femur and the extension line of the line from the lateral side of the patella (see *Figure 1F* for details). Patellofemoral index (PFI) measures the distance *ab* between the narrowest part of the medial surface of the patellofemoral joint and the distance *cd* between the narrowest part of the lateral surface. The ratio of *ab/cd* is the PFI (see *Figure 1C* for details). Length of the lateral contact surface of the patellofemoral joint (LSPJ): the length *g* of the contact between the patella and the lateral cartilage of the trochlear (see *Figure 1F* for details).

Statistical analysis

All original data in this paper were collected and organized in Excel (Microsoft, Redmond, WA, USA). All MR measurements were expressed in (mean \pm standard deviation). The statistical software SPSS 22.0 (IBM Corp., Armonk, NY, USA) was used for data analysis, such as counting data, which can be C2 tested, and independent sample *t*-test was used for measuring data meeting the requirements of normal distribution; Logistic regression was used for univariate analysis. In the process of model fitting, age and sex were added. A *P* value <0.05 was defined as statistically significant, that is, there was significant correlation between the two groups.

Results

Baseline data

A total of 195 cases were collected in this study, and 57 were diagnosed with CP, including 19 males and 38 females; there were 138 cases in the control group (i.e., normal

group), including 80 males and 58 females.

In this study, the male positive rate was about 19.19% and the female positive rate was about 39.58% in the CP group. The total positive rate was about 29.23%. The 4-grid table is drawn as follows (*Table 1*).

Relationship between patella morphology and patella softening

The widths of the medial and lateral articular surfaces of the patella softening group were 18.57 ± 1.94 and 26.62 ± 2.36 mm, respectively, whereas the widths of the medial and lateral articular surfaces of the patella in the normal group were 19.09 ± 1.73 and 26.28 ± 2.49 mm, respectively. There was no statistical difference between the two groups; The Wiberg index of the patella softening group and the control group were 0.70 ± 0.08 and 0.73 ± 0.09 respectively. The Wiberg index of the patella softening group was lower than that of the control group ($P=0.043$), and there was a significant difference between the two groups. The patella depth in the patella softening group was 10.38 ± 1.07 mm, and that in the control group was 9.67 ± 1.19 mm. There was a significant difference between the two groups ($P=0.001$), that is, the patella depth in the patella softening group was less than that in the clinical normal group. The lateral inclination angle of the patella in the patella softening group was 23.32 ± 2.84 , and that in the control group was 24.45 ± 2.94 . There was a significant difference between the two groups ($P=0.040$). The lateral inclination angle of the patella in the patella softening group was significantly lower than that in the normal group. However, the patella face angle of the CP and the control group were 132.13 ± 6.31 and 131.59 ± 6.30 , respectively, with no significant difference ($P=0.649$) (*Table 2*).

Relationship between femoral trochlear morphology and patella softening

The control group and the patella softening group had significant statistical differences in the ratio of the internal and external articular surfaces of the trochlear of the femur ($P=0.020$), the depth of the trochlear groove ($P=0.000$), the angle of the trochlear groove ($P=0.010$), and the inclination angle of the lateral trochlear ($P=0.040$). Although the angle of the trochlear groove of the patella softening group was greater than that of the control group, the depth of the trochlear groove was less than that of the control group, and the inclination angle of the lateral trochlear was

Table 2 Comparison of measurement results of patella morphology parameters

Patella measurement	Control (N=138)	CP (N=57)	t value	P value
Wiberg index	0.73±0.09	0.70±0.08	2.045	0.043
Patella depth (mm)	10.38±1.07	9.67±1.19	3.345	0.001
Patellar facial angle (°)	131.59±6.30	132.13±6.31	-0.456	0.649
Lateral inclination angle of patella (°)	24.45±2.94	23.32±2.84	2.082	0.040

The data are shown as mean ± standard deviation. CP, chondromalacia patellae.

Table 3 Comparison of measurement results of morphologic parameters

Morphology parameters	Control (N=138)	CP group (N=57)	t value	P value
Width of inner side of pulley (mm)	13.57±2.52	12.32±1.89	3.008	0.003
Width of outer side of pulley (mm)	22.77±2.29	22.67±2.52	-0.745	0.458
Ratio of inner and outer articular surfaces of trochlear	0.60±0.13	0.55±0.11	2.312	0.020
Pulley depth (mm)	4.25±1.20	3.66±0.90	2.937	0.000
Sulcus angle (°)	149.05±8.02	152.84±8.05	-2.516	0.010
Inclination angle of outer pulley (°)	18.40±4.91	16.70±3.98	2.027	0.040

The data are shown as mean ± standard deviation. CP, chondromalacia patellae.

Table 4 Comparison of measurement results of patellofemoral joint parameters

Patellofemoral joint parameters	Control (N=138)	CP group (N=57)	t value	P value
Lateral patellofemoral angle (°)	6.83±3.66	5.22±3.04	2.544	0.010
Patellofemoral index	1.08±0.42	1.16±0.67	-0.707	0.480
Width of lateral patellofemoral contact surface (mm)	20.72±2.16	19.58±2.39	2.682	0.010

The data are shown as mean ± standard deviation. CP, chondromalacia patellae.

significantly less than that of the control group. The ratio between the internal and external articular surfaces of the femoral trochlear was less than that of the control group. The widths of the inner side of the trochlear in the patella softening group and the control group were 12.32±1.89 and 13.57±2.52 mm, respectively, with significant difference; however, the lateral widths of the trochlear in the patella softening group and the control group were 22.67±2.52 and 22.77±2.29 mm, respectively. There was no statistical difference between the two groups (Table 3).

Relationship between the parameters related to patellofemoral morphology and patella softening

The width of the lateral patellofemoral contact surface in the control group was 20.72±2.16 mm, whereas the

lateral contact surface in the patella softening group was 19.58±2.39 mm; the LPA of the patella softening group was significantly lower than that of the control group. There was no statistical difference in PFI between the two groups (Table 4).

Relationship between gender and patellofemoral morphological parameters

We used gender and disease as covariates to analyze patellofemoral parameters with significant differences, such as Wiberg index, patella depth, TD, lateral inclination angle of patella, lateral width of trochlear, and trochlear internal and external relations.

The pitch ratio, the angle of the trochlear groove, the inclination angle of the lateral trochlear, the lateral

Table 5 Gender grouping of related parameters in the CP group

Morphology parameters	Female	Male	t value	P value
Wiberg index	0.70±0.09	0.70±0.06	-0.059	0.953
Patella depth (mm)	9.34±1.08	10.30±1.16	-3.069	0.003
Lateral inclination angle of patella (°)	24.00±2.60	22.00±2.87	2.63	0.011
Width of inner side of pulley (mm)	12.02±1.79	12.89±1.98	-1.665	0.102
Ratio of inner and outer sides of pulley	0.56±0.11	0.54±0.11	0.498	0.621
Pulley depth (mm)	3.66±0.99	3.68±0.70	-0.071	0.943
Sulcus angle (°)	152.35±9.04	153.79±5.75	-0.63	0.532
Inclination angle of outer pulley (°)	17.69±3.93	14.76±3.40	2.888	0.006
Lateral patellofemoral angle (°)	5.17±3.29	5.32±2.56	-0.185	0.854
Width of contact surface of lateral patella (mm)	18.93±2.36	20.84±1.91	-3.032	0.004

The data are shown as mean ± standard deviation. CP, chondromalacia patellae.

Table 6 Gender grouping comparison of patellofemoral parameters in the control group

Patellofemoral morphology parameters	Female	Male	t value	P value
Wiberg index	0.76±0.08	0.70±0.09	2.799	0.007
Patella depth (mm)	9.83±0.98	10.91±0.88	-4.408	0.000
Lateral inclination angle of patella (°)	24.59±3.06	24.31±2.85	0.355	0.724
Width of inner side of pulley (mm)	12.44±2.22	14.71±2.31	-3.804	0.000
Ratio of inner and outer sides of pulley	0.57±0.12	0.63±0.12	-1.893	0.064
Pulley depth (mm)	4.01±1.14	4.48±1.22	-1.539	0.129
Sulcus angle (°)	148.52±8.45	149.59±7.68	-0.504	0.616
Inclination angle of outer pulley (°)	18.31±5.02	18.48±4.88	-0.133	0.895
Lateral patellofemoral angle (°)	7.17±4.16	6.48±3.11	0.715	0.478
Width of contact surface of lateral patella (mm)	19.76±1.66	21.68±2.21	-3.032	0.000

The data are shown as mean ± standard deviation.

patellofemoral angle, and the width of the lateral patellofemoral contact surface were further analyzed. In the patella softening group, with gender as the covariate, there were significant statistical differences between men and women in patella depth, lateral patella inclination angle, LTI angle, and lateral patella contact surface width ($P<0.05$) (Table 5).

In the control group, there were significant differences between men and women only in the Wiberg index, patella depth, width of the medial side of the trochlear, and width of the lateral patellofemoral contact surface ($P<0.05$) (Table 6).

Univariate analysis of risk factors

Logistic regression was used for univariate analysis. In the process of model fitting, age and sex were added. The results showed that the angle of trochlear groove was a harmful factor for patella softening; patella depth, LPA, LTI angle, TD, and lateral width of trochlear are beneficial factors for CP (Table 7).

Discussion

Patella malacia refers to the edema, hardening,

Table 7 Logistic regression results

Morphology parameters	OR (95% CI)	P value
Sulcus angle	1.05 (0.99, 1.13)	0.03063*
Patella depth	0.54 (0.29, 0.94)	0.0382*
Lateral patellofemoral angle	0.84 (0.71, 0.98)	0.0312*
Inclination angle of outer pulley	0.87 (0.76, 0.99)	0.0414*
Pulley depth	0.7 (0.42, 1.13)	0.0399*
Width of inner side of pulley	0.79 (0.6, 1.01)	0.04295*
Width of medial articular surface of patella	1.03 (0.76, 1.4)	0.8688
Wiberg index	0 (0, 0)	0.999
Width of lateral patellofemoral contact surface	0.86 (0.66, 1.09)	0.2237
Patellar facial angle	1.08 (0.99, 1.19)	0.1077
Lateral inclination angle of patella	0.84 (0.68, 1.02)	0.0896
Patellofemoral index	0.99 (0.39, 2.52)	0.978
Width of outer side of pulley	1.05 (0.84, 1.32)	0.6506
Ratio of inner and outer sides of pulley	0 (0, 0)	0.999

*P<0.05. OR, odds ratio; CI, confidence interval.

fragmentation, degeneration, and other changes of the patella cartilage caused by external force on the patella or forces arising from the body itself. It often causes clinical related symptoms such as limited knee flexion and extension activities and pain. It is the most common cause of patellofemoral joint pain. Due to the limitation of medical level and cognition, CP has long been neglected by outpatient doctors, or is often mistaken as just knee osteoarthritis or simply classified as the so-called “pre patellar pain syndrome” without systematic and in-depth follow-up observation, treatment and research. Lu and other (10) researchers have confirmed that the incidence rate of CP gradually increases with the age, increases significantly in people over 50 years old, and there is no significant difference in gender. Su *et al.* (11) reported that the incidence rate of people over 60 years old is as high as 65.12%, which is consistent with the research results of Xu (12) and Duran *et al.* (13), that is, the patellofemoral joints of middle-aged and elderly people (especially after menopause) have different degrees of softening and degeneration. Young and middle-aged people (18–45 years old, according to the classification standard of the World Health Organization) are the bulk and core of social construction. However, there are few studies on the shape of patellofemoral joint and patella softening in young and

middle-aged people. Therefore, this paper intended to select people aged 18–45 years for observation.

In this study, we found through statistical analysis that the incidence rate of CP is high in young and middle-aged people, with an overall positive rate of 29.23%, which may be related to the fact that this study set the population as middle-aged and young people and excluded the injured population. However, it still conforms to the characteristics of high incidence rate of CP mentioned in relevant reports in China and internationally (1-3). Meanwhile, in this study, the positive rate of CP in young and middle-aged women was as high as 39.58%. In contrast, the positive rate of CP in men was only 19.19%, and the prevalence rate of men was significantly lower than that of women. The difference between the two genders was statistically significant (P=0.002), which was consistent with the studies of Lu (10) and Duran (13), that is, the positive rate of women was significantly higher than that of men. Previous researches (12-14) believe that this is closely related to the particularity of the anatomical structure of female patients. The female pelvis is generally wide, so the space between the anterior superior iliac spine is relatively large. The Q angle of the lower limbs of the human body increases with the increase of the space between the anterior superior iliac spine. The increased Q angle causes the external vector deflection

force of the patella to increase. Therefore, compared with men, the female patella is more prone to tilt and lateral subluxation. When the patella is inclined and subluxed, the pressure distribution between the patellofemoral joint surfaces is not uniform, and the pressure will be relatively concentrated on the lateral joint surface of the patella, resulting in the destruction and wear of the softening surface of the patella and the damage and softening of the articular cartilage.

At present, the etiological study of CP is not clear. Most researchers tend to relate the biomechanical function disorder of the patellofemoral joint due to various factors, such as knee joint trauma, patellofemoral instability, cartilage dystrophy, and so on (6,12,14). The abnormal morphology of the patellofemoral joint can destroy the stability of the patellofemoral joint, so that the pressure distribution on the cartilage surface of the patellofemoral joint is not uniform, and the wear and softening of the patellar cartilage are aggravated. Many previous studies had investigated the correlation between patella position and CP. Researchers such as Chareancholvanich (15) confirmed that there is a significant correlation between high patella and adult CP, and its index is one of the reliable indicators suitable for evaluating CP. The patella and femoral trochlea are the main components of the coordinated operation of the patellofemoral joint. At present, there are few relevant studies. This study focused on measuring the main parameters reflecting the shape of the patellofemoral joint, and analyzed and discussed whether the relevant morphological parameters are related to CP.

The Wiberg classification of the patella, as a classic classification of the patella, was proposed by the famous medical scientist Wiberg in 1941. By collecting a large number of samples and analyzing them under the 30° axial radiograph of patella, he divided the joint surface of patella into types I, II, and III according to the difference in morphology. Soon Baumgartl added the fourth type, since then, this classification has been followed as an international classic classification (16). In the Wiberg classification, from type I to type IV, the medial articular surface of the patella gradually becomes smaller, and the lateral articular surface gradually becomes larger. Type I patella: the medial and lateral articular surfaces are slightly depressed, and the articular surfaces on both sides are basically symmetrical and roughly the same size; Type III and type IV patella: the lateral articular surface is mainly, and the medial articular surface is slightly convex; Type II patella: the shape is among the above. Wiberg believes that in type I–II patella,

because the inner and outer cartilage surfaces are relatively close, the center of gravity of the patella crest is close to the middle of the patella, so that the track of the patella movement is stable under the action of static and dynamic stability factors. However, the inner cartilage surface of type III patella is narrow and the outer cartilage surface is significantly wider, which makes the center of gravity of the central ridge of the patella biased toward the inner side, so the LPA is small, thus driving the patella to be easily dislocated outward (16–18). In this study, the Wiberg index of the patella softening group was 0.70 ± 0.08 , which was significantly lower than that of the control group 0.73 ± 0.09 ($t=2.045$, $P=0.043$). Therefore, we can consider that the patella of the patella softening group belongs to unstable patella.

Hunter *et al.* (19) confirmed that abnormal patellar position plays a very important role in the pathogenesis of CP. The lateral inclination angle of the patella is helpful to evaluate the lateral stability mechanism of the patella. With the increasing of the lateral patellar tilt angle, the lateral patellar tilt angle and the LPA decrease gradually. Kalichman *et al.* (20) showed that the lateral inclination angle of patella was negatively correlated with the loss of patellar cartilage. Many studies have confirmed that the lateral displacement of the patella is related to the patellofemoral cartilage lesions, but this study did not measure the lateral inclination angle of the patella, the LPA and the patella depth (19–21). Our literature search showed that there is no quantitative measurement based on MRI to study the relationship between the lateral patellar inclination angle, LPA, patellar depth, and patellar chondromalacia. We have shown that the inclination angle of the lateral side of the patella and the lateral patellofemoral angle of the patella in patients with CP are decreased, and the patella depth is decreased ($P<0.05$), which indicates that the patella shape of the CP group is more flat than that of the normal group. In this study, we also studied the patella facial angle, and there was no significant difference between the CP group and the normal group ($P>0.05$). This research result is consistent with previous studies (21–23). The PFI is defined as the ratio between the shortest distance between the medial patellofemoral joint space and the shortest distance between the lateral patellofemoral joint. This index mainly reflects the patella tilt. In this study, there was no significant difference in PFI between the softening group and the control group ($P>0.05$), which can be interpreted as that the PFI has nothing to do with patella softening. However, there are no other relevant reports, and further

research is needed.

At present, relevant studies have shown that femoral trochlear dysplasia is one of the main risk factors for patellofemoral joint disease (22-24). Trochlear dysplasia will reduce the stability of the patellofemoral joint, lead to the instability of patella and dislocation of patella, as well as the disorder of patellofemoral joint function, and finally lead to irreversible damage of patellar cartilage (24). Previous literature suggests that the trochlear morphological parameters such as the ratio of the inner and outer articular surfaces of the trochlear, the angle of the trochlear groove, the depth of the trochlear groove, and the inclination angle of the lateral trochlear can reflect the development of the trochlear (24-26).

We reviewed the relevant literature and found that there are very few studies on the ratio of the internal and external articular surfaces of the trochlear. In this study, we found that compared with the control group, the ratio of the inner and outer articular surfaces of the trochlear and the width of the inner side of the trochlear in the CP group were significantly smaller than those in the control group. However, there was no statistical difference between the two groups in the width of the outer side of the trochlear ($P < 0.05$), which suggested that the smaller ratio of the inner and outer articular surfaces of the trochlear in the CP group was mainly caused by the smaller width of the inner side of the trochlear. In this case, the width of the lateral patellofemoral contact surface will increase, and the friction force it receives will increase correspondingly when the joint moves. In this study, the width of the lateral patellofemoral contact surface of the CP group and the control group was 19.58 ± 2.39 and 20.72 ± 2.16 mm, respectively. There was a statistically significant difference between the 2 ($P < 0.05$). Therefore, patella softening was more common on the lateral articular surface, which was consistent with the clinical observation.

In the research related to trochlear dysplasia, many researchers have found that the shallow trochlear groove is significantly related to the instability of the patella. The angle of the femoral trochlear groove was the included angle between the medial articular surface and the lateral articular surface of the femoral trochlear, which reflected the degree of trochlear dysplasia and the gradient of the trochlear groove (26). Previous imaging studies have shown that there is a correlation between wide trochlear groove angle and CP (27-29). At present, there are few MRI studies evaluating the correlation between trochlear dysplasia and chondromalacia, and the conclusions are inconsistent. Endo

et al. considered that there was no correlation between TD and chondromalacia patella, but Tuna *et al* held the opposite attitude (22,23). According to the analysis of Yang and others, the angle of trochlear groove is not related to the injury of patellar cartilage, but the shallow femoral trochlear groove can increase the risk of CP (21). Ali Syed and other researchers have found that the two morphological parameters of TD and trochlear groove angle were significantly correlated with severe patellar cartilage injury under the age of 40 years, but not with mild patellar cartilage injury (28). The relevant data of this study show that the angle of the trochlear groove of the CP group is significantly greater than that of the control group, and the depth of the trochlear is significantly less than that of the control group, which suggests that CP may be related to the increase of the angle of the trochlear groove and the decrease of the depth of the trochlear. From the perspective of human structural mechanics, when the angle of the trochlear groove increases and the depth of the trochlear decreases, the limiting force of the patella by the femoral condyles and external condyles will be reduced. In this case, the patella easily loses stability, and the uneven stress will make the patella more prone to tilt, even subluxation, resulting in the injury and softening of the patellar cartilage. The big data study on osteoarthritis by Kalichman and others has also confirmed this point (20). The LTI angle is often used to evaluate the development of the lateral condyle of the femur. At present, there is no definite conclusion on the correlation between the LTI angle and the patellar cartilage injury. Stefanik and other researchers have asserted that the LTI angle is significantly related to the patellar cartilage injury, but this is just opposite to the conclusion of previous reports (29-34). In this study, the LTI angle of the control group was significantly greater than that of the CP group, which was consistent with Stefanik's conclusion. After analysis, we believe that the inclination angle of the lateral trochlear is less developed than that of the lateral condyle of the femur, and that the lateral condyle of the femur has less binding force on the lateral displacement of the patella, so the patella is more likely to move laterally, resulting in cartilage damage and softening.

The overall positive rate of CP in this study was 29.23%, of which the positive rate of women was 39.58%, and that of men was 19.19%. The positive rate of CP in women was significantly higher than that in men. We further analyzed the patellofemoral morphological parameters with significant statistical differences and found that in the control group, the width of the inner side of the trochlear

was significantly smaller in women than in men; at the same time, both in the control group and the CP group, the depth of the patella and the width of the lateral patella contact surface of women were significantly smaller than that of men. According to the data of this study, we can speculate that compared with men, women have a shallower patella depth and a narrower width of the inner side of the trochlear, and the patellofemoral joint is in a shallow and flat state. In this case, as the stress on the outer side of the patellofemoral joint increases, the width of the lateral contact surface of the patellofemoral joint also increases, and the friction force on the patellofemoral joint will increase correspondingly during the movement, so that the lateral patellar cartilage of women is more vulnerable to damage, leading to a significant increase in the incidence rate of CP. To our knowledge, these imaging reference parameters are widely applied in clinical and the research and development of the application is imperative.

Conclusions

The inclination angle of the lateral side of the patella and the lateral contact surface of the patellofemoral, as newly proposed indicators, are significantly reduced in patients with CP, and can be used to evaluate the diagnosis of CP together with other relevant patellofemoral joint morphological parameters. The data of this study show that the prevalence rate of women is significantly higher than that of men, and the width of the inner side of the trochlear and the depth of the patella are significantly reduced in women, suggesting that this is an important factor leading to the better incidence of female CP. Our results showed that the morphological characteristics of patellofemoral joint were significantly correlated with the occurrence of CP in young adults.

Acknowledgments

Funding: This study was supported by Health Research Foundation of Wuhan (No. WX19D25).

Footnote

Reporting Checklist: The authors have completed the MDAR reporting checklist. Available at <https://atm.amegroups.com/article/view/10.21037/atm-22-6200/rc>

Data Sharing Statement: Available at <https://atm.amegroups.com/article/view/10.21037/atm-22-6200/dss>

Conflicts of Interest: Both authors have completed the ICMJE uniform disclosure form (available at <https://atm.amegroups.com/article/view/10.21037/atm-22-6200/coif>). The authors have no conflicts of interest to declare.

Ethical Statement: The authors are accountable for all aspects of the work in ensuring that questions related to the accuracy or integrity of any part of the work are appropriately investigated and resolved. The study was conducted in accordance with the Declaration of Helsinki (as revised in 2013). The study was approved by institutional ethics committee of Wuhan Fourth Hospital (No. KY2022-042-01) and informed consent was taken from all the patients.

Open Access Statement: This is an Open Access article distributed in accordance with the Creative Commons Attribution-NonCommercial-NoDerivs 4.0 International License (CC BY-NC-ND 4.0), which permits the non-commercial replication and distribution of the article with the strict proviso that no changes or edits are made and the original work is properly cited (including links to both the formal publication through the relevant DOI and the license). See: <https://creativecommons.org/licenses/by-nc-nd/4.0/>.

References

1. Ye Q, Wu Z, Wang Y, et al. Etiology, diagnosis and treatment of patella malacia. *Journal of Chinese Academy of Medical Sciences* 2001;(2):181-3.
2. Ruiz Santiago F, Pozuelo Calvo R, Almansa López J, et al. T2 mapping in patellar chondromalacia. *Eur J Radiol* 2014;83:984-8.
3. Cross M, Smith E, Hoy D, et al. The global burden of hip and knee osteoarthritis: estimates from the global burden of disease 2010 study. *Ann Rheum Dis* 2014;73:1323-30.
4. Wang B, Xing D, Dong S, et al. Systematic review on epidemiology and disease burden of knee osteoarthritis in China. *Chinese Journal of Evidence Based Medicine* 2018;18:134-42.
5. Sheehan FT, Derasari A, Brindle TJ, et al. Understanding patellofemoral pain with maltracking in the presence of joint laxity: complete 3D in vivo patellofemoral and

- tibiofemoral kinematics. *J Orthop Res* 2009;27:561-70.
6. Tabary M, Esfahani A, Nouraie M, et al. Relation of the chondromalacia patellae to proximal tibial anatomical parameters, assessed with MRI. *Radiol Oncol* 2020;54:159-67.
 7. Hing C, Raleigh E, Bailey M, et al. A prospective study of the diagnostic potential of the knee tunnel view radiograph in assessing anterior knee pain. *Knee* 2007;14:29-33.
 8. Recht MP, Piraino DW, Paletta GA, et al. Accuracy of fat-suppressed three-dimensional spoiled gradient-echo FLASH MR imaging in the detection of patellofemoral articular cartilage abnormalities. *Radiology* 1996;198:209-12.
 9. Qu M, Yu C. *Practical sports medicine*. 4th Edition Beijing: Peking University Press, 2003:795.
 10. Lu W. Study on the correlation between patella position and patella malacia. Fudan University, 2008.
 11. Su P, Zhang H. Study on the correlation between patellar tilt, patellar subluxation and patella malacia. *Chinese Journal of Orthopaedic Surgery* 2014;22:1365-68.
 12. Xu X, Gao J, Liu S, et al. Magnetic resonance imaging for non-invasive clinical evaluation of normal and regenerated cartilage. *Regen Biomater* 2021;8:rbab038.
 13. Duran S, Cavusoglu M, Kocadal O, et al. Association between trochlear morphology and chondromalacia patella: an MRI study. *Clin Imaging* 2017;41:7-10.
 14. Damgaci L, Özer H, Duran S. Correction to: Patella-patellar tendon angle and lateral patella-tilt angle decrease patients with chondromalacia patella. *Knee Surg Sports Traumatol Arthrosc* 2020;28:2722.
 15. Chareancholvanich K, Narkbunnam R. Novel method of measuring patellar height ratio using a distal femoral reference point. *Int Orthop* 2012;36:749-53.
 16. Yan G. Morphology and thickness of patella. *Chinese Journal of Joint Surgery: Electronic Edition* 2016;10:1.
 17. Argenson JN, Guillaume JM, Aubaniac JM. Is there a place for patellofemoral arthroplasty? *Clin Orthop Relat Res* 1995;(321):162-7.
 18. Reider B, Marshall JL, Koslin B, et al. The anterior aspect of the knee joint. *J Bone Joint Surg Am* 1981;63:351-6.
 19. Hunter DJ, Zhang YQ, Niu JB, et al. Patella malalignment, pain and patellofemoral progression: the Health ABC Study. *Osteoarthritis Cartilage* 2007;15:1120-7.
 20. Kalichman L, Zhang Y, Niu J, et al. The association between patellar alignment and patellofemoral joint osteoarthritis features--an MRI study. *Rheumatology (Oxford)* 2007;46:1303-8.
 21. Yang B, Tan H, Yang L, et al. Correlating anatomy and congruence of the patellofemoral joint with cartilage lesions. *Orthopedics* 2009;32:20.
 22. Endo Y, Schweitzer ME, Bordalo-Rodrigues M, et al. MRI quantitative morphologic analysis of patellofemoral region: lack of correlation with chondromalacia patellae at surgery. *AJR Am J Roentgenol* 2007;189:1165-8.
 23. Tuna BK, Semiz-Oysu A, Pekar B, et al. The association of patellofemoral joint morphology with chondromalacia patella: a quantitative MRI analysis. *Clin Imaging* 2014;38:495-8.
 24. Rebolledo BJ, Nam D, Cross MB, et al. Familial association of femoral trochlear dysplasia with recurrent bilateral patellar dislocation. *Orthopedics* 2012;35:e574-9.
 25. Diederichs G, Issever AS, Scheffler S. MR imaging of patellar instability: injury patterns and assessment of risk factors. *Radiographics* 2010;30:961-81.
 26. Pfirrmann CW, Zanetti M, Romero J, et al. Femoral trochlear dysplasia: MR findings. *Radiology* 2000;216:858-64.
 27. Davies AP, Costa ML, Shepstone L, et al. The sulcus angle and malalignment of the extensor mechanism of the knee. *J Bone Joint Surg Br* 2000;82:1162-6. Erratum in: *J Bone Joint Surg Br* 2001;83:777.
 28. Ali SA, Helmer R, Terk MR. Analysis of the patellofemoral region on MRI: association of abnormal trochlear morphology with severe cartilage defects. *AJR Am J Roentgenol* 2010;194:721-7.
 29. Mehl J, Feucht MJ, Bode G, et al. Association between patellar cartilage defects and patellofemoral geometry: a matched-pair MRI comparison of patients with and without isolated patellar cartilage defects. *Knee Surg Sports Traumatol Arthrosc* 2016;24:838-46.
 30. Zheng X, Shi J, Wu J. Analysis of factors and corresponding interactions influencing clinical management assistant ability using competency model in China. *Medicine (Baltimore)* 2020;99:e23516.
 31. Xia F, Li Q, Luo X, et al. Association between urinary metals and leukocyte telomere length involving an artificial neural network prediction: Findings based on NHANES 1999-2002. *Front Public Health* 2022;10:963138.
 32. Xia F, Li Q, Luo X, et al. Machine learning model for depression based on heavy metals among aging people: A study with National Health and Nutrition Examination Survey 2017-2018. *Front Public Health* 2022;10:939758.
 33. Xia F, Li Q, Luo X, et al. Identification for heavy metals exposure on osteoarthritis among aging people

- and Machine learning for prediction: A study based on NHANES 2011-2020. *Front Public Health* 2022;10:906774.
34. Stefanik JJ, Roemer FW, Zumwalt AC, et al. Association between measures of trochlear morphology and structural

features of patellofemoral joint osteoarthritis on MRI: the MOST study. *J Orthop Res* 2012;30:1-8.

(English Language Editor: J. Jones)

Cite this article as: Kong Y, Yu H. A study on the correlation between patellofemoral joint morphology and early patella malacia in young adults: quantitative analysis based on magnetic resonance. *Ann Transl Med* 2023;11(2):48. doi: 10.21037/atm-22-6200