



# ProtekDuo percutaneous ventricular support system – physiology and clinical applications

Kevin John John<sup>1</sup>, Christoph G. S. Nabzdyk<sup>2</sup>, Haval Chweich<sup>3</sup>, Ajay Kumar Mishra<sup>4</sup>, Amos Lal<sup>5^</sup>

<sup>1</sup>Department of Medicine, Tufts Medical Center, Boston, MA, USA; <sup>2</sup>Biomedical Innovation and Translation, Critical Care & Cardiac Anesthesia, Brigham and Women's Hospital, Harvard Medical School, Boston, MA, USA; <sup>3</sup>Division of Pulmonary, Critical Care, and Sleep Medicine, Tufts Medical Center, Boston, MA, USA; <sup>4</sup>Department of Cardiovascular Medicine, Saint Vincent Hospital, Worcester, MA, USA; <sup>5</sup>Division of Pulmonary and Critical Care Medicine, Department of Medicine, Mayo Clinic, Rochester, MN, USA

*Contributions:* (I) Conception and design: All authors; (II) Administrative support: All authors; (III) Provision of study materials or patients: All authors; (IV) Collection and assembly of data: All authors; (V) Data analysis and interpretation: All authors; (VI) Manuscript writing: All authors; (VII) Final approval of manuscript: All authors.

*Correspondence to:* Amos Lal, MBBS, MD, MS, FACP. Division of Pulmonary and Critical Care Medicine, Department of Medicine, Mayo Clinic, 200 1st St. SW, Rochester, MN 55905, USA. Email: Lal.Amos@mayo.edu; manavamos@gmail.com.

**Abstract:** The ProtekDuo (LivaNova, London, UK) cannula is a dual-lumen device, typically inserted into the right internal jugular (IJ) vein through a percutaneous approach, with fluoroscopy or ultrasound guidance. When connected to a pump, such as the TandemHeart (LivaNova, London, UK) or CentriMag (Abbott, Pleasanton, CA, USA), it can function as a right ventricular (RV) mechanical circulatory support (MCS). When an oxygenator is also added [veno-pulmonary (V-P)], it can provide extracorporeal membrane oxygenation (ECMO) support. This review aims to provide a comprehensive overview of the device's physiology and clinical applications. In the setting of RV failure (RVF), the ProtekDuo cannula, with its outflow in the main pulmonary artery (PA), can bypass the failing RV, improving pulmonary flow, left atrial (LA) filling pressures, and left ventricular (LV) preload. This can also reduce ventricular interdependence and leftward shift of the interventricular septum that occurs in RVF. In this review, the key sections expand on the use of the ProtekDuo cannula in the management of critically ill patients, specifically, the use of ProtekDuo for RV myocardial infarction (MI) RVF, LV assist device (LVAD) implantation-associated RVF, RVF post-heart transplantation, temporary biventricular MCS as bridge to recovery (ECpella 2.0 or PROpella), biventricular support as bridge to recovery or decision, isolated LV failure, post lung transplantation (LT) care, and other miscellaneous clinical scenarios. ProtekDuo is an important tool in the armory of RVF management. The ProtekDuo system is expected to gain more popularity given its clear advantages such as groin-free approach allowing for mobility, easy percutaneous deployment, compatibility with various pumps and oxygenators, and the versatility to be integrated in numerous configurations. In an era of expanding MCS options, further research is needed to better understand the optimal tool for specific patient subsets.

**Keywords:** ProtekDuo; right ventricular failure (RVF); left ventricular failure (LV failure); lung transplant; pulmonary embolism (PE)

Submitted Jul 02, 2023. Accepted for publication Nov 09, 2023. Published online Dec 04, 2023.

doi: 10.21037/atm-23-1734

**View this article at:** <https://dx.doi.org/10.21037/atm-23-1734>

<sup>^</sup> ORCID: 0000-0002-0021-2033.

## Introduction

The ProtekDuo (LivaNova, London, UK) cannula is a dual-lumen device typically inserted into the right internal jugular (IJ) vein using a percutaneous approach, with fluoroscopy or ultrasound guidance. When connected to a pump, such as the TandemHeart (LivaNova, London, UK) or CentriMag (Abbott, Pleasanton, CA, USA), it can function as a right ventricular (RV) mechanical circulatory support (MCS) device. When an oxygenator is also added [veno-pulmonary (V-P)], it can provide extracorporeal membrane oxygenation (ECMO) support (1,2). While the configuration described above is the most typical for the ProtekDuo, several variations of this setup have been documented in the literature. The first-in-man use of the ProtekDuo cannula was described in 2016, and clinical outcomes were reported 2 years later (3,4). This review aims to provide a comprehensive overview of the device's physiology and clinical applications.

## ProtekDuo—design and impact on RV physiology

The ProtekDuo cannula, in its typical configuration, receives venous drainage from the upper and lower body through its inflow ports in the right atrium (RA) (*Figure 1*). There are two versions of the device, with diameters of 29- or 31-F for the proximal lumen (inflow) and 16- or 18.5-F for the distal lumen (outflow). The intended position for the outflow cannula is the main pulmonary artery (PA), bypassing the RV (*Figure 1*). Anterograde migration of the cannula into either of the PAs must be prevented to mitigate the risk of PA injury and shunting. It is also vital to prevent cannula retraction, as this could result in acute RV overload. If properly positioned, the ProtekDuo can efficiently decrease RV preload, resulting in decreased RA and RV wall tension and microvascular resistance, reducing RV mechanical work and oxygen demand.

In the setting of RV failure (RVF), the ProtekDuo cannula, with its outflow in the main PA, can bypass the failing RV, improving pulmonary flow, left atrial (LA) filling pressures, and left ventricular (LV) preload. This also reduces ventricular interdependence and leftward shift of the interventricular septum that may occur in RVF. The ProtekDuo cannula, when connected to a pump, can deliver approximately 4.5–5 L of flow per minute, depending on the cannula's size (5). The ProtekDuo cannula and TandemHeart pump are approved for use for up to 6 days by the US Food and Drug Administration (FDA) and up

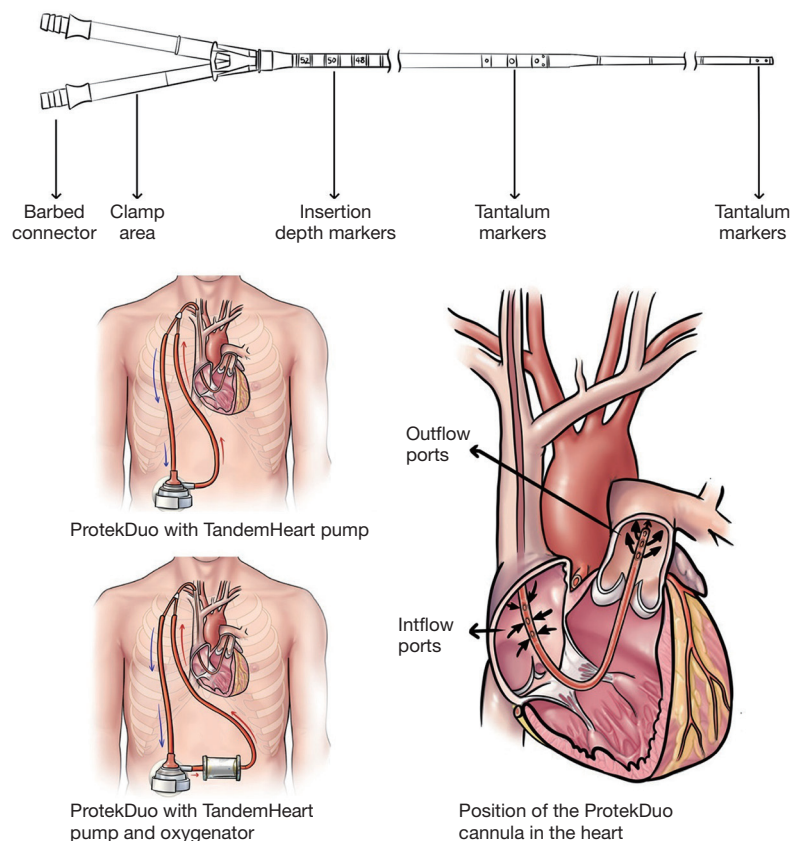
to 30 days by the European Medicines Evaluation Agency (EMA) (6).

## RVF

Acute RVF can stem from various factors such as RV myocardial infarction (MI), myocarditis, pulmonary embolism (PE), arrhythmia, post-surgical myocardial ischemia, RV primary graft dysfunction (PGD) after heart transplant, or LV failure (7). It is noteworthy that acute RVF occurs in over 20% of cases following isolated LV assist device (LVAD) implantation, significantly contributing to mortality within this cohort (8). Among patients with chronic heart failure, irrespective of ejection fraction, the incidence of RVF ranges between 48% and 65%, and correlates with diminished exercise capacity and heightened mortality (9–11).

An abrupt increase in RV afterload or a decrease in RV contractility can cause precipitate RVF. The RV adapts better to changes in volume rather than pressure, as it is coupled to the high-compliance, low-resistance pulmonary circulation (12). In response to increased afterload, the RV undergoes a remodeling process similar to the LV. However, the RV is more vulnerable to acute increases in afterload and oxidative stress, which can lead to myocyte hypertrophy, changes in capillary density, total capillary length, and endothelial cell proliferation (7,13). These changes, known as the angiogenic response, increase the surface area and volume of the capillaries, allowing for increased tissue diffusion. Despite these adaptive changes, the RV has a limited capacity for the angiogenic response compared to the LV, leading to greater activation of cell death pathways in the setting of pressure or volume overload. Reduced RV stroke volume leads to RV dilation, promoting tricuspid regurgitation further exacerbating RV dilation. This reduces LV filling by shifting the interventricular septum leftward, reducing LV transmural filling pressure and promotes ventricular interdependence (14).

Managing RVF requires a multifaceted approach that includes optimizing preload, reducing afterload, providing inotropic support, revascularization, synchronizing atrioventricular function, and potentially using MCS (15). Pulmonary circulation and LV filling abnormalities should be identified as targets for reducing RV afterload and enhancing RV function (16). In cases where acute RVF is refractory to medical therapy or when there is evidence of end-organ dysfunction, MCS may be used as a bridge to recovery or more definitive therapy such as heart



**Figure 1** ProtekDuo design and proper positioning.

transplantation. The primary goal of MCS in acute RVF is to provide adequate cardiac output and oxygen delivery to the vital organs while reducing RV workload and can be achieved through ECMO, surgical RV assist devices (RVADs), or percutaneous RV MCS.

The ProtekDuo has been used as an RV MCS to treat acute RVF in a variety of clinical situations, such as post-MI, cardiomyopathy, or heart transplant. One of the major benefits of this device is its minimally invasive, groin-free approach, which allows for early patient mobility, as well as implantation or explanation while the patient is awake or mildly sedated. This eliminates the need for sternotomy, surgical vascular access, or cardiopulmonary bypass (CPB) during the implantation or explanation process. A theoretical concern while using ProtekDuo as isolated RV MCS is pulmonary edema and pulmonary hemorrhage if flows are greater than what the LV is able to tolerate (17). However, this is yet to be reported for the ProtekDuo. Originally indicated for hemodynamic RV support, the ProtekDuo has recently been used for a variety of other

scenarios including LV support, making it an attractive option for an expanding range of clinical indications.

### ProtekDuo for RVMI RVF

Kremer *et al.* published data on ten patients who required percutaneous RV MCS support for RVF after acute MI from July 2016 to November 2019 (18). The mean implantation time for the RV MCS was  $32.8 \pm 8.3$  minutes, and the mean duration of RV MCS support was  $10.0 \pm 7.4$  days. The study found a significant reduction in central venous pressure ( $19.3 \pm 2.7$  vs.  $8.2 \pm 2.6$  mmHg,  $P < 0.001$ ) and a significant increase in central venous saturation ( $52.8\% \pm 15.6\%$  vs.  $80.0\% \pm 6.0\%$ ,  $P < 0.001$ ) after RV MCS support with the ProtekDuo. Despite the favorable hemodynamic responses, the 30 days mortality remained high at 40%. The time to implementation of ProtekDuo was overall short but the degree of hemodynamic-metabolic shock was not reported in this paper rendering the interpretation of survival benefit challenging. There were no RV MCS-associated

complications reported in this study.

### ProtekDuo for durable LVAD implantation-associated RVF

RVF is a common and feared complication after durable LVAD implantation. Early biventricular support has been shown to improve outcomes compared to delayed conversion to bi-ventricular assist devices (BiVADs) (19). To support the RV after durable LVAD implantation, there are several options available. One of these options is surgical RVAD (RA to PA) which requires surgical insertion and potentially re-thoracotomy for decannulation. Another option is percutaneous femoral-approach RV MCS such as Impella RP, or veno-arterial (V-A) ECMO, both of which restricts the patient's mobility. An alternative less invasive approach is using a percutaneously placed ProtekDuo cannula with a pump (VxP) in conjunction with the LVAD. This strategy allows for rapid postoperative mobilization and is recommended in patients with pre-existing RV dysfunction (6).

Kazui *et al.* successfully used this approach in a 70-year-old patient who developed RVF on the second postoperative day after Heartmate II implantation (1). The patient was supported by a ProtekDuo-CentriMag RV MCS and decannulated on the eleventh postoperative day. In a retrospective, single-center observational study of 11 patients with end-stage HF who underwent concomitant permanent LVAD implantation and temporary RV MCS using the ProtekDuo cannula, 90.9% of patients were weaned from temporary RV MCS support (20). The mean length of stay in the ICU was  $23.8 \pm 16.5$  days, and the 30-day survival rate was 72.7%. No severe complications related to using the RV MCS were observed, but the study's generalizability is limited due to the lack of a comparison arm. Historical data shows that 1-year survival rates for patients with LVAD who later require biventricular support are typically less than 50% (21,22).

In a retrospective database review of 17 patients from two centers, 12 of whom had durable LVADs and received percutaneous RV support using the ProtekDuo, only 23% of patients were successfully weaned off RV support without the need for home inotropes or urgent transplantation (23). The percentage of patients who could not be weaned and had to be transitioned to a surgical RVAD or a durable RVAD was 35%. Complications such as epistaxis, hematemesis, and injury to the left IJ vein which prevented catheter advancement, intracranial bleeding, and bleeding at the

catheter insertion site occurred in 35% of patients, and the overall mortality rate was 41%.

### ProtekDuo for massive PE

Massive PE leading to shock can result in acute RVF, which has a mortality rate of almost 25% (24). Systemic tissue plasminogen activator (tPA) is the recommended therapy for massive PE, although evidence supporting its use is limited (class IIa, level of evidence B) (25). Because tPA has a high bleeding risk, it is contraindicated in some patients. In addition, some patients with massive PE may progress to circulatory shock despite tPA administration. In patients with massive PE, RV MCS has been used as a bridge to recovery or embolectomy. Traditionally, V-A ECMO has been used as rescue support or an initial support strategy to recovery or embolectomy (26,27). Other RV MCS options for massive PE include Impella RP and ProtekDuo (28).

Jayanna *et al.* published a case report about a 72-year-old woman who presented to the emergency department in cardiogenic shock due to a massive PE and RVF (29). After undergoing catheter-directed mechanical thrombectomy, the patient's RV function did not improve, and a ProtekDuo RV MCS was inserted. The RV MCS was successfully weaned over the following 48 hours as the patient's RV function improved. A notable advantage of ProtekDuo compared to V-A ECMO and Impella RP is that ProtekDuo is inserted via the IJ vein, allowing it to be placed in patients with inferior vena cava (IVC) filters.

### ProtekDuo for RVF post-heart transplantation

PGD is a common complication after a heart transplant, affecting 2% to 28% of transplanted patients (30). It represents the leading cause of early death after a heart transplant. V-A ECMO is traditionally used to manage severe forms of PGD that are refractory to maximal medical therapy. However, in up to 45% of patients, the dysfunction is confined to the RV alone. This is due to several reasons, including higher susceptibility to temperature changes and ischemia-reperfusion injury, dependence on preload conditions, or underlying pulmonary hypertension or elevated pulmonary vascular resistance (31,32). In such cases, V-A ECMO may be unfavorable due to its detrimental effects, such as non-physiological circulation with reduced pulmonary flow which increases the risk of intravascular pulmonary thrombosis, increased left ventricle afterload, and the presence of an oxygenator. Therefore, in isolated RV

PGD, a short-term RV MCS is a preferable option.

Carrozzini *et al.* reported their institutional experience utilizing ProtekDuo in three patients who developed primary RV PGD. In all three cases, the ProtekDuo was implanted within 8 hours post-transplant, and all patients were successfully weaned off ProtekDuo support within 4, 9, and 12 days, respectively, and subsequently discharged home. The favorable reported results are likely a reflection of the timely implementation of MCS. Adverse events included IJ thrombosis, acute kidney injury, and respiratory failure, which were likely related to the critical condition of the patients before the transplant as well as the low flow state before the implementation of percutaneous RV MCS (33).

### ProtekDuo for RVF related to miscellaneous etiologies

Oliveros *et al.* published a case series describing the use of ProtekDuo as a temporary RV MCS in 11 patients admitted for acute RVF between August 2015 and February 2018 (2). Causes of RVF included lung resection (4/11), acute respiratory distress syndrome (2/11), postpartum cardiomyopathy (1/11), PE (1/11), post-LVAD implantation (1/11), post-valve surgery (1/11), and acute MI (1/11). Duration of support ranged from 11 to 154 days, and complications included stroke (18.2%), sepsis (63.6%), massive gastrointestinal bleeding (45.5%), and heparin-induced thrombocytopenia (54.5%). There were no complications related to device insertion itself. The overall 30-day survival rate was 82%, and the 180-day survival rate was 72%.

### ProtekDuo and V-P ECMO

Heart failure is a common complication seen in 4–21% of hospitalized coronavirus disease 2019 (COVID-19) patients, 30% of whom have RVF (34–36). The percentage of patients with RVF may be even higher in those with severe ARDS requiring ECMO support, making them prime candidates for RV MCS support (37). Patel *et al.* described a 53-year-old COVID-19 patient on V-V ECMO who developed severe RVF (38). The circuit was changed to a ProtekDuo RV MCS cannula (V-P ECMO) for additional RV support, resulting in a good outcome. In this way, the ProtekDuo can be incorporated into the ECMO circuit, which may be beneficial in situations where an IVC filter precludes IVC cannulation (39). Another advantage of

ProtekDuo is the absence of recirculation which is seen in the setting of high ECMO flow while managing patients with severe ARDS and RVF.

In a retrospective analysis, Cain and colleagues compared the outcomes of 39 patients who received V-P ECMO support with a ProtekDuo to those who received invasive mechanical ventilation (IMV) alone (40). The ProtekDuo group had significantly lower in-hospital and 30-day mortality rates compared to the IMV alone group, with rates of 11.1% and 5.6% *vs.* 52.4% and 42.9%, respectively ( $P=0.008$  and  $P=0.011$ ). Additionally, the ProtekDuo group had a significantly lower rate of acute kidney injury (0% *vs.* 71.4%,  $P<0.001$ ), and no device-related complications were reported in that group. At the end of the study period, 11 out of 18 patients in the ProtekDuo group were successfully decannulated, with an average duration of 13 days on device support.

The V-P ProtekDuo configuration allows patients on mechanical ventilation to be extubated while still on MCS support. Mustafa and colleagues published a retrospective series of 40 COVID-19 patients who required ECMO after reaching maximum ventilatory support (41). After the placement of a ProtekDuo cannula, ventilation was discontinued while patients continued to receive ECMO support (V-P). At the time of publication, all patients were successfully extubated after ECMO initiation, and 80% were no longer on ECMO. Ultimately, 73% of patients were discharged off oxygen. The reintubation rate was 25%, but all patients were eventually extubated. The team reported minimal complications and a low mortality rate of 15%.

Maybauer and colleagues reported several other ECMO circuit configurations utilizing the ProtekDuo cannula (42,43). In one configuration, they added a 25-F femoral multistage venous drainage cannula to the circuit to enhance venous drainage. The venous return from the femoral drainage was spliced with the venous tubing of the ProtekDuo and directed into the pump, resulting in a veno-venopulmonary (V-VP) ECMO configuration. In another configuration, the 25-F multistage drainage cannula was the sole venous drainage, and both lumens of the ProtekDuo were utilized for arterial flow into the RA and PA, resulting in a veno-double-lumen venopulmonary [V-(dl)VP] ECMO configuration. This configuration resulted in increased blood flow and oxygenation [oxygen saturation ( $SpO_2$ ) increased from 78% to 100%] (42). The reported flow through the proximal port of the ProtekDuo was 4 L/min, and the flow through the distal port was 3 L/min.

## Newer and atypical uses of ProtekDuo

### *ProtekDuo as part of temporary biventricular MCS as bridge to recovery (ECpella 2.0 or PROpella)*

Although V-A ECMO is a very effective MCS strategy in specific scenarios, it can be associated with several complications such as prolonged immobilization, limb ischemia due to cannulation, infection, air embolism, bleeding, and stroke. One specific issue with V-A ECMO is ensuring adequate LV venting in the setting of increased LV afterload from retrograde arterial flow, which can be addressed using intra-aortic balloon pump (IABP), atrial septostomy, and trans-septal LA drainage. Of late, percutaneous, temporary, axial flow MCS devices such as Impella have been used as effective LV vents in patients on V-A ECMO, a concept referred to as ECpella. Ruhparwar *et al.* improved upon this concept with ECpella 2.0/PROpella, a groin-free MCS consisting of a surgically implanted full-flow axial flow pump (Impella 5.0/5.5) as an LVAD in combination with the TandemHeart/ProtekDuo system as an RV MCS (44,45). This allows for complete biventricular support with the option to splice in an oxygenator if needed. The authors described using ECpella 2.0 in two patients with circulatory shock who were successfully weaned off support at postoperative days 5 and 22, respectively.

Chivasso *et al.* utilized the ECpella 2.0 approach to facilitate the weaning of a cardiogenic shock patient from V-A ECMO (46). The patient, a 38-year-old male, presented with a non-ST elevation MI and developed cardiogenic shock necessitating V-A ECMO with Impella CP for LV venting. As the patient improved, the Impella CP was retained while V-A ECMO was discontinued. However, echocardiography showed residual impaired RV function, with TAPSE of 11 mm, CVP greater than 18 mmHg, and PAPI less than 2.0 despite inotropic support and inhaled nitric oxide prompting the use of ProtekDuo RV MCS to support the RV. Although the authors did not mention whether the patient was optimized from volume standpoint before ProtekDuo RV MCS placement, this approach allowed for gradual RV recovery, and the patient was eventually discharged on day 24.

### *ProtekDuo for biventricular support as bridge to recovery or decision*

In a case series of three patients, Khalpey *et al.* described simultaneously using two ProtekDuo devices as minimally invasive BiVADs (47). The ProtekDuo cannula was used

with a CentriMag pump to provide RV MCS support in the standard configuration. For LV support, the ProtekDuo cannula was inserted into the LV via an apical puncture, with the distal tip crossing past the aortic valve. The first patient was transitioned to a total artificial heart (TAH) (SynCardia Systems, Inc., Tucson, AZ, USA) on day 34. The second patient had his RV MCS, and LVAD support discontinued on postoperative days 4 and 6, respectively, and was subsequently discharged to a rehabilitation center. The third patient was weaned off the RV MCS on postoperative day 13 but did not recover, and the family ultimately withdrew support on postoperative day 19.

The use of ProtekDuo devices as minimally invasive BiVADs offers several advantages. One of the main benefits is that it can be placed in less than 3 hours with relatively minimal blood loss. Additionally, this approach avoids the need for a median sternotomy, which preserves the sternum for future use in a durable LVAD or heart transplant. Femoral artery cannulation, which may lead to leg ischemia even with ipsilateral distal perfusion cannulation is avoided, reducing the risk of complications. Moreover, the ProtekDuo functions as both an LV vent and an MCS device, eliminating the need for separate LV venting, while promoting ventricular recovery.

### *ProtekDuo for isolated LV failure*

The use of ProtekDuo for temporary LV MCS is via a trans-apical approach. Goodwin *et al.* reported a case of a 51-year-old patient with refractory cardiogenic shock who received ProtekDuo support through the intercostal space (48). The device was connected to a CentriMag pump, and the patient initially showed improvement. However, on day 26, he suffered a hemorrhagic stroke and died. The authors chose the ProtekDuo over an Impella because they believed it better offloads the LV in the presence of aortic regurgitation and has a lower risk of hemolysis, especially at high flow rates needed for severe AR. Similarly, Belani *et al.* reported a case of a 47-year-old Jehovah's Witness patient with decompensated systolic heart failure who received ProtekDuo LV support over an Impella (34). The authors felt that the Impella has a higher risk of hemolysis, which may have necessitated transfusion. V-A ECMO and a durable LVAD were not chosen due to higher risk of bleeding.

### *ProtekDuo for lung transplantation (LT) care*

Approximately 25% of patients presenting for orthotopic

**Table 1** Summary of clinical indications, advantages, and disadvantages of the ProtekDuo

Uses of ProtekDuo	Advantages	Disadvantages
RVF	Minimally invasive, groin-free approach	Risks associated with central venous cannulation—bleeding, infection, air embolism, device clotting
RV support after LVAD implantation	Early post-procedure mobilization	Surgical expertise is needed for trans-apical puncture when used as LVAD
ECMO	Avoid surgical insertion, sternotomy, and transfer to the operating room	
ECpella	Avoid re-thoracotomy for decannulation	
Isolated LV failure	Easy to incorporate into existing ECMO circuit	
Complete biventricular support	Avoid complications of peripheral cannulation, such as limb ischemia	
CPB	Able to use in cases where inferior vena cava IVC cannot be cannulated (e.g., IVC filter) Able to de-couple oxygenator from the pump while weaning Lower risk of hemolysis Less risk of systemic inflammatory response syndrome Better offloading in the presence of aortic insufficiency Able to use for LV support via transapical approach if femoral or subclavian arterial vessels are inaccessible Allows for intra-operative configuration switch in CPB	

RVF, RV failure; RV, right ventricular; LVAD, left ventricular assist device; ECMO, extracorporeal membrane oxygenation; LV, left ventricular; CPB, cardiopulmonary bypass; IVC, inferior vena cava.

LT have end-stage pulmonary hypertension and resulting RV dysfunction (49). To support these patients during surgery, ECMO is often used in addition to traditional CPB. In a case report by Budd *et al.*, a patient undergoing sequential bilateral LT was intraoperatively supported initially with a ProtekDuo V-P configuration (50). After arrival of donor lungs, the configuration was converted to central (dl)V-A ECMO by cannulating the ascending aorta and converting ProtekDuo to double lumen drainage. Once transplantation was done the circuit was converted back to V-P configuration to decompress the RV. The ProtekDuo, used as part of the V-A ECMO circuit, provided good intraoperative stability and RV support. Sinha *et al.* also reported two cases in which a ProtekDuo was used as a bridge to heart-lung and LT (51). Harano *et al.* reported outcomes of four patients with idiopathic pulmonary fibrosis who were placed on ProtekDuo in V-P configuration as a bridge to transplantation, all of whom underwent double LT (52). There was one in-hospital mortality due to superimposed pseudomonas pneumonia with influenza virus

infection on postoperative day 97, while the other three were alive at 2-year follow up. A brief summary of clinical indications, advantages, and disadvantages of the use of ProtekDuo are highlighted in *Table 1*.

## Conclusions

ProtekDuo is an important tool in the armory of RVF management. ProtekDuo offers clear advantages including groin-free approach allowing for mobility, easy percutaneous deployment, compatibility with various pumps and oxygenators and its versatility to be integrated in numerous configurations. As with any other MCS, ProtekDuo has its own sets of risks including vascular injury, hemolysis, iatrogenic tricuspid regurgitation, pulmonary valve dysfunction, superior vena cava syndrome, cardiac wall perforation, pericardial effusion with tamponade, infection, embolism and thrombosis as well as cannula migration leading to ineffective unloading of RV (53). Moreover, in some instances such as during heart transplant for PGD

where there is no access to the IJ vein, ProtekDuo may be difficult to deploy.

It is important to acknowledge that experience in utilization of ProtekDuo in atypical configurations, for instance as a temporary LVAD, remains limited and falls within the realm of experimental usage. Despite this, the ProtekDuo system is expected to gain more popularity in the future. With the expansion of the available MCS options, further research and experience is needed to better understand the best tool for each subset of patients. The THEME registry may offer more insights into the effectiveness of the ProtekDuo in real-world settings (54).

## Acknowledgments

*Funding:* None.

## Footnote

*Peer Review File:* Available at <https://atm.amegroups.com/article/view/10.21037/atm-23-1734/prf>

*Conflicts of Interest:* All authors have completed the ICMJE uniform disclosure form (available at <https://atm.amegroups.com/article/view/10.21037/atm-23-1734/coif>). A.L. serves as an unpaid editorial board member of *Annals of Translational Medicine* from September 2022 to August 2024. The other authors have no conflicts of interest to declare.

*Ethical Statement:* The authors are accountable for all aspects of the work in ensuring that questions related to the accuracy or integrity of any part of the work are appropriately investigated and resolved.

*Open Access Statement:* This is an Open Access article distributed in accordance with the Creative Commons Attribution-NonCommercial-NoDerivs 4.0 International License (CC BY-NC-ND 4.0), which permits the non-commercial replication and distribution of the article with the strict proviso that no changes or edits are made and the original work is properly cited (including links to both the formal publication through the relevant DOI and the license). See: <https://creativecommons.org/licenses/by-nc-nd/4.0/>.

## References

1. Kazui T, Tran PL, Echeverria A, et al. Minimally invasive approach for percutaneous CentriMag right ventricular assist device support using a single PROTEKDuo Cannula. *J Cardiothorac Surg* 2016;11:123.
2. Oliveros E, Collado FM, Poulin MF, et al. Percutaneous Right Ventricular Assist Device Using the TandemHeart ProtekDuo: Real-World Experience. *J Invasive Cardiol* 2021;33:E407-11.
3. Aggarwal V, Einhorn BN, Cohen HA. Current status of percutaneous right ventricular assist devices: First-in-man use of a novel dual lumen cannula. *Catheter Cardiovasc Interv* 2016;88:390-6.
4. Nicolais CD, Suryapalam M, O'Murchu B, et al. Use of protek duo tandem heart for percutaneous right ventricular support in various clinical settings: A case series. *J Am Coll Cardiol* 2018;71:A1314.
5. Upadhyay R, Alrayes H, Arno S, et al. Current landscape of temporary percutaneous mechanical circulatory support technology. *US Cardiol Rev* 2021;15:e21.
6. Schmack B, Weymann A, Popov AF, et al. Concurrent Left Ventricular Assist Device (LVAD) Implantation and Percutaneous Temporary RVAD Support via CardiacAssist Protek-Duo TandemHeart to Preempt Right Heart Failure. *Med Sci Monit Basic Res* 2016;22:53-7.
7. Reddy S, Bernstein D. Molecular Mechanisms of Right Ventricular Failure. *Circulation* 2015;132:1734-42.
8. Lampert BC, Teuteberg JJ. Right ventricular failure after left ventricular assist devices. *J Heart Lung Transplant* 2015;34:1123-30.
9. Iglesias-Garriz I, Olalla-Gómez C, Garrote C, et al. Contribution of right ventricular dysfunction to heart failure mortality: a meta-analysis. *Rev Cardiovasc Med* 2012;13:e62-9.
10. La Vecchia L, Paccanaro M, Bonanno C, et al. Left ventricular versus biventricular dysfunction in idiopathic dilated cardiomyopathy. *Am J Cardiol* 1999;83:120-2, A9.
11. Frea S, Pidello S, Bovolo V, et al. Prognostic incremental role of right ventricular function in acute decompensation of advanced chronic heart failure. *Eur J Heart Fail* 2016;18:564-72.
12. Haddad F, Hunt SA, Rosenthal DN, et al. Right ventricular function in cardiovascular disease, part I: Anatomy, physiology, aging, and functional assessment of the right ventricle. *Circulation* 2008;117:1436-48.
13. Kolb TM, Peabody J, Baddoura P, et al. Right Ventricular Angiogenesis is an Early Adaptive Response to Chronic Hypoxia-Induced Pulmonary Hypertension. *Microcirculation* 2015;22:724-36.
14. Haddad F, Doyle R, Murphy DJ, et al. Right ventricular function in cardiovascular disease, part II: pathophysiology,



- clinical importance, and management of right ventricular failure. *Circulation* 2008;117:1717-31.
15. Chhapra DA, Mahajan SK, Thorat ST. A study of the clinical profile of right ventricular infarction in context to inferior wall myocardial infarction in a tertiary care centre. *J Cardiovasc Dis Res* 2013;4:170-6.
  16. Konstam MA, Kiernan MS, Bernstein D, et al. Evaluation and Management of Right-Sided Heart Failure: A Scientific Statement From the American Heart Association. *Circulation* 2018;137:e578-622.
  17. Usman AA, Cevasco M, Maybauer MO, et al. Oxygenated right ventricular assist device as part of veno-venopulmonary extracorporeal membrane oxygenation to support the right ventricle and pulmonary vasculature. *J Cardiothorac Surg* 2023;18:134.
  18. Kremer J, Farag M, Brcic A, et al. Temporary right ventricular circulatory support following right ventricular infarction: results of a groin-free approach. *ESC Heart Fail* 2020;7:2853-61.
  19. Fitzpatrick JR 3rd, Frederick JR, Hiesinger W, et al. Early planned institution of biventricular mechanical circulatory support results in improved outcomes compared with delayed conversion of a left ventricular assist device to a biventricular assist device. *J Thorac Cardiovasc Surg* 2009;137:971-7.
  20. Schmack B, Farag M, Kremer J, et al. Results of concomitant groin-free percutaneous temporary RVAD support using a centrifugal pump with a double-lumen jugular venous cannula in LVAD patients. *J Thorac Dis* 2019;11:S913-20.
  21. Kirklin JK, Pagani FD, Kormos RL, et al. Eighth annual INTERMACS report: Special focus on framing the impact of adverse events. *J Heart Lung Transplant* 2017;36:1080-6.
  22. LaRue SJ, Raymer DS, Pierce BR, et al. Clinical outcomes associated with INTERMACS-defined right heart failure after left ventricular assist device implantation. *J Heart Lung Transplant* 2017;36:475-7.
  23. Ravichandran AK, Baran DA, Stelling K, et al. Outcomes with the Tandem Protek Duo Dual-Lumen Percutaneous Right Ventricular Assist Device. *ASAIO J* 2018;64:570-2.
  24. Kucher N, Goldhaber SZ. Management of massive pulmonary embolism. *Circulation* 2005;112:e28-32.
  25. Jaff MR, McMurtry MS, Archer SL, et al. Management of massive and submassive pulmonary embolism, iliofemoral deep vein thrombosis, and chronic thromboembolic pulmonary hypertension: a scientific statement from the American Heart Association. *Circulation* 2011;123:1788-830.
  26. Al-Bawardy R, Rosenfield K, Borges J, et al. Extracorporeal membrane oxygenation in acute massive pulmonary embolism: a case series and review of the literature. *Perfusion* 2019;34:22-8.
  27. Pasrija C, Shah A, George P, et al. Triage and optimization: A new paradigm in the treatment of massive pulmonary embolism. *J Thorac Cardiovasc Surg* 2018;156:672-81.
  28. Shokr M, Rashed A, Mostafa A, et al. Impella RP Support and Catheter-Directed Thrombolysis to Treat Right Ventricular Failure Caused by Pulmonary Embolism in 2 Patients. *Tex Heart Inst J* 2018;45:182-5.
  29. Jayanna MB, Ahmad TA, Maalouf M, et al. Catheter-Directed Mechanical Thrombectomy in Massive Pulmonary Embolism With Cardiogenic Shock. *JACC Case Rep* 2020;2:1036-41.
  30. Singh SSA, Dalzell JR, Berry C, et al. Primary graft dysfunction after heart transplantation: a thorn amongst the roses. *Heart Fail Rev* 2019;24:805-20.
  31. Kobashigawa J, Zuckermann A, Macdonald P, et al. Report from a consensus conference on primary graft dysfunction after cardiac transplantation. *J Heart Lung Transplant* 2014;33:327-40.
  32. Cosío Carmena MD, Gómez Bueno M, Almenar L, et al. Primary graft failure after heart transplantation: characteristics in a contemporary cohort and performance of the RADIAL risk score. *J Heart Lung Transplant* 2013;32:1187-95.
  33. Carrozzini M, Merlanti B, Olivieri GM, et al. Percutaneous RVAD with the Protek Duo for severe right ventricular primary graft dysfunction after heart transplant. *J Heart Lung Transplant* 2021;40:580-3.
  34. Belani K, Saikus CE, Schroder JN, et al. Transapical Protek Duo Rapid Deployment Cannula as Temporary Left Ventricular Assist Device in a Jehovah's Witness Patient. *J Cardiothorac Vasc Anesth* 2021;35:3735-42.
  35. Argulian E, Sud K, Vogel B, et al. Right Ventricular Dilation in Hospitalized Patients With COVID-19 Infection. *JACC Cardiovasc Imaging* 2020;13:2459-61.
  36. John KJ, Nayar J, Mishra AK, et al. In-hospital clinical complications of COVID-19: a brief overview. *Future Virol* 2021.
  37. John K, Mishra AK, Nayar J, et al. Coronavirus disease 2019 and mechanical circulatory support devices: a comprehensive review. *Monaldi Arch Chest Dis* 2022. doi: 10.4081/monaldi.2022.2362.
  38. Patel SP, Solomon BJ, Pascotto RD, et al. Right Ventricular Failure Manifesting in Corona Virus Disease

- 2019 Acute Respiratory Distress Syndrome: A Call to Transition from Venovenous Extracorporeal Membranous Oxygenation to Right Ventricular Assist Device Extracorporeal Membranous Oxygenation. *J Cardiothorac Vasc Anesth* 2022;36:3197-201.
39. Giani M, Pisa A, Passera E, et al. Tracheal stenting on venovenous ECMO with a dual lumen right atrium-to-pulmonary artery cannula in a COVID-19 patient with an inferior vena cava filter. *Perfusion* 2023;38:654-6.
  40. Cain MT, Smith NJ, Barash M, et al. Extracorporeal Membrane Oxygenation with Right Ventricular Assist Device for COVID-19 ARDS. *J Surg Res* 2021;264:81-9.
  41. Mustafa AK, Alexander PJ, Joshi DJ, et al. Extracorporeal Membrane Oxygenation for Patients With COVID-19 in Severe Respiratory Failure. *JAMA Surg* 2020;155:990-2.
  42. Maybauer MO, Koerner MM, Mihu MR, et al. The ProtekDuo as double lumen return cannula in V-VP ECMO configuration: A first-in-man method description. *Ann Card Anaesth* 2022;25:217-9.
  43. Maybauer MO, Koerner MM, Swol J, et al. The novel ProtekDuo ventricular assist device: Configurations, technical aspects, and present evidence. *Perfusion* 2023;38:887-93.
  44. Ruhparwar A, Zubarevich A, Osswald A, et al. ECPPELLA 2.0-Minimally invasive biventricular groin-free full mechanical circulatory support with Impella 5.0/5.5 pump and ProtekDuo cannula as a bridge-to-bridge concept: A first-in-man method description. *J Card Surg* 2020;35:195-9.
  45. Maybauer MO, Swol J, Sharif A, et al. The ProtekDuo in percutaneous peripheral venopulmonary-arterial ECMO and PROpella configuration for cardiogenic shock with biventricular failure. *Ann Card Anaesth* 2023;26:339-42.
  46. Chivasso P, Miele M, Romano R, et al. Impella CP and ProtekDuo as a bridge to recovery following surgical revascularization complicated by electrical storm. *Gen Thorac Cardiovasc Surg* 2021;69:877-81.
  47. Khalpey Z, Smith R, Echeverria A, et al. A novel minimally invasive off-pump biventricular assist device insertion technique. *J Thorac Cardiovasc Surg* 2016;151:e5-7.
  48. Goodwin ML, Roberts S, Lampert BC, et al. Temporary extracorporeal left ventricular support with transapical ProtekDuo cannula. *JTCVS Tech* 2021;5:76-9.
  49. Arcasoy SM, Christie JD, Ferrari VA, et al. Echocardiographic assessment of pulmonary hypertension in patients with advanced lung disease. *Am J Respir Crit Care Med* 2003;167:735-40.
  50. Budd AN, Kozarek K, Kurihara C, et al. Use of ProtekDuo as Venous-arterial and Venous-venous Extracorporeal Membrane Oxygenation During Bilateral Lung Transplantation. *J Cardiothorac Vasc Anesth* 2019;33:2250-4.
  51. Sinha N, Goodarzi A, Akku R, et al. ProtekDuo as a bridge to lung transplant and heart-lung transplant. *Clin Transplant* 2021;35:e14273.
  52. Harano T, Chan EG, Furukawa M, et al. Oxygenated right ventricular assist device with a percutaneous dual-lumen cannula as a bridge to lung transplantation. *J Thorac Dis* 2022;14:832-40.
  53. Salna M, Garan AR, Kirtane AJ, et al. Novel percutaneous dual-lumen cannula-based right ventricular assist device provides effective support for refractory right ventricular failure after left ventricular assist device implantation. *Interact Cardiovasc Thorac Surg* 2020;30:499-506.
  54. ClinicalTrials.gov. TandemHeart Experiences and MEthods (THEME Registry) (THEME). NCT02326402. 2022. [Cited 2022 Sep 9]. Available online: <https://clinicaltrials.gov/ct2/show/NCT02326402>

**Cite this article as:** John KJ, Nabzdyk CGS, Chweich H, Mishra AK, Lal A. ProtekDuo percutaneous ventricular support system—physiology and clinical applications. *Ann Transl Med* 2024;12(1):14. doi: 10.21037/atm-23-1734