



# Scoping review of robotics technology in spinal surgery with highlights of the Annual Seattle Science Foundation Course

Nicholas Dietz<sup>1</sup>, Victoria Alkin<sup>2</sup>, Isador Lieberman<sup>3</sup>, Andrew Manista<sup>4</sup>, Terrence Kim<sup>5</sup>, J. Patrick Johnson<sup>6</sup>, Doniel Drazin<sup>7</sup>

<sup>1</sup>Department of Neurosurgery, University of Louisville, Louisville, KY, USA; <sup>2</sup>Department of Neurobiology and Behavior, Cornell University, Ithaca, NY, USA; <sup>3</sup>Scoliosis and Spine Tumor Center, Texas Back Institute, Plano, TX, USA; <sup>4</sup>The Spine Center, Olympia Orthopedic Associates, Olympia, WA, USA; <sup>5</sup>Department of Orthopedics, Cedars-Sinai Medical Center, Los Angeles, CA, USA; <sup>6</sup>Department of Neurosurgery, Cedars-Sinai Medical Center, Los Angeles, CA, USA; <sup>7</sup>Department of Neurosurgery, Providence Neuroscience Center Everett, Everett, WA, USA

*Contributions:* (I) Conception and design: N Dietz, V Alkin, D Drazin; (II) Administrative support: N Dietz, D Drazin; (III) Provision of study materials or patients: I Lieberman, A Manista, T Kim, JP Johnson, D Drazin; (IV) Collection and assembly of data: V Alkin, N Dietz; (V) Data analysis and interpretation: V Alkin, N Dietz; (VI) Manuscript writing: All authors; (VII) Final approval of manuscript: All authors.

*Correspondence to:* Nicholas Dietz, MD. Department of Neurosurgery, University of Louisville, 200 Abraham Flexner Way, Louisville, KY 40202, USA. Email: [nkd25@georgetown.edu](mailto:nkd25@georgetown.edu).

**Background:** Robotic assistance has become increasingly prevalent in spinal surgery in recent years, emerging as a tool to increase accuracy and precision and lower complication rates and radiation exposure. The 7<sup>th</sup> and 8<sup>th</sup> Annual Seattle Science Foundation (SSF) Robotics Courses showcased presentations and demonstrations from some of the field's most experienced leaders on latest topics in robotics and spinal surgery, including cutting-edge preoperative planning technologies, augmented reality (AR) in the operating room, cervical fusion with transpedicular screws, and neuro-oncologic management. We provide a scoping review of the use of robotics technology in spinal surgery featuring highlights from the 7<sup>th</sup> and 8<sup>th</sup> Annual SSF Robotics Courses.

**Methods:** A scoping review of the literature was conducted (last search conducted in July 2024). Key search terms included “robotic assistance”, “spine surgery”, and “robotic technology” on the PubMed database. Additionally, highlights are included from the 7<sup>th</sup> and 8<sup>th</sup> Annual SSF Robotics Courses.

**Results:** Applications of navigation robotics span subspecialties of spine surgery including deformity correction, minimally invasive approaches, lateral single position operations, spinal oncology, and cervical fusion. Tips on overcoming traditional obstacles of robotics integration such as streamlining staff workflow and adoption while financing robotic-assisted technology are shared. Future directions of robotics enhanced with AR may further guide surgeon decision-making, assist in more practical fashion intraoperatively, and optimize patient outcomes.

**Conclusions:** While improved precision and accuracy, less radiation, and standardization of procedures represent current advantages of robotic-assistance across spine surgery, robotics in spine surgery will usher more transformative changes to patient care and operative skill in coming years.

**Keywords:** Robotics; spinal fusion; emerging technologies; pre-operative planning; spine

Submitted May 20, 2024. Accepted for publication Sep 26, 2024. Published online Dec 18, 2024.

doi: [10.21037/atm-24-100](https://doi.org/10.21037/atm-24-100)

View this article at: <https://dx.doi.org/10.21037/atm-24-100>

## Introduction

Robotic assistance has become increasingly prevalent in spinal surgery in recent years, emerging as a tool to increase accuracy and precision and lower complication rates and radiation exposure. Robotic assistance is used in a variety of surgeries for multiple purposes and surgical stages. The 2022–2023 Seattle Science Foundation Robotics Courses (7<sup>th</sup> and 8<sup>th</sup> Annual) showcased emergent robotic assistance technologies, use of artificial intelligence in preoperative planning, intraoperative augmented reality (AR) examples that improve workflow, and applications of robotic assistance in various types of spinal surgeries, including cervical transpedicular fusion, neurooncology, and bone graft placement. As robotic assistance becomes more commonly used in a wide scope of spinal surgery subspecialties and with an increasing number of applications, it is important to characterize the use of these robotic systems in spinal surgery to provide a resource describing their applications. This scoping review describes the variety of surgery types in which robotic assistance has been utilized, the specifics of how these robotic systems are integrated into surgical techniques, and the advantages and challenges presented by the integration of these technologies. It also includes highlights from the 2022–2023 7<sup>th</sup> and 8<sup>th</sup> Annual Seattle

Science Foundation (SSF) Robotics Courses.

The benefits of robotic assistance in spinal surgery, including improved accuracy and precision, decreased radiation exposure, and minimally invasive nature of robotic spine surgery (1-3). Overcoming the hurdles financial and workflow integration of navigation robotic surgery is discussed to offer methods to ease adoption of this important adjunct to spine surgery. Speakers share tips on introducing technology into the operating room (OR) and recruiting staff adoption and familiarity to optimize transition to practice. Still in the early-adoption phase of robotics, spinal surgery has expanding indications for its use and broad applicability and potential for planning software to optimize outcomes with accurately placed hardware with enhanced biomechanically appropriate constructs.

Robotic preoperative planning simplifies complex screw placement and optimizes single position lateral surgery with less use of O-arm and other tools and allow for reduction maneuvers at adjacent spinal levels (4,5). Additionally, artificial intelligence (AI) may guide surgeon choice in approach depending on goals of surgery and anatomical nuances (6,7). Notably, robotic assistance works particularly well in cases of prone pedicle screws, lateral pedicle screws, graft placement, and now cervical transpedicular approaches (4,5). However, more work is needed to develop robotic assistance in odontoid screw placement and robotic assistance in trans-pedicular/extra-pedicular access to disc space and transdiscal/tricortical instrumentation.

Cervical spine fusion may currently under-utilize robotic guided pedicle screw placement given accuracy and feasibility for a superior pull-out strength construct in the cervical spine. Endoscopy is another area in which robotic assistance can be utilized, helping with robotic targeting, endoscopic visualization, and planning the interbody trajectory. Robotic assist is also beneficial in the subspecialty of spinal deformity and scoliosis surgery in the pre-operative and intra-operative planning, instrumentation delivery, and rod insertion phases, leading to standardization, consistency, and better outcomes. Robotic systems facilitate minimally invasive surgery (MIS) techniques and screw placement in single-position surgery for oblique lumbar interbody fusion.

Future directions demonstrate impactful potential to transform preoperative planning and operative technique with the addition of AR technology machine learning and technological advancements in robotic capabilities. We present this article in accordance with the PRISMA-ScR reporting checklist (available at <https://atm.amegroups.com/article/view/10.21037/atm-24-100/rc>).

### Highlight box

#### Key findings

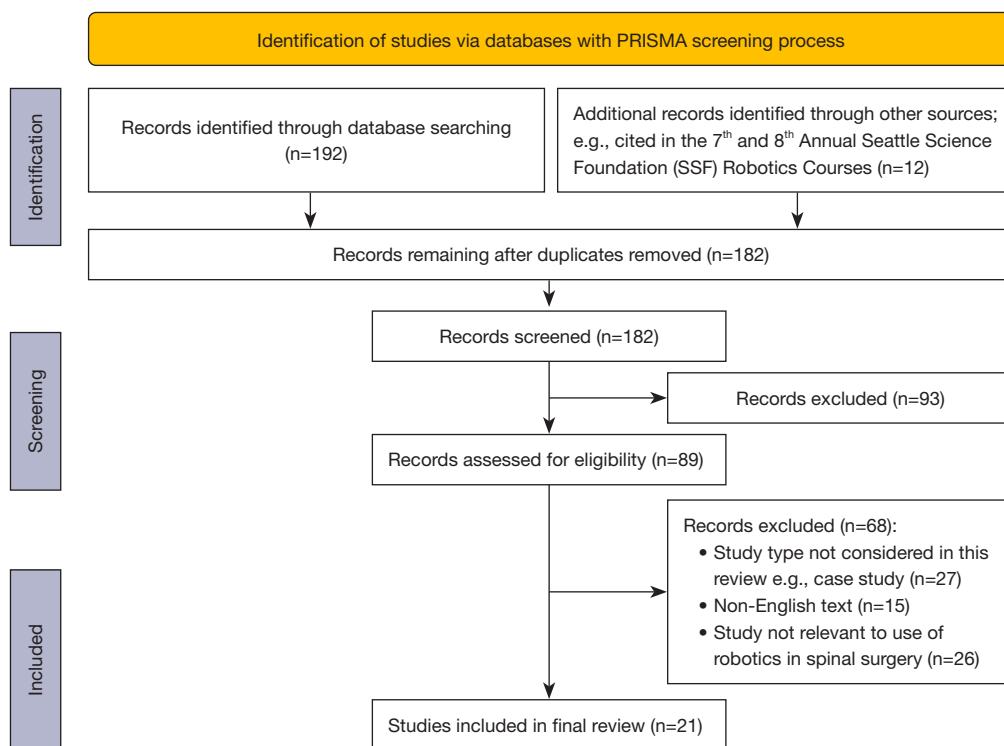
- Robotic-assisted spine surgery may be used for preoperative planning, cervical transpedicular fusion, bone graft placement, and neuro-oncologic management.
- Robotic assistance presents advantages including improved precision and accuracy, reduced radiation exposure, and more comprehensive pre-operative planning.

#### What is known and what is new?

- Robotic assistance has become an increasingly prevalent tool in spinal surgery, used in a variety of surgeries for multiple purposes and surgical stages.
- This scoping review describes the variety of surgery types in which robotic assistance has been utilized, the specifics of how these robotic systems are integrated into surgical techniques, and the advantages and challenges presented by the integration of these technologies.

#### What is the implication, and what should change now?

- Both the advantages and challenges of robotic assistance should be considered in spinal surgery.
- As newer technologies are developed, their integration into spinal surgery will bring new possibilities to patient care.



**Figure 1** Diagram of PRISMA screening process.

**Table 1** Exact search strategy for PubMed database

Search term	Alternate search terms	Field
Robotics	Robotic assistance OR robotic technology OR augmented reality	Title/abstract
AND spinal surgery	Spine surgery	Title/abstract
OR spine endoscopy	Endoscopy	Title/abstract
OR neuro-oncology	Brain cancer OR spinal metastases	Title/abstract
OR learning curve	–	Title/abstract
OR pre-operative planning	–	Title/abstract
OR single-position minimally invasive	–	Title/abstract

## Methods

A scoping review of the literature was conducted, with the last search conducted in July 2024 (*Figure 1*). Key search terms included “robotic assistance”, “spine surgery”, and “robotic technology” on the PubMed database, with the full search strategy presented in *Table 1*. All included studies were related to the use of robotic assistance in various types of spinal surgery on human patients. Case reports were excluded from this study. Study search included the years 1995–2024, but mostly studies from the years range of

2020–2024 were considered, with earlier studies included only if they were deemed crucial foundational studies. Only English-language texts were considered. Pre-print publication status studies were not included. Highlights are included from the 7<sup>th</sup> and 8<sup>th</sup> Annual SSF Robotics Courses, which showcased presentations and demonstrations from some of the field’s most experienced leaders on latest topics in robotics and spinal surgery, including cutting-edge preoperative planning technologies, AR in the OR, cervical fusion with transpedicular screws, and neuro-oncologic management.

The articles found with these search terms were then included or excluded based on the additional criteria described above. Article selection and data extraction were completed independently by team members. Data were sought for variables including type of spinal surgery, purpose of utilization of robotic assistance, stage of surgery in which robotic assistance is utilized, surgical outcomes, comparison of robotic-assisted surgical outcomes to traditional surgery outcomes, and advantages and challenges presented by robotic assistance in surgeries. The data were then categorized into groups based on these variables. The categories were based primarily on surgery type, and sources pertaining to similar surgery types were grouped and analyzed together. Data were summarized in relation to the variables described previously, focusing on the utilizations, advantages, and disadvantages of robotic assistance in spinal surgery.

## Results

### *Pros and cons of robotic assistance*

The PRISMA screening process yielded 21 studies to be included in the final review. Characteristics for which data were charted for each source include authors, year, type of spinal surgery, purpose of utilization of robotic assistance, stage of surgery in which robotic assistance is utilized, and outcomes. Pros of robotic assistance in spine surgery include increased accuracy and precision, reduced complication rates, reduced OR time, and reduced radiation exposure (8,9). One better-known advantage of robotic assist is that accuracy and precision with robotic assisted transpedicular screws can be improved reproducibly (10-13). In a study comparing 485 patients, robotic-guidance was almost six-times less likely to have a surgical complication, less likely to undergo revision surgery, and had less radiation exposure (14). Robotic guidance has shown less blood loss and better screw placement than free-hand navigation (15) with better radiographic results in scoliosis surgery cases.

In a 2022 study, there was no significant difference in the OR time between robot-assisted versus traditional navigation surgeries, while an advantage of the robots was decreased exposure to radiation (16). In 2021, OR time was equivocal between robotic guidance and computed tomography (CT) navigation surgeries (15).

Cost of equipment and use represents a drawback of using robotic systems that may be over \$1.2 million, despite evidence of long-term cost effectiveness (8,17).

Many models of how hospitals may finance or lease robotic systems to manage the upfront high capital requirements. However, use of robotic assistance could eventually lead to lower costs for patients by decreasing the likelihood of a revision surgery (8).

Additional evidence from a retrospective analysis of 300 cases (comparing MIS, open, and robotic-assist) shows that MIS techniques without robotic assistance may be more cost-effective in lumbar fusion, as technology and financial landscape continues to improve specifically for robotic integration into hospitals (18). Technological improvements may focus on integrating a greater sense of haptic feedback to the surgeon to identify and control familiarity with landmarks and anatomy during the procedure. To date, this technological inhibition represents a potential drawback of the field and an opportunity to reduce complication rates. Overcoming financial hindrances may serve to incentive its widespread use and better unlock the potential of robotics and a climate of familiarity.

Another potential drawback is the learning curve associated with using new technologies. If workflow is slowed or expectations are not met quickly enough, some surgeons and institutions lose interest in adoption (19). However, numerous studies demonstrate that the typical learning curve is around 20 cases or six months' time of use (7,20-23).

### *Pearls and pitfalls of robotic-assisted spine surgeries*

As robotic assistance has become increasingly prevalent in spinal surgery in recent years, emerging as a tool to increase accuracy and precision and lower complication rates and radiation exposure, an important subject of discussion and investigation has become the extent to which robotic assistance should be relied upon in surgeries and the optimal ways to integrate these new technologies (8,9). The speakers of the Seattle Science Foundation Course discussed that as robotic and navigation platforms are employed in the OR, robotic assistance should be viewed as a complementary tool, cautioning against becoming over-reliant on technology to emphasizing the importance of maintaining the primary goals of the surgery, including decompressing the nerves, improving alignment, and minimizing damage to adjacent tissues—there is no substitute for surgeon's insight and awareness of individualized patient goals for the case (12).

One important factor in the implementation of robotic assistance in spinal surgery is the adaptation and time

investment required to transition from known and mastered conventional surgical techniques to the novel techniques of robotic assistance (9). As discussed at the Annual Seattle Science Foundation Course, one of the key considerations when starting to use robotic assist is to get the staff engaged, because a robot or any enabling technology with large OR footprint translates to significantly more work for staff. Speakers at the Annual Seattle Science Foundation Course shared their approaches for preparing the staff and getting the entire team on board when first implementing new technologies. Prior to implementation in the OR, one team's effective strategy to learn the use of new equipment is to take time to set up the robotic machinery weeks before official implementation and remove it before performing the procedure. Once the introduction and potential use of the robotic equipment was optimized and streamlined after multiple test runs were the OR was comfortable with the components and workflow. Another tip to make the process of integration easier for the staff was to use a double-stacked table with extra trays for the robot for assembly and registration. Additionally, it is recommended to start with familiar "home run" cases, and then implement the new technology gradually to other cases. Organizational workflow is key to effective transition of robotics into the OR. It has even been helpful in some institutions to recruit organizational human engineers to make necessary transitions and changes. Moreover, during troubleshooting, it is important to also have a threshold for removing the robot and falling back to standard fluoroscopy or O-arm navigation. Lastly, bringing a checklist to avoid potential problems if the technology does not let you proceed with registration and execution is a helpful fallback resource when issues arise.

Speakers of the Seattle Science Foundation Course suggested that when integrating robotic assistance technology for screw placement, prior to leaving the OR surgeons should ensure robotic-assisted placement has been accurate without unforeseen navigation errors. Multiple methods exist to confirm screw placement before finishing the case that include (I) intraoperative screw stimulation, (II) transpedicular nanoscope to visualize the transpedicular corridor, and (III) final OR spin to ensure screw and construct position.

### *Pre-operative planning and AR*

Robotics allows efficient and comprehensive preoperative planning with the advent of tools such as planning software

that assists with labeling anatomic landmarks, targeting placement and size of screws, and projecting trajectories (24). Recognition of the biomechanics of spinal forces and landmark nuances are critical in the preoperative surgical planning phase that span indications of spondylolisthesis, congenital lytic deformity, adolescent idiopathic scoliosis, and degenerative conditions. Developing robotic and software technologies promise to transform comprehensive preoperative planning. Importantly, thorough preoperative planning not only enhances preparedness and execution of the case but also saves time in the OR as screw trajectories are set and workflow is more seamless. One study on 28 patients comparing the correction achieved with and without pre-operative planning software demonstrated the use of pre-operative planning software and robotic guidance improved deformity correction 7 degrees in the coronal plane and 10 degrees in the sagittal plane (24).

AR is another novel technology that has recently become increasingly utilized in spinal surgeries, and its use has been shown to increase accuracy, decrease OR time, and improve surgical workflow by allowing for the visualization of anatomy without obscuring the surgical field (25). AR may also improve operative workflow with a microscope operative view that highlights anatomical landmark boundaries and orients the surgeon in real-time (26). This has been shown to aid in decompression and fusion during a MIS transforaminal lumbar interbody fusion (TLIF) procedure from preoperative planning and registration, and facilitates resident/fellow education simultaneously. Heads up display with 2D and 3D depictions on the helmet screen for the surgeon have also been intuitively implemented, and may one day be used for osteotomy and decompression assistance.

Assimilation of the preoperative diagnostics, imaging, demographics into a plan that recognizes spinal biomechanics, loads, and produces a logical plan for levels, grafts, and screw trajectories is possible with artificial intelligence (27-29). Predictive analytics and science applied to preoperative planning allows patient-specific dynamic model that integrates anatomy and biomechanical forces (6). Simulations and other runs can guide approach and treatment options and predict key metrics, including rod stress, bone stress, and proximal junctional kyphosis, distal junctional failure, and cage subsidence. Software that allows finite element modeling and failure analysis may be incorporated into surgical planning to identify previous construct failures and improved surgical plans to optimize construct durability and biomechanical safety (6,30). As



machine learning is increasingly applied to neuroscience and surgical disciplines, advancements in spinal surgery are expected to impact the robotics sphere naturally (13,29,31,32).

### *Cervical spine*

The use of robotics has been integrated into cervical spine surgery more recently than other areas of spine surgery (33). Pedicle screw instrumentation in the cervical spine has superior biomechanical pullout strength and stability (34-36). However, given the complex and variable anatomy of the cervical pedicle and the risk of catastrophic complications, cervical pedicle screw placement is not widely utilized. One of the potential applications of robotic spine surgery, discussed in the Annual Seattle Science Foundation Course, is its incorporation into cervical transpedicular screw placement that can ultimately lead to more rigid fixation and reduce the number of levels fused (15). CT scans show that the C2 pedicles, for example, can accommodate, 98% of the time, a 3.5 mm pedicle screw, and pedicle widths less than 4mm are extremely rare (1.7%) (37). The cervical pedicles are elliptical to triangular in cross section and the medial wall is 1.4 to 3.6 times thicker than the lateral wall. In a retrospective study of their consecutive patients who underwent robotic cervical pedicle screw placement, there were no intra-operative complications related to placement for all 78 screws (28). Any pedicle breaches were medial and less than 1mm, and may have been because the medial wall was pre-drilled and therefore more vulnerable (28). The use of robotic assistance in cervical screw placement has been shown to lead to increases in accuracy of screw placement, decreased intraoperative blood loss, and decreased radiation exposure relative to the previously established methods of fluoroscopy and computer-assisted navigation (33,38).

### *Adult spinal deformity surgery*

Spinal deformity is known to have complication rates as high as 70% morbidity, large number of fixation levels with high variability in surgical approaches lends itself to robotic assistance integration (39-42). Achieving consensus across surgeons is difficult in the many stages of adult spinal deformity surgery, including patient selection, approach, interbody device, osteotomies, instrumentation delivery, and final correction (41,43,44). Gradually, novel technologies including navigation, robot-guided approaches, and patient-

specific rods have been integrated into the treatment of adult spinal deformity (45). These technologies have been shown to increase accuracy of screw placement, reduce complications rates, reduce OR and recovery time, decrease radiation exposure, reduce blood loss, and yield fewer mistakes and lower inter-surgeon variability (45,46). Speakers at the Annual Seattle Science Foundation Course reported that navigation with robotic assistance may offer homogenized work-flow and results in the instrumentation delivery phase that includes pedicle screws and pre-contoured, patient-specific rods. Advantages to robotic assistance in deformity include pre-set screw trajectories and streamline screw insertion that optimize execution. Speakers at the Annual Seattle Science Foundation Course described the use of navigation and robotic assistance in adult spinal deformity surgery. Full-length x-rays may be uploaded to the software and different surgical strategies for deformity correction can be tested and trialed through software. Further, virtual images are generated with various interventions to work toward desired final correction. Once a plan is finalized and sent to the manufacturer, pre-contoured rods are then designed to assume the ideal position set by the surgeon. Robotic assistance in spine surgery incorporates enabling technologies that contribute to standardization of each step in deformity approaches, leading to consistency, potentially more reliable outcomes, and the ability to track and to readjust results in real-time (47). Adjunctive robotic technology has also allowed more stable distal constructs to the pelvis with multiple devices and hardware in particularly narrow corridors (48). Navigation can be further utilized in revision cases where anatomy and overgrowth can be distinctly identified and removed with postoperative evidence of neural decompression.

### *Single-position MIS*

The advent of robotic systems allows screw placement in a manner conducive to single-position surgery (49-52). Oblique lateral approach represents an optimal approach for L4-L5, L5-S1 fusion strategy in single-position. Segments L4-S1 represent a critical junctional segment of the spine in degeneration and deformity biomechanically (53-57). Robotic systems have been incorporated into single-position minimally invasive spine surgeries in recent years in response to concerns related to malposition of screws, nerve and vascular injuries, and radiation exposure resulting from intraoperative fluoroscopy (58). The use of robotic

assistance in pedicle screw placement have been shown to decrease the likelihood of inaccurate placement, increase consistency and precision, minimize radiation exposure, and reduce OR time (58). Speakers of the Annual Seattle Science Foundation Course reported that outcomes of robot-assisted single-position OLIFs, in which single-lateral position is used without flipping or repositioning, increase the efficiency of the approach and reduce risks such as adjacent segment, revision surgeries, and breakdown of the levels above. In the procedure detailed in the Annual Seattle Science Foundation Course, patients are positioned in the lateral decubitus position, using a flat Jackson positioned as close to the edge of the bed as possible to facilitate placement of downside screws with robotic assistance. The robotic system is mounted to the bed and includes a work station and a stealth station while C-arm is used for registration shots.

### *Endoscopy*

Recent years have seen a gradual transition in spinal surgery from conventional open surgery to MIS. In minimally invasive spine surgery, endoscopic spine surgery has become an increasingly important procedure (59,60). With the increase in use and breadth of applications of endoscopic spine surgery, novel technologies including navigation and robotics have become integrated into these procedures (59,60). Endoscopic spine surgery is associated with a significant learning curve, including determination of the ideal approach and trajectory, management of inadvertent deviation from the planned trajectory, and recognition of anatomical landmarks across patient variability (61). Navigation, which has been becoming more prevalent as a tool in endoscopic spine surgery since its first incorporation into these procedures in 2014, offers a solution to flatten the learning curve while also decreasing radiation exposure. It can also help to determine a more precise surgical trajectory, avoid unnecessary collateral damage, and reduce complications (60). Navigation can be applied to endoscopic spine surgery in various ways, for example assisting in the calculations related to the initial stage of endoscopic spine surgery, including determination of the ideal trajectory and incision points to precisely reach the target (59). Navigated spinal endoscopy for 23 patients (including 20 lumbar cases and 3 cervical cases) was shown to be feasible and assist with workflow (62). Robotics and endoscopy have been combined as well, to help with robotic targeting, endoscopic visualization, and planning the interbody

trajectory (21). The impact of full-endoscopic spine surgery is changing practice patterns with highly standardized MIS procedures, quicker discharge home and recovery, reduced radiation exposure, enhanced accuracy (up to 95–100%), and more favorable perioperative complication rates in line with enhanced recovery after surgery (ERAS) protocols (59,60,63). There are certain limitations of incorporating robotic technologies into endoscopic spine surgery. For example, certain robotic systems require the installation of a reference frame, which necessitates additional small incisions, an unfavorable factor in MIS (59). Additionally, the high initial and maintenance costs of robotic instruments could eventually be reflected in the medical costs of the patient (59). Very recently, AR has been introduced as a new emergent technology that can be integrated into endoscopic surgery, allowing the surgeon to view the surgical anatomy through AR eyeglasses. This technology is still in the early stages of development (60,64,65).

### *Cancer therapy*

Robotic assistance has also been implemented into oncological spinal surgeries, including surgery for the treatment of spine tumors (66). One study found that the use of robotic assistance in spinal tumor surgeries led to improved surgical complication rates (66). Several applications exist in robotics for spinal oncological disease and treatments, some of which were described at the Seattle Science Foundation Course. Gross dissection and resection of tumor using DaVinci may be used as an adjunct tool to remove an extradural spinal mass after transpedicular screws are placed, for example. Intraspinal and intradural work may be implemented one day with improvements in haptic feedback and microsurgery techniques of the spine. Additionally, as an alternative to titanium implants and their associated imaging artifact, carbon implants can be utilized with much-improved post-operation imaging or surgeon evaluation, radiation treatment planning, oncological follow-up, and perioperative complication management (67,68). The use of intraoperative radiotherapy (iORT) can also be applied to brain metastases and spine metastases. iORT was originally used (and still mostly utilized) in patients with breast cancer diagnosis. After breast surgery, the applicator is placed in the breast and is used for intraoperative local radiotherapy. In a similar fashion, 100 cases of treatment for brain metastases have utilized this approach. Recently, the iORT approach has been applied to spine metastases and now offers an alternative treatment

option. Intraoperative radiosurgery represents a promising method to reduce postoperative complications, and patients often return home on the fifth or sixth postoperative day without needing to return for additional radiotherapy.

## Discussion

The potential of robotic technology to offer improvements preoperatively, intraoperatively, and postoperatively hold an exciting promise in spine surgery. The integration of robotic assistance in spine surgery has been shown to lead to increased accuracy and precision, reduced complication rates, reduced OR time, and reduced radiation exposure. Navigation technology may improve from the current camera and array setup that is vulnerable to navigation error and technical issue intraoperatively. Moving away from cameras to a new paradigm like electromagnetic (EM) navigation used more commonly in cranial procedures may limit hold-ups and OR-time prolongation from routine technical issues. Industry partnership and communication may help move this frontier forward. Improvements in bone graft placement to limit cage migration and subsequent complications and reoperation. Augmented reality and artificial intelligence offer methods to bridge the gap between preoperative diagnostics and imaging and the surgical execution to achieve individualized patient results with improved outcomes. Robotics serve as decision-support tools that will assist surgeon practice through data collection and construct failure analysis. Enhanced efficiency in future models with greater capabilities with imaging modality integration, not just 3D CT scans. Robots may one day also reach more automated levels of finer decompressions such as particular laminectomy depth, facetectomy and handling of soft tissue or mass resection. Semi-autonomous versus more surgeon-controlled haptic feedback are different modes perhaps that could be explored. Reducing the OR footprint with improved portability of machines that has been shown to improve efficiency and OR time and continue to improve (11). Increasing user-friendliness and lowering costs of machines may lower thresholds for widespread hospital and surgeon adoption. A limitation of this review is that by nature of its role as a scoping review, it provides more analysis on the breadth and scope of research on these topics than on in-depth detailed analysis on any one specific subtopic.

## Conclusions

Robotic-assisted spine surgery may be used for cervical transpedicular fusion, bone graft placement, and neuro-oncologic management. Integration in the OR may encourage broad application of robotic assistance across spinal sub-disciplines. Preoperative planning may bolster the clinical value of robotic technology in spine surgery. As this technology advances, increased accuracy and precision of instrumentation placement, reduced radiation exposure, limited time under anesthesia, and decreased invasiveness of spinal surgery highlight some of the more well-known benefits of its adoption. The nexus of complementary technologies including artificial intelligence, AR, robotics, and navigation may offer streamlined procedures with improved patient outcomes and educational benefit in training.

## Acknowledgments

*Funding:* None.

## Footnote

*Reporting Checklist:* The authors have completed the PRISMA-ScR reporting checklist. Available at <https://atm.amegroups.com/article/view/10.21037/atm-24-100/rc>

*Peer Review File:* Available at <https://atm.amegroups.com/article/view/10.21037/atm-24-100/prf>

*Conflicts of Interest:* All authors have completed the ICMJE uniform disclosure form (available at <https://atm.amegroups.com/article/view/10.21037/atm-24-100/coif>). The authors have no conflicts of interest to declare.

*Ethical Statement:* The authors are accountable for all aspects of the work in ensuring that questions related to the accuracy or integrity of any part of the work are appropriately investigated and resolved.

*Open Access Statement:* This is an Open Access article distributed in accordance with the Creative Commons Attribution-NonCommercial-NoDerivs 4.0 International License (CC BY-NC-ND 4.0), which permits the non-



commercial replication and distribution of the article with the strict proviso that no changes or edits are made and the original work is properly cited (including links to both the formal publication through the relevant DOI and the license). See: <https://creativecommons.org/licenses/by-nc-nd/4.0/>.

## References

- Roser F, Tatagiba M, Maier G. Spinal robotics: current applications and future perspectives. *Neurosurgery* 2013;72 Suppl 1:12-8.
- Vaccaro AR, Harris JA, Hussain MM, et al. Assessment of Surgical Procedural Time, Pedicle Screw Accuracy, and Clinician Radiation Exposure of a Novel Robotic Navigation System Compared With Conventional Open and Percutaneous Freehand Techniques: A Cadaveric Investigation. *Global Spine J* 2020;10:814-25.
- Fatima N, Massaad E, Hadzipasic M, et al. Safety and accuracy of robot-assisted placement of pedicle screws compared to conventional free-hand technique: a systematic review and meta-analysis. *Spine J* 2021;21:181-92.
- Pham MH, Diaz-Aguilar LD, Shah V, et al. Simultaneous Robotic Single Position Oblique Lumbar Interbody Fusion With Bilateral Sacropelvic Fixation in Lateral Decubitus. *Neurospine* 2021;18:406-12.
- Hernandez NS, Diaz-Aguilar LD, Pham MH. Single position L5-S1 lateral ALIF with simultaneous robotic posterior fixation is safe and improves regional alignment and lordosis distribution index. *Eur Spine J* 2024;33:3583-92.
- Lieberman IH, Kisinde S, Hesselbacher S. Robotic-Assisted Pedicle Screw Placement During Spine Surgery. *JBJS Essent Surg Tech* 2020;10:e0020.
- Hu X, Lieberman IH. What is the learning curve for robotic-assisted pedicle screw placement in spine surgery? *Clin Orthop Relat Res* 2014;472:1839-44.
- D'Souza M, Gendreau J, Feng A, et al. Robotic-Assisted Spine Surgery: History, Efficacy, Cost, And Future Trends. *Robot Surg* 2019;6:9-23.
- Lopez IB, Benzakour A, Mavrogenis A, et al. Robotics in spine surgery: systematic review of literature. *Int Orthop* 2023;47:447-56.
- Parker SL, McGirt MJ, Farber SH, et al. Accuracy of free-hand pedicle screws in the thoracic and lumbar spine: analysis of 6816 consecutive screws. *Neurosurgery* 2011;68:170-8; discussion 178.
- Soliman MA, Khan A, O'Connor TE, et al. Accuracy and Efficiency of Fusion Robotics™ Versus Mazor-X™ in Single-Level Lumbar Pedicle Screw Placement. *Cureus* 2021;13:e15939.
- Park C, Shabani S, Agarwal N, et al. Robotic-Assisted Surgery and Navigation in Deformity Surgery. *Neurosurg Clin N Am* 2023;34:659-64.
- Browd SR, Park C, Donoho DA. Potential Applications of Artificial Intelligence and Machine Learning in Spine Surgery Across the Continuum of Care. *Int J Spine Surg* 2023;17:S26-33.
- Good CR, Orosz L, Schroerlucke SR, et al. Complications and Revision Rates in Minimally Invasive Robotic-Guided Versus Fluoroscopic-Guided Spinal Fusions: The MIS ReFRESH Prospective Comparative Study. *Spine (Phila Pa 1976)* 2021;46:1661-8.
- Zhou LP, Zhang RJ, Sun YW, et al. Accuracy of Pedicle Screw Placement and Four Other Clinical Outcomes of Robotic Guidance Technique versus Computer-Assisted Navigation in Thoracolumbar Surgery: A Meta-Analysis. *World Neurosurg* 2021;146:e139-50.
- Shahi P, Vaishnav A, Araghi K, et al. Robotics Reduces Radiation Exposure in Minimally Invasive Lumbar Fusion Compared With Navigation. *Spine (Phila Pa 1976)* 2022;47:1279-86.
- Menger RP, Savardekar AR, Farokhi F, et al. A Cost-Effectiveness Analysis of the Integration of Robotic Spine Technology in Spine Surgery. *Neurospine* 2018;15:216-24.
- Passias PG, Brown AE, Alas H, et al. A cost benefit analysis of increasing surgical technology in lumbar spine fusion. *Spine J* 2021;21:193-201.
- Härtl R, Lam KS, Wang J, et al. Worldwide survey on the use of navigation in spine surgery. *World Neurosurg* 2013;79:162-72.
- Hsu BH, Liu HW, Lee KL, et al. Learning Curve of ROSA ONE Spine System for Transpedicular Screw Placement. *Neurospine* 2022;19:367-75.
- Bai YS, Zhang Y, Chen ZQ, et al. Learning curve of computer-assisted navigation system in spine surgery. *Chin Med J (Engl)* 2010;123:2989-94.
- Kam JKT, Gan C, Dimou S, et al. Learning Curve for Robot-Assisted Percutaneous Pedicle Screw Placement in Thoracolumbar Surgery. *Asian Spine J* 2019;13:920-7.
- Pennington Z, Judy BF, Zakaria HM, et al. Learning curves in robot-assisted spine surgery: a systematic review and proposal of application to residency curricula. *Neurosurg Focus* 2022;52:E3.
- Kisinde S, Hu X, Hesselbacher S, et al. The predictive accuracy of surgical planning using pre-op planning

- software and a robotic guidance system. *Eur Spine J* 2021;30:3676-87.
25. Burström G, Persson O, Edström E, et al. Augmented reality navigation in spine surgery: a systematic review. *Acta Neurochir (Wien)* 2021;163:843-52.
  26. Sommer F, Hussain I, Kirnaz S, et al. Augmented Reality to Improve Surgical Workflow in Minimally Invasive Transforaminal Lumbar Interbody Fusion - A Feasibility Study With Case Series. *Neurospine* 2022;19:574-85.
  27. Satin AM, Kisinde S, Lieberman IH. Robotic-Assisted Revision Spine Surgery. *Int J Spine Surg* 2022;16:S14-21.
  28. Kisinde S, Hu X, Hesselbacher S, et al. Robotic-guided placement of cervical pedicle screws: feasibility and accuracy. *Eur Spine J* 2022;31:693-701.
  29. Rasouli JJ, Shao J, Neifert S, et al. Artificial Intelligence and Robotics in Spine Surgery. *Global Spine J* 2021;11:556-64.
  30. Hyun SJ, Jung JM, Kim KJ, et al. Durability and Failure Types of S2-Alar-Iliac Screws: An Analysis of 312 Consecutive Screws. *Oper Neurosurg (Hagerstown)* 2020;20:91-7.
  31. Dietz N, Vaitheesh Jaganathan, Alkin V, et al. Machine learning in clinical diagnosis, prognostication, and management of acute traumatic spinal cord injury (SCI): A systematic review. *J Clin Orthop Trauma* 2022;35:102046.
  32. English M, Kumar C, Ditterline BL, et al. Machine Learning in Neuro-Oncology, Epilepsy, Alzheimer's Disease, and Schizophrenia. *Acta Neurochir Suppl* 2022;134:349-61.
  33. Beyer RS, Nguyen A, Brown NJ, et al. Spinal robotics in cervical spine surgery: a systematic review with key concepts and technical considerations. *J Neurosurg Spine* 2023;38:66-74.
  34. Jones EL, Heller JG, Silcox DH, et al. Cervical pedicle screws versus lateral mass screws. Anatomic feasibility and biomechanical comparison. *Spine (Phila Pa 1976)* 1997;22:977-82.
  35. Johnston TL, Karaikovic EE, Lautenschlager EP, et al. Cervical pedicle screws vs. lateral mass screws: uniplanar fatigue analysis and residual pullout strengths. *Spine J* 2006;6:667-72.
  36. Ito Z, Higashino K, Kato S, et al. Pedicle screws can be 4 times stronger than lateral mass screws for insertion in the midcervical spine: a biomechanical study on strength of fixation. *J Spinal Disord Tech* 2014;27:80-5.
  37. Burke LM, Yu WD, Ho A, et al. Anatomical feasibility of C-2 pedicle screw fixation: the effect of variable angle interpolation of axial CT scans. *J Neurosurg Spine* 2013;18:564-7.
  38. Lebl DR, Avrumova F, Abjornson C, et al. Cervical Spine Navigation and Enabled Robotics: A New Frontier in Minimally Invasive Surgery. *HSS J* 2021;17:333-43.
  39. Dietz N, Gruter BE, Nevzati E, et al. Compensatory mechanisms in adult degenerative thoracolumbar spinal deformity - Radiographic patterns, their reversibility after corrective surgery, and the influence of pelvic morphology. *J Craniovertebr Junction Spine* 2022;13:454-9.
  40. Spiessberger A, Dietz N, Gruter BE, et al. Restoring Segmental Spinal Alignment in Mini-Open Lateral Spinal Deformity Surgery-Determiners of Radiographic Outcome. *Int J Spine Surg* 2022;16:540-7.
  41. Wang MY, Mummaneni PV. Minimally invasive surgery for thoracolumbar spinal deformity: initial clinical experience with clinical and radiographic outcomes. *Neurosurg Focus* 2010;28:E9.
  42. Chen X, Feng F, Yu X, et al. Robot-assisted orthopedic surgery in the treatment of adult degenerative scoliosis: a preliminary clinical report. *J Orthop Surg Res* 2020;15:282.
  43. Mummaneni PV, Park P, Shaffrey CI, et al. The MISDEF2 algorithm: an updated algorithm for patient selection in minimally invasive deformity surgery. *J Neurosurg Spine* 2020;32:221-8.
  44. Mummaneni PV, Haid RW, Rodts GE. Lumbar interbody fusion: state-of-the-art technical advances. Invited submission from the Joint Section Meeting on Disorders of the Spine and Peripheral Nerves, March 2004. *J Neurosurg Spine* 2004;1:24-30.
  45. Patel AV, White CA, Schwartz JT, et al. Emerging Technologies in the Treatment of Adult Spinal Deformity. *Neurospine* 2021;18:417-27.
  46. Kim HJ, Yang JH, Chang DG, et al. Adult Spinal Deformity: A Comprehensive Review of Current Advances and Future Directions. *Asian Spine J* 2022;16:776-88.
  47. Schmidt FA, Lekuya HM, Kirnaz S, et al. Novel MIS 3D NAV Single Step Pedicle Screw System (SSPSS): Workflow, Accuracy and Initial Clinical Experience. *Global Spine J* 2022;12:1098-108.
  48. Martin CT, Holton KJ, Jones KE, et al. Bilateral open sacroiliac joint fusion during adult spinal deformity surgery using triangular titanium implants: technique description and presentation of 21 cases. *J Neurosurg Spine* 2022;36:86-92.
  49. Huntsman KT, Riggelman JR, Ahrendtsen LA, et al. Navigated robot-guided pedicle screws placed successfully in single-position lateral lumbar interbody fusion. *J Robot*

- Surg 2020;14:643-7.
50. Sinkov V, Lockey SD, Cunningham BW. Single Position Lateral Lumbar Interbody Fusion With Posterior Instrumentation Utilizing Computer Navigation and Robotic Assistance: Retrospective case review and surgical technique considerations. *Global Spine J* 2022;12:75S-81S.
  51. Fayed I, Tai A, Triano M, et al. Robot-Assisted Percutaneous Pedicle Screw Placement: Evaluation of Accuracy of the First 100 Screws and Comparison with Cohort of Fluoroscopy-guided Screws. *World Neurosurg* 2020;143:e492-502.
  52. Diaz-Aguilar LD, Shah V, Himstead A, et al. Simultaneous Robotic Single-Position Surgery (SR-SPS) with Oblique Lumbar Interbody Fusion: A Case Series. *World Neurosurg* 2021;151:e1036-43.
  53. Bari TJ, Heegaard M, Bech-Azeddine R, et al. Lordosis Distribution Index in Short-Segment Lumbar Spine Fusion - Can Ideal Lordosis Reduce Revision Surgery and Iatrogenic Deformity? *Neurospine* 2021;18:543-53.
  54. Zheng G, Wang C, Wang T, et al. Relationship between postoperative lordosis distribution index and adjacent segment disease following L4-S1 posterior lumbar interbody fusion. *J Orthop Surg Res* 2020;15:129.
  55. Lafage R, Schwab F, Elysee J, et al. Surgical Planning for Adult Spinal Deformity: Anticipated Sagittal Alignment Corrections According to the Surgical Level. *Global Spine J* 2022;12:1761-9.
  56. Xu F, Sun Z, Li W, et al. Correlation between lordosis distribution index, lordosis tilt, and occurrence of proximal junctional kyphosis following surgery for adult degenerative scoliosis. *Eur Spine J* 2022;31:267-74.
  57. Nevzati E, Moser M, Dietz N, et al. Clinically relevant biomechanical properties of three different fixation techniques of the upper instrumented vertebra in deformity surgery. *Spine Deform* 2022;10:1017-27.
  58. Vo CD, Jiang B, Azad TD, et al. Robotic Spine Surgery: Current State in Minimally Invasive Surgery. *Global Spine J* 2020;10:34S-40S.
  59. Hahn BS, Park JY. Incorporating New Technologies to Overcome the Limitations of Endoscopic Spine Surgery: Navigation, Robotics, and Visualization. *World Neurosurg* 2021;145:712-21.
  60. Jitpakdee K, Liu Y, Heo DH, et al. Minimally invasive endoscopy in spine surgery: where are we now? *Eur Spine J* 2023;32:2755-68.
  61. Choi G, Pophale CS, Patel B, et al. Endoscopic Spine Surgery. *J Korean Neurosurg Soc* 2017;60:485-97.
  62. Shin Y, Sunada H, Shiraishi Y, et al. Navigation-assisted full-endoscopic spine surgery: a technical note. *J Spine Surg* 2020;6:513-20.
  63. Dietz N, Sharma M, Adams S, et al. Enhanced Recovery After Surgery (ERAS) for Spine Surgery: A Systematic Review. *World Neurosurg* 2019;130:415-26.
  64. Carl B, Bopp M, Saß B, et al. Implementation of augmented reality support in spine surgery. *Eur Spine J* 2019;28:1697-711.
  65. Jamshidi AM, Makler V, Wang MY. Augmented Reality Assisted Endoscopic Transforaminal Lumbar Interbody Fusion: 2-Dimensional Operative Video. *Oper Neurosurg (Hagerstown)* 2021;21:E563-4.
  66. Hu X, Scharschmidt TJ, Ohnmeiss DD, et al. Robotic assisted surgeries for the treatment of spine tumors. *Int J Spine Surg* 2015;9:1.
  67. Kumar N, Lopez KG, Alathur Ramakrishnan S, et al. Evolution of materials for implants in metastatic spine disease till date - Have we found an ideal material? *Radiother Oncol* 2021;163:93-104.
  68. Müller BS, Ryang YM, Oechsner M, et al. The dosimetric impact of stabilizing spinal implants in radiotherapy treatment planning with protons and photons: standard titanium alloy vs. radiolucent carbon-fiber-reinforced PEEK systems. *J Appl Clin Med Phys* 2020;21:6-14.

**Cite this article as:** Dietz N, Alkin V, Lieberman I, Manista A, Kim T, Johnson JP, Drazin D. Scoping review of robotics technology in spinal surgery with highlights of the Annual Seattle Science Foundation Course. *Ann Transl Med* 2024;12(6):118. doi: 10.21037/atm-24-100