



# Cementless tapered wedge stems in patients undergoing primary total hip arthroplasty with Dorr C bone – are complication risks increased?

Jonathon Lindner<sup>1</sup>, Jonathan Napier<sup>2</sup>, Anthony Feher<sup>3</sup>, Heather S. Haeberle<sup>4</sup>, Linsen T. Samuel<sup>5</sup>, Michael A. Mont<sup>6</sup>, Ronald Delanois<sup>7</sup>, Arthur L. Malkani<sup>8</sup>

<sup>1</sup>Department of Orthopaedic Surgery, University of Louisville, Louisville, KY, USA; <sup>2</sup>Department of Emergency Medicine, University of Kentucky, Lexington, KY, USA; <sup>3</sup>Franciscan Health Total Joint Reconstruction, Carmel, IN, USA; <sup>4</sup>Baylor College of Medicine, Houston, TX, USA; <sup>5</sup>Department of Orthopaedic Surgery, Cleveland Clinic, Cleveland, OH, USA; <sup>6</sup>Department of Orthopaedic Surgery, Lenox Hill Hospital, Northwell Health, New York, NY, USA; <sup>7</sup>Rubin Institute for Advanced Orthopedics, Owings Mills, MD, USA; <sup>8</sup>Adult Reconstruction Program, University of Louisville, Louisville, KY, USA

*Contributions:* (I) Conception and design: AL Malkani, R Delanois, MA Mont; (II) Administrative support: None; (III) Provision of study materials or patients: J Napier, HS Haeberle; (IV) Collection and assembly of data: J Napier, HS Haeberle, LT Samuel; (V) Data analysis and interpretation: J Lindner, A Feher, LT Samuel, HS Haeberle; (VI) Manuscript writing: All authors; (VII) Final approval of manuscript: All authors.

*Correspondence to:* Arthur L. Malkani, MD. Adult Reconstruction Program, University of Louisville, 201 Abraham Flexner Way, Street 100, Louisville, KY 40202, USA. Email: arthur.malkani@louisville.edu.

**Background:** The use of cementless femoral stems in patients undergoing primary total hip arthroplasty (THA) with Dorr C bone remains controversial for fear of fracture or subsidence. Purpose of this multicenter study was to compare clinical outcomes and complications of THA using a tapered femoral prosthesis in patients with Dorr C bone versus Dorr A/B bone.

**Methods:** A total of 1,030 patients underwent primary THA with a tapered wedge femoral stem at a minimum one year follow up. Forty-eight patients with Dorr C bone (mean age 68.7 years) were compared with a matched cohort of patients with Dorr A/B bone (mean age 69.9 years). Mean follow-up was approximately 4 years in both cohorts. There were no differences in sex, age, body mass index (BMI), Harris Hip Score (HHS), complications, and radiographic outcomes including subsidence and aseptic loosening were evaluated.

**Results:** Postoperative HHSs were a mean of 82 points in the Dorr C cohort compared to 84 points in the Dorr A/B cohort ( $P=0.2653$ ). There was no significant difference in complication or revision rates for any reason ( $P=0.23$ ). Mean subsidence for the Dorr C and Dorr A/B was 1.4 and 1.2 mm, respectively ( $P=0.5164$ ), and there was no aseptic loosening of the femoral component found in either group.

**Conclusions:** Current generation tapered wedge cementless femoral stems provide stable fixation for patients with Dorr C bone quality without increased complications with respect to fracture or subsidence and can be considered an alternative to cemented stems in patients with compromised bone quality.

**Keywords:** Primary total hip arthroplasty (primary THA); Dorr C bone; tapered wedge cementless femoral stem; clinical outcomes; complications; radiographic outcomes

Submitted Aug 13, 2019. Accepted for publication Aug 28, 2019. Published online Sep 23, 2019.

doi: 10.21037/atm.2019.08.124

View this article at: <http://dx.doi.org/10.21037/atm.2019.08.124>

## Introduction

With increases in lifespan, the number of elderly patients undergoing primary total hip arthroplasty (THA) continues to grow (1). THA in this group presents a challenge due to the increased risk of medical and surgical complications (2). The optimal method of femoral fixation in these elderly patients remains controversial due to commonly found compromised proximal femoral bone stock, often classified as Dorr type C bone (*Figure 1*) (3).

According to the Dorr classification system, proximal femoral bone quality may be classified as type A (thick cortices and narrow intramedullary canal), type B (thinning of posterior cortical wall), or type C (thin cortices and wide intramedullary canal) (3,4). Specifically, with the growing use of cementless tapered femoral stems, the outcomes of these implants in patients with suboptimal bone quality need to be examined.

Cementless tapered femoral stems for primary THA are the standard for the treatment of primary hip osteoarthritis in younger patients, relying on immediate implant stability for success (5). However, cementless THA in the elderly remains controversial for fear of fracture or component subsidence (6). Methylmethacrylate is commonly used for stem fixation in patients with Dorr C bone undergoing definitive treatment of hip osteoarthritis (7). However, the use of cemented femoral stems in general has declined due to challenges in obtaining a consistent and reproducible cement mantle for long-term durable fixation. Additionally, the use of cement can lead to medical complications including pulmonary and cardiac collapse, fat embolism, as well as increased operative time (8-12). Therefore, there has been increased interest in the use of cementless THA in older patients with compromised bone quality (5,13).

Given the controversy concerning femoral fixation in suboptimal bone, the purpose of this multicenter study was to compare: (I) clinical outcomes and (II) complications mainly with respect to fracture and subsidence using a tapered femoral prosthesis in patients with Dorr type C versus A/B bone undergoing primary THA.

## Methods

This study was conducted in accordance to the Helsinki declaration and approved by institutional/regional/national ethics/committee/ethics board of The University of Louisville Institutional Review Board (No. 16.1002) and informed consent was taken from all the patients.

Following the various Institutional Review Board approvals, a multicenter review at two different institutions was conducted, including 1,030 patients who underwent primary THA from 2004 to 2015 with a tapered wedge cementless femoral stem. All preoperative hip radiographs were categorized using the Dorr classification system (*Figure 1*) (3). During this period, 48 patients with Dorr C bone who underwent THA were identified. This cohort included 38 females and 10 males who had a mean age of 69 years (range, 51 to 91 years), a mean body mass index (BMI) of 30.5 kg/m<sup>2</sup> (range, 19.8 to 43.4 kg/m<sup>2</sup>), a mean Charlson Comorbidity Index (CCI) of 1.3 (range, 0 to 9), and a mean follow-up of 50.6 months (range, 24.0 to 85 months). These patients were compared to a matched cohort of 48 patients with Dorr A/B bone, matched for age, sex, and BMI. This cohort included 38 females and 10 males who had a mean age of 70 years (range, 50 to 91 years), a mean BMI of 31.1 kg/m<sup>2</sup> (range, 20.7 to 50.2 kg/m<sup>2</sup>), a mean CCI of 1.9 (range, 0 to 4), and a mean follow-up of 46.9 months (range, 24 to 71 months) (*Table 1*).

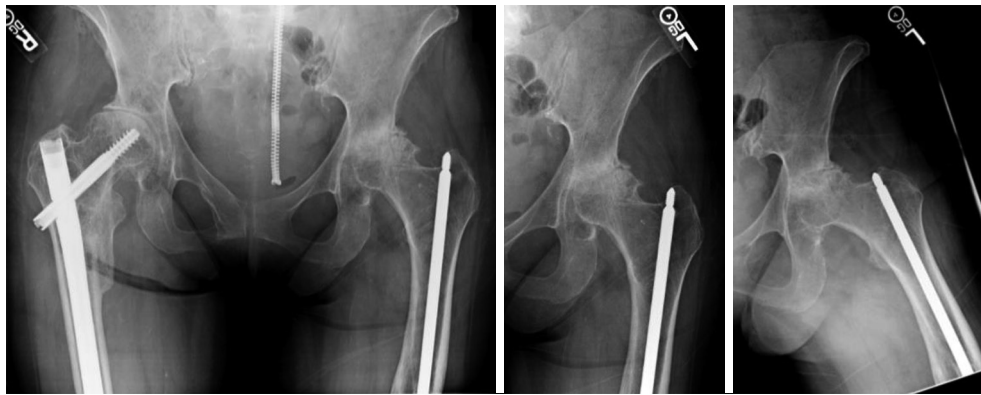
All THAs were performed using hydroxyapatite tapered femoral stems (Stryker Accolade I or II<sup>TM</sup>, Mahwah, New Jersey) in the lateral decubitus position through either a posterior or direct lateral approach (14). The Accolade I<sup>TM</sup> TMZF component is a titanium-alloy cementless stem with a PureFix hydroxyapatite coating (15). Compared to the first generation design, the Accolade II<sup>TM</sup> stem is shorter, has an enhanced proximal fit, and utilizes titanium Ti6Al4V alloy (15,16). Despite these minor design differences, these implants rely on similar fixation principles. All patients were immediately full weight bearing postoperatively and started physical therapy on the day of surgery.

Demographic, clinical, and surgical data were extracted from the institutions' total joint registries. Clinical outcomes were evaluated using preoperative and postoperative Harris Hip Scores (HHSs) (17). Complications including fracture, dislocation, and infection were recorded.

Postoperative anteroposterior (AP) pelvis and AP and lateral hip X-rays were evaluated for femoral component subsidence or loosening (*Figure 2*) (18,19).

Subsidence was measured using bony landmarks in the AP radiograph. Magnification differences between time intervals were controlled for by knowing and measuring the size of the implanted femoral head.

Student *t*-tests were performed to evaluate significant differences in demographic variables (age, BMI, CCI), HHSs, composite revision rates, and subsidence between the two groups. All data analyses were performed using



**Figure 1** Preoperative X-rays of a 67-year-old patient with a history of osteoporosis, previous retained hardware and severe left hip osteoarthritis.

**Table 1** Demographic data

Variables	Dorr A/B	Dorr C	P value
Total patients	48	49	–
Mean follow-up (month)	46.9	50.6	0.2751
Demographics			
Mean age, years	69.9	68.7	0.5409
Females	38	38	–
Males	10	10	–
Mean BMI, kg/m <sup>2</sup>	31.1	30.5	0.6329
Mean CCI	1.9	1.3	0.0455

BMI, body mass index; CCI, Charlson Comorbidity Index.

SPSS 22 (IBM Corp., Armonk, NY, USA). A P value of 0.05 was set to determine statistical significance.

## Results

### Clinical outcomes

There were no significant differences in the postoperative HHS ( $P=0.2653$ ) or the change in HHS ( $P=0.9320$ ) between the two cohorts (Table 2).

In patients with Dorr C bone, pre- and postoperative mean HHSs were 49 points (range, 8 to 85 points) and 82 points (range, 50 to 99 points), respectively, with a mean improvement in HHS of 44 points. The Dorr A/B pre- and postoperative mean HHSs were 44 points (range, 28 to 74 points) and 84 points (range, 68 to 99 points), respectively, with a mean improvement in HHS

of 44 points.

### Complications

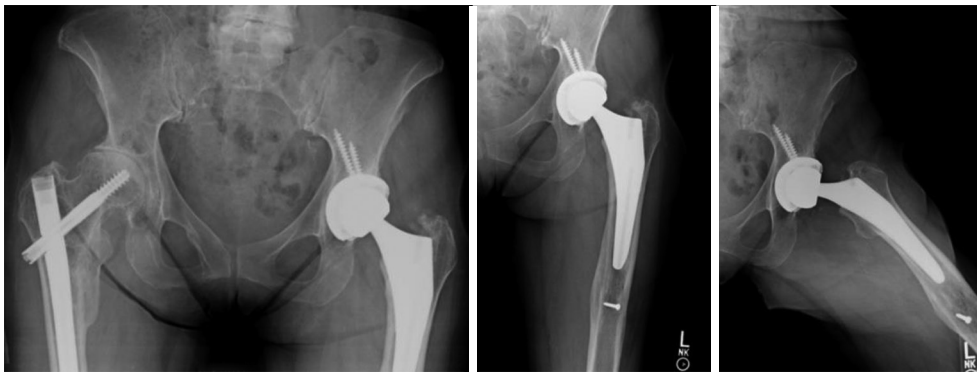
Overall, there were three complications in the Dorr C group and one complication in the Dorr A/B group (Table 2). There were no intraoperative fractures or immediate postoperative fractures in either cohort. In the Dorr C group, one patient dislocated during the first year following the index procedure but did not require a revision surgery. There was one case of postoperative prosthetic infection requiring revision surgery in the Dorr C group. In each group, one patient had a fall more than 1 year postoperatively, sustaining a periprosthetic femur fracture requiring revision. There was no difference in revisions for any reason ( $P=0.232$ ).

### Radiographic outcomes

The mean 1-year subsidence of the Dorr C and A/B groups were 1.4 mm (range, 0 to 6 mm) and 1.2 mm (range, 0 to 5 mm) respectively ( $P=0.5164$ ). Neither group had signs of postoperative aseptic loosening of the femoral component, but 2 patients in the Dorr C group had aseptic loosening of the acetabular component (Table 2).

### Discussion

Although THA initially utilized cemented fixation with excellent results, the use of methylmethacrylate is not without risk, as it is associated with complications including loosening, osteolysis, pulmonary embolism, and cement



**Figure 2** Postoperative X-rays of a 67-year-old patient demonstrating a stable, well-fixed tapered wedge Accolade II implant.

**Table 2** Clinical outcomes, complications, and radiographic outcomes

Outcomes	Dorr A/B	Dorr C	P value
Preoperative HHS (mean)	44.4	49.4	0.2192
Postoperative HHS (mean)	84.3	81.7	0.2653
Change in HHS (mean)	44.4	43.9	0.9320
Intraoperative fractures	0	0	–
Postoperative periprosthetic fractures	1	1	–
Postoperative dislocation	0	1	–
Infections requiring revision	0	1	–
Mean one year subsidence (mm)	1.2	1.4	0.5164
Aseptic loosening of acetabular component	0	2	–
Aseptic loosening of femoral component	0	0	–

HHS, Harris Hip Score.

toxicity (10,11,20,21). The utilization of cemented THA has declined markedly due to the advent of cementless designs, with growing interest in the use of cementless femoral stems in elderly patients given the success of long-term biologic fixation (13). Yet, due to need for immediate and rigid implant fixation with the use of cementless implants, there is a concern for fracture and subsidence in patients with compromised host bone quality, such as those with Dorr C bone (22). In this study, we demonstrated that patients with Dorr C bone undergoing cementless THA achieved similar clinical outcomes, complication rates, and radiographic outcomes to those with Dorr A/B bone.

This study is not without limitations. This is a small

consecutive series with only 51 primary THA patients who had Dorr C bone receiving a tapered cementless implant. We expect this proportion to rise given the projected increase in the number of elderly patients undergoing primary THA over the next decade. However, this number is consistent with other series in the literature using cementless femoral implants in Dorr C bone, with a total of 210 cases reported in 4 series (Table 3).

Additionally, this is a short-term study with one-year minimum follow-up, and longer-term follow-up may be necessary to fully evaluate any differences between these two groups. Despite these limitations, we believe the results of this multicenter matched cohort study are valuable in understanding the excellent initial outcomes in patients with poor bone quality following cementless THA.

Many studies have demonstrated excellent radiographic, functional, and clinical outcomes of patients undergoing primary THA utilizing a tapered uncemented femoral component. Kolisek *et al.* demonstrated a 0.3% femoral component revision rate at 5 years using a tapered cementless femoral implant in 936 patients (26). Pierce *et al.* reported 5-year aseptic and all-cause survivorship rates of 99.4% and 97.9%, respectively, for the femoral component used in this study (27). However, very few studies have stratified outcomes based on Dorr bone classification (Table 3). For example, Issa *et al.* demonstrated that a cementless tapered stem system has the ability for stable fixation for all Dorr types due to variation in the medial and lateral dimensions based on the stem size (15). In a study including 127 patients with Dorr C bone, Meding *et al.* demonstrated no difference in aseptic survivorship, HHSs, or radiographic outcomes between the Dorr type A, B, or C cohorts (13). Similarly, in the present study, no significant

**Table 3** Current review of literature outcomes of cementless THA in Dorr C bone

Author	Hips (number)	Dorr C hips (number)	Average age (years)	Follow-up (years)	Overall aseptic survivorship (%)	HHS at last follow-up
Berend <i>et al.</i> (23)	96	48	79	5	97.96	84
Hozack <i>et al.</i> (24)	105	5	61.2	6.1	99	88.6
Meding <i>et al.</i> (13)	2,321	127	61	5.9	99.99	93.2
McLaughlin <i>et al.</i> (25)	350	68	69	20	98	89
Lindner <i>et al.</i>	98	49	68.7	4.2	100	81.7

THA, total hip arthroplasty; HHS, Harris Hip score.

difference was found in postoperative HHSs between the Dorr type C and Dorr A/B cohorts.

In patients with Dorr C bone quality, attempting to provide rigid and stable fixation with tapered stems against cortical bone can lead to fracture unless the technique for broaching and stem insertion are performed in a careful manner. The variation in the femoral canal medial and lateral fit in the stem design utilized in this study allowed for excellent fit in all bone types, minimizing the risk of fracture. The present study demonstrated similar rates of intraoperative and postoperative periprosthetic femoral fracture between the Dorr C and the Dorr A/B groups. This is in contrast to the finding by Gromov *et al.* that Dorr C bone resulted in a five-fold increase in the risk of periprosthetic femur fracture compared to Dorr B bone in a cohort of 1,441 patients ( $P < 0.001$ ) (7). However, not all cementless femoral stems are the same and the type of cementless stem design is a risk factor for fracture (28-30). In the present study, there was 1 dislocation in the Dorr C group (2%) and no dislocations in the Dorr A/B group. Recent studies have shown the incidence of dislocation following primary THA to approach 2%, which is comparable to the rate demonstrated in this study (31). There were similar rates of prosthetic joint infection between the two groups in this study, with one infection in the Dorr C group and no infections in the Dorr A/B group.

In terms of radiographic outcomes, there was no significant difference between Dorr C and A/B groups at one year with respect to subsidence. There were no cases of aseptic loosening of the femoral component in either group. These findings are consistent with the findings of Riley *et al.* who found 2-year aseptic survivorship of cementless femoral components to be 99% in a cohort of 74 patients aged 80 years or older (5).

With the marked rise of the use of cementless femoral

components over the past decade, surgeons may feel inclined to use cementless stems in Dorr C bone due to their comfort level using the same predictable and reproducible surgical technique. This study demonstrates clinical and radiographic success of THA with cementless tapered femoral stems in patients with compromised proximal femoral bone stock. We did not identify an increased risk of complications in the Dorr C group especially with respect to intraoperative fracture or subsidence. With careful surgical technique, cementless tapered wedge stems are a viable alternative to cemented femoral fixation in patients with Dorr C bone undergoing primary THA.

## Conclusions

Current generation tapered wedge cementless femoral stems provide stable fixation for patients with Dorr C bone quality without increased complications with respect to fracture or subsidence and can be considered an alternative to cemented stems in patients with compromised bone quality.

## Acknowledgments

*Funding:* None.

## Footnote

*Conflicts of Interest:* All authors have completed the ICMJE uniform disclosure form (available at <https://atm.amegroups.com/article/view/10.21037/atm.2019.08.124/coif>). RD declares the following outside of the submitted work: Baltimore City Medical Society: board or committee member; Flexion Therapeutics: research support; Orthofix, Inc.: research support; Stryker: research support; tissue

Gene: research support; United Orthopedics: research support. MAM declares the following outside of the submitted work: AAOS: board or committee member; American Association of Hip and Knee Surgeons: board or committee member; Cymedica: paid consultant; DJ Orthopaedics: paid consultant; research support; Flexion Therapeutics: paid consultant; Johnson & Johnson: paid consultant; research support; *Journal of Arthroplasty*: editorial or governing board; *Journal of Knee Surgery*: editorial or governing board; Knee Society: board or committee member; Medicus Works LLC: publishing royalties, financial or material support; Microport: IP royalties; National Institutes of Health (NIAMS & NICHD): research support; Ongoing Care Solutions: paid consultant; research support; *Orthopedics*: editorial or governing board; Orthosensor: paid consultant; research support; Pacira: paid consultant; Peerwell: paid consultant; stock or stock options; Performance Dynamics: paid consultant; Pfizer: paid consultant; Skye Biologics: paid consultant; Stryker: IP royalties; paid consultant; research support; *Surgical Techniques International*: editorial or governing board; TissueGene: paid consultant; research support; Up-to-Date: publishing royalties, financial or material support; USMI: stock or stock options; Wolters Kluwer Health-Lippincott Williams & Wilkins: publishing royalties, financial or material support. ALM declares the following outside of the submitted work: AAOS: board or committee member; *Journal of Arthroplasty*: editorial or governing board; Stryker: IP royalties; paid consultant; paid presenter or speaker; research support. The other authors have no conflicts of interest to declare.

**Ethical Statement:** The authors are accountable for all aspects of the work in ensuring that questions related to the accuracy or integrity of any part of the work are appropriately investigated and resolved. This study was conducted in accordance to the Helsinki declaration and approved by institutional/regional/national ethics/committee/ethics board of The University of Louisville Institutional Review Board (No. 16.1002) and informed consent was taken from all the patients.

**Open Access Statement:** This is an Open Access article distributed in accordance with the Creative Commons Attribution-NonCommercial-NoDerivs 4.0 International License (CC BY-NC-ND 4.0), which permits the non-commercial replication and distribution of the article with the strict proviso that no changes or edits are made and

the original work is properly cited (including links to both the formal publication through the relevant DOI and the license). See: <https://creativecommons.org/licenses/by-nc-nd/4.0/>.

## References

1. Maradit Kremers H, Larson DR, Crowson CS, et al. Prevalence of total hip and knee replacement in the United States. *J Bone Joint Surg Am* 2015;97:1386-97.
2. Gavaskar AS, Tummala NC, Subramanian M. Cemented or cementless THA in patients over 80 years with fracture neck of femur: a prospective comparative trial. *Musculoskelet Surg* 2014;98:205-8.
3. Dorr LD, Faugere MC, Mackel AM, et al. Structural and cellular assessment of bone quality of proximal femur. *Bone* 1993;14:231-42.
4. Issa K, Stroh AD, Mont MA, et al. Effect of bone type on clinical and radiographic outcomes of a proximally-coated cementless stem in primary total hip arthroplasties. *J Orthop Res* 2014;32:1214-20.
5. Riley SA, Spears JR, Smith LS, et al. Cementless Tapered Femoral Stems for Total Hip Arthroplasty in Octogenarians. *J Arthroplasty* 2016;31:2810-3.
6. Jämsen E, Eskelinen A, Peltola M, et al. High early failure rate after cementless hip replacement in the octogenarian. *Clin Orthop Relat Res* 2014;472:2779-89.
7. Gromov K, Bersang A, Nielsen CS, et al. Risk factors for post-operative periprosthetic fractures following primary total hip arthroplasty with a proximally coated double-tapered cementless femoral component. *Bone Joint J* 2017;99-B:451-7.
8. McMinn DJW, Snell KIE, Daniel J, et al. Mortality and implant revision rates of hip arthroplasty in patients with osteoarthritis: Registry based cohort study. *BMJ* 2012;344:e3319.
9. Garland A, Gordon M, Garellick G, et al. Risk of early mortality after cemented compared with cementless total hip arthroplasty: a nationwide matched cohort study. *Bone Joint J* 2017;99-B:37-43.
10. Cohen CA, Smith TC. The intraoperative hazard of acrylic bone cement: report of a case. *Anesthesiology* 1971;35:547-9.
11. Dandy DJ. Fat embolism following prosthetic replacement of the femoral head. *Injury* 1971;3:85-8.
12. Hungerford DS, Jones LC. The rationale for cementless total hip replacement. *Orthop Clin North Am* 1993;24:617-26.

13. Meding JB, Galley MR, Ritter MA. High survival of uncemented proximally porous-coated titanium alloy femoral stems in osteoporotic bone. *Clin Orthop Relat Res* 2010;468:441-7.
14. Stryker. Stryker Accolade II Femoral Hip System Surgical Technique Guide. Surgical Technique Guide. 2012.
15. Issa K, Pivec R, Wuestemann T, et al. Radiographic fit and fill analysis of a new second-generation proximally coated cementless stem compared to its predicate design. *J Arthroplasty* 2014;29:192-8.
16. Faizan A, Wuestemann T, Nevelos J, et al. Development and verification of a cementless novel tapered wedge stem for total hip arthroplasty. *J Arthroplasty* 2015;30:235-40.
17. Harris WH. Traumatic arthritis of the hip after dislocation and acetabular fractures: treatment by mold arthroplasty. An end-result study using a new method of result evaluation. *J Bone Joint Surg Am* 1969;51:737-55.
18. Loudon JR, Charnley J. Subsidence of the femoral prosthesis in total hip replacement in relation to the design of the stem. *J Bone Joint Surg Br* 1980;62-B:450-3.
19. Patil S, Luis C, Finn H. Porous femoral fixation in total hip arthroplasty with short anatomical stem: Radiographic evaluation. *Clin Orthop Surg* 2017;9:255-62.
20. Charnley J. Total hip replacement by low-friction arthroplasty. *Clin Orthop Relat Res* 1970;72:7-21.
21. Middleton RG, Uzoigwe CE, Young PS, et al. Perioperative mortality after hemiarthroplasty for fracture of the hip. *Bone Joint J* 2014;96-B:1185-91.
22. Kienapfel H, Sprey C, Wilke A, et al. Implant fixation by bone ingrowth. *J Arthroplasty* 1999;14:355-68.
23. Berend KR, Lombardi AV, Mallory TH, et al. Cementless double-tapered total hip arthroplasty in patients 75 years of age and older. *J Arthroplasty* 2004;19:288-95.
24. Hozack WJ, Rothman RH, Eng K, et al. Primary cementless hip arthroplasty with a titanium plasma sprayed prosthesis. *Clin Orthop Relat Res* 1996:217-25.
25. McLaughlin JR, Lee KR. Long-term results of uncemented total hip arthroplasty with the Taperloc femoral component in patients with Dorr type C proximal femoral morphology. *Bone Joint J* 2016;98-B:595-600.
26. Kolisek FR, Issa K, Harwin SE, et al. Minimum 5-year Follow-up for Primary THA Using a Tapered, Proximally Coated Cementless Stem. *Orthopedics* 2013;36:e633-6.
27. Pierce TP, Jauregui JJ, Cherian JJ, et al. Prospective evaluation of short and mid-term outcomes of total hip arthroplasty using the Accolade™ stem. *Hip Int* 2015;25:447-51.
28. Watts CD, Abdel MP, Lewallen DG, et al. Increased Risk of Periprosthetic Femur Fractures Associated With a Unique Cementless Stem Design. *Clin Orthop Relat Res* 2015;473:2045-53.
29. Sarvilinna R, Huhtala H, Pajamäki J. Young age and wedge stem design are risk factors for periprosthetic fracture after arthroplasty due to hip fracture: A case-control study. *Acta Orthop* 2005;76:56-60.
30. Lindahl H, Malchau H, Herberts P, et al. Periprosthetic femoral fractures: Classification and demographics of 1049 periprosthetic femoral fractures from the Swedish National Hip Arthroplasty Register. *J Arthroplasty* 2005;20:857-65.
31. Goel A, Lau EC, Ong KL, et al. Dislocation Rates Following Primary Total Hip Arthroplasty Have Plateaued in the Medicare Population. *J Arthroplasty* 2015;30:743-6.

**Cite this article as:** Lindner J, Napier J, Feher A, Haeberle HS, Samuel LT, Mont MA, Delanois R, Malkani AL. Cementless tapered wedge stems in patients undergoing primary total hip arthroplasty with Dorr C bone—are complication risks increased? *Ann Transl Med* 2023;11(10):349. doi: 10.21037/atm.2019.08.124