



# Elucidating the anatomy of the quadrivial pattern of the right upper lobe bronchus using 3D-CT images

Xibin Zhong<sup>1#</sup>, Yang Huang<sup>1#</sup>, Mengsi Yang<sup>1</sup>, Longfei Jia<sup>1</sup>, Yuanzhou Wu<sup>1</sup>, Yaru Zhu<sup>2</sup>, Hui Li<sup>1</sup>, Qunqing Chen<sup>1^</sup>

<sup>1</sup>Thoracic Surgery Department, Zhujiang Hospital, Southern Medical University, Guangzhou, China; <sup>2</sup>Department of Critical Care Medicine, Zhujiang Hospital, Southern Medical University, Guangzhou, China

*Contributions:* (I) Conception and design: X Zhong, Y Huang, H Li, Q Chen; (II) Administrative support: X Zhong, Q Chen; (III) Provision of study materials or patients: X Zhong, Y Huang, M Yang; (IV) Collection and assembly of data: Y Huang, L Jia, Y Wu; (V) Data analysis and interpretation: X Zhong, H Li, Q Chen, Y Zhu; (VI) Manuscript writing: All authors; (VII) Final approval of manuscript: All authors.

<sup>#</sup>These authors contributed equally to this work.

*Correspondence to:* Dr. Qunqing Chen; Dr. Hui Li. Thoracic Surgery Department, Zhujiang Hospital, Southern Medical University, No. 253, Gongye Avenue, Guangzhou 510000, China. Email: chenqqg1985@sina.com; sameul\_li@sina.com.

**Background:** A preoperative understanding of the thoracic anatomy of the patients with the quadrivial pattern of branching of the right upper lobe is key to successful surgery. We analyzed the quadrivial pattern of division of the right upper lobe bronchus of patients using three-dimensional (3D) computed tomography (CT) angiography and bronchography.

**Methods:** A total of 212 consecutive adult patients who had undergone thoracic CT scans before surgery at the Zhujiang Hospital of the Southern Medical University from August 2020 to August 2021 was used for retrospective study. The 3D-CT images were taken using Mimics software. Radiology technicians processed all the 3D images, and thoracic surgeons confirmed the validity of all the reconstructions.

**Results:** Six (2.83%) were identified as having a quadrivial pattern of division of the right upper lobe bronchus with 1 female, and 5 males. Based on the number of pulmonary artery branches, 5 (83.3%) and 1 (16.7%) were classified as “trunk superior (Tr.sup) + ascending artery (A.asc) and Tr.sup + trunk inferior (Tr.inf) + ascending artery (A.asc) (1/6, 16.7%). Based on the number of ascending artery branches, the patients were also divided into type A (3/6, 50%) and type B (3/6, 50%). The patients were also divided into 1 of the following three types based on the origins of the A2: (I) A2 originates from A6 (1/6, 16.7%); (II) A2 originates from the pulmonary trunk (4/6, 66.7%); and (III) A2a originates from A3, and A2b originates from the pulmonary artery stem (1/6, 16.7%). According to the number of A1b branches, patients were divided into two types: (I) 1 branch (4/6, 66.7 %); and (II) 2 branches (2/6, 33.3 %). In the present study, anterior + central type was observed which classified into two types: (I) type Iab, the anterior vein ran from V1a to V1b (4/6, 66.7%); and (II) type Ib, the anterior vein ran from V1b only (2/6, 33.3%).

**Conclusions:** 3D-CT was successfully used for analyzing the quadrivial bronchovascular patterns of the right upper lobe bronchus. Our study provides certain references to perform anatomical pulmonary segmentectomy, which should improve the success rate of operations.

**Keywords:** Quadrivial type; right upper lung; bronchus; pulmonary vessels; 3D reconstruction

Submitted Oct 21, 2021. Accepted for publication Dec 30, 2021.

doi: 10.21037/atm-21-6282

**View this article at:** <https://dx.doi.org/10.21037/atm-21-6282>

<sup>^</sup>ORCID: 0000-0002-7310-5108.

## Introduction

A surgery that involves removing cancer and lymph nodes from the chest is performed when a tumor appears to be confined to the lung and when the procedure can be performed safely (1). Due to advances in medical technology, lung screening using low-dose spiral computed tomography (CT) has recently become widespread, and has been associated with the earlier detection of small lung lesions (2-4). A segmentectomy preserves more lung function than a lobectomy (5). Villamizar *et al.* recommend the use of radical anatomical segmentectomy in the treatment of patients with non-small cell lung carcinoma (NSCLC)  $\leq 2$  cm in size, and older patients with limited cardiopulmonary function (5). However, a segmentectomy is more complex than a standard lobectomy because of the anatomical complexity of the peripheral vessels and bronchi (segmental bronchovascular structures can vary individually at different levels) (6). Thus, an understanding of pulmonary bronchovascular patterns, including rare anatomical variations, is especially important to the performance of safe and accurate pulmonary surgery.

Mimics software allows medical image data (DICOM) to be imported, and the anatomy to be segmented to create accurate three-dimensional (3D) images. 3D-CT has been used for evaluating and diagnosing with airway diseases. Such as Furuhashi *et al.*, showed that 3D CT image reconstruction accurately confirmed morphological changes in the upper airway during oral appliance therapy in patients with obstructive sleep apnoea (7). Watanabel *et al.* demonstrated that 3D-CT was an effective non-invasive method for evaluating airway tract involvement in relapsing polychondritis (8). 3D-CT scan reconstructions cannot capture the dynamic nature of the airway that requires increased radiation exposure in order to obtain high resolution of airway anatomy. 3D-CT also cannot differentiate well between mucus and the airway wall which lead to inaccuracies in airway measurement in planar and reconstructed images. Endoscopy could capture the dynamic nature of the airway and visualize airway wall components clearly. However, accurate discernment of airway outline at any given cross-sectional level is challenging, especially when the entire cross section cannot be seen in a single field of view (9). Compared to traditional 2-dimensional CT images, 3D-CT images can reveal the pulmonary anatomical relationship and any anatomical variations, providing a knowledge of an individual's pulmonary anatomy before

and during surgical procedures. However, it is difficult to fully understand pulmonary segmental anatomy using 3D-CT images without a good understanding of pulmonary bronchovascular patterns, especially the branching patterns of pulmonary veins. Further, current studies on pulmonary bronchovascular patterns are limited (10-12).

There are three patterns of branching of the right upper bronchus (10): (I) trifurcated; (II) bifurcated; and (III) quadrivial. In the quadrivial pattern of branching, four segmental bronchi arise from the right upper lobe bronchus (see *Figure 1*). The quadrivial pattern of branching occurs in 0.8% of cases (11,13). However, studies on the quadrivial pattern of branching of the right upper lobe bronchus are limited, and its anatomical characteristics require further investigation. A full understanding of its anatomical characteristics would enable surgeons to carefully dissect and ligate the branching vessels during the operation, and thus improve the success rate of operations.

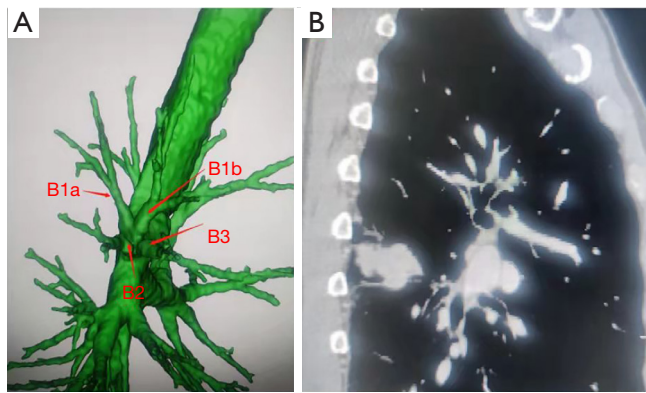
The present study sought to explore the anatomy of the quadrivial pattern of branching of the right upper lobe bronchus, especially the segmental bronchovascular structures. We identified six cases of the quadrivial pattern of branching of the right upper lobe bronchus, and analyzed the position relationship between the bronchus and blood vessels using data derived from 3D-CT angiography and bronchography, and thus extended understandings of thoracic anatomy for thoracic surgeons performing right upper lung segment resections.

We present the following article in accordance with the MDAR reporting checklist (available at <https://atm.amegroups.com/article/view/10.21037/atm-21-6282/rc>).

## Methods

### *Reconstruction of 3D-CT images*

Preoperative routine chest enhanced CT examinations were performed on 212 patients who were to undergo surgery at the Zhujiang Hospital of the Southern Medical University. The scanning equipment used was the PHILIPS Brilliance64-slice CT and the 256-slice spiral CT. The contrast agent used was ultravist at a concentration of 370 mg/mL. The preoperative CT of patients was transferred into Mimics software; the software converted the data to a 3D-CT angiographic format. Radiology technicians processed all the 3D images, and thoracic surgeons confirmed the validity of all the reconstructions.



**Figure 1** Revised the quadrivial pattern of branching of the bronchus of the right upper lung. (A) 3D reconstruction model of the quadrivial pattern of branching of the bronchus of the right upper lung. (B) A sagittal CT of the bronchus. CT, computed tomography.

#### ***Patient preparation and examination***

Between August 2020 to August 2021, 212 patients with lung cancer underwent preoperative routine chest enhanced CT examinations before surgery (pulmonary lobectomy or segmentectomy). Six consecutive patients (one female, five males; mean age: 54 years) were confirmed to have the quadrivial pattern of branching of the right upper lobe bronchus. All procedures performed in this study involving human participants were in accordance with the Declaration of Helsinki (as revised in 2013). The study was approved by the Research Ethics Committee at the Zhujiang Hospital of the Southern Medical University (No. 2021-KY-176) and informed consent was taken from all the patients.

#### ***The definition of pulmonary vessels***

Branching of the pulmonary artery of the right upper lung was defined as follows (10): trunk superior (Tr.sup): the first branch of the right main pulmonary artery; trunk inferior (Tr.inf): the second branch of the right main pulmonary artery originating from the mediastinum of the artery; ascending artery (A.asc): the artery that originates from the distal part of the first middle lobe artery and arises from the interstitial portion of the right pulmonary artery; recurrent artery (A.rec): the artery that branches from the Tr.sup, supplying the posterior segment.

Branching of the pulmonary vein of the right upper lung was classified into the following four types: (I) anterior type:

V1–3 mainly drained into the anterior vein (V.ant); (II) central type: V1–3 mainly drained into the V.cent (central vein); (III) Iab type: the anterior vein originated from V1a to V1b; and (IV) Ib type: the anterior vein originated from V1b only (11). V1a is between S1a and S1b, and V1b is between S1b and S3b. No anterior or central type alone were found.

#### ***Statistical analysis***

Statistical analysis was performed using SPSS (Chicago, IL, USA) version 19.0 software. The 3D-CT images were taken and analysis by using Mimics software.

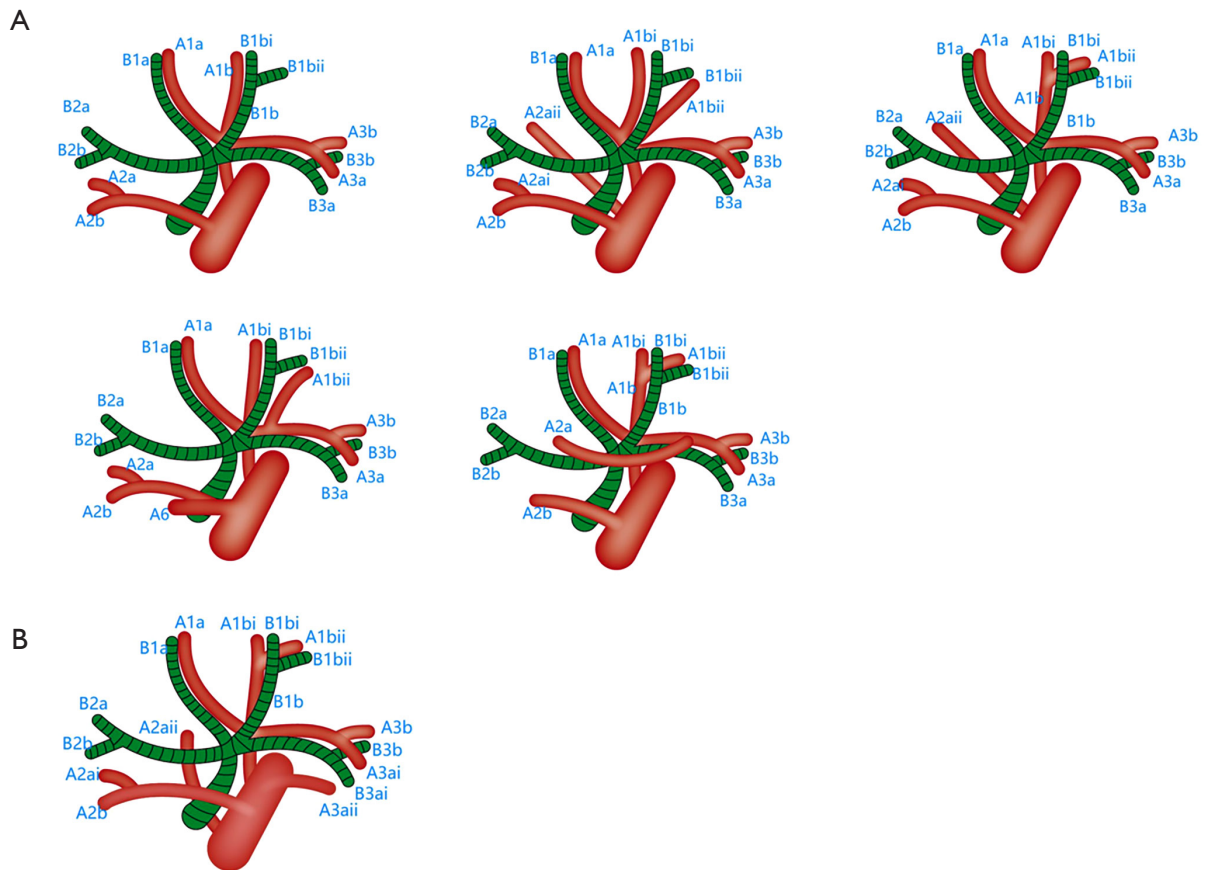
#### **Results**

This study described six patients (6/212, 2.83%) with a quadrivial pattern of branching of the right upper lobe bronchus (one female and five males, with a mean age of 54 years). Based on the branching of the pulmonary artery, these six patients were classified as having the following artery branching patterns: “Tr.sup + A.asc” (5/6, 83.3%; see *Figure 2A*) and “Tr.sup + Tr.inf + A.asc” (1/6, 16.7%; see *Figure 2B*). No A.rec type of artery was observed. Based on the ascending artery branches in A.asc, 2 other types were defined: type A (2 ascending branches; 3/6, 50%; see *Figure 3A*) and type B (1 ascending branch; 3/6, 50%; see *Figure 3B*). Patients can be divided into one of the following three types based on the origins of A2: (I) A2 originates from A6 (1/6, 16.7%; see *Figure 4A*); (II) A2 originates from the pulmonary trunk (4/6, 66.7%; see *Figure 4B*); and (III) A2a originates from A3, and A2b originates from the pulmonary artery stem (1/6, 16.7%; see *Figure 4C*).

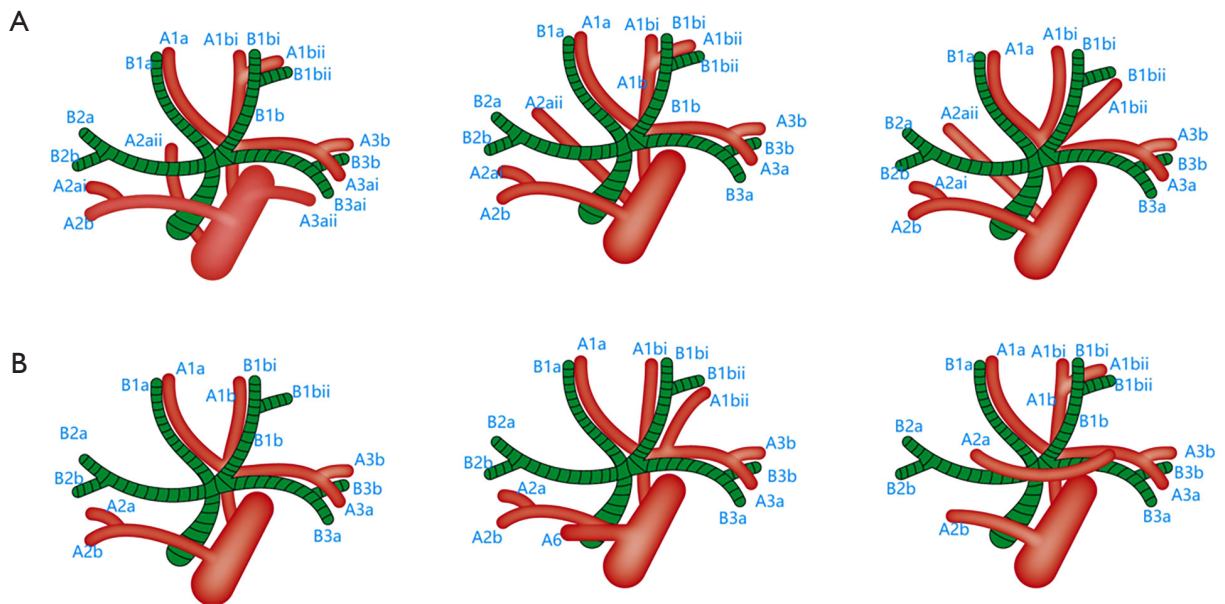
There are four types of branching of the pulmonary vein. In the present study, only the anterior + central vein type was observed in the patients, who were further classified into the following two types according to the origin of the anterior vein: type Iab (the anterior vein originated from V1a to V1b; 4/6, 66.7%; see *Figure 5A,5B*); and type Ib (the anterior vein originated from only V1b; 2/6, 33.3%; see *Figure 5C,5D*).

#### **Discussion**

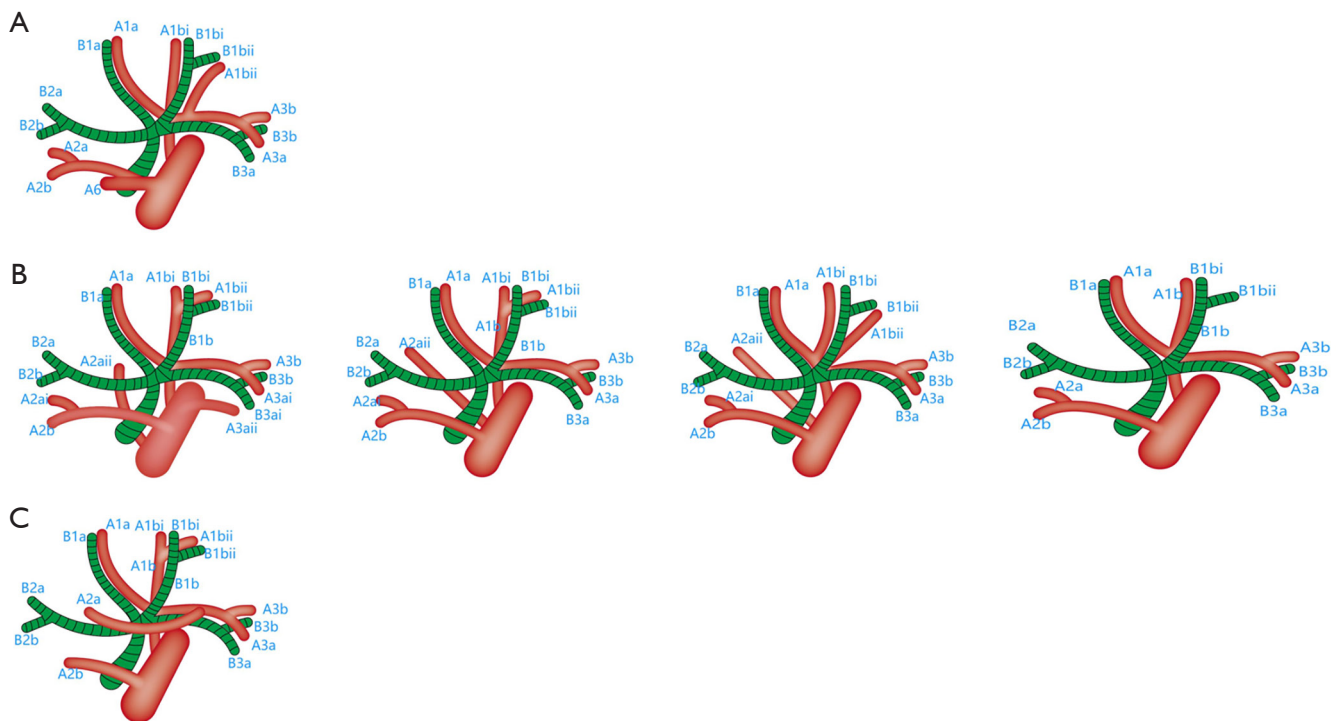
An understanding of pulmonary bronchovascular patterns is essential if thoracic surgeons are to perform safe and precise lung resections. Branching patterns of the right upper



**Figure 2** Simplified figure of the pulmonary trunk branches of the right upper lung: (A) Tr.sup + A.asc; (B) Tr.sup + Tr.inf + A.asc.



**Figure 3** Simplified model of ascending artery branches and bronchus: (A) 2 ascending arteries; (B) 1 ascending artery.



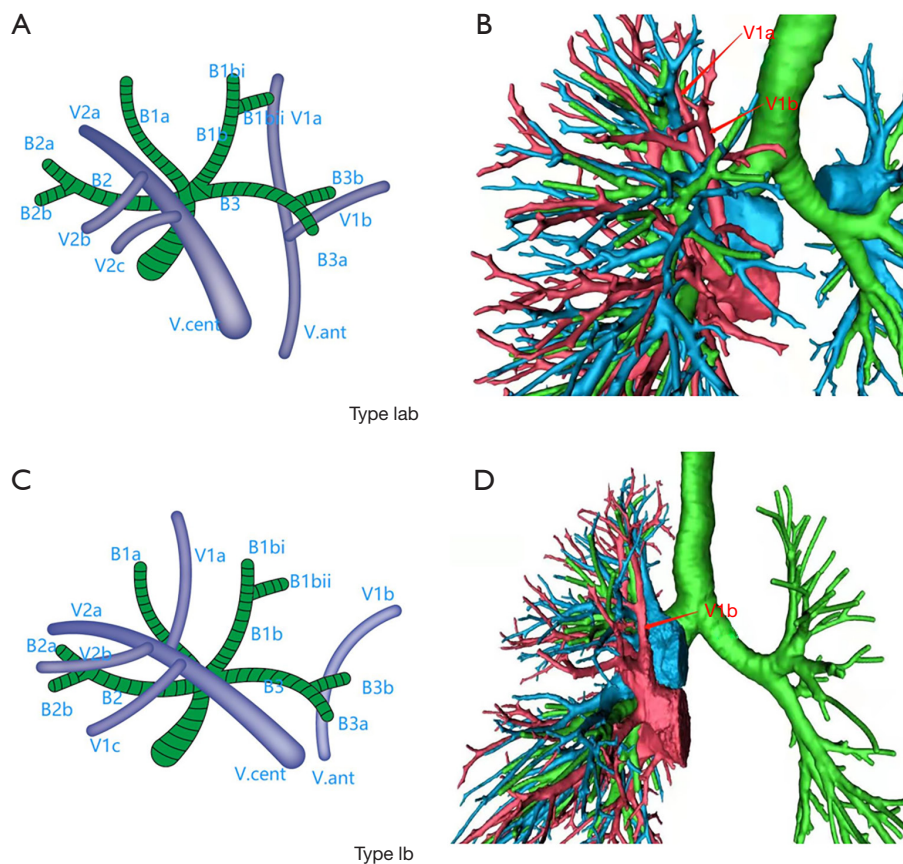
**Figure 4** Simplified figure of bronchus and arteries based on A2 origin: (A) A2 originates from A6; (B) A2 originates from the right pulmonary trunk; (C) A2a originates from A3, and A2b originates from the right pulmonary trunk.

lobar bronchus are classified into the trifurcated pattern of branching (the most common type), the bifurcated pattern of branching, and the quadrivial pattern of branching (the rarest type) (10). Due to the widespread use of 3D-CT images, lung anatomical structures have been well analyzed (10,12,14). Nagashima *et al.* explored the bronchovascular pattern and the frequency of variations of the right upper lobe using a large number of 3D-CT images, and found that the incidence rate of the quadrivial pattern of branching is 0.8% (10). We found that the incidence of the quadrivial pattern of branching in 6 of 212 patients was 2.83%; a figure significantly higher than that cited by Nagashima *et al.* ( $P < 0.001$ ). The anatomical features of the quadrivial pattern of branching required further investigation. Thus, in this study, we used 3D-CT images to examine its anatomical characteristics, especially any vascular variation patterns.

The pulmonary artery branching patterns were classified into the following four types: (I) “Tr.sup + A.asc.” type; (II) “Tr.sup + Tr.inf + A.asc” type; (III) “Tr.sup + Tr.inf” type; and (IV) “Tr.sup” type. The “Tr.sup + A.asc” type is the most common type with a reported incident rate of 71.9% (10). A proportion of 28.6 of cases have a B1

defective type of the bifurcated pattern of branching of the right upper lobe bronchus (12). In the present study, this type was observed in five of the six cases (83.3%). A previous study reported that “Tr.sup + Tr.inf + A.asc” type” occurs in 13.7% of cases (10), and its incident rate in cases with the B1 defective type of the bifurcated pattern of branching of the right upper lobe bronchus was 28.6%. In the present study, this type was only observed in one of the six cases (16.7%). The incident rates of these two types in the quadrivial pattern of branching were comparable to those reported in other research (10). We found no cases of “Tr.sup” or “Tr.sup + Tr.inf” types in the present study. Nor did we find the A.rec type artery in the present study.

An understanding of the branching pattern of A.asc is important in clinical practice if safe and accurate segmentectomies are to be performed. Of the six A.asc cases, three patients had two ascending arteries (50%, type A) and three had one ascending artery (50%, type B). The occurrence rate of type A, A.asc in the quadrivial pattern of branching was significantly more frequent than that previously reported (28/255, 12.4%;  $P < 0.001$ ) (10), and did not differ to the occurrence rate of the B1 defective type



**Figure 5** Simplified diagram and 3D reconstruction of the right upper pulmonary vein and bronchus, (A) Simplified diagram of V1a and V1b flowing into the anterior vein together. (B) 3D diagram of V1 and V1b flowing into the anterior vein together. (C) Simplified diagram of V1b flowing into the anterior vein alone. (D) 3D diagram of V1b flowing into the anterior vein alone.

of the bifurcated pattern of branching (12). If the origins of A2 are known in advance, injury and bleeding can be avoided. Thus, we divided patients into the following three types according to the origins of A2: (I) A2 originates from A6 (1/6, 16.7%); (II) A2 originates from the pulmonary trunk (4/6, 66.7%); and (III) A2a originates from A3, and A2b originates from the pulmonary artery stem (1/6, 16.7%). The anatomical variation whereby A6 shared a common trunk with A2 was found in one patient. In the lung resection surgery, A2 should be carefully isolated from A6 before it is divided to avoid injuring the A6 artery in the upper lobes. In the patients who had two ascending arteries, A2a originated in A31 in one patient. In such patients, the blood vessel should be cut during the resection of the posterior segment of the upper lobe of the right lung. Additionally, we also found that A1b had two branches and shared a common trunk with A3 in 4 of the six cases. An understanding of the branches and direction of A1b

before surgery allows the surgeon to carefully peel off these two branches during the intraoperative anatomy, avoiding injury to A3. This vascular type is rare in clinical practice; however, if it occurs, it causes great difficulties in the performance of pulmonary segmental resection in patients. The mis-operation of blood vessels may lead to serious complications and even surgical failure.

To better understand of the anatomy of peripheral vessels and bronchi, Shimizu examined the pulmonary vein branches and their variation using 3D-CT images (11). Branching of the pulmonary vein was classified into the following four types: (I) anterior type; (II) central type; (III) Ia type; and (IV) Ib type. Only the anterior + central vein type was observed in patients in the present study, and it was further classified into two types according to the origin of the anterior vein: type Ia (4/6, 66.7%) and type Ib (2/6, 33.3%). For the pulmonary vein in the B1 defective type of the bifurcated pattern of branching, there

are two types: type Ia<sub>b</sub> (2/7, 28.6%) and type Ib (5/7, 71.4%) (12). However, the occurrence rate of type Ib in the quadrivial pattern of branching is significantly less frequent than that in the B1 defective type of the bifurcated pattern of branching (12). 3D-CT reconstructions can provide a framework for computational fluid dynamics of airflow through normal and pathologic airways (15) which will could assist surgeons with airway assessment and patient specific medical and surgical planning for patients with airway problems. Thus, 3D-CT could help reduce the mis-operation of blood vessels which lead to serious complications and even surgical failure.

This study had several limitations. First, a few small branches were not reflected. Second, this was a retrospective study with a limited sample size from a single center. The anatomical features of the quadrivial pattern of branching of the right upper lobe bronchus were analyzed in six cases. A larger database is needed to further analyze the anatomical features of the quadrivial pattern of branching of the right upper lobe bronchus. Despite these limitations, this study elucidated the anatomy of the quadrivial pattern of branching of the right upper lobe bronchus using 3D-CT images and has extended understandings of the pulmonary anatomy of the quadrivial pattern of branching of the right upper lobe bronchus for thoracic surgeons, which in turn should improve the success rate of surgeries. In addition, endoscopy is an effective tool for obtaining airway measurements compared with 3D reconstructions derived from CT. However, 3D airway reconstructions from CT and quantitative airway endoscopy have different strengths and weaknesses, therefore, a multi-modality approach to airway measurement may currently be the best approach.

## Conclusions

In conclusion, the quadrivial pattern of branching of the right upper lobe bronchus is special and has many anatomical variations, which are rarely seen in clinical practice. We analyzed bronchovascular patterns in the quadrivial branching of the right upper lobe bronchus. Our study provides certain references that surgeons can use to perform anatomical pulmonary segmentectomy for patients with the quadrivial pattern of branching of the right upper lobe bronchus, and thus improve the success rate of surgeries.

## Acknowledgments

*Funding:* None.

## Footnote

*Reporting Checklist:* The authors have completed the MDAR reporting checklist. Available at <https://atm.amegroups.com/article/view/10.21037/atm-21-6282/rc>

*Data Sharing Statement:* Available at <https://atm.amegroups.com/article/view/10.21037/atm-21-6282/dss>

*Conflicts of Interest:* All authors have completed the ICMJE uniform disclosure form (available at <https://atm.amegroups.com/article/view/10.21037/atm-21-6282/coif>). The authors have no conflicts of interest to declare.

*Ethical Statement:* The authors are accountable for all aspects of the work in ensuring that questions related to the accuracy or integrity of any part of the work are appropriately investigated and resolved. All procedures performed in this study involving human participants were in accordance with the Declaration of Helsinki (as revised in 2013). The study was approved by the Research Ethics Committee at the Zhujiang Hospital of the Southern Medical University (No. 2021-KY-176) and informed consent was taken from all the patients.

*Open Access Statement:* This is an Open Access article distributed in accordance with the Creative Commons Attribution-NonCommercial-NoDerivs 4.0 International License (CC BY-NC-ND 4.0), which permits the non-commercial replication and distribution of the article with the strict proviso that no changes or edits are made and the original work is properly cited (including links to both the formal publication through the relevant DOI and the license). See: <https://creativecommons.org/licenses/by-nc-nd/4.0/>.

## References

1. Pompili C, Koller M, Velikova G. Choosing the right survey: the lung cancer surgery. *J Thorac Dis* 2020;12:6892-901.
2. Okada M, Nishio W, Sakamoto T, et al. Correlation between computed tomographic findings, bronchioloalveolar carcinoma component, and biologic behavior of small-sized lung adenocarcinomas. *J Thorac Cardiovasc Surg* 2004;127:857-61.
3. Yoshida J, Nagai K, Yokose T, et al. Limited resection trial for pulmonary ground-glass opacity nodules: fifty-case experience. *J Thorac Cardiovasc Surg* 2005;129:991-6.

4. Nakata M, Sawada S, Yamashita M, et al. Objective radiologic analysis of ground-glass opacity aimed at curative limited resection for small peripheral non-small cell lung cancer. *J Thorac Cardiovasc Surg* 2005;129:1226-31.
5. Villamizar N, Swanson SJ. Lobectomy vs. segmentectomy for NSCLC (T<2 cm). *Ann Cardiothorac Surg* 2014;3:160-6.
6. Karenovics W, Gonzalez M. How to decrease technical obstacles to difficult video-assisted thoracoscopic surgery segmentectomy? *J Thorac Dis* 2019;11:53-6.
7. Furuhashi A, Yamada S, Shiomi T, et al. Effective three-dimensional evaluation analysis of upper airway form during oral appliance therapy in patients with obstructive sleep apnoea. *J Oral Rehabil* 2013;40:582-9.
8. Watanabel M, Osawa T, Naniwa T, et al. Efficacy of three-dimensional computed tomography for evaluating airway tract involvement in patients with relapsing polychondritis. *Nihon Kokyuki Gakkai Zasshi* 2008;46:363-7.
9. Calloway HE, Kimbell JS, Davis SD, et al. Comparison of endoscopic versus 3D CT derived airway measurements. *Laryngoscope* 2013;123:2136-41.
10. Nagashima T, Shimizu K, Ohtaki Y, et al. An analysis of variations in the bronchovascular pattern of the right upper lobe using three-dimensional CT angiography and bronchography. *Gen Thorac Cardiovasc Surg* 2015;63:354-60.
11. Shimizu K, Nagashima T, Ohtaki Y, et al. Analysis of the variation pattern in right upper pulmonary veins and establishment of simplified vein models for anatomical segmentectomy. *Gen Thorac Cardiovasc Surg* 2016;64:604-11.
12. Zhang M, Mao N, Wang SH, et al. The B1 defective type of bifurcated right upper lobe bronchus. *J Thorac Dis* 2019;11:4218-23.
13. Conci DI. Quadrivial pattern of division in the right upper lobe: the axillary bronchus. *J Bronchology Interv Pulmonol* 2014;21:182-3.
14. Bhat V, Gadabanahalli K, Auti O. Main pulmonary artery trifurcation in association with persistent right common pulmonary vein: a piece of embryological puzzle. *Quant Imaging Med Surg* 2017;7:380-2.
15. Masters IB, Eastburn MM, Wootton R, et al. A new method for objective identification and measurement of airway lumen in paediatric flexible videobronchoscopy. *Thorax* 2005;60:652-8.

(English Language Editor: L. Huleatt)

**Cite this article as:** Zhong X, Huang Y, Yang M, Jia L, Wu Y, Zhu Y, Li H, Chen Q. Elucidating the anatomy of the quadrivial pattern of the right upper lobe bronchus using 3D-CT images. *Ann Transl Med* 2022;10(2):46. doi: 10.21037/atm-21-6282