



# Current treatments and outlook in adenocarcinoma of the esophagogastric junction: a narrative review

Fei Cao<sup>1,2#</sup>, Can Hu<sup>1,2#</sup>, Zhi-Yuan Xu<sup>1,2</sup>, Yan-Qiang Zhang<sup>1,2</sup>, Ling Huang<sup>1,2</sup>, Jia-Hui Chen<sup>1,2</sup>, Jiang-Jiang Qin<sup>1,2</sup>, Xiang-Dong Cheng<sup>1,2</sup>

<sup>1</sup>Department of Gastric Surgery, the Cancer Hospital of the University of Chinese Academy of Sciences (Zhejiang Cancer Hospital), Institute of Basic Medicine and Cancer (IBMC), Chinese Academy of Sciences, Hangzhou, China; <sup>2</sup>Diagnosis and Therapy Center of Upper Gastrointestinal Tumors in Zhejiang Province, Hangzhou, China

*Contributions:* (I) Conception and design: F Cao, C Hu; (II) Administrative support: XD Cheng, JJ Qin; (III) Provision of study materials or patients: None; (IV) Collection and assembly of data: None; (V) Data analysis and interpretation: None; (VI) Manuscript writing: All authors; (VII) Final approval of manuscript: All authors.

<sup>#</sup>These authors contributed equally to this work.

*Correspondence to:* Xiang-Dong Cheng; Jiang-Jiang Qin. Department of Gastric Surgery, the Cancer Hospital of the University of Chinese Academy of Sciences (Zhejiang Cancer Hospital), Institute of Basic Medicine and Cancer (IBMC), Chinese Academy of Sciences, Hangzhou, China. Email: chengxd@zjcc.org.cn; jqin@ucas.ac.cn.

**Background and Objective:** Adenocarcinoma of the esophagogastric junction (AEG) is a tumor of the esophagogastric junction (EGJ). Research has suggested that AEG may be an independent tumor because of its peculiar site and biological behavior. During the past several decades, the incidence of AEG has increased globally. Therefore, it is necessary to explore appropriate treatments for AEG. The aim of this review is to summarize the current treatments for AEG and forecast their future developments.

**Methods:** We critically conducted a literature search in PubMed (from the inception of the database to October 31, 2021). The keywords used in the search were “adenocarcinoma of the esophagogastric junction”, “gastroesophageal adenocarcinoma and surgical treatment”, “gastroesophageal adenocarcinoma and target therapy”, “gastroesophageal adenocarcinoma and neoadjuvant therapy” and “gastroesophageal adenocarcinoma and immunotherapy”.

**Key Content and Findings:** This study introduced the existing treatments for AEG from the aspects of surgical therapy, neoadjuvant therapy and targeted therapy, and prospected the future research direction.

**Conclusions:** Treatments for AEG often have different plans (such as surgical treatment, neoadjuvant therapy, targeted therapy and immunotherapy) according to the pathological type of patients, the status of metastasis, and the conditions of patients. Surgical treatment is the most commonly used treatment in clinical practice. Minimally invasive surgery promising potential for further development. Targeted therapy and immunotherapy can improve the quality of life and survival of patients. Currently, some drugs, such as trastuzumab, ramucirumab, pembrolizumab, and nivolumab have been approved by the Food and Drug Administration (FDA) for clinical treatment of AEG. However, targeted therapy and immunotherapy still have a long way to go and need to be further explored.

**Keywords:** Adenocarcinoma of the esophagogastric junction (AEG); surgical treatment; neoadjuvant therapy; targeted therapy

Submitted Dec 27, 2021. Accepted for publication Mar 21, 2022.

doi: 10.21037/atm-22-1064

View this article at: <https://dx.doi.org/10.21037/atm-22-1064>

## Introduction

Adenocarcinoma of the esophagogastric junction (AEG) is a tumor of the esophagogastric junction (EGJ). Its peculiar site and biological behavior lead researchers to suggest that AEG is an independent tumor (1). AEG is caused by smoking, alcohol, gastro-esophageal reflux disease, obesity, and helicobacter pylori infection (2). During the past several decades, the incidence of AEG has increased not only in Western countries, but also in Asian countries (3,4). Surgery is the optimal treatment for patients with gastric cancer (GC) and provides the best chance of long-term survival. Neoadjuvant chemotherapy significantly improves the outcome of advanced Siewert Type II AEG over surgery alone. Furthermore, programmed cell death-1 (PD-1) inhibitor combined with chemotherapy has excellent tolerance and has been demonstrated encouraging efficacy for the treatment of unresectable advanced AEG (5).

However, there are also some controversies in the treatment of AEG, such as surgical approach, surgical resection range, reconstruction techniques, neoadjuvant therapy regimens, and immunotherapy, among others. Here, we review the current advances in and outlook for the treatments of AEG. Compared with previous studies (1,4), this study introduced the existing treatments for AEG in a more systematic and comprehensive way from the aspects of surgical treatment, neoadjuvant therapy and targeted therapy. What's more, it analyzed the advantages and disadvantages of these treatment methods, providing reference for the further treatments for AEG and the improvement of prognosis. We present the following article in accordance with the Narrative Review reporting checklist (available at <https://atm.amegroups.com/article/view/10.21037/atm-22-1064/rc>).

## Methods

In the process of writing this review, we critically conducted a literature search in PubMed (from the inception of the database to 2021). The keywords used in the search included “adenocarcinoma of the esophagogastric junction”, “gastroesophageal adenocarcinoma and surgical treatment”, “gastroesophageal adenocarcinoma and target therapy”, “gastroesophageal adenocarcinoma and neoadjuvant therapy” and “gastroesophageal adenocarcinoma and immunotherapy” (As shown in *Table 1* and *Table S1*).

## Surgical treatment

Because of the special location of AEG, it cannot be simply categorized as the treatment of esophageal cancer or GC, especially in surgery. For early cases of AEG with a low lymph node metastasis rate (Tis or T1a stage), endoscopic submucosal dissection or endoscopic mucosal resection have become the standard treatment. Such patients often had a higher R0 removal rate and a higher overall removal rate (6-8). For locally advanced tumors with the possibility of lymph node invasion, radical resection is still the main treatment of AEG. In recent years, with the development of minimally invasive surgical techniques, ensuring safety, reducing postoperative complications, and improving the quality of life of patients have increasingly become the focus of treatment (9). Increasingly, surgeons have focused on improving the surgical approach, resection range, lymph node dissection, and digestive tract reconstruction. However, there is also no unified standard treatment for AEG (10,11).

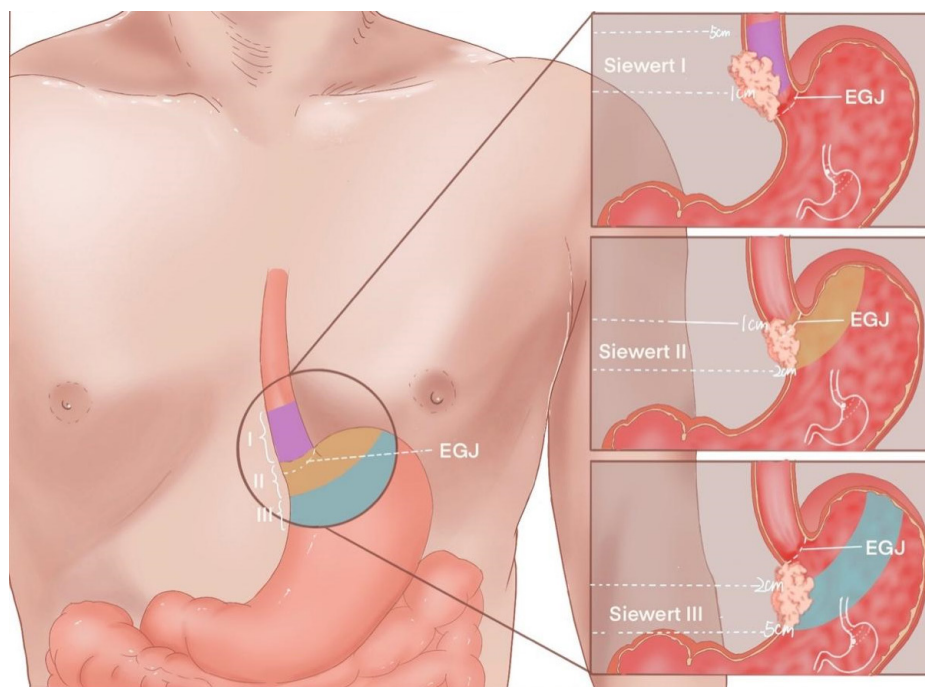
## Selection of surgical approach

At present, the most widely accepted classification was made by German scholars Siewert and Stein, which classifies AEG into types I, II, and III (*Figure 1*). For type I, the center of the tumor is located 1 to 5 cm above the gastroesophageal junction. For type II, the center of the tumor is located 1 cm above and 2 cm below the gastroesophageal junction. For type III, the center of the tumor is located 2 to 5 cm below the gastroesophageal junction (12). This classification has become a common clinical tool to guide treatment decisions.

Due to the high frequency of Siewert type I AEG tumors involving thoracic lymph nodes, esophagectomy was performed by transthoracic approach, while total gastrectomy (TG) was performed by abdominal approach for Siewert type II AEG. However, the optimal surgical treatment for Siewert type II AEG remains controversial. There are three treatments for Siewert type II AEG, including a right transthoracic approach (Ivor Lewis surgery), an abdominal transdiaphragmatic approach (TH), and a left thoracoabdominal approach (LTA). A random controlled trial divided AEG patients into a group that was treated with the left LTA and a group treated with the TH approach. The results showed no improvement in survival but a lower incidence of postoperative complications in the

**Table 1** The search strategy summary

Items	Specification
Date of search (specified to date, month and year)	August 7th,2021
Databases and other sources searched	PubMed
Search terms used (including MeSH and free text search terms and filters)	The search terms included “adenocarcinoma of the esophagogastric junction”, “gastroesophageal adenocarcinoma and surgical treatment”, “gastric cancer and surgical treatment”, “gastroesophageal adenocarcinoma and target therapy”, “gastroesophageal adenocarcinoma and neoadjuvant therapy” and “gastroesophageal adenocarcinoma and immunotherapy”
Timeframe	From 1955 to 2021
Inclusion and exclusion criteria (study type, language restrictions etc.)	Articles of great relevance to the content of this article and studies targeting or including adenocarcinoma of the esophagogastric junction were included
Selection process (who conducted the selection, whether it was conducted independently, how consensus was obtained, etc.)	Fei Cao and Can Hu conducted the selection. Can Hu was responsible for the selection of surgical treatment and neoadjuvant therapy, and Fei Cao was responsible for the selection of targeted therapy. We discussed it together and reached a consensus
Any additional considerations, if applicable	None



**Figure 1** Siewert classification of AEG. Type I: the tumor center located within 1–5 cm above the EGJ; type II: the center located within 1 cm above to 2 cm below the EGJ; type III: the tumor center between 2 and 5 cm below the EGJ. AEG, adenocarcinoma of the esophagogastric junction; EGJ, esophagogastric junction.

TH group compared with the LTA group (13).

In addition, with the development of laparoscopic surgery, laparoscopic-assisted gastrectomy for early Siewert

type II/III AEG have become increasingly popular. Existing research found that there is no significant difference in 3-year overall survival (OS) between laparoscopic-assisted

gastrectomy and open TG (13). We performed laparoscopic or open gastrectomy via the left thoracic surgical approach for Siewert type II/III AEG patients, which allowed exposure of the upper esophagus and extensive lymph nodes dissection without additional complications (14). Therefore, the TH approach is recommended for Siewert III patients because it allows dissection of the abdominal and inferior mediastinal lymph nodes. A transesophageal hiatus TH approach is generally recommended for the treatment of Siewert II AEG. If esophageal invasion is greater than 3 cm, a right transthoracic approach is recommended for surgical treatment (15).

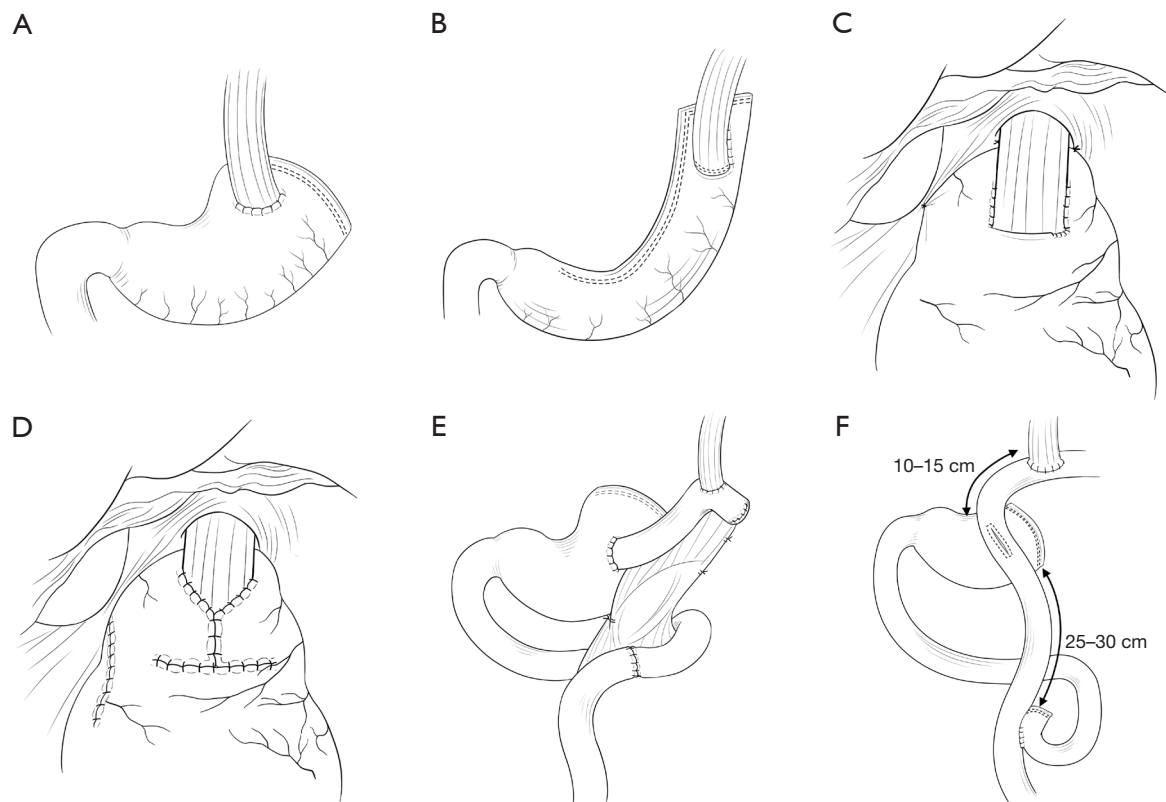
### *Selection of surgical resection scope*

The extent of surgical resection should be further determined according to the Siewert classification and tumor stage. Esophagectomy is generally considered for Siewert I tumors, and gastrectomy is recommended for Siewert III tumors. However, there is no specific treatment for Siewert II tumors (16). It remains unclear whether Siewert II AEG should undergo proximal gastrectomy (PG) or TG. A nationwide multi-institutional study analyzed long-term quality of life after PG and TG. Univariate and multivariate analyses found that the incidence and symptoms of weight loss, diarrhea, and dumping syndrome in patients treated with PG were better than those treated with TG (17). One study evaluated the index of estimated benefit from lymph node dissection (IEBLD) in patients with Siewert II and III AEG. The results showed that the IEBLDs were similar between Siewert II and III AEG at all stations except for the lower peri-gastric lymph nodes. Therefore, researchers suggested that PG can be performed for Siewert II AEG, while TG should be performed for Siewert III AEG (18).

### *Selection of lymph node dissection scope*

Lymph node metastasis is the main type of AEG metastasis and is characterized by simultaneous thoracic and abdominal metastasis, which affects the survival rate and prognosis of patients. Therefore, radical AEG resection should not only consider the resection scope of the esophagus and stomach but should also consider lymph node dissection. The specific scope of lymph node dissection, including the mediastinal and abdominal lymph nodes, is closely related to the tumor type and esophageal invasion length. For mediastinal lymph nodes, significant differences in lymph node metastasis among different types of AEG were

found in a retrospective analysis. The mediastinal lymph node metastasis rate of Siewert I, II, and III AEG was 65%, 12%, and 6%, respectively (19). One study examined the relationship between esophageal invasion length of tumors at the EGJ and mediastinal lymph node metastasis in Siewert II AEG patients. The overall inferior mediastinal lymph node metastasis rate of Siewert II AEG was 13.7%. When esophageal invasion length was less than 2.5 cm, the rate of inferior mediastinal lymph node metastasis decreased to 9.3%, and, when esophageal invasion length was  $\geq 2.5$  cm, the rate of inferior mediastinal lymph node metastasis increased to 24.0% (20). A prospective multicenter study analyzed the distance of esophageal tumor involvement, and the results showed that, when the distance of esophageal tumor involvement was 2.0–3.0 cm, 3.0–4.0 cm, or  $>4.0$  cm, the metastasis rate of No. 110 lymph nodes was 10.8%, 20.8%, and 28.6%, respectively. The longer the distance of the esophagus involved, the higher the rate of inferior mediastinal lymph node metastasis. Therefore, it is recommended that inferior mediastinal lymph nodes including No. 110 lymph nodes should be dissected if esophageal involvement exceeds 2.0 cm (21). For abdominal lymph nodes, the study by Pedrazzani *et al.* (22) showed that Siewert III AEG had the highest rate of abdominal lymph node metastasis, and Siewert I AEG had a lower rate of abdominal lymph node metastasis than Siewert II AEG. A retrospective study found that abdominal lymph nodes with a metastasis rate of greater than 10% for Siewert I included No. 1, 2, 3, and 7 lymph nodes. Siewert II included No. 1, 2, 3, 7, 9, 11p, and 16 lymph nodes, and Siewert III included NO. 1, 2, 3, 4sa, 4D, 7, 8, 10, 11p, and 16 lymph nodes (23). In addition, Yamashita *et al.* (24) confirmed that, regardless of whether the AEG is located in the deviatoric esophagus or the gastric side, the abdominal lymph nodes metastasis were mainly concentrated in numbers 1, 2, 3, and 7. The study by Matsuda *et al.* (25) showed that the rate of abdominal lymph nodes metastasis in Siewert type II AEG was 40.8% in the number 1 lymph node, 31.7% in the number 2 lymph node, 43.2% in the No.3 lymph nodes, and 27.6% in No. 7 lymph nodes. What is more, 3 categories were defined for dissection of AEG lymph nodes. It is necessary to dissect the category 1 lymph nodes, including No. 1, 2, 3, 7, 9, and 11p, because their rate of metastasis is more than 10%. It is better to dissect category 2 lymph nodes, including No. 8a, 19, and 110, because their rate of metastasis ranges from 5% to 10%. There is no need to dissect lymph nodes which have a metastasis rate of less than 5% (21).



**Figure 2** Reconstruction of the digestive tract after a proximal gastrectomy. (A) Traditional esophagogastric anastomosis. (B) Tubular gastric anastomosis. (C) Side overlap anastomosis. (D) Kamikawa anastomosis. (E) Jejunum interposition single tract anastomosis. (F) Interposition jejunum double channel anastomosis.

### *Selection of reconstruction of digestive tract*

PG lacks a standard postoperative approach to digestive tract reconstruction. Because of the position of Siewert type II AEG, compared with TG, PG can effectively prevent the hypofunction of the digestive tract and anemia by using the reserving and storing food function of the gastric stump. However, in PG in patients with Siewert type AEG, the normal physiological anti-reflux anatomical structure was destroyed by the cardia resection. The occurrence of esophageal reflux seriously affected the postoperative quality of life of patients, so choosing a reasonable method of postoperative digestive tract reconstruction is key. Esophagogastric anastomosis, jejunal interposition anastomosis, or double tract anastomosis are the main methods for gastrointestinal reconstruction after PG.

Esophagogastric anastomosis (*Figure 2A*) is still used today because of its simple and safe operation method and because it will not change the natural physiological pathway

of normal food. But the method has the shortcomings of insufficient gastric stump capacity and a high incidence of gastroesophageal reflux after the operation (26). Therefore, Adachi *et al.* (27) first proposed to use esophageal tubular gastric anastomosis (*Figure 2B*) because it maintained the physiological structure of the original digestive tract and the reflux symptoms were significantly better than those of the patients with esophagogastric anastomosis alone. Moreover, the tubular gastric method can also reduce the tension of anastomosis and ensure the safety of anastomosis. However, the incidence of anastomotic stenosis is still high after esophageal tubular gastric anastomosis (28). In recent years, the method of side overlap anastomosis (*Figure 2C*) has rapidly developed esophagogastric anastomosis methods with a unique anti-reflux mechanism. Yamashita *et al.* (29) showed that 13 out of 14 patients who underwent side overlap anastomosis had no reflux symptoms and did not need proton pump inhibitors. Furthermore, Muraoka (25) proposed a novel type of esophagogastric anastomosis called Kamikawa

(Figure 2D) with a double-flap technique. Some studies showed that, although Kamikawa anastomosis required a more complex intracorporeal suturing technique and a longer duration of surgery, good physiological function was maintained because of the relatively large remnant stomach and distinctive anastomotic technique (30,31).

Jejunal interposition anastomosis (Figure 2E) was proposed by Merendino (32). In this technique, a jejunum is used to connect the remnant gastric and esophagus and form a buffer zone to prevent reflux caused by the alkaline environment and the peristalsis function of the intestine (33). Compared with esophagogastric anastomosis, jejunal interposition anastomosis more effectively prevented reflux (34). However, the optimal length of interposition jejunum is still controversial. If the interposition jejunum is too long, food will stagnate in the jejunum, and it is also not conducive to postoperative endoscopic examination. Nomura *et al.* (35) confirmed that the optimal length of the interposition jejunum is 10–15 cm.

For double tract anastomosis (Figure 2F), Roux-en-Y anastomosis was performed first after the PG, and then side to side anastomosis was performed between the residual gastric and jejunum about 10 cm below the anastomosis (36). Therefore, food could enter the distal jejunum through the residual gastric and jejunum. This technique prevented reflux by interposition, accelerated food digestion, and promoted the absorption of nutrients by stimulating the secretion of bile and pancreatic juice by digesta passing through the duodenum. A meta-analysis confirmed that a PG and double tract anastomosis are a more effective to prevent vitamin B12 deficiency without increasing the risk of anastomotic stenosis and reflux esophagitis (37). With the development of laparoscopic technology, laparoscopic proximal GC surgery has been widely used. Some studies showed that there was no significant difference in early and late complications between laparoscopic PG with double tract anastomosis and laparoscopic TG. They also showed that the rate of decrease of body mass and the skeletal muscle index was lower in patients undergoing laparoscopic PG with double tract anastomosis than that of patients undergoing laparoscopic TG (38,39).

## Neoadjuvant therapy

### Neoadjuvant chemotherapy

Recently, neoadjuvant chemotherapy was developed to improve the prognosis of patients with AEG. The

advantages of neoadjuvant chemotherapy have been demonstrated in numerous large studies, such as reducing tumor size, improving the rate of R0 resection, and improving OS and progression-free survival (PFS). For the neoadjuvant chemotherapy used in AEG treatment, most reference data come from the studies on esophageal adenocarcinoma and proximal gastric adenocarcinoma. However, whether the treatment regimen of esophageal adenocarcinoma and proximal gastric adenocarcinoma can lead to survival benefits for patients with AEG is still controversial.

A trial evaluated whether surgery and perioperative chemotherapy could improve patient outcomes. In this study, 503 patients with GC, gastroesophageal junction carcinoma, and lower esophageal adenocarcinoma were recruited and randomly divided into the surgery alone group and the surgery plus perioperative chemotherapy group. The chemotherapy regimen was ECF (epirubicin + cisplatin + fluorouracil) for 3 cycles before and after surgery. The results showed that perioperative chemotherapy decreased the tumor size and stage, and significantly increased OS and PFS (40).

Similarly, a Phase III trial demonstrated the advantage of perioperative chemotherapy over surgery alone. The trial randomized 224 patients with resectable lower esophagus, gastroesophageal junction, or gastric adenocarcinoma into the perioperative chemotherapy group and the surgery alone group. Fluorouracil plus cisplatin was used for chemotherapy before and after surgery. The prognosis of the perioperative chemotherapy group was better than that of the surgery alone group (41).

In terms of the selection of chemotherapeutic agents, there is no standard neoadjuvant chemotherapy regimen. More clinical trials are needed. The Phase II and III trial compared the docetaxel-based FLOT group (fluorouracil plus leucovorin, oxaliplatin, and docetaxel) with the classical platinum-containing ECF/ECX group (fluorouracil or capecitabine plus cisplatin and epirubicin). The incidence of serious adverse events was similar in both groups, but the survival was significantly increased in the FLOT group (42). In addition, A clinical trial (43) enrolled 1,022 patients with AEG or GC who had a D2 gastrectomy, and the results showed that patients with perioperative S-1 and oxaliplatin (SOX) chemotherapy had a better OS compared with that of the group treated with adjuvant capecitabine and oxaliplatin (CapOx) chemotherapy. The adjuvant-SOX was non-inferior to adjuvant-CapOx in those patients. This suggests that the SOX regimen could be

**Table 2** Summary of clinical trials of HER2-targeted therapies for AEG

Name of trial	Agents	Line of treatment	Phase	Number of patients	PFS (month)	OS (month)
ToGA	Fluoropyrimidine/cisplatin plus trastuzumab vs. fluoropyrimidine/cisplatin	First or second line	III	594 (18% AEG)	6.7 vs. 5.5	13.8 vs. 11.1
WJOG7112 (T-ACT Study)	PT vs. paclitaxel alone	Second line	II	91	3.7 vs. 3.2	10.2 vs. 10.0
LOGiC	Lapatinib plus CapeOx vs. placebo plus CapeOx	First line	III	545 (9% AEG)	6.0 vs. 5.4	12.2 vs. 10.5
TYTAN	Lapatinib plus paclitaxel vs. paclitaxel	Second line	III	261	5.4 vs. 4.4	11.0 vs. 8.9
GATSBY	T-DM1 vs. taxane	Second line	II/III	415	2.7 vs. 2.4	7.9 vs. 8.6
JACOB	Pertuzumab plus trastuzumab and chemotherapy vs. placebo plus trastuzumab and chemotherapy	First line	III	780	8.4 vs. 7.0	17.5 vs. 14.2

AEG, adenocarcinoma of the esophagogastric junction; PFS, progression-free survival; OS, overall survival; PT, paclitaxel and trastuzumab; T-DM1, trastuzumab emtansine.

considered a new treatment option for patients with AEG.

### *Neoadjuvant chemoradiotherapy*

Some studies have also focused on neoadjuvant chemoradiotherapy in order to improve both pathologic complete response and systemic control (44,45). A trial divided 363 patients with resectable esophageal cancer or AEG into the preoperative chemoradiotherapy group and the simple surgery group. The preoperative chemoradiotherapy regimen included a weekly TP (paclitaxel plus carboplatin) regimen plus concurrent radiotherapy. Median survival was significantly improved in the preoperative chemoradiotherapy group (48.6 vs. 24.0 months) (44). In addition, A trial randomly assigned patients to receive either 15 weeks of neoadjuvant chemotherapy or 12 weeks of induction chemotherapy plus 3 weeks of concurrent chemoradiotherapy, followed by surgery. Experimental results showed that the addition of radiotherapy to preoperative chemotherapy improved the local PFS of patients with locally advanced EGJ adenocarcinoma, but the difference was not statistically significant (45). While these studies are promising, the number of large randomized controlled studies of neoadjuvant chemoradiotherapy is too few, and most studies remain in phase II. More long-term and larger clinical trials are needed.

### **Targeted therapies**

Recently, targeting the HER2 and the vascular endothelial growth factor (VEGF) pathways with trastuzumab and ramucirumab, respectively, has been found to improve survival, while targeted therapies against a number of other pathways are under clinical evaluation.

#### *Human epidermal growth factor receptor 2 (HER-2) as a target in AEG*

HER-2 can form heterodimers with HER-3, HER-4, etc., and cause phosphorylation of tyrosine residues at the carboxy-terminal of HER-2, which induces activation of the downstream Ras-Raf-MEK-MAPK pathway and the PI3K-Akt pathway. The expression rate of HER-2 in patients with AEG is 15–20%, while the expression rate of HER-2 in GC tissues is 10–15%. The high expression of HER-2 is correlated with the invasion and differentiation degree of the tumor, however, its correlation with the overall prognosis of the tumor is still controversial (46). An overview of clinical trials of HER2-targeted therapies for AEG is shown in *Table 2*.

#### *Trastuzumab*

Trastuzumab is an anti-HER2 monoclonal antibody which

can block the attachment of the human epidermal growth factor to HER2 by attaching itself to it. Therefore, the growth of cancer cells is inhibited. In the ToGA study, the patients were assigned to chemotherapy plus trastuzumab or chemotherapy alone in a ratio of 1:1. Median OS was 13.8 months with chemotherapy plus trastuzumab *vs.* 11.1 months with chemotherapy alone ( $P=0.0046$ ). Median PFS was 6.7 months with chemotherapy plus trastuzumab *vs.* 5.5 months with chemotherapy alone ( $P=0.0002$ ). The results showed that trastuzumab combined with chemotherapy in first-line treatment of HER2-positive AEG improved the remission rates and OS (47). Trastuzumab was subsequently included in the standard treatment regimen for patients with HER2-positive GC or AEG. Recently, a randomized phase II study evaluated the continuous use of trastuzumab beyond progression in HER2-positive advanced GC or AEG. There was no significant difference in the OS or response rate in patients who continued to receive trastuzumab compared to those who did not in second-line treatment (48). This study had some limitations, such as a small sample size and a small number of biomarker samples, therefore the expression status of HER2 would need to be reassessed with larger studies.

### ***Trastuzumab emtansine (T-DM1)***

T-DM1 is an antibody drug conjugate which is conjugated by trastuzumab and the cytotoxic drug DM1 through a non-reducing thioether-linked conjugate. It not only retains the antigen-dependent cell-mediated cytotoxicity of trastuzumab, but also can accurately bring DM1 into tumor cells through endocytosis. This is highly effective in killing tumor cells, thus effectively reversed the resistance of first-line anti-HER2 therapy. Regarding the mechanism, T-DM1 has a dual anti-tumor effect, improves the treatment window, and effectively overcomes the first-line anti-HER2 resistance (49).

The GATSBY study researched the efficacy of T-DM1 in patients who were previously treated for HER2-positive advanced GC including AEG. The results showed that T-DM1 was not superior to taxane in second-line therapy (50).

### ***Lapatinib***

Lapatinib is a reversible tyrosine kinase inhibitor (TKI) which can effectively inhibit the activity of ErbB1 and

ErbB2 tyrosine kinase. Its mechanism of action is to inhibit the intracellular ATP sites of EGFR (ERBB-1) and HER2(ERBB-2), which prevents the phosphorylation and activation of tumor cells and blocks the down-regulation signal through the homodimer and heterodimer of EGFR (ERBB-1) and HER2 (ERBB-1) (51).

Two phase III clinical trials investigated the efficacy of lapatinib in patients with HER2-positive GC or AEG. The LOGiC study was carried out to evaluate the efficacy of adding lapatinib to CapeOx in patients with HER2-positive AEG. Patients were randomly divided into two groups—the lapatinib arm group and the placebo arm group. The lapatinib arm group was treated with CapeOx (capecitabine 1,700 mg/m<sup>2</sup> and oxaliplatin 130 mg/m<sup>2</sup>) plus lapatinib 1,250 mg. The placebo arm group was given a placebo and CapeOx. Median OS in the lapatinib and placebo arm groups was 12.2 and 10.5 months, respectively, but this was not statistically significant. Median PFS in the lapatinib and placebo arm groups was 6.0 and 5.4 months, respectively ( $P=0.0381$ ). The lapatinib arm group had a significant improvement in response rate of 53%, compared with 39% in the placebo arm group ( $P=0.0031$ ). The results showed that the combination of lapatinib and CapeOx did not extend OS in patients with HER2-positive AEG (52). The TyTAN study was conducted to determine whether a combination of lapatinib and paclitaxel had a better effect than paclitaxel alone in second-line treatment in Asian patients with HER2-amplified AEG (53). Although the results of these two trials suggested that the OS was not prolonged, they still suggested that lapatinib had a potential benefit for patients. Therefore, scholars are carrying out studies on the treatment of HER2-positive locally advanced AEG with lapatinib combined with neoadjuvant radiotherapy and chemotherapy (54), and further results are worth examining.

### ***VEGF or vascular endothelial growth factor receptor (VEGFR) as a target in AEG***

VEGF is a major growth factor of endothelial cells. VEGFR is a receptor tyrosine kinase, which binds with the VEGF to promote the proliferation, survival, migration, and differentiation of endothelial cells. It plays an important role in angiogenesis, vascular development, vascular permeability, embryonic vascular development, cell migration, and the regulation of cancer cells (55). An overview of clinical trials of VEGF or VEGFR-targeted



**Table 3** Summary of clinical trials of VEGF or VEGFR-targeted therapies for AEG

Name of trial	Agents	Line of treatment	Phase	Number of patients	PFS (month)	OS (month)
REGARD	Ramucirumab vs. placebo	Second line	III	355	2.1 vs. 1.3	5.2 vs. 3.8
RAINBOW	Ramucirumab plus paclitaxel vs. placebo plus paclitaxel	Second line	III	665		9.6 vs. 7.4
RAINFALL	Ramucirumab plus fluoropyrimidine and cisplatin vs. placebo plus fluoropyrimidine and cisplatin	First line	III	645	5.7 vs. 5.4	11.2 vs. 10.7
N	Bevacizumab plus docetaxel, cisplatin, and fluorouracil	First line	II	44 (45% AEG)	12	16.8
N	Bevacizumab plus oxaliplatin and docetaxel	First line	II	38 (55% AEG)	6.6	11.1
AVAGAST	Bevacizumab plus capecitabine and cisplatin vs. placebo plus capecitabine and cisplatin	First line	III	774 (14% AEG)	6.7 vs. 5.3	12.1 vs. 10.1
AVATAR	Bevacizumab plus capecitabine and cisplatin vs. placebo plus capecitabine and cisplatin	First line	III	202	6.3 vs. 6.0	10.5 vs. 11.4
N	Apatinib vs. placebo	Third line	III	267 (22% AEG)	2.6 vs. 1.8	6.5 vs. 4.7

VEGF, vascular endothelial growth factor; VEGFR, vascular endothelial growth factor receptor; AEG, adenocarcinoma of the esophagogastric junction; PFS, progression-free survival; OS, overall survival; N, no specific names.

therapies for AEG is shown in *Table 3*.

### **Ramucirumab**

Ramucirumab is a monoclonal antibody targeting VEGFR2 with antitumor activity. The REGARD study was conducted to evaluate the benefit of ramucirumab in second-line treatment in patients with previously treated AGC or AEG. Median OS was 5.2 months in the ramucirumab group and 3.8 months in the placebo group, respectively. This indicated that ramucirumab increased the median OS of patients. Median PFS (2.1 vs. 1.3 months) was also improved in the ramucirumab group. Ramucirumab had satisfactory tolerance in this patient population. Most adverse event rates were similar to those in the placebo group (56). After that, a phase III clinical trial was conducted. From the results of this trial, the group assigned to ramucirumab compared to the placebo group had a definite improvement in median OS (9.6 vs. 7.4 months), median PFS (4.4 vs. 2.9 months), and response rate (28% vs. 16 %) (57). In 2014, ramucirumab was approved by Food and Drug Administration (FDA) for second-line

treatment of advanced GC or gastroesophageal junction adenocarcinoma. Further studies then explored the potential for ramucirumab to be used as a first-line treatment. In 2015, a phase III trial was conducted. The RAINFALL study was designed to assess whether ramucirumab in combination with cisplatin and fluoropyrimidine could enhance the effects of chemotherapy in patients with GC or AEG with distant metastases. The researchers assessed a significantly longer PFS in the ramucirumab group than the placebo group. However, the claim was not confirmed by independent central assessments. The median OS was not statistically significant between the two groups (11.2 vs. 10.7 months). As a result, for this population, ramucirumab in combination with cisplatin was not recommended as a first-line treatment (58).

### **Bevacizumab**

Bevacizumab is a recombinant humanized monoclonal antibody that can bind to human VEGF, block its biological activity, and inhibit endothelial cell proliferation and angiogenesis (59). Two phase II clinical trials showed

that bevacizumab combined with chemotherapy drugs in the treatment of metastatic gastric or gastroesophageal junction adenocarcinoma had good curative effects (60,61). Therefore, bevacizumab plus chemotherapy had the potential for further evaluation. A phase III trial called AVAGAST was conducted to test this. The trial assessed whether the addition of bevacizumab could improve the effectiveness of chemotherapy in first-line therapy. There was no significant improvement in median OS (12.1 *vs.* 10.1), but median PFS was 6.7 and 5.3 in the bevacizumab group and the control group, respectively, which showed a significant improvement. Regional analysis of the data showed no significant benefit for Asian patients, while benefits were increased for patients from Europe and the Pan-American regions (62). In 2009, a Phase III trial was conducted on 202 Chinese patients. Like AVAGAST, the addition of bevacizumab did not increase median OS and median PFS (63).

### *Apatinib*

Apatinib is a novel and highly selective inhibitor of small molecule tyrosine kinase targeting VEGFR2, which has shown some efficacy in the treatment of a variety of advanced tumors (64). The efficacy and safety of apatinib were demonstrated in a Phase III clinical trial conducted in China. This study showed that apatinib, as a monotherapy, could prolong patients' median OS and median PFS (65). Because of this trial, the China FDA approved apatinib in 2014 for metastatic GC or AEG after second-line chemotherapy.

### *Some other TKIs*

Sunitinib and sorafenib are multi-target kinase inhibitors with multiple effects of inhibiting tumor angiogenesis and anti-tumor cell growth. These drugs have been tested in some randomized Phase II trials and have shown some efficacy, but further research is needed (66-70).

### *The epidermal growth factor receptor (EGFR) as a target in AEG*

EGFR is a tyrosine kinase-type receptor of epidermal growth factor cells proliferation and signal transduction. It is associated with proliferation, angiogenesis, invasion, metastasis, and inhibition of apoptosis of tumor cells.

### *Panitumumab and cetuximab*

Panitumumab is a fully humanized monoclonal antibody with a high affinity to EGFR, which can bind to the EGFR of tumor cells, inhibit downstream cell signal transduction, and inhibit tumor growth (71). Cetuximab can competitively inhibit the binding of ligand to EGFR, block phosphorylation of receptor-related enzymes, inactivate the receptor, and block the EGFR-mediated cell signal transduction pathway, thus inhibiting the growth of tumor cells and inducing apoptosis of tumor cells (72). Neither approach has been shown to benefit patients with gastric or gastroesophageal junction adenocarcinoma. Two phase III trials, REAL3 and EXPAND, demonstrated that the addition of panitumumab or cetuximab to chemotherapy did not increase OS (73,74). Therefore, the two drugs cannot be recommended for use in patients with advanced GC or AEG.

### *Other targets in AEG*

There are many other targets available for AEG therapy, such as mesenchymal epithelial transition factor (MET), mammalian target of rapamycin (mTOR), Claudin 18.2 and PD-1/programmed-death ligand 1 (PD-L1). These targets may bring hope for targeted therapy of AEG.

### *MET*

The MET pathway plays an important role in tumor genesis. Several cancers, including gastric, lung, and colorectal cancers have been linked to this pathway. As a result, MET is a promising target for cancer therapy and drug discovery (75). A Phase III study analyzed the efficacy and safety of onartuzumab, a protein antibody that targets MET directly. The 562 patients were divided into two groups: onartuzumab plus mFOLFOX and placebo plus mFOLFOX. The results showed that the addition of onartuzumab did not improve patients' OS, PFS, or response ratio (76). The RILOMET-1 study was an attempt to evaluate whether rilotumumab had an effect on advanced MET-positive gastric or gastroesophageal junction cancer. But the trial was ended early because of the higher death rate in the rilotumumab group. The rilotumumab group and the placebo group had similar rates of serious adverse events, but the rilotumumab group had more deaths (77).

### ***mTOR***

The activity of mTOR is constantly upregulated in human cancers. The growth and metastasis of tumors are promoted by activation of the mTOR. Many mTOR inhibitors have been used in cancer treatment (78). A Phase III trial called GRANITE-1 found that everolimus did not significantly improve survival gains in advanced GC that had progressed after one or two lines of previous systemic chemotherapy (79).

### ***Claudin 18.2***

Claudin 18.2 is a gastric specific membrane protein that is considered a potential therapeutic target for GC and other types of cancer (80). Zolbetuximab (IMAB362) is a chimeric monoclonal antibody. It can kill Claudin 18.2-positive cells through immune effector mechanisms. The FAST study compared zolbetuximab in combination with EOX (epirubicin/oxaliplatin/capecitabine) *vs.* EOX alone in patients with advanced gastric/gastroesophageal junction and oesophageal adenocarcinoma. The results showed that the zolbetuximab group had a median OS of 13.0 months compared with 8.3 months for the placebo group. Median PFS for the zolbetuximab and placebo groups were 7.5 and 5.3, respectively. The OS and PFS of the Zolbetuximab group were significantly improved, and the risk of death was reduced (81). This therapy is expected to be a new targeted therapy for specific patients. It is expected that this therapy can be approved and can be applied to the clinic as soon as possible to benefit more cancer patients.

### ***PD-1/PD-L1***

In recent years, immune checkpoint therapy has emerged as an exciting therapeutic strategy for several malignancies, and monoclonal antibodies that inhibit PD-1, PD-L1, and cytotoxic T lymphocyte-associated antigen-4 (CTLA-4) have shown significant responses and clinical benefits against multiple tumor types. In September 2017, the FDA accelerated approval of pembrolizumab, a humanized monoclonal antibody that binds to and blocks PD-1 located on lymphocytes, for the treatment of patients with recurrent locally advanced or metastatic GC or AEG. Tumor growth was effectively inhibited by inhibiting the binding of PD-1 and its endogenous ligand PD-L1. This approval was based on the results of the KEYNOTE-059 study, which enrolled 259 patients with locally advanced or metastatic GC or AEG. The objective response rate in these patients was

11.6%, and 2.3% of patients achieved a complete response. The median (range) response duration was 8.4 (1.6+ to 17.3+) months (82). The KEYNOTE-061 study found that, in second-line therapy, compared with paclitaxel chemical drugs, pembrolizumab did not significantly improve the OS of AEG patients with a PD-L1 combined positive score of 1 or more, but showed higher safety (83). Whether pembrolizumab combined with agents as a neoadjuvant/adjuvant chemotherapy can significantly improve survival in patients with resectable AEG remains to be seen in the ongoing KEYNOTE-585 clinical trial (84). CHECKMATE 649 is a randomized, multicenter, open-label trial that enrolled a total of 1,581 previously untreated patients with advanced or metastatic GC, AEG, or esophageal adenocarcinoma. Patients were randomly assigned to either receive nivolumab plus chemotherapy or chemotherapy alone. The results showed that patients who received nivolumab combined with chemotherapy had better OS and PFS than patients who received chemotherapy alone, and its safety was acceptable (85). Nivolumab was approved by the FDA in April 2021 for first-line treatment of advanced or metastatic GC or AEG based on the results of the CHECKMATE 649 trial.

### **Discussion**

With the increasing trend for the use of multi-disciplinary teams in the management of AEG, the majority of AEG patients can benefit from the selection of appropriate treatment for different tumor stages.

Surgery is still the most important method in the comprehensive treatment of AEG. In recent years, with the improvement of technology, minimally invasive technology in surgery has developed rapidly. Minimally invasive AEG surgery has wide application prospects, and its research is the future trend (86-88). Minimally invasive esophagectomy can improve survival with fewer complications compared with traditional open esophagectomy (89). However, there is still no consensus on the ideal type of minimally invasive surgery, and a large number of randomized controlled trials are needed to investigate which minimally invasive technique is the best treatment for AEG (90). In addition, in order to improve the quality of life and survival of patients, targeted therapy and immunotherapy have been increasingly studied. However, because of the remarkable heterogeneity in AEG, several large Phase II clinical studies have failed, and it is very difficult to put the targeted therapy of gastroesophageal junction adenocarcinoma into

clinical practice. This shows that more detailed inclusion criteria should be formulated in the future studies and more bioactive tumor markers need to be found through molecular typing which may bring new directions of thinking for targeted therapy of gastroesophageal junction adenocarcinoma.

In summary, in order to select the most appropriate surgical plan or improve the surgical methods on this basis, the author summarized the selection of the surgical approach, resection scope, lymph node dissection scope and digestive tract reconstruction. In terms of neoadjuvant therapy and targeted therapy, this review summarized existing drugs and their clinical trial results for researchers' reference, so as to select the most appropriate drugs to improve the prognosis of patients and develop new drugs.

### Acknowledgments

*Funding:* This research was supported by grants from Medical Science and Technology Project of Zhejiang Province (No. WKJ- ZJ-2022), Natural Science Foundation of Zhejiang Province (No. LR21H280001), Program of Zhejiang Provincial TCM Sci-tech Plan (No. 2020ZZ005), National Key R&D Program of China (No. 2021YFA0910100).

### Footnote

*Reporting Checklist:* The authors have completed the Narrative Review reporting checklist. Available at <https://atm.amegroups.com/article/view/10.21037/atm-22-1064/rc>

*Conflicts of Interest:* All authors have completed the ICMJE uniform disclosure form (available at <https://atm.amegroups.com/article/view/10.21037/atm-22-1064/coif>). The authors have no conflicts of interest to declare.

*Ethical Statement:* The authors are accountable for all aspects of the work in ensuring that questions related to the accuracy or integrity of any part of the work are appropriately investigated and resolved.

*Open Access Statement:* This is an Open Access article distributed in accordance with the Creative Commons Attribution-NonCommercial-NoDerivs 4.0 International License (CC BY-NC-ND 4.0), which permits the non-commercial replication and distribution of the article with the strict proviso that no changes or edits are made and the

original work is properly cited (including links to both the formal publication through the relevant DOI and the license). See: <https://creativecommons.org/licenses/by-nc-nd/4.0/>.

### References

1. Takeuchi H, Kitagawa Y. Adenocarcinoma of the esophagogastric junction: territory of the esophagus or stomach, or an independent region? *Ann Surg Oncol* 2013;20:705-6.
2. Whiteman DC, Sadeghi S, Pandeya N, et al. Combined effects of obesity, acid reflux and smoking on the risk of adenocarcinomas of the oesophagus. *Gut* 2008;57:173-80.
3. Kusano C, Gotoda T, Khor CJ, et al. Changing trends in the proportion of adenocarcinoma of the esophagogastric junction in a large tertiary referral center in Japan. *J Gastroenterol Hepatol* 2008;23:1662-5.
4. Liu K, Yang K, Zhang W, et al. Changes of Esophagogastric Junctional Adenocarcinoma and Gastroesophageal Reflux Disease Among Surgical Patients During 1988-2012: A Single-institution, High-volume Experience in China. *Ann Surg* 2016;263:88-95.
5. Boku N, Ryu MH, Kato K, et al. Safety and efficacy of nivolumab in combination with S-1/capecitabine plus oxaliplatin in patients with previously untreated, unresectable, advanced, or recurrent gastric/gastroesophageal junction cancer: interim results of a randomized, phase II trial (ATTRACTION-4). *Ann Oncol* 2019;30:250-8.
6. Liu S, Chai N, Lu Z, et al. Long-term outcomes of superficial neoplasia at the esophagogastric junction treated via endoscopic submucosal dissection and endoscopic submucosal tunnel dissection: a cohort study of a single center from China. *Surg Endosc* 2020;34:216-25.
7. Liu Y, He S, Zhang Y, et al. Comparing long-term outcomes between endoscopic submucosal dissection (ESD) and endoscopic mucosal resection (EMR) for type II esophagogastric junction neoplasm. *Ann Transl Med* 2021;9:322.
8. Nagami Y, Ominami M, Otani K, et al. Endoscopic Submucosal Dissection for Adenocarcinomas of the Esophagogastric Junction. *Digestion* 2018;97:38-44.
9. Ajani JA, D'Amico TA, Bentrem DJ, et al. Esophageal and Esophagogastric Junction Cancers, Version 2.2019, NCCN Clinical Practice Guidelines in Oncology. *J Natl Compr Canc Netw* 2019;17:855-83.
10. Hölscher AH, Law S. Esophagogastric junction adenocarcinomas: individualization of resection with

- special considerations for Siewert type II, and Nishi types EG, E=G and GE cancers. *Gastric Cancer* 2020;23:3-9.
11. Kumamoto T, Kurahashi Y, Niwa H, et al. True esophagogastric junction adenocarcinoma: background of its definition and current surgical trends. *Surg Today* 2020;50:809-14.
  12. Maric R, Cheng KK. Classification of adenocarcinoma of the oesophagogastric junction. *Br J Surg* 1999;86:1098-9.
  13. Huang CM, Lv CB, Lin JX, et al. Laparoscopic-assisted versus open total gastrectomy for Siewert type II and III esophagogastric junction carcinoma: a propensity score-matched case-control study. *Surg Endosc* 2017;31:3495-503.
  14. Hu C, Zhu HT, Xu ZY, et al. Novel abdominal approach for dissection of advanced type II/III adenocarcinoma of the esophagogastric junction: a new surgical option. *J Int Med Res* 2019;47:398-410.
  15. Sasako M, Sano T, Yamamoto S, et al. Left thoracoabdominal approach versus abdominal-transhiatal approach for gastric cancer of the cardia or subcardia: a randomised controlled trial. *Lancet Oncol* 2006;7:644-51.
  16. Haverkamp L, Seesing MF, Ruurda JP, et al. Worldwide trends in surgical techniques in the treatment of esophageal and gastroesophageal junction cancer. *Dis Esophagus* 2017;30:1-7.
  17. Takiguchi N, Takahashi M, Ikeda M, et al. Long-term quality-of-life comparison of total gastrectomy and proximal gastrectomy by postgastrectomy syndrome assessment scale (PGSAS-45): a nationwide multi-institutional study. *Gastric Cancer* 2015;18:407-16.
  18. Goto H, Tokunaga M, Miki Y, et al. The optimal extent of lymph node dissection for adenocarcinoma of the esophagogastric junction differs between Siewert type II and Siewert type III patients. *Gastric Cancer* 2014. [Epub ahead of print].
  19. Feith M, Stein HJ, Siewert JR. Adenocarcinoma of the esophagogastric junction: surgical therapy based on 1602 consecutive resected patients. *Surg Oncol Clin N Am* 2006;15:751-64.
  20. Koyanagi K, Kato F, Kanamori J, et al. Clinical significance of esophageal invasion length for the prediction of mediastinal lymph node metastasis in Siewert type II adenocarcinoma: A retrospective single-institution study. *Ann Gastroenterol Surg* 2018;2:187-96.
  21. Kurokawa Y, Takeuchi H, Doki Y, et al. Mapping of Lymph Node Metastasis From Esophagogastric Junction Tumors: A Prospective Nationwide Multicenter Study. *Ann Surg* 2021;274:120-7.
  22. Pedrazzani C, de Manzoni G, Marrelli D, et al. Lymph node involvement in advanced gastroesophageal junction adenocarcinoma. *J Thorac Cardiovasc Surg* 2007;134:378-85.
  23. Hosokawa Y, Kinoshita T, Konishi M, et al. Clinicopathological features and prognostic factors of adenocarcinoma of the esophagogastric junction according to Siewert classification: experiences at a single institution in Japan. *Ann Surg Oncol* 2012;19:677-83.
  24. Yamashita H, Seto Y, Sano T, et al. Results of a nationwide retrospective study of lymphadenectomy for esophagogastric junction carcinoma. *Gastric Cancer* 2017;20:69-83.
  25. Matsuda T, Kurokawa Y, Yoshikawa T, et al. Clinicopathological Characteristics and Prognostic Factors of Patients with Siewert Type II Esophagogastric Junction Carcinoma: A Retrospective Multicenter Study. *World J Surg* 2016;40:1672-9.
  26. Yoo CH, Sohn BH, Han WK, et al. Long-term results of proximal and total gastrectomy for adenocarcinoma of the upper third of the stomach. *Cancer Res Treat* 2004;36:50-5.
  27. Adachi Y, Inoue T, Hagino Y, et al. Surgical results of proximal gastrectomy for early-stage gastric cancer: jejunal interposition and gastric tube reconstruction. *Gastric Cancer* 1999;2:40-5.
  28. Aihara R, Mochiki E, Ohno T, et al. Laparoscopy-assisted proximal gastrectomy with gastric tube reconstruction for early gastric cancer. *Surg Endosc* 2010;24:2343-8.
  29. Yamashita Y, Yamamoto A, Tamamori Y, et al. Side overlap esophagogastrectomy to prevent reflux after proximal gastrectomy. *Gastric Cancer* 2017;20:728-35.
  30. Kano Y, Ohashi M, Ida S, et al. Laparoscopic proximal gastrectomy with double-flap technique versus laparoscopic subtotal gastrectomy for proximal early gastric cancer. *BJS Open* 2020;4:252-9.
  31. Shoji Y, Nunobe S, Ida S, et al. Surgical outcomes and risk assessment for anastomotic complications after laparoscopic proximal gastrectomy with double-flap technique for upper-third gastric cancer. *Gastric Cancer* 2019;22:1036-43.
  32. Merendino KA, Dillard DH. The concept of sphincter substitution by an interposed jejunal segment for anatomic and physiologic abnormalities at the esophagogastric junction; with special reference to reflux esophagitis, cardiospasm and esophageal varices. *Ann Surg* 1955;142:486-506.
  33. Katai H, Morita S, Saka M, et al. Long-term outcome

- after proximal gastrectomy with jejunal interposition for suspected early cancer in the upper third of the stomach. *Br J Surg* 2010;97:558-62.
34. Nozaki I, Hato S, Kobatake T, et al. Long-term outcome after proximal gastrectomy with jejunal interposition for gastric cancer compared with total gastrectomy. *World J Surg* 2013;37:558-64.
  35. Nomura E, Lee SW, Kawai M, et al. Functional outcomes by reconstruction technique following laparoscopic proximal gastrectomy for gastric cancer: double tract versus jejunal interposition. *World J Surg Oncol* 2014;12:20.
  36. Yamashita K, Iwatsuki M, Koga Y, et al. Preservation of physiological passage through the remnant stomach prevents postoperative malnutrition after proximal gastrectomy with double tract reconstruction. *Surg Today* 2019;49:748-54.
  37. Li S, Gu L, Shen Z, et al. A meta-analysis of comparison of proximal gastrectomy with double-tract reconstruction and total gastrectomy for proximal early gastric cancer. *BMC Surg* 2019;19:117.
  38. Jung DH, Lee Y, Kim DW, et al. Laparoscopic proximal gastrectomy with double tract reconstruction is superior to laparoscopic total gastrectomy for proximal early gastric cancer. *Surg Endosc* 2017;31:3961-9.
  39. Sugiyama M, Oki E, Ando K, et al. Laparoscopic Proximal Gastrectomy Maintains Body Weight and Skeletal Muscle Better Than Total Gastrectomy. *World J Surg* 2018;42:3270-6.
  40. Cunningham D, Allum WH, Stenning SP, et al. Perioperative chemotherapy versus surgery alone for resectable gastroesophageal cancer. *N Engl J Med* 2006;355:11-20.
  41. Ychou M, Boige V, Pignon JP, et al. Perioperative chemotherapy compared with surgery alone for resectable gastroesophageal adenocarcinoma: an FNCLCC and FFCO multicenter phase III trial. *J Clin Oncol* 2011;29:1715-21.
  42. Al-Batran SE, Homann N, Pauligk C, et al. Perioperative chemotherapy with fluorouracil plus leucovorin, oxaliplatin, and docetaxel versus fluorouracil or capecitabine plus cisplatin and epirubicin for locally advanced, resectable gastric or gastro-oesophageal junction adenocarcinoma (FLOT4): a randomised, phase 2/3 trial. *Lancet* 2019;393:1948-57.
  43. Zhang X, Liang H, Li Z, et al. Perioperative or postoperative adjuvant oxaliplatin with S-1 versus adjuvant oxaliplatin with capecitabine in patients with locally advanced gastric or gastro-oesophageal junction adenocarcinoma undergoing D2 gastrectomy (RESOLVE): an open-label, superiority and non-inferiority, phase 3 randomised controlled trial. *Lancet Oncol* 2021;22:1081-92.
  44. Shapiro J, van Lanschot JJB, Hulshof MCCM, et al. Neoadjuvant chemoradiotherapy plus surgery versus surgery alone for oesophageal or junctional cancer (CROSS): long-term results of a randomised controlled trial. *Lancet Oncol* 2015;16:1090-8.
  45. Stahl M, Walz MK, Riera-Knorrenschild J, et al. Preoperative chemotherapy versus chemoradiotherapy in locally advanced adenocarcinomas of the oesophagogastric junction (POET): Long-term results of a controlled randomised trial. *Eur J Cancer* 2017;81:183-90.
  46. Fanotto V, Ongaro E, Rihawi K, et al. HER-2 inhibition in gastric and colorectal cancers: tangible achievements, novel acquisitions and future perspectives. *Oncotarget* 2016;7:69060-74.
  47. Bang YJ, Van Cutsem E, Feyereislova A, et al. Trastuzumab in combination with chemotherapy versus chemotherapy alone for treatment of HER2-positive advanced gastric or gastro-oesophageal junction cancer (ToGA): a phase 3, open-label, randomised controlled trial. *Lancet* 2010;376:687-97.
  48. Makiyama A, Sukawa Y, Kashiwada T, et al. Randomized, Phase II Study of Trastuzumab Beyond Progression in Patients With HER2-Positive Advanced Gastric or Gastroesophageal Junction Cancer: WJOG7112G (T-ACT Study). *J Clin Oncol* 2020;38:1919-27.
  49. Barok M, Joensuu H, Isola J. Trastuzumab emtansine: mechanisms of action and drug resistance. *Breast Cancer Res* 2014;16:209.
  50. Thuss-Patience PC, Shah MA, Ohtsu A, et al. Trastuzumab emtansine versus taxane use for previously treated HER2-positive locally advanced or metastatic gastric or gastro-oesophageal junction adenocarcinoma (GATSBY): an international randomised, open-label, adaptive, phase 2/3 study. *Lancet Oncol* 2017;18:640-53.
  51. Kim JW, Kim HP, Im SA, et al. The growth inhibitory effect of lapatinib, a dual inhibitor of EGFR and HER2 tyrosine kinase, in gastric cancer cell lines. *Cancer Lett* 2008;272:296-306.
  52. Hecht JR, Bang YJ, Qin SK, et al. Lapatinib in Combination With Capecitabine Plus Oxaliplatin in Human Epidermal Growth Factor Receptor 2-Positive Advanced or Metastatic Gastric, Esophageal, or Gastroesophageal Adenocarcinoma: TRIO-013/

- LOGiC--A Randomized Phase III Trial. *J Clin Oncol* 2016;34:443-51.
53. Satoh T, Xu RH, Chung HC, et al. Lapatinib plus paclitaxel versus paclitaxel alone in the second-line treatment of HER2-amplified advanced gastric cancer in Asian populations: TyTAN--a randomized, phase III study. *J Clin Oncol* 2014;32:2039-49.
  54. Shepard G, Arrowsmith ER, Murphy P, et al. A Phase II Study with Lead-In Safety Cohort of 5-Fluorouracil, Oxaliplatin, and Lapatinib in Combination with Radiation Therapy as Neoadjuvant Treatment for Patients with Localized HER2-Positive Esophagogastric Adenocarcinomas. *Oncologist* 2017;22:1152-e98.
  55. Tie J, Desai J. Antiangiogenic therapies targeting the vascular endothelia growth factor signaling system. *Crit Rev Oncog* 2012;17:51-67.
  56. Fuchs CS, Tomasek J, Yong CJ, et al. Ramucirumab monotherapy for previously treated advanced gastric or gastro-oesophageal junction adenocarcinoma (REGARD): an international, randomised, multicentre, placebo-controlled, phase 3 trial. *Lancet* 2014;383:31-9.
  57. Wilke H, Muro K, Van Cutsem E, et al. Ramucirumab plus paclitaxel versus placebo plus paclitaxel in patients with previously treated advanced gastric or gastro-oesophageal junction adenocarcinoma (RAINBOW): a double-blind, randomised phase 3 trial. *Lancet Oncol* 2014;15:1224-35.
  58. Fuchs CS, Shitara K, Di Bartolomeo M, et al. Ramucirumab with cisplatin and fluoropyrimidine as first-line therapy in patients with metastatic gastric or junctional adenocarcinoma (RAINFALL): a double-blind, randomised, placebo-controlled, phase 3 trial. *Lancet Oncol* 2019;20:420-35.
  59. Ferrara N, Hillan KJ, Gerber HP, et al. Discovery and development of bevacizumab, an anti-VEGF antibody for treating cancer. *Nat Rev Drug Discov* 2004;3:391-400.
  60. El-Rayes BF, Zalupski M, Bekai-Saab T, et al. A phase II study of bevacizumab, oxaliplatin, and docetaxel in locally advanced and metastatic gastric and gastroesophageal junction cancers. *Ann Oncol* 2010;21:1999-2004.
  61. Shah MA, Jhaver M, Ilson DH, et al. Phase II study of modified docetaxel, cisplatin, and fluorouracil with bevacizumab in patients with metastatic gastroesophageal adenocarcinoma. *J Clin Oncol* 2011;29:868-74.
  62. Ohtsu A, Shah MA, Van Cutsem E, et al. Bevacizumab in combination with chemotherapy as first-line therapy in advanced gastric cancer: a randomized, double-blind, placebo-controlled phase III study. *J Clin Oncol* 2011;29:3968-76.
  63. Shen L, Li J, Xu J, et al. Bevacizumab plus capecitabine and cisplatin in Chinese patients with inoperable locally advanced or metastatic gastric or gastroesophageal junction cancer: randomized, double-blind, phase III study (AVATAR study). *Gastric Cancer* 2015;18:168-76.
  64. Zhang H. Apatinib for molecular targeted therapy in tumor. *Drug Des Devel Ther* 2015;9:6075-81.
  65. Li J, Qin S, Xu J, et al. Randomized, Double-Blind, Placebo-Controlled Phase III Trial of Apatinib in Patients With Chemotherapy-Refractory Advanced or Metastatic Adenocarcinoma of the Stomach or Gastroesophageal Junction. *J Clin Oncol* 2016;34:1448-54.
  66. Bang YJ, Kang YK, Kang WK, et al. Phase II study of sunitinib as second-line treatment for advanced gastric cancer. *Invest New Drugs* 2011;29:1449-58.
  67. Wu C, Mikhail S, Wei L, et al. A phase II and pharmacodynamic study of sunitinib in relapsed/refractory oesophageal and gastro-oesophageal cancers. *Br J Cancer* 2015;113:220-5.
  68. Moehler M, Gepfner-Tuma I, Maderer A, et al. Sunitinib added to FOLFIRI versus FOLFIRI in patients with chemorefractory advanced adenocarcinoma of the stomach or lower esophagus: a randomized, placebo-controlled phase II AIO trial with serum biomarker program. *BMC Cancer* 2016;16:699.
  69. Sun W, Powell M, O'Dwyer PJ, et al. Phase II study of sorafenib in combination with docetaxel and cisplatin in the treatment of metastatic or advanced gastric and gastroesophageal junction adenocarcinoma: ECOG 5203. *J Clin Oncol* 2010;28:2947-51.
  70. Janjigian YY, Vakiani E, Ku GY, et al. Phase II Trial of Sorafenib in Patients with Chemotherapy Refractory Metastatic Esophageal and Gastroesophageal (GE) Junction Cancer. *PLoS One* 2015;10:e0134731.
  71. Del Prete M, Giampieri R, Faloppi L, et al. Panitumumab for the treatment of metastatic colorectal cancer: a review. *Immunotherapy* 2015;7:721-38.
  72. Mazarella L, Guida A, Curigliano G. Cetuximab for treating non-small cell lung cancer. *Expert Opin Biol Ther* 2018;18:483-93.
  73. Waddell T, Chau I, Cunningham D, et al. Epirubicin, oxaliplatin, and capecitabine with or without panitumumab for patients with previously untreated advanced oesophagogastric cancer (REAL3): a randomised, open-label phase 3 trial. *Lancet Oncol* 2013;14:481-9.
  74. Lordick F, Kang YK, Chung HC, et al. Capecitabine and cisplatin with or without cetuximab for patients with previously untreated advanced gastric cancer (EXPAND):

- a randomised, open-label phase 3 trial. *Lancet Oncol* 2013;14:490-9.
75. Mo HN, Liu P. Targeting MET in cancer therapy. *Chronic Dis Transl Med* 2017;3:148-53.
  76. Shah MA, Bang YJ, Lordick F, et al. Effect of Fluorouracil, Leucovorin, and Oxaliplatin With or Without Onartuzumab in HER2-Negative, MET-Positive Gastroesophageal Adenocarcinoma: The METGastric Randomized Clinical Trial. *JAMA Oncol* 2017;3:620-7.
  77. Catenacci DVT, Tebbutt NC, Davidenko I, et al. Rilotumumab plus epirubicin, cisplatin, and capecitabine as first-line therapy in advanced MET-positive gastric or gastro-oesophageal junction cancer (RILOMET-1): a randomised, double-blind, placebo-controlled, phase 3 trial. *Lancet Oncol* 2017;18:1467-82.
  78. Hua H, Kong Q, Zhang H, et al. Targeting mTOR for cancer therapy. *J Hematol Oncol* 2019;12:71.
  79. Ohtsu A, Ajani JA, Bai YX, et al. Everolimus for previously treated advanced gastric cancer: results of the randomized, double-blind, phase III GRANITE-1 study. *J Clin Oncol* 2013;31:3935-43.
  80. Jiang H, Shi Z, Wang P, et al. Claudin18.2-Specific Chimeric Antigen Receptor Engineered T Cells for the Treatment of Gastric Cancer. *J Natl Cancer Inst* 2019;111:409-18.
  81. Sahin U, Türeci Ö, Manikhas G, et al. FAST: a randomised phase II study of zolbetuximab (IMAB362) plus EOX versus EOX alone for first-line treatment of advanced CLDN18.2-positive gastric and gastro-oesophageal adenocarcinoma. *Ann Oncol* 2021;32:609-19.
  82. Bang YJ, Kang YK, Catenacci DV, et al. Pembrolizumab alone or in combination with chemotherapy as first-line therapy for patients with advanced gastric or gastroesophageal junction adenocarcinoma: results from the phase II nonrandomized KEYNOTE-059 study. *Gastric Cancer* 2019;22:828-37.
  83. Shitara K, Özgüroğlu M, Bang YJ, et al. Pembrolizumab versus paclitaxel for previously treated, advanced gastric or gastro-oesophageal junction cancer (KEYNOTE-061): a randomised, open-label, controlled, phase 3 trial. *Lancet* 2018;392:123-33.
  84. Bang YJ, Van Cutsem E, Fuchs CS, et al. KEYNOTE-585: Phase III study of perioperative chemotherapy with or without pembrolizumab for gastric cancer. *Future Oncol* 2019;15:943-52.
  85. Janjigian YY, Shitara K, Moehler M, et al. First-line nivolumab plus chemotherapy versus chemotherapy alone for advanced gastric, gastro-oesophageal junction, and oesophageal adenocarcinoma (CheckMate 649): a randomised, open-label, phase 3 trial. *Lancet* 2021;398:27-40.
  86. Gemmill EH, McCulloch P. Systematic review of minimally invasive resection for gastro-oesophageal cancer. *Br J Surg* 2007;94:1461-7.
  87. Straatman J, van der Wielen N, Nieuwenhuijzen GA, et al. Techniques and short-term outcomes for total minimally invasive Ivor Lewis esophageal resection in distal esophageal and gastroesophageal junction cancers: pooled data from six European centers. *Surg Endosc* 2017;31:119-26.
  88. Tagkalos E, Goense L, Hoppe-Lotichius M, et al. Robot-assisted minimally invasive esophagectomy (RAMIE) compared to conventional minimally invasive esophagectomy (MIE) for esophageal cancer: a propensity-matched analysis. *Dis Esophagus* 2020;33:doz060.
  89. Yamashita K, Watanabe M, Mine S, et al. Minimally invasive esophagectomy attenuates the postoperative inflammatory response and improves survival compared with open esophagectomy in patients with esophageal cancer: a propensity score matched analysis. *Surg Endosc* 2018;32:4443-50.
  90. Zhang S, Orita H, Fukunaga T. Current surgical treatment of esophagogastric junction adenocarcinoma. *World J Gastrointest Oncol* 2019;11:567-78.

**Cite this article as:** Cao F, Hu C, Xu ZY, Zhang YQ, Huang L, Chen JH, Qin JJ, Cheng XD. Current treatments and outlook in adenocarcinoma of the esophagogastric junction: a narrative review. *Ann Transl Med* 2022;10(6):377. doi: 10.21037/atm-22-1064



## Supplementary

**Table S1** The results of search terms

Search terms	Results
Adenocarcinoma of the esophagogastric junction	2,723
Gastroesophageal adenocarcinoma and surgical treatment	1,717
Gastroesophageal adenocarcinoma and target therapy	363
Gastroesophageal adenocarcinoma and neoadjuvant therapy	400
Gastroesophageal adenocarcinoma and immunotherapy	101