



Pectic polysaccharides ameliorate the pathology of ulcerative colitis in mice by reducing pyroptosis

Lu-Jia Cui^{1#}, Wei Yuan^{2#}, Feng-Ying Chen¹, Yu-Xuan Wang¹, Qiu-Min Li¹, Cheng Lin¹, Xin-Pu Miao¹

¹Department of Gastroenterology, Hainan General Hospital/Hainan Affiliated Hospital of Hainan Medical University, Haikou, China; ²Department of Emergency Surgery, Hainan General Hospital/Hainan Affiliated Hospital of Hainan Medical University, Haikou, China

Contributions: (I) Conception and design: XP Miao; (II) Administrative support: XP Miao; (III) Provision of study materials or patients: LJ Cui, W Yuan, C Lin; (IV) Collection and assembly of data: FY Chen, YX Wang; (V) Data analysis and interpretation: QM Li; (VI) Manuscript writing: All authors; (VII) Final approval of manuscript: All authors.

[#]These authors contributed equally to this work.

Correspondence to: Xin-Pu Miao. Department of Gastroenterology, Hainan General Hospital/Hainan Affiliated Hospital of Hainan Medical University, No. 19 Xiuhua Road, Haikou 570311, China. Email: miaoxinpu@163.com.

Background: Ulcerative colitis (UC) is an inflammatory bowel disease which seriously affects the quality of life of patients. There has been an increasing amount of research related to the therapeutic effects and mechanisms of natural plant substances in the treatment of recurrent UC. *Rauwolfia verticillata* var. *Hainanensis* is a medicinal plant that is native to Hainan Island, China. Some studies have documented that pectic polysaccharides (PPs) from *Rauwolfia* inhibited the progression of colon ulcers. However, their mechanisms of action have not been established. Studies have revealed that suppressing pyroptosis can attenuate the damage of experimental colitis. However, it is unclear whether PPs from *Rauwolfia verticillata* inhibit inflammation through pyroptosis. This study investigated the effects and potential mechanisms of PPs extracted from *Rauwolfia verticillata* on experimental UC in mice.

Methods: Male C57 mice (6–8 weeks old) were allocated into the control group, the dextran sulfate sodium (DSS)-induced UC model group (DSS group), or the DSS with pectic polysaccharides treatment group (DSS + PP group). The body weights, rectal bleeding, and stool consistencies in the mice were observed, and the disease activity index (DAI) score was calculated. Colon tissues were collected for pathological analysis by histological hematoxylin and eosin (H&E) staining. The levels of caspase-1 and interleukin (IL)-1 β were detected by immunohistochemistry. Pyroptosis was assessed by transmission electron microscopy.

Results: UC in mice induced by DSS resulted in decreased general physical activity and body weight, increased DAI score, significant histological changes, inhibited caspase-1 and IL-1 β expression, and promoted pyroptosis. These DSS-induced changes could be partially ameliorated by administration of PP.

Conclusions: PPs exerted an ameliorative effect on DSS-induced UC in mice by reducing pyroptosis.

Keywords: Pectic polysaccharides (PPs); ulcerative colitis (UC); pyroptosis; inflammation

Submitted Jan 14, 2022. Accepted for publication Mar 21, 2022.

doi: 10.21037/atm-22-877

View this article at: <https://dx.doi.org/10.21037/atm-22-877>

Introduction

Ulcerative colitis (UC) is a chronic idiopathic inflammatory disease with increasing prevalence worldwide (1). The clinical manifestations of UC include recurrent abdominal pain, diarrhea, and blood in the stool. UC is characterized

by low quality of life, long duration, low curative rates, and high risk of malignancies (2). The pathogenesis of UC remains elusive, but it has been associated with genetic and environmental factors, as well as immune response abnormalities. While immunosuppressants, glucocorticoids,

and biological agents are the gold standard for UC therapy (3), there are many disadvantages associated with these agents (4). Therefore, understanding the molecular mechanisms of UC is crucial for the development of novel targeted therapies or effective clinical regimens for the treatment UC.

There has been an increasing amount of research related to the therapeutic effects and mechanisms of natural plant substances in the treatment of recurrent UC (5). Natural-derived polysaccharides are becoming a research hotspot for their therapeutic effects on inflammatory bowel disease (IBD) (6). *Rauwolfia verticillata* var. *hainanensis* is a medicinal plant that is native to Hainan Island, China. It is mostly distributed in tropical rainforests such as those of Ledong Jianfengling and Lingshui Diaoluo Mountains in Hainan. The active components of this medicinal plant are pectin polysaccharides (PPs) and alkaloids (7). Popov *et al.* documented that PPs from *Rauwolfia* inhibited the progression of colon ulcers and reduced rectal myeloperoxidase levels in mice (8). However, their mechanisms of action have not been established. Previous studies have shown that *Rauwolfia hainanensis* extracts, especially PPs, inhibited the progression of dextran sulfate sodium (DSS)-induced colitis in mice by regulating the nuclear factor (NF)- κ B pathway and interleukin (IL)-17 (9,10). Other reports have demonstrated that its mechanisms may be associated with the NF- κ B and mitogen-activated protein kinase (MAPK) signaling pathways in which dendrites derived from mouse bone marrow shape cells play an essential role (10).

Pyroptosis is one form of programmed cell death that is associated with inflammation. It is mechanistically and morphologically distinct from other forms of cell death. A defining feature of pyroptosis is the crucial role of the enzyme caspase 1 (11). Activated inflammatory caspases can induce pyroptosis and produce pro-inflammatory cytokines, and inflammatory caspases could be attractive therapeutic targets for UC in which pyroptosis may play an important role (12). Studies have revealed that suppressing pyroptosis can attenuate the damage of experimental colitis (13,14). These results indicated a potential role of pyroptosis in the development of UC. However, it is unclear whether PPs from *Rauwolfia verticillata* inhibit inflammation through pyroptosis. This current study investigated the effects of PPs extracted from *Rauwolfia verticillata* in DSS-induced UC in mice and examined the potential mechanisms of action. We present the following article in accordance with

the ARRIVE reporting checklist (available at <https://atm.amegroups.com/article/view/10.21037/atm-22-877/rc>).

Methods

Ethical statement

This study was approved by the animal care review committee of the Hainan General Hospital/Hainan Affiliated Hospital of Hainan Medical University under a project license (No. 20210305), in compliance with National Research Council (NRC) Guide for the Care and Use of Laboratory Animals (8th edition).

Plant collection and pectic polysaccharide (PP) extraction

Rauwolfia verticillata was obtained on June 21, 2018 from the Jianfengling National Forest Park of Ledong Li autonomous county, Hainan province, China. The PPs were extracted as previously described with minor modifications (8). Briefly, 5 g of rhizome was dried at 40 °C, treated with dilute HCl (pH 4.4) at 50 °C for 3 hours and extracted with 0.7% aqueous ammonium oxalate. The polysaccharide fraction was precipitated with 10 mL 96% ethanol. After centrifugation at 8,000 g for 10 minutes, the precipitate was obtained and dried at 40 °C.

Animal models

Specific pathogen-free (SPF) male C57 mice (6–8 weeks old) were purchased from Hunan SJA Laboratory Animal Co., Ltd. The mice were housed under standard conditions and maintained in a 12-hour light/dark cycle at 23±1 °C with free access to food and water. A total of 18 mice were randomly distributed into 3 groups of 6 mice each: the control group (normal control), in which the mice were administered ultrapure water; the DSS group, in which mice were administered 5% DSS aqueous solution for 5 days; and the DSS + PP group, in which mice were administered DSS aqueous solution for 5 days followed by intragastric administration of 100 μ L PP solution (100 mg/kg/d) for 7 consecutive days (9,10). The 5% DSS aqueous solution was prepared using ultrapure water. The overall behavior of the mice was observed. At the end of the experiment, the mice were sacrificed (*Figure 1A*) and their colon tissues collected, cleaned, and fixed with formalin and electron microscope fixation solution.

Evaluation of the body weight and the disease activity index (DAI)

During the treatment period, the body weights of the mice were measured on days 0, 5, 10, and 12. The DAI score, used to evaluate the severity of colitis (15), was calculated as a total score taking into account the decrease in body weight, stool observations for rectal bleeding, and stool consistency. The maximum value is 14.

Histological staining

Tissue slices were baked at 70 °C for 30 minutes and dewaxed twice in xylene for 10 minutes. Slices were washed twice with 100% ethanol for 5 minutes, followed by hydration in ethanol for 5 minutes (three times) and hydration in distilled water. Hematoxylin staining was performed for 3 minutes followed by washing under running water for 2 minutes. Hydrochloric acid alcohol (1%) was applied for 2 seconds for differentiation. Slides were then washed under running water for 15 minutes, and washed with distilled water for 2 seconds. Samples were stained with eosin for 30 seconds followed by differentiation and dehydration in 80% ethanol. Xylene was applied twice for 10 minutes each time, and a drop of neutral gum was added to the center of the paraffin section. A glass cover slide was applied, and the samples were observed under a light microscope.

Immunohistochemistry (IHC) staining

The caspase-1 antibody (1:50 dilution; cat. Ab74279, Shanghai, China) and the IL-1 β antibody (1:100 dilution; cat. Ab2105, Shanghai, China), were purchased from Abcam. After heat-mediated antigen retrieval was performed, caspase-1 and IL-1 β expression levels in colonic tissues were detected by immunohistochemistry. Positively stained cells were counted and expressed as a percentage of total cells.

Transmission electron microscopy

Tissue samples were fixed with 1% osmium acid fixative solution for 1–2 hours, rinsed 3 times with 0.1 M phosphoric acid solution for 5 minutes and dehydrated using ethanol. Samples were embedded using pure acetone and an embedding solution (EPON812) at 37 °C overnight,

followed by incubation at 45 °C for 12 hours and at 60 °C for 48 hours. The ultra-thin microtome Lycra EMUC7 was used to prepare 70 nm sections. Sections were stained with 2% uranyl acetate-lead citrate and observed under a transmission electron microscope (Hitachi Ltd) HT7800 135 (80 KV).

Statistical analysis

The GraphPad Prism software (version 6.01) was used for statistical analysis. The Student's *t*-test was used for pairwise comparisons while one-way analysis of variance (ANOVA) was used for multiple comparisons. A *P* value ≤ 0.05 was considered statistically significant. Data are presented as the mean \pm standard error of the mean (SEM).

Results

The effects of PPs on the general physical activity and body weight of DSS-induced UC mice

On day 5 post-DSS induction, 3 of the 6 mice in the DSS group (50%) showed low alertness and decreased food consumption, and by day 10, this was observed in all 6 mice (100%). Mice in this group showed significantly drier and duller hair, as well as perianal bleeding. Compared to the DSS group, the DSS + PP group exhibited reduced symptoms of colitis 10 days after PP administration, including more alertness, reduced hair loss, and more physical activity. *Figure 1B* shows that the body weight of the mice in the control group increased steadily, while the body weight in the model group gradually decreased. The weight of the mice in the DSS + PP group was also reduced on day 5. However, after administration of the PP on day 6, the body weight did not significantly decrease, demonstrating that the PP was effective in ameliorating colitis-associated weight loss.

The effects of PPs on DAI score

As shown in *Table 1*, no changes in DAI scores were found between day 0 and day 5 in any of the groups of mice. On day 10, the DAI scores were significantly increased in the DSS group and the DSS + PP group compared to the control group ($P < 0.05$). This suggested that there was persistent destruction of the colon in both these groups. Administration of PPs in UC mice reduced the increase in

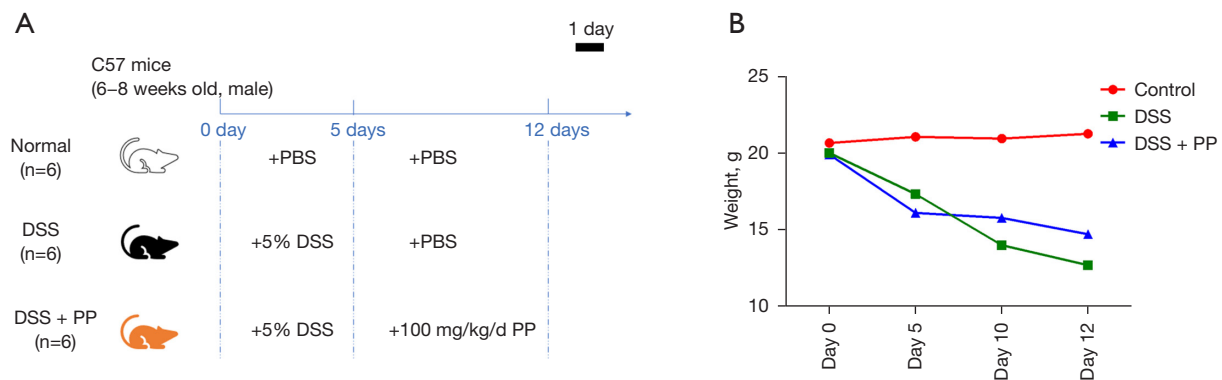


Figure 1 The mice handling process and weight determination. (A) Description of the three groups of mice; (B) the changes in the body weights of the mice. The body weight in the control group increased steadily, and decreased gradually in the model group. The weight of the mice in the DSS + PP group was also reduced on day 5. However, after administration of PPs on day 6, the body weight did not significantly decrease, suggesting that the treatment was effective. PBS, phosphate buffered saline; DSS, dextran sulfate sodium; PP, pectic polysaccharide.

Table 1 The DAI in mice

Group (n=6)	Days of treatment			
	0	5	10	12
Control	0	0	0	0
DSS	0	0	7.53±0.31	4.96±0.04
DSS + PP	0	0	6.52±0.26*	3.55±0.22*

*, $P < 0.05$ in statistical analysis comparing the DSS + PP group to the DSS group. DAI, disease activity index; DSS, dextran sulphate sodium; PP, pectic polysaccharides.

DAI scores on days 10 and 12 compared to the DSS group ($P < 0.05$).

The effects of PPs on the histology observed in DSS-induced UC mice

To assess the effects of PPs in DSS-induced UC mice, histological observations were performed by H&E staining on day 12. In the control group, tissue sections showed intact intestinal mucosal epithelium, typical submucosal blood vessels, and regularly arranged gland structure (Figure 2A). There were no obvious congestion, edema, nor corrosion ulcers. The goblet cells were visible. However, in the DSS model group, part of the intestinal epithelium of the colon was ruptured and shed. The glands were destroyed and there was a large infiltration of inflammatory cells. The blood vessels were significantly dilated and

congested. There were proliferated granulation tissue and decreased goblet cells. Ulcers and various degrees of focal erosion were formed. In contrast, the colon epithelium of mice in the DSS + PP group showed varying degrees of repair and significantly reduced inflammatory cell infiltration.

PPs decrease the expression of caspase-1 and IL-1 β in DSS-induced UC mice

Caspase-1 and IL-1 β have been shown to be involved in the pathway of pyroptosis. Immunohistochemistry showed that the expression of caspase-1 and IL-1 β in the control group were 0.652 ± 0.080 and 0.903 ± 0.279 , respectively. The expression of caspase-1 and IL-1 β were significantly higher in both the DSS group and the DSS + PP group compared to the control group ($P < 0.001$; Figure 2B, 2C). The expression of caspase-1 and IL-1 β in the DSS group were 4.142 ± 0.508 and 7.263 ± 0.433 , respectively. Treatment of DSS mice with PPs reduced the caspase-1 and IL-1 β levels to 2.015 ± 0.228 and 4.267 ± 0.184 , respectively ($P < 0.01$ compared to the DSS group; Figure 2B, 2C). This suggested that PPs significantly inhibited the progression of UC, and the potential mechanisms of action may involve the inhibition of critical proteins such as caspase-1 and IL-1 β .

PPs inhibit pyroptosis of cells in DSS-induced UC mice

To better evaluate pyroptosis, transmission electron

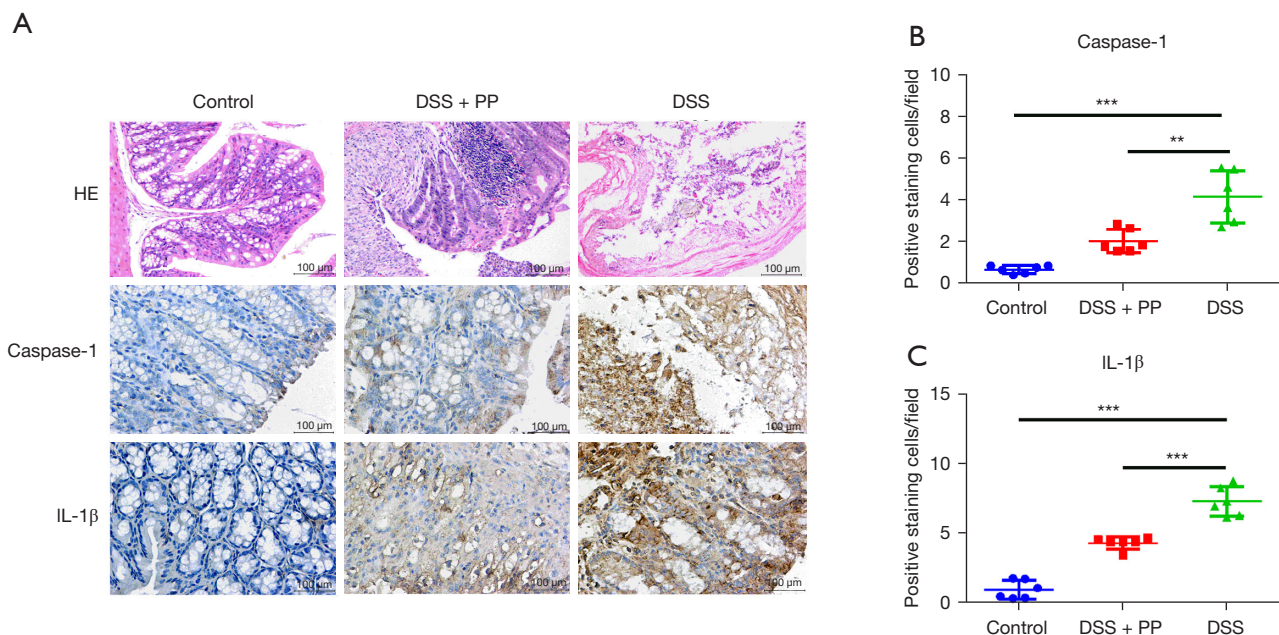


Figure 2 Hematoxylin and eosin staining and immunohistochemical detection of caspase-1 and IL-1 β expression. (A) H&E staining and immunohistochemical detection of caspase-1 and IL-1 β expression. The figures are 209 mm \times 122 mm (300 \times 300 DPI). In the control group, tissue sections showed intact intestinal mucosal epithelium, typical submucosal blood vessels, and regularly arranged gland structure. In the DSS model group, part of the intestinal epithelium of the colon was ruptured and shed. Ulcers and various degrees of focal erosion were formed. The colon epithelium of mice in the DSS + PP group showed varying degrees of repair, and significantly reduced infiltration of inflammatory cells. (B) Immunohistochemical detection of caspase-1. (C) Immunohistochemical detection of IL-1 β . Results are presented as mean \pm SEM. **, $P < 0.01$; ***, $P < 0.001$. Scale bar = 100 μ m for (A). H&E, hematoxylin and eosin; IL, interleukin; DSS, dextran sulfate sodium; PP, pectic polysaccharide; SEM, standard error of the mean; DPI, dots per inch.

microscopy was performed to assess the colorectal tissue sections from each group of mice (Figure 3). The results showed that cells in the control group exhibited a normal morphology. In contrast, the DSS group exhibited a classic scorch phase characterized by abnormally enlarged cells, ruptured cell membranes, and released cell contents that triggered local inflammation. In the DSS + PP group, while a proportion of cells exhibited pyroptosis morphology, the number of damaged cells was fewer, and the sizes were smaller than those in the DSS group, indicating that PPs alleviated the effects of DSS-induced pyroptosis.

Discussion

The rising prevalence of UC has resulted in high economic burden to individuals and society. The present study demonstrated the ameliorative effects of PPs on experimental UC in mice. In this mouse model, 5% DSS

was used to induce acute colitis, resulting in disrupted integrity of intestinal epithelial cells and tense inflammation. Treatment with PPs reduced the colitis-associated weight loss, improved the DAI scores, and relieved the histological changes, suggesting that PPs may have therapeutic potential for UC. Moreover, the histological results demonstrated that DSS-induced caspase-1 and IL-1 β is inhibited by PP treatment. The potential mechanisms may involve the inhibition of pyroptosis. While transmission electron microscopy detected pyroptosis in the DSS group, treatment with PPs alleviated the effects of DSS-induced pyroptosis in mice.

UC has been listed as a risk factor for developing intestinal cancers via mechanisms that remain incompletely understood. The early events of UC are represented by oxidative DNA damage and DNA methylation that can produce an inhibition of onco-suppressor genes, mutation of p53, aneuploidy, and microsatellite instability (16).

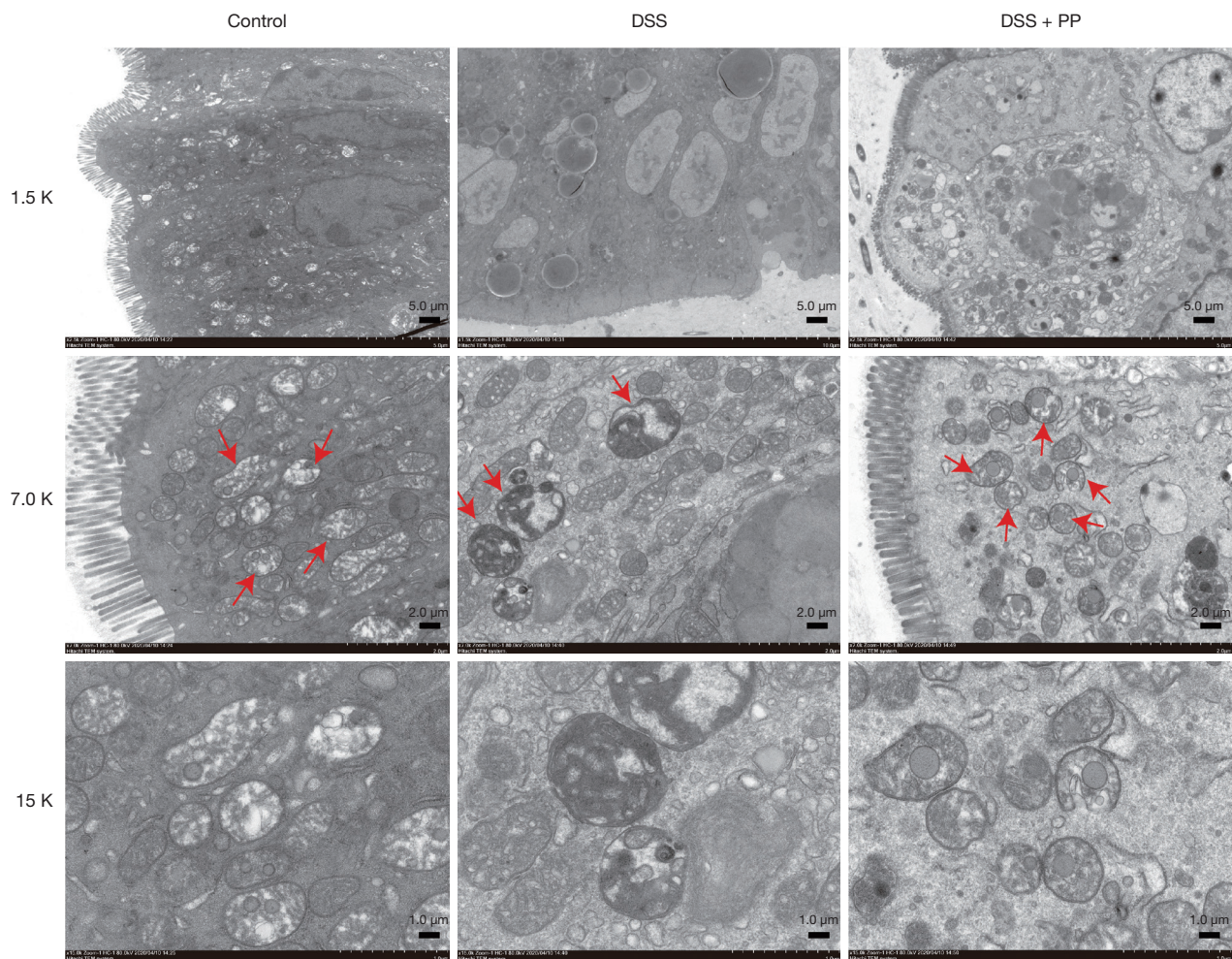


Figure 3 Administration of pectic polysaccharides ameliorates the morphological changes due to DSS-induced pyroptosis. Electron microscopy revealed that colorectal tissue in control mice exhibited normal morphology (red arrow for Control group). Mice treated with DSS showed a classic scorch phase, characterized by abnormally enlarged cells, rupture of the cell membranes, and released cell contents that triggered local inflammation (red arrow for DSS group). In DSS mice treated with PPs, some cells exhibited pyroptosis morphology, while other cells did not (red arrow for DSS + PP group). 1.5 K scale bar = 5 μm , 7.0 K scale bar = 2 μm , 15 K scale bar = 1 μm . DSS, dextran sulfate sodium; PP, pectic polysaccharide.

To date, there are still no specific effective drugs for the treatment of UC. The present drugs such as salicylic acid, glucocorticoids, and immunosuppressant are associated with many side effects, unstable efficacies, and high relapse when administration is terminated (17). Furthermore, the long-term use of these biological agents confers extreme adverse reactions and heavy financial burden (18). PPs are components of the cell walls of fruits and vegetables (19) and have been shown to have immune regulation, antitumor, hypoglycemic, hypolipidemic, and antioxidant

activities. Since they are food polysaccharides, they are a less toxic and effective therapeutic option (20). Studies have shown that PPs from *Rauvolfia verticillata* have therapeutic effects against UC (7-10). Intestinal mucosal immunity plays an important role in the pathogenesis of intestinal inflammation. Many components of mucosal immune system are strongly related to the development of UC, including lymphoid cells, innate immune response, as well as adaptive immune response (21). Also complete colon mucosal works as barriers of protection and intestinal immune system (22).

In our study, we found that the colon epithelium of mice in the DSS + PP group showed varying degrees of repair and significantly reduced inflammatory cell infiltration, which demonstrated the therapeutic effects of PPs in preventing damage to mucosal immunity. In addition, the DAI score and general physical activity in mice with colitis could be partially relieved with PP treatment.

Pyroptosis, also known as inflammatory necrosis, is programmed cell death that is accompanied by the progression of inflammation (23). It is regulated by two main pathways, namely, the classical pyroptosis pathway induced by caspase-1 and the non-classical pyroptosis pathway induced by caspase-11 (24). Inflammasome activation and the induction of pyroptosis occur via a two-step mechanism. In the initiation step, pre-transcriptional pro-inflammatory mediators such as IL-1 β , inflammasome NLPR3 (NLR pyrin domain containing 3, NLR receptor domain 3), and caspase-11 are secreted. In the activation step, the inflammasomes are assembled, and caspase-1 is activated. Active caspase-1 proteolysis breaks down IL-1 β and IL-18 into active forms and induces partial pyroptosis by cleaving gasdermin D (25). Activated NLPR3 enhances the cleavage of the caspase-1 precursor into active caspase-1, which in turn initiates pyroptosis (26). Pyroptosis eliminates inflammatory cells and prevents cells from further damage (27). Caspase-11 is an essential protein for pyroptosis that is expressed in the colonic mucosa and prevents DSS-induced UC (28).

This current study demonstrated that the expression of caspase-1 and IL-1 β in DSS mice was significantly higher compared to control mice, suggesting that DSS effectively induced pyroptosis in the intestines of the mice. After PP treatment, caspase-1 and IL-1 β levels were significantly lower compared to the DSS group, suggesting that pyroptosis is involved in the occurrence and development of UC and that PPs exerted a therapeutic effect. Therefore, alternative therapeutic options such as PPs may inhibit colorectal cell pyroptosis, thereby inhibiting the progression of colitis. In the present study, the relationship between pyroptosis and the pathophysiology of UC was examined. The results showing caspase 1 and IL-1 β expression indicated that pyroptosis was indeed involved in the mechanism of PPs. Future studies should verify these results by examining the changes in other inflammatory factors.

These experimental data demonstrated that pyroptosis plays

an important role in the progression of UC. Moreover, PPs were found to inhibit pyroptosis by suppressing the expression of caspase-1 and IL-1 β in mice. Therefore, PPs may be an effective alternative medicine for the treatment of UC.

Acknowledgments

Funding: This work was supported by the Education Department of Hainan Province (Hnky2021ZD-13), the Postgraduates Project with Innovation in Practice in Hainan Province (Hys2020-373), and the Hainan Provincial Natural Science Foundation of China (821MS126).

Footnote

Reporting Checklist: The authors have completed the ARRIVE reporting checklist. Available at <https://atm.amegroups.com/article/view/10.21037/atm-22-877/rc>

Data Sharing Statement: Available at <https://atm.amegroups.com/article/view/10.21037/atm-22-877/dss>

Conflicts of Interest: All authors have completed the ICMJE uniform disclosure form (available at <https://atm.amegroups.com/article/view/10.21037/atm-22-877/coif>). The authors have no conflicts of interest to declare.

Ethical Statement: The authors are accountable for all aspects of the work in ensuring that questions related to the accuracy or integrity of any part of the work are appropriately investigated and resolved. This study was approved by the animal care review committee of the Hainan General Hospital/Hainan Affiliated Hospital of Hainan Medical University under a project license (No. 20210305), in compliance with NRC Guide for the Care and Use of Laboratory Animals (8th edition).

Open Access Statement: This is an Open Access article distributed in accordance with the Creative Commons Attribution-NonCommercial-NoDerivs 4.0 International License (CC BY-NC-ND 4.0), which permits the non-commercial replication and distribution of the article with the strict proviso that no changes or edits are made and the original work is properly cited (including links to both the formal publication through the relevant DOI and the license). See: <https://creativecommons.org/licenses/by-nc-nd/4.0/>.

References

- Glick LR, Cifu AS, Feld L. Ulcerative Colitis in Adults. *JAMA* 2020;324:1205-6.
- Sairenji T, Collins KL, Evans DV. An Update on Inflammatory Bowel Disease. *Prim Care* 2017;44:673-92.
- Nakamura T, Nagahori M, Kanai T, et al. Current pharmacologic therapies and emerging alternatives in the treatment of ulcerative colitis. *Digestion* 2008;77 Suppl 1:36-41.
- Moreau J, Mas E. Drug resistance in inflammatory bowel diseases. *Curr Opin Pharmacol* 2015;25:56-61.
- Cao F, Liu J, Sha BX, et al. Natural Products: Experimental Efficient Agents for Inflammatory Bowel Disease Therapy. *Curr Pharm Des* 2019;25:4893-913.
- Li C, Wu G, Zhao H, et al. Natural-Derived Polysaccharides From Plants, Mushrooms, and Seaweeds for the Treatment of Inflammatory Bowel Disease. *Front Pharmacol* 2021;12:651813.
- Lin M, Yang BQ, Yu DQ. Studies on the quaternary alkaloids of *Rauwolfia verticillata* (Lour.) Baill var. *hainanensis* Tsiang. *Yao Xue Xue Bao* 1986;21:114-8.
- Popov SV, Vinter VG, Patova OA, et al. Chemical characterization and anti-inflammatory effect of rauwolfian, a pectic polysaccharide of *Rauwolfia callus*. *Biochemistry (Mosc)* 2007;72:778-84.
- Miao XP, Sun XN, Cui LJ, et al. Suppressive effect of pectic polysaccharides extracted from *Rauwolfia verticillata* (Lour.) Baill.var.*hainanensis* Tsiang on inflammation by regulation of NF- κ B pathway and interleukin-17 in mice with dextran sulphatesodium-induced ulcerative colitis. *Asian Pac J Trop Med* 2015;8:147-52.
- Miao XP, Sun XN, Li QS, et al. Pectic polysaccharides extracted from *Rauwolfia verticillata* (Lour.) Baill. var. *hainanensis* Tsiang ameliorate ulcerative colitis via regulating the MAPKs and NF- κ B pathways in dendritic cells. *Clin Exp Pharmacol Physiol* 2019;46:48-55.
- Bergsbaken T, Fink SL, Cookson BT. Pyroptosis: host cell death and inflammation. *Nat Rev Microbiol* 2009;7:99-109.
- Yuan YY, Xie KX, Wang SL, et al. Inflammatory caspase-related pyroptosis: mechanism, regulation and therapeutic potential for inflammatory bowel disease. *Gastroenterol Rep (Oxf)* 2018;6:167-76.
- Xiong Y, Lou Y, Su H, et al. Cholecalciferol cholesterol emulsion ameliorates experimental colitis via down-regulating the pyroptosis signaling pathway. *Exp Mol Pathol* 2016;100:386-92.
- Chao L, Li Z, Zhou J, et al. Shen-Ling-Bai-Zhu-San Improves Dextran Sodium Sulfate-Induced Colitis by Inhibiting Caspase-1/Caspase-11-Mediated Pyroptosis. *Front Pharmacol* 2020;11:814.
- Murano M, Maemura K, Hirata I, et al. Therapeutic effect of intracolonicly administered nuclear factor kappa B (p65) antisense oligonucleotide on mouse dextran sulphate sodium (DSS)-induced colitis. *Clin Exp Immunol* 2000;120:51-8.
- Scarpa M, Castagliuolo I, Castoro C, et al. Inflammatory colonic carcinogenesis: a review on pathogenesis and immunosurveillance mechanisms in ulcerative colitis. *World J Gastroenterol* 2014;20:6774-85.
- Bressler B, Marshall JK, Bernstein CN, et al. Clinical practice guidelines for the medical management of nonhospitalized ulcerative colitis: the Toronto consensus. *Gastroenterology* 2015;148:1035-1058.e3.
- Berends SE, Strik AS, Löwenberg M, et al. Clinical Pharmacokinetic and Pharmacodynamic Considerations in the Treatment of Ulcerative Colitis. *Clin Pharmacokinet* 2019;58:15-37.
- Maxwell EG, Belshaw NJ, Waldron KW, et al. Pectin – An emerging new bioactive food polysaccharide. *Trends in Food Science & Technology* 2012;24:64-73.
- Christiaens S, Van Buggenhout S, Houben K, et al. Process-Structure-Function Relations of Pectin in Food. *Crit Rev Food Sci Nutr* 2016;56:1021-42.
- Abreu MT. Updates in mucosal immunology for inflammatory bowel diseases. *Curr Opin Gastroenterol* 2018;34:375-6.
- Vancamelbeke M, Vermeire S. The intestinal barrier: a fundamental role in health and disease. *Expert Rev Gastroenterol Hepatol* 2017;11:821-34.
- Kolb JP, Oguin TH 3rd, Oberst A, et al. Programmed Cell Death and Inflammation: Winter Is Coming. *Trends Immunol* 2017;38:705-18.
- Huang X, Feng Y, Xiong G, et al. Caspase-11, a specific sensor for intracellular lipopolysaccharide recognition, mediates the non-canonical inflammatory pathway of pyroptosis. *Cell Biosci* 2019;9:31.
- Vande Walle L, Lamkanfi M. Pyroptosis. *Curr Biol* 2016;26:R568-72.
- Strowig T, Henao-Mejia J, Elinav E, et al. Inflammasomes in health and disease. *Nature* 2012;481:278-86.
- Abe J, Morrell C. Pyroptosis as a Regulated Form of

- Necrosis: PI+/Annexin V-/High Caspase 1/Low Caspase 9 Activity in Cells = Pyroptosis? *Circ Res* 2016;118:1457-60.
28. Demon D, Kuchmiy A, Fossoul A, et al. Caspase-11 is expressed in the colonic mucosa and protects against

dextran sodium sulfate-induced colitis. *Mucosal Immunol* 2014;7:1480-91.

(English Language Editor: J. Teoh)

Cite this article as: Cui LJ, Yuan W, Chen FY, Wang YX, Li QM, Lin C, Miao XP. Pectic polysaccharides ameliorate the pathology of ulcerative colitis in mice by reducing pyroptosis. *Ann Transl Med* 2022;10(6):347. doi: 10.21037/atm-22-877