



# Commissural and coronary alignment of the Venus-A valve after transcatheter aortic valve replacement: a retrospective cross-sectional study

Siyu Xi<sup>1</sup>, Haishan Zhang<sup>1</sup>, Yuan Gao<sup>1</sup>, Xin Chen<sup>2</sup>, Wenfei Tan<sup>3</sup>, Liang Guo<sup>1</sup>, Yingxian Sun<sup>1</sup>

<sup>1</sup>Department of Cardiology, The First Hospital of China Medical University, Shenyang, China; <sup>2</sup>Department of Cardiovascular Ultrasound, The First Hospital of China Medical University, Shenyang, China; <sup>3</sup>Department of Anesthesiology, The First Hospital of China Medical University, Shenyang, China

**Contributions:** (I) Conception and design: L Guo; (II) Administrative support: L Guo; (III) Provision of study materials or patients: L Guo; (IV) Collection and assembly of data: S Xi, H Zhang, X Chen, W Tan; (V) Data analysis and interpretation: All authors; (VI) Manuscript writing: All authors; (VII) Final approval of manuscript: All authors.

**Correspondence to:** Liang Guo, MD, PhD. Department of Cardiology, The First Hospital of China Medical University, 155 Nanjing North Street, Heping District, Shenyang 110001, China. Email: lguo@cmu.edu.cn.

**Background:** Previous studies have shown that neo-commissural orientation of transcatheter heart valve (THV) can influence coronary obstruction during transcatheter aortic valve replacement (TAVR), long-term durability of THV, and coronary artery access for reintervention after TAVR. Specific initial orientations of Evolut R/Pro and Acurate Neo aortic valves can improve commissural alignment. However, the method of achieving commissural alignment with the Venus-A valve remains unknown. Therefore, this study aimed to evaluate the extent of commissural and coronary alignment of the Venus-A self-expanding valve after TAVR using a standard system delivery technique.

**Methods:** A retrospective cross-sectional study was performed. At the time of enrollment, patients who underwent pre- and post-procedural electrocardiographically-gated contrast-enhanced CT with a second-generation 64-row multidetector scanner were selected for the study. Commissural alignment was categorized as aligned (0–15° angle deviation), mild (15–30°), moderate (30–45°), or severe (45–60°) commissural misalignment (CMA). Coronary alignment was categorized as having no coronary overlap (CO) (>35°), moderate CO (20–35°), or severe CO (≤20°). The results were represented as proportions to assess the extent of commissural and coronary alignment.

**Results:** Forty-five TAVR patients were ultimately included in the analysis. THVs were shown to be randomly implanted: 20.0% of THVs were aligned, 33.3% had mild CMA, 26.7% had moderate CMA, and 20.0% had severe CMA. The incidence of severe CO was 24.4% with the left main coronary artery, 28.9% with the right coronary artery, 6.7% with both coronary arteries, and 46.7% with one or both coronary arteries.

**Conclusions:** The results showed that commissural or coronary alignment could not be achieved with the Venus-A valve using a standard system delivery technique. Therefore, specific methods to attain alignment with the Venus-A valve need to be identified.

**Keywords:** Commissural alignment; coronary alignment; transcatheter aortic valve replacement (TAVR); Venus-A self-expanding valve

Submitted Nov 10, 2022. Accepted for publication Apr 17, 2023. Published online May 10, 2023.

doi: 10.21037/cdt-22-565

**View this article at:** <https://dx.doi.org/10.21037/cdt-22-565>

## Introduction

Transcatheter aortic valve replacement (TAVR) is a recognized minimally invasive technique for patients with severe aortic stenosis (AS). As TAVR technology matured over the course of the past decade, the indications for TAVR have been further expanded compared to the surgical aortic valve replacement (SAVR) (1,2). TAVR has been gradually performed in younger patients, which means increased lifetime expectancy and more prevalent coronary artery diseases after TAVR. Unlike SAVR, where the surgical valve commissures can be completely aligned with native valve commissures, commissural alignment during TAVR is not easily achieved, as transcatheter heart valve (THV) are always randomly implanted (3). Previous studies have shown that neo-commissural orientation of THV influences coronary obstruction during TAVR, long-term durability of THV, and coronary artery access for reintervention after TAVR (3-5). In addition, commissural alignment also increases the feasibility of bioprosthetic or native aortic scallop intentional laceration to prevent iatrogenic coronary artery obstruction in cases when TAVR was utilized in a failed THV. In recent years, Tang *et al.* have found that specific initial orientations of Evolut R/Pro and Acurate Neo aortic valves improve commissural alignment (6-8). Both valves, like the Venus-A (Venus MedTech, Inc., Hangzhou, China), are self-expanding valves. For Evolut R/Pro aortic valves, commissural alignment was achieved

by inserting the delivery catheter with the flush port facing the 3 o'clock position, while for Acurate Neo valves, facing the 12 o'clock position. However, the method of achieving commissural alignment with the Venus-A self-expanding valve remains unknown.

The Venus-A self-expanding valve was shown in *Figure 1A*. There are three fluoroscopic markers in the middle of each cusp. During the procedure, the delivery system was inserted with the flush port located at 9 o'clock orientation (facing the operator) as recommended by the manufacturer (*Figure 1B*). In the right coronary cusp (RCC) and the left coronary cusp (LCC) overlap view, the noncoronary cusp (NCC) is isolated on the left side of the fluoroscopic screen, and simultaneously the RCC and the LCC are located on the right side. Therefore, if there are two markers overlapping on the right side and one marker on the left as the *Figure 1C*, we can find that commissural alignment is obtained through the pre- and post-TAVR computed tomography (CT) scans (*Figure 1D,1E*). On the contrary, if there are two markers overlapping on the left side and one marker on the right as the *Figure 1F*, commissural misalignment (CMA) will be obtained (*Figure 1G,1H*). The present study aimed to evaluate the extent of commissural and coronary alignment of the Venus-A self-expanding valve after TAVR using a standard system delivery technique. We present the following article in accordance with the STROCSS reporting checklist (available at <https://cdt.amegroups.com/article/view/10.21037/cdt-22-565/rc>).

### Highlight box

#### Key findings

- The Venus-A valves were randomly implanted and commissural or coronary alignment were not achieved using a standard system delivery technique.

#### What is known and what is new?

- Neo-commissural orientation of transcatheter heart valve (THV) can influence coronary obstruction during transcatheter aortic valve replacement (TAVR), long-term durability of THV, and coronary artery access for reintervention after TAVR.
- Specific initial orientations of Evolut R/Pro and Acurate Neo aortic valves can improve commissural alignment.
- The extent of commissural and coronary alignment of the Venus-A self-expanding valve after TAVR using a standard system delivery technique.

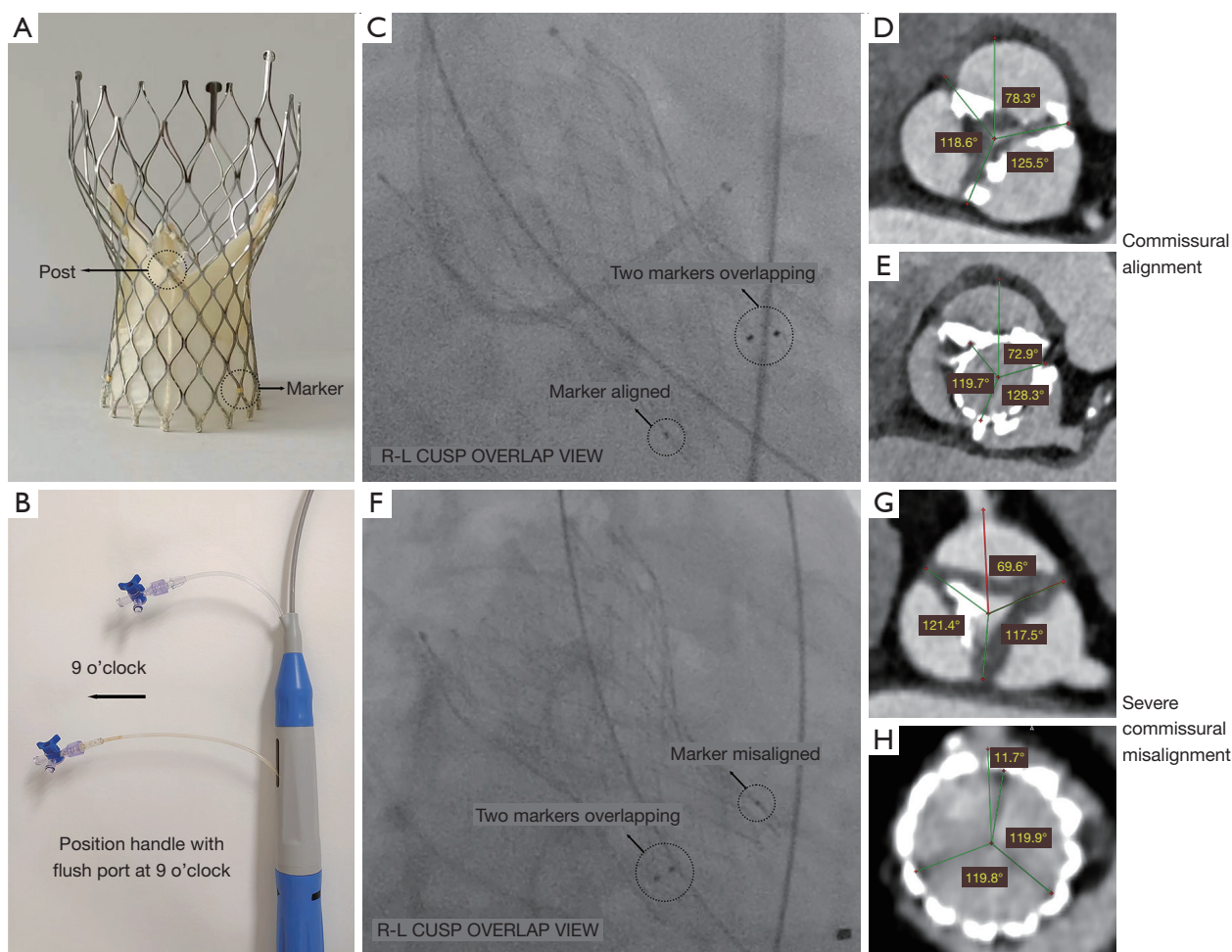
#### What is the implication, and what should change now?

- Specific methods to attain alignment with the Venus-A valve need to be identified.

## Methods

### Study population

This is a single-center retrospective cross-sectional study. 69 patients recruited all at once who underwent TAVR with the Venus-A self-expanding valve for severe AS between July 2018 and August 2022 in the First Hospital of China Medical University. The exclusion criteria were as follows: (I) patients missing clinical information; (II) patients missing pre- or post-procedural CT; (III) patients with the poor visualization of coronary ostia and commissures. Pre- and post-procedural multidetector CT results were ultimately analyzed for 45 patients that the mean age was  $71.1 \pm 8.6$  years. A flowchart of the study design and timelines is presented in *Figure S1*. The extent of commissural and coronary alignment was measured. But the extent of commissural alignment cannot be measured in type 0 bicuspid aortic valves (BAVs). In addition, among



**Figure 1** Definition of commissural alignment. (A) The fluoroscopic markers and commissural posts of the Venus-A valve. (B) The delivery system was inserted with the flush port located at 9 o'clock orientation. (C) The commissural alignment in the fluoroscope. (D) The pre-TAVR CT scan of commissural alignment. (E) The post-TAVR CT scan of commissural alignment. (F) The CMA in the fluoroscope. (G) The pre-TAVR CT scan of CMA. (H) The post-TAVR CT scan of CMA. TAVR, transcatheter aortic valve replacement; CT, computed tomography; CMA, commissural misalignment.

45 patients, aortic valve-in-valve (VIV) procedures were performed in 5 patients. We only analyzed commissural and coronary alignment of the final implanted Venus-A valves. During the procedure, the delivery system was inserted with the flush port located at 9 o'clock orientation (facing the operator) as recommended by the manufacturer (Figure 1B).

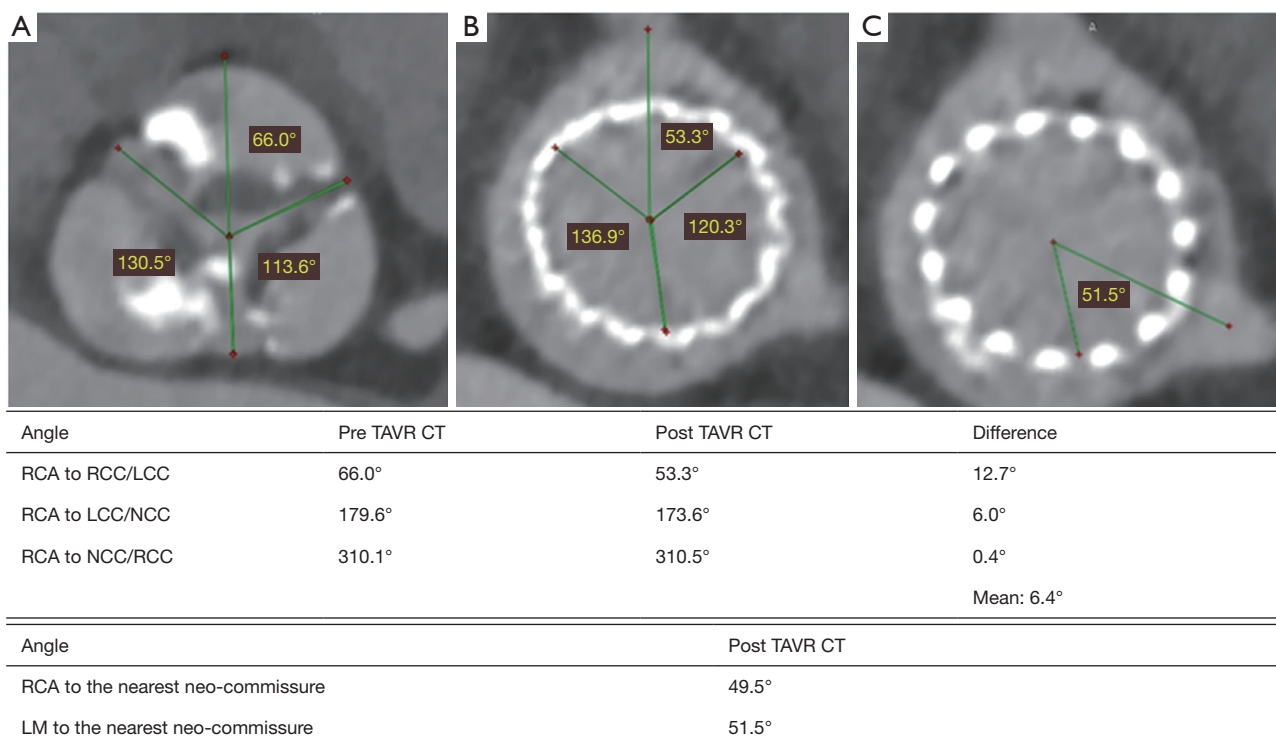
#### CT image acquisition and analysis

All patients underwent pre- and post-procedural electrocardiographically-gated contrast-enhanced CT with a second-generation 64-row multidetector scanner (Somatom Definition; Siemens Healthcare, Forchheim,

Germany). The commissural orientation of the native aortic valve, neo-commissural orientation of THV, and coronary ostia orientation were analyzed using RadiAnt DICOM Viewer software (Version 5.5; Medixant, Poland).

#### Definition of commissural alignment

To maintain consistency within the same patient and the entire cohort, the right coronary artery (RCA) was set at 12 o'clock in the image of the cross-section perpendicular to the axis of the aorta. A vertical line was drawn through RCA and the center of the aorta. Then, three angles from the RCA to the RCC/LCC commissure, from the RCA



**Figure 2** Three figures for patient with TAV or type 1 BAV. (A) The angles between RCA and each commissure were calculated. (B) The angles between RCA and each neo-commissure were calculated. (C) The angle between LM and the nearest neo-commissure. TAV, tricuspid aortic valve; BAV, bicuspid aortic valve; RCA, right coronary artery; LCC, left coronary cusp; NCC, non-coronary cusp; RCC, right coronary cusp; LM, left main.

to the LCC/ NCC commissure, and from the RCA to the NCC/RCC commissure were measured. For each of these three angles, an angle deviation between the pre- and post-TAVR scans was calculated. The mean of the three angle deviations was calculated to evaluate commissural alignment (3). Finally, commissural alignment between bioprosthetic and native aortic valve was categorized as aligned (0–15° angle deviation), mild (15–30°), moderate (30–45°), or severe (45–60°) CMA (Figure 2A,2B).

### Definition of coronary alignment

Neo-commissural orientation of THV and coronary ostia orientation were measured in the post-procedural CT scan. Two lines were drawn through the coronary ostium and the center of the aorta. Then, two angles from the coronary ostium to the nearest neo-commissure were measured to evaluate coronary alignment. Finally, coronary alignment was categorized as having no coronary overlap (CO) (>35°), moderate CO (20–35°), or severe CO (≤20°) (Figure 2B,2C,

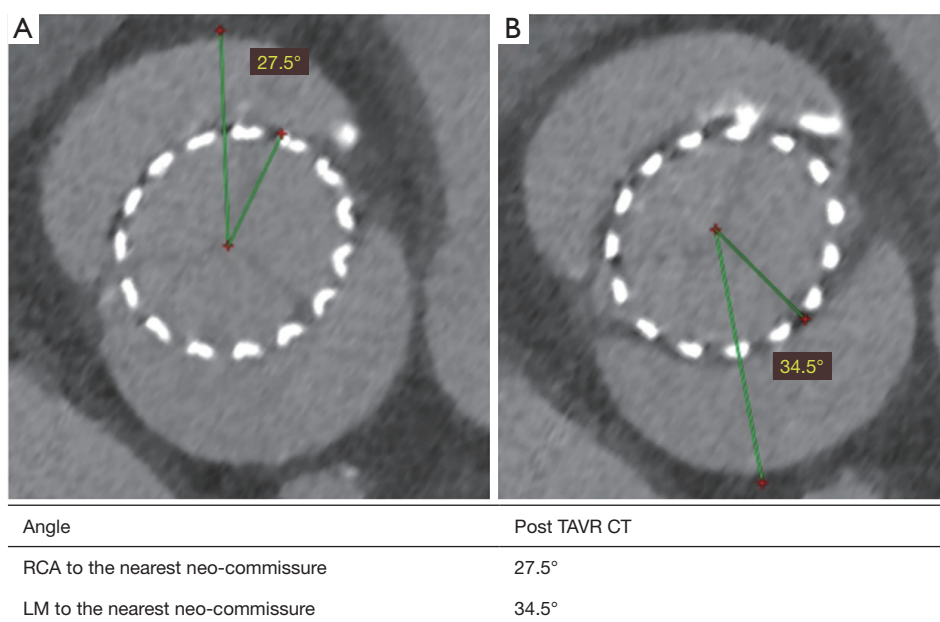
Figure 3).

### Statistical analysis

Continuous variables were represented as mean ± standard deviation or medians (interquartile ranges) for those with normal or skewed distributions, respectively. Categorical variables were represented as proportions. All analyses were performed with the SPSS 26.0 software (IBM, Armonk, NY, USA).

### Ethical statement

Study approval was obtained from the institutional review board of The First Hospital of China Medical University (No. 2022QL103) and the study conformed to the ethical guidelines of the Declaration of Helsinki (as revised in 2013) on the principles for medical research involving human subjects. All subjects gave written informed consent to participate in the study.



**Figure 3** Two figures for patient with type 0 BAV. (A) The angle between RCA and the nearest neo-commissure. (B) The angle between LM and the nearest neo-commissure. BAV, bicuspid aortic valve; RCA, right coronary artery; LM, left main.

## Results

### Baseline characteristics

Patient characteristics are listed in *Table 1*. Briefly, the mean age was  $71.1 \pm 8.6$  years and 35.6% of patients were female. Most patients (57.8%) were in the New York Heart Association (NYHA) class III or IV at admission, with a median Society of Thoracic Surgeons (STS) score of 3.0 (IQR: 1.8–5.5). The median deviation of left ventricular ejection fraction (LVEF) was 49.0% (IQR: 34.0–60.0%), with a mean gradient of  $60.0 \pm 19.8$  mmHg, and 12 patients (26.7%) had at least moderate aortic regurgitation. In addition, there were 12 (26.7%) patients with tricuspid aortic valves (TAVs), 15 (33.3%) with type 0 BAVs, and 18 (40.0%) with type 1 BAVs.

### Commissural alignment

Based on the pre- and post-procedural CT analysis among 30 patients (12 with TAVs and 18 with type 1 BAVs), it was shown that six THVs (20.0%) were implanted aligned with the native aortic valve commissures, ten THVs (33.3%) were implanted with mild CMA, eight THVs (26.7%) with moderate CMA, and six THVs (20.0%) with severe CMA. Separately, for the 12 cases with TAVs, it was shown that two THV (16.7%) was implanted aligned with the

native aortic valve commissures, four THVs (33.3%) were implanted with mild CMA, three THVs (25.0%) with moderate CMA, and three THVs (25.0%) with severe CMA. For the 18 cases with type 1 BAVs, it was shown that four THVs (22.2%) were implanted aligned with the native aortic valve commissures, six THVs (33.3%) were implanted with mild CMA, five THVs (27.8%) with moderate CMA, and three THVs (16.7%) with severe CMA (*Table 2, Figure 4*).

### Coronary alignment

Post-TAVR CT results for all 45 patients showed that for the left main (LM), 11 THVs (24.4%) were implanted with severe CO, 19 THVs (42.2%) with moderate CO, and 15 THVs (33.3%) with no CO. For the RCA, 13 THVs (28.9%) were implanted with severe CO, 14 THVs (31.1%) with moderate CO, and 18 THVs (40.0%) with no CO. The overall incidence of severe CO was as follows: 11 with LM (24.4%), 13 with RCA (28.9%), three with both coronary arteries (6.7%), and 21 with one or both coronary arteries (46.7%). Separately, it was shown that for the LM among the 12 patients with TAVs, five THVs (41.7%) were implanted with severe CO, four THVs (33.3%) with moderate CO, and three THVs (25.0%) with no CO. For the RCA, three THVs (25.0%) were implanted with severe

**Table 1** Baseline characteristics

Variables	Values (total n=45)
Age, years	71.1±8.6
Female sex	16 (35.6)
BMI, kg/m <sup>2</sup>	23.0±3.2
Atrial fibrillation	11 (24.4)
Hypertension	19 (42.2)
Diabetes	10 (22.2)
Chronic kidney disease	15 (33.3)
COPD	15 (33.3)
Prior PCI	4 (8.9)
Prior CABG	0 (0.0)
Prior stroke	6 (13.3)
Prior permanent pace-maker	0 (0.0)
STS score (%)	3.0 (1.8–5.5)
NYHA (class III–IV)	26 (57.8)
LVEF (%)	49.0 (34.0–60.0)
Mean gradient, mmHg	60.0±19.8
AR ≥ moderate	12 (26.7)
TAV	12 (26.7)
Type 0 BAV	15 (33.3)
Type 1 BAV	18 (40.0)

Values are mean ± SD, n (%), or median (range). BMI, body mass index; COPD, chronic obstructive pulmonary disease; PCI, percutaneous coronary interventions; CABG, coronary artery bypass graft; STS, Society of Thoracic Surgeons; NYHA, New York Heart Association; LVEF, left ventricle ejection fraction; AR, aortic regurgitation; BAV, bicuspid aortic valve; TAV, tricuspid aortic valve.

CO, four THVs (33.3%) with moderate CO, and five THVs (41.7%) with no CO. Among the 18 patients with type 1 BAVs, it was shown that for the LM, four THVs (22.2%) were implanted with severe CO, six THVs (33.3%) with moderate CO, and eight THVs (44.4%) with no CO. For the RCA, seven THVs (38.9%) were implanted with severe CO, five THVs (27.8%) with moderate CO, and six THVs (33.3%) with no CO. Among the 15 patients with type 0 BAVs, it was shown that for the LM, two THVs (13.3%) were implanted with severe CO, nine THVs (60.0%) with moderate CO, and four THVs (26.7%) with no CO. For the RCA, three THVs (20.0%) were implanted with severe CO, five THVs (33.3%) with moderate CO, and seven THVs (46.7%) with no CO (Table 3, Figure 5).

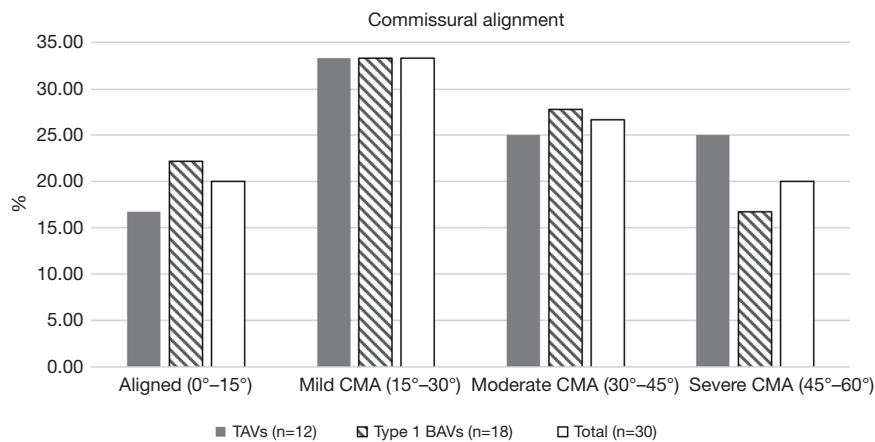
## Discussion

As TAVR is gradually being performed in younger patients, the feasibility of coronary artery access and long-term durability of THVs become more and more important. For one thing, due to randomly implanted THVs, the neo-commissural posts may block the coronary ostia. This issue may be more important in THVs with supra-annular stent frames because the coronary catheter will need to go through the stent frame to engage the coronary artery (4). For another, due to the uneven calcification of the annulus and leaflets in AS patients, there is a heterogeneity in the extrusion degree of the native commissures and leaflets to the stent frame. This means that the extent of commissural alignment may cause uneven extrusion to the stent frame, affecting the function and long-term durability of THVs. Other research has reported that there is a significantly higher rate of mild central aortic regurgitation if moderate

**Table 2** Commissural alignment of the Venus-A self-expanding valve after TAVR using a standard system delivery technique

Variables	TAVs (n=12)	Type 1 BAVs (n=18)	Total (n=30)
Aligned (0°–15°)	2 (16.7)	4 (22.2)	6 (20.0)
Mild CMA (15°–30°)	4 (33.3)	6 (33.3)	10 (33.3)
Moderate CMA (30°–45°)	3 (25.0)	5 (27.8)	8 (26.7)
Severe CMA (45°–60°)	3 (25.0)	3 (16.7)	6 (20.0)

Values are n (%). TAVR, transcatheter aortic valve replacement; CMA, commissural misalignment; BAV, bicuspid aortic valve; TAV, tricuspid aortic valve.



**Figure 4** A histogram of commissural alignment with the Venus-A self-expanding valve after TAVR using a standard system delivery technique. CMA, commissural misalignment; TAV, tricuspid aortic valve; BAV, bicuspid aortic valve; TAVR, transcatheter aortic valve replacement.

**Table 3** Coronary alignment of the Venus-A self-expanding valve after TAVR using a standard system delivery technique

Variables	TAVs (n=12)	Type 1 BAVs (n=18)	Type 0 BAVs (n=15)	Total (n=45)
Both severe CO	1 (8.3)	1 (5.6)	1 (6.7)	3 (6.7)
1 or both coronaries severe CO	7 (58.3)	10 (55.6)	4 (26.7)	21 (46.7)
LM				
Severe CO	5 (41.7)	4 (22.2)	2 (13.3)	11 (24.4)
Moderate CO	4 (33.3)	6 (33.3)	9 (60.0)	19 (42.2)
No CO	3 (25.0)	8 (44.4)	4 (26.7)	15 (33.3)
RCA				
Severe CO	3 (25.0)	7 (38.9)	3 (20.0)	13 (28.9)
Moderate CO	4 (33.3)	5 (27.8)	5 (33.3)	14 (31.1)
No CO	5 (41.7)	6 (33.3)	7 (46.7)	18 (40.0)

Values are n (%). TAVR, transcatheter aortic valve replacement; CO, coronary overlap; LM, left main; RCA, right coronary artery; BAV, bicuspid aortic valve; TAV, tricuspid aortic valve.

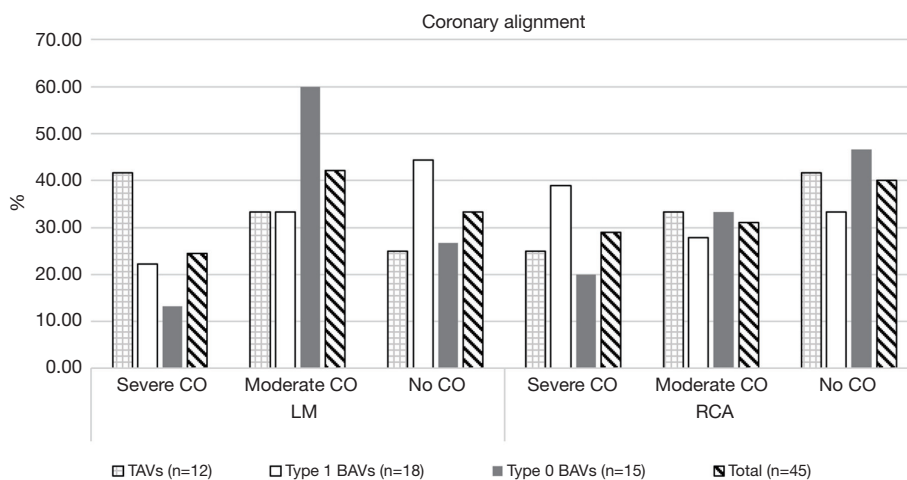
or severe CMA is present (3). Therefore, achieving commissural alignment between the bioprosthesis and native aortic valves is essential.

Recently, Wang *et al.* have found that despite considering cusp asymmetry and coronary ostial eccentricity, using the right/left cusp overlap view during TAVR for achieving commissural alignment can simultaneously obtain coronary alignment in most TAVs and type 1 BAVs (9). However, another research study has reported that 32 out of 100 patients had moderate to severe CO despite ideal commissural alignment, so the

right/left CO view during TAVR was recommended (10). This method may be more suitable in China because patients with type 0 BAVs are more prevalent than in other countries. Although type 0 BAV anatomy may be more favorable for post-TAVR coronary access than TAV and type 1 BAV anatomy (11), achieving coronary alignment is also very important.

**Study limitations**

This was a single-center retrospective study enrolling



**Figure 5** A histogram of coronary alignment with the Venus-A self-expanding valve after TAVR using a standard system delivery technique. CO, coronary overlap; LM, left main; RCA, right coronary artery; TAV, tricuspid aortic valve; BAV, bicuspid aortic valve; TAVR, transcatheter aortic valve replacement.

a small number of patients. Larger sample sizes will be needed in future studies.

## Conclusions

The present study results showed that THVs were randomly implanted, and that commissural or coronary alignment could not be achieved with the Venus-A valve using a standard system delivery technique. Therefore, specific methods to attain alignment with the Venus-A valve need to be identified.

## Acknowledgments

We thank International Science Editing (<http://www.internationalscienceediting.com>) and Grammarly for editing this manuscript.

**Funding:** This work was supported by Shenyang Science and Technology Program (grant No. 22-321-33-09).

## Footnote

**Reporting Checklist:** The authors have completed the STROCSS reporting checklist. Available at <https://cdt.amegroups.com/article/view/10.21037/cdt-22-565/rc>

**Data Sharing Statement:** Available at <https://cdt.amegroups.com/article/view/10.21037/cdt-22-565/dss>

[com/article/view/10.21037/cdt-22-565/dss](https://cdt.amegroups.com/article/view/10.21037/cdt-22-565/dss)

**Conflicts of Interest:** All authors have completed the ICMJE uniform disclosure form (available at <https://cdt.amegroups.com/article/view/10.21037/cdt-22-565/coif>). The authors have no conflicts of interest to declare.

**Ethical Statement:** The authors are accountable for all aspects of the work in ensuring that questions related to the accuracy or integrity of any part of the work are appropriately investigated and resolved. Study approval was obtained from the institutional review board of The First Hospital of China Medical University (No. 2022QL103) and the study conformed to the ethical guidelines of the Declaration of Helsinki (as revised in 2013) on the principles for medical research involving human subjects. All subjects gave written informed consent to participate in the study.

**Open Access Statement:** This is an Open Access article distributed in accordance with the Creative Commons Attribution-NonCommercial-NoDerivs 4.0 International License (CC BY-NC-ND 4.0), which permits the non-commercial replication and distribution of the article with the strict proviso that no changes or edits are made and the original work is properly cited (including links to both the formal publication through the relevant DOI and the license).

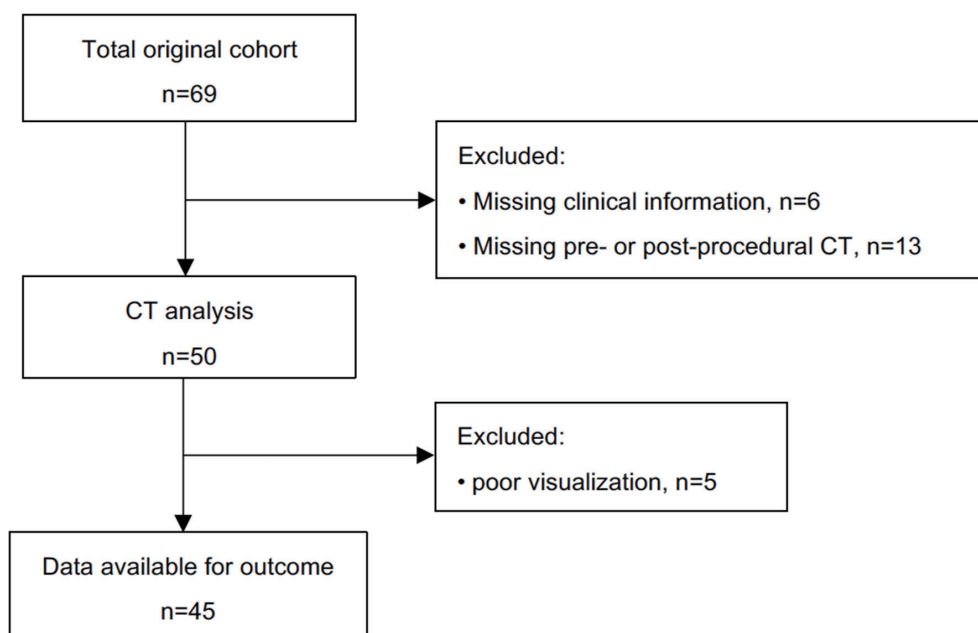


See: <https://creativecommons.org/licenses/by-nc-nd/4.0/>.

## References

1. Vahanian A, Beyersdorf F, Praz F, et al. 2021 ESC/EACTS Guidelines for the management of valvular heart disease. *Eur J Cardiothorac Surg* 2021;60:727-800.
2. Otto CM, Nishimura RA, Bonow RO, et al. 2020 ACC/AHA Guideline for the Management of Patients With Valvular Heart Disease: A Report of the American College of Cardiology/American Heart Association Joint Committee on Clinical Practice Guidelines. *J Am Coll Cardiol* 2021;77:e25-e197.
3. Fuchs A, Kofoed KF, Yoon SH, et al. Commissural Alignment of Bioprosthetic Aortic Valve and Native Aortic Valve Following Surgical and Transcatheter Aortic Valve Replacement and its Impact on Valvular Function and Coronary Filling. *JACC Cardiovasc Interv* 2018;11:1733-43.
4. Ochiai T, Chakravarty T, Yoon SH, et al. Coronary Access After TAVR. *JACC Cardiovasc Interv* 2020;13:693-705.
5. Lederman RJ, Babaliaros VC, Rogers T, et al. Preventing Coronary Obstruction During Transcatheter Aortic Valve Replacement: From Computed Tomography to BASILICA. *JACC Cardiovasc Interv* 2019;12:1197-216.
6. Tang GHL, Zaid S, Gupta E, et al. Impact of Initial Evolut Transcatheter Aortic Valve Replacement Deployment Orientation on Final Valve Orientation and Coronary Reaccess. *Circ Cardiovasc Interv* 2019;12:e008044.
7. Tang GHL, Zaid S, Fuchs A, et al. Alignment of Transcatheter Aortic-Valve Neo-Commissures (ALIGN TAVR): Impact on Final Valve Orientation and Coronary Artery Overlap. *JACC Cardiovasc Interv* 2020;13:1030-42.
8. Tang GHL, Sengupta A, Alexis SL, et al. Conventional versus modified delivery system technique in commissural alignment from the Evolut low-risk CT substudy. *Catheter Cardiovasc Interv* 2022;99:924-31.
9. Wang X, De Backer O, Bieliauskas G, et al. Cusp Symmetry and Coronary Ostial Eccentricity and its Impact on Coronary Access Following TAVR. *JACC Cardiovasc Interv* 2022;15:123-34.
10. Redondo A, Baladrón Zorita C, Tchétché D, et al. Commissural Versus Coronary Optimized Alignment During Transcatheter Aortic Valve Replacement. *JACC Cardiovasc Interv* 2022;15:135-46.
11. Chen F, Jia K, Li Y, et al. Coronary access after transcatheter aortic valve replacement in bicuspid versus tricuspid aortic stenosis. *EuroIntervention* 2022;18:203-12.

**Cite this article as:** Xi S, Zhang H, Gao Y, Chen X, Tan W, Guo L, Sun Y. Commissural and coronary alignment of the Venus-A valve after transcatheter aortic valve replacement: a retrospective cross-sectional study. *Cardiovasc Diagn Ther* 2023;13(3):487-495. doi: 10.21037/cdt-22-565



**Figure S1** A flowchart of the study design and timelines. CT, computed tomography.