



# Adjuvant intraluminal therapies for upper tract urothelial carcinoma

Raymond Khargi<sup>1</sup>, Christopher Connors<sup>1</sup>, Anna Ricapito<sup>1,2</sup>, Alan J. Yaghoubian<sup>1</sup>, Blair E. Gallante<sup>1</sup>, Johnathan A. Khusid<sup>1</sup>, William M. Atallah<sup>1</sup>, Mantu Gupta<sup>1</sup>

<sup>1</sup>Department of Urology, Icahn School of Medicine at Mount Sinai, New York, NY, USA; <sup>2</sup>Department of Urology and Renal Transplantation, University of Foggia, Foggia, Italy

*Contributions:* (I) Conception and design: All authors; (II) Administrative support: JA Khusid, WM Atallah, M Gupta; (III) Provision of study materials or patients: All authors; (IV) Collection and assembly of data: R Khargi, C Connors, A Ricapito; (V) Data analysis and interpretation: R Khargi, C Connors, A Ricapito, AJ Yaghoubian; (VI) Manuscript writing: All authors; (VII) Final approval of manuscript: All authors.

*Correspondence to:* Raymond Khargi, MD. Icahn School of Medicine at Mount Sinai, Department of Urology, 1 Gustave L. Levy Place, New York, NY 10029, USA. Email: raymond.khargi@gmail.com.

**Abstract:** Upper urinary tract urothelial carcinomas (UTUCs) are often identified and first treated endoscopically. After proper risk stratification, adjuvant treatment may be recommended. Consequently, as adjuvant therapy becomes more common place in the oncological armamentarium, we seek to better characterize its existing and future therapeutic landscape. In this article, we present an overview of the most up-to-date information about intracavitary instillations as an adjuvant therapy in the context of UTUC. We reviewed the current literature on the epidemiology, disease characteristics, treatment, and outcomes of UTUC with a particularly focus on intraluminal adjuvant therapy for UTUC. This review provides a comprehensive overview of the most recent available data regarding adjuvant therapies used for UTUC. Intraluminal therapy plays an increasingly important role in the management of UTUC. Mitomycin C is the most common adjuvant treatment for UTUC with bacillus Calmette-Guerin (BCG) being utilized to a lesser extent. UGN-101 is a novel topical gel-based therapy that has shown promising results and thus recently garnered Food and Drug Administration (FDA) approval for UTUC. Other treatments such as BCG-IFN, gemcitabine, docetaxel, and drug-eluting stents (DES) may play a future role in UTUC treatment given further research. It is important to caveat that current studies on topical adjuvant treatments demonstrate varying degrees of effectiveness. This is largely due to limited research on UTUC, consisting of small sample sizes, and mostly retrospective experiences. Accordingly, further clinical trials are needed to evaluate the true benefit of these treatments.

**Keywords:** Upper tract urothelial carcinoma; adjuvant therapy; kidney-sparing surgery; intracavitary treatment

Submitted Jan 13, 2023. Accepted for publication Jul 31, 2023. Published online Aug 14, 2023.

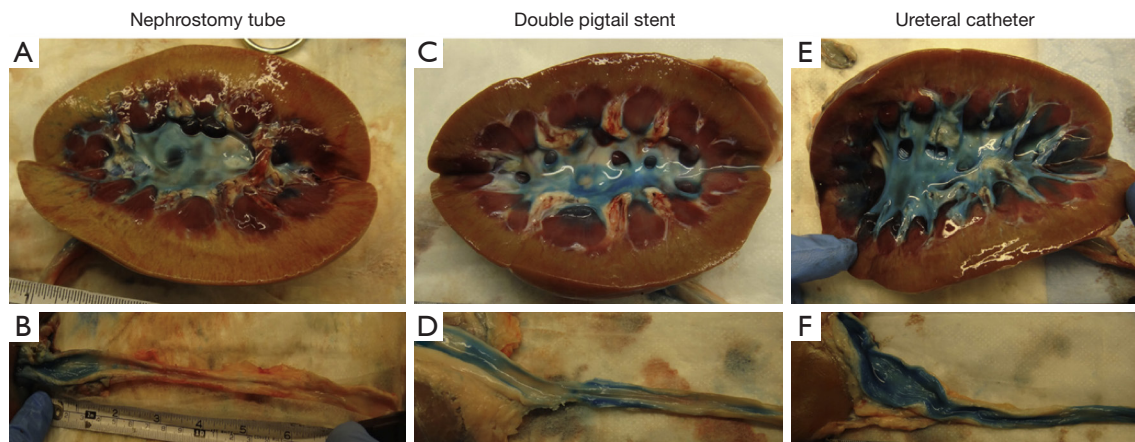
doi: 10.21037/tau-23-35

**View this article at:** <https://dx.doi.org/10.21037/tau-23-35>

## Introduction

Upper urinary tract urothelial carcinomas (UTUCs) are a relatively uncommon urologic malignancy that can arise anywhere between the renal collecting system and the ureterovesical junction. They account for 5% to 10% of all urothelial carcinomas and are more common among older patients, with a peak incidence between 70 and 90 years of age and a mean age at diagnosis of 73 (1,2). In Western nations, the yearly incidence of UTUC is believed to be between 1–2 cases per 100,000 inhabitants; nevertheless,

the incidence rate has grown in recent years due to the advancement of diagnostic techniques and prolonged bladder cancer survival (2-4). Unlike bladder urothelial carcinomas, UTUC is often discovered at a later stage and has a poorer prognosis (5). Indeed, up to two-thirds of UTUC patients present with invasive disease, and approximately 9% have metastases at the time of diagnosis (6). In addition, about 95% of patients manifest with unilateral UTUC, whereas 10% to 20% have multifocal tumors (1). Depending on tumor stage, the 5-year cancer-specific survival (CSS) of UTUC ranges from 10% to 70% (4,7,8).



**Figure 1** Representative images of stained urothelium after: (A,B) nephrostomy tube dye delivery; (C,D) dye delivery through double-pigtail stent; (E,F) ureteral catheter dye delivery. This figure was published in ref. (19), Copyright Elsevier 2013—permission granted for reuse.

In the past, low-grade UTUCs were routinely treated in the same manner as high-grade UTUCs, for which radical nephroureterectomy with bladder cuff excision is currently the gold standard (9). Recent advancements in ureteroscopic and laser technology, however, have made endoscopic kidney-sparing surgery (KSS) a feasible therapeutic option for low-risk UTUC and carefully chosen individuals with high-risk disease, such as those with severe renal insufficiency and solitary kidney (10,11). The European Association of Urology (EAU) guidelines characterize low-risk UTUC as unifocal, small tumor size (<2 cm), low-grade by cytology and ureteroscopic biopsy, and without evidence of invasion on computed tomography (10). Intraluminal chemotherapy and immunotherapy instillations within the upper tract have become an increasing area of investigation as an adjuvant treatment for endoscopically-managed UTUC patients (1). Numerous therapeutic agents utilized as intravesical instillations for the treatment of bladder cancer have been studied for the upper urinary tract with variable degrees of efficacy on patient outcomes. Consequently, as adjuvant therapy becomes more common place in the oncological armamentarium, we seek to better characterize its existing and future therapeutic landscape. In this review, we provide a summary of the most recent information about intracavitary instillations as an adjuvant therapeutic in the UTUC setting.

### Modality

The technique of intracavitary instillation is a crucial factor to consider when deciding on a therapy. The current

medical literature specifies three primary methods for intracavitary treatments for UTUC. The first method utilizes an antegrade approach in which the medication is delivered via a percutaneous nephrostomy tube (12-14). The second method utilizes an open-ended ureteric catheter to instill the medication over a period of time in a retrograde fashion (15,16). The final method involves retrograde administration along with the placement of a ureteral stent (either double J or single J stent) that allows for medication to be delivered by means of vesicoureteral reflux (17).

In terms of effectiveness, the current preference for a retrograde technique has mostly been supported by porcine model experiments. The anatomical complexity of the ureter and renal collecting system poses the greatest challenge for topical intracavitary instillations (18). In particular, the upper urinary system has limited capacity for storage, and topical medications are continually diluted by the flow of urine (18). For topical administration to be effective, medication concentration and the duration of urothelial tissue exposure are critical. Using an *ex-vivo* porcine model and an indigo carmine dye solution as a surrogate for an intracavitary chemotherapy instillation, Pollard *et al.* evaluated the effectiveness of each of the three mentioned techniques (*Figure 1*) (19). The study concluded that the open-ended catheter retrograde approach may be the most effective as it resulted in the maximum staining of the upper urinary system. Liu *et al.* conducted a similar investigation but examined the three delivery techniques using an *in-vivo* pig model. Similarly, the retrograde ureteral catheter method resulted in the largest degree of staining, providing weight to the argument that it may be the most

**Table 1** Summary of select studies investigating adjuvant BCG treatment for low-risk UTUC

Study author	Year	Participants, N	Mean follow-up, months	Upper tract recurrence (%)
Schoenberg <i>et al.</i> (30)	1991	9	24	36
Martínez-Piñeiro <i>et al.</i> (27)	1996	21	31	14
Clark <i>et al.</i> (28)	1999	16	21	31
Rastinehad <i>et al.</i> (29)	2009	50	61	36
Giannarini <i>et al.</i> (24)	2011	18	42	61

BCG, Bacillus Calmette-Guerin; UTUC, upper urinary tract urothelial carcinoma.

effective strategy (20).

The other methods also present certain downsides. For instance, the percutaneous approach has an increased risk of tumor seeding and also carries the possibility of the treatment solution bypassing certain calyces and flowing straight down into the ureter (20). For the ureteral stent approach, the main challenge is that vesicoureteral reflux is not guaranteed. Indeed, a study by Yossepowitch *et al.* demonstrated that only 59% of patients treated via this approach experienced reflux (21). Ultimately, while existing evidence supports this retrograde method, further research is required to discover whether it produces improved clinical outcomes compared to alternative methods.

### Bacillus Calmette-Guerin (BCG)

BCG is one of the most often utilized intracavitary instillations for treating UTUC (3). BCG is a live-attenuated strain of *Mycobacterium bovis* that was first established in 1921 for use as a tuberculosis vaccine, but it subsequently acquired appeal as a treatment for various urologic malignancies (22). In fact, the first documented use of BCG as a treatment for bladder cancer can be dated back to the year 1976 (22). The crux of intraluminal BCG's usefulness for UTUC comes under two broad indications. First, for patients with high-risk UTUC, namely carcinoma in situ (CIS), BCG is commonly utilized as part of the standard therapy paradigm following endoscopic management (23). Second, BCG has also been utilized as an adjuvant treatment following KSS for individuals with low-risk UTUC and is largely considered experimental (1,23). The main focus of this review is to summarize the most recent knowledge on adjuvant BCG therapy. However, a brief overview of BCG's usage as a primary therapy is provided below.

BCG treatment for CIS is generally characterized by a high initial efficacy. When compared to low-risk patients

receiving BCG as an adjuvant treatment, high-risk CIS patients receiving BCG as a primary treatment often demonstrate more favorable progression-free survival and recurrence-free survival (24). However, the long-term effectiveness remains questionable as UTUC recurrence rates and mortality have been shown to be poor in long-term studies that follow patients treated with primary BCG (25).

Several series have investigated the use of adjuvant BCG treatment for low-risk UTUC. Among these studies, the efficacy of BCG as an adjuvant therapy has been highly variable. For example, in 2011, Giannarini *et al.* studied 18 patients treated with adjuvant BCG for an average of 42 months (24). They found local recurrence in 11 (61%) individuals, which is one of the highest recurrence rates reported in the literature. Additionally, a retrospective study of 50 patients by Rastinehad *et al.* demonstrated no statistically significant changes in recurrence rates, advancement of tumor grade, kidney preservation, or overall survival between the BCG-treated and untreated groups (26). On the other hand, studies by other groups present a more optimistic view of adjuvant BCG therapy. In 1996, Martínez-Piñeiro *et al.* found that only 3 (14%) of the 21 patients with low-grade UTUC developed upper tract recurrence, which was considerably lower than those who did not receive adjuvant intracavitary BCG (14% *vs.* 50%,  $P < 0.05$ ) (27). A summary of studies (24,27-30) that investigated adjuvant BCG in UTUC patients can be seen in *Table 1*. Overall, recurrence rates are highly variable, and there remains doubt about the beneficial role of adjuvant BCG for low-risk UTUC.

Intracavitary instillation of BCG typically shows a tolerable safety profile. The most common adverse events (AEs) include fever, which was reported in up to 67% patients in one series, and colonization of skin flora in the nephrostomy tube (16). Additionally, urinary tract infections, ureteric stenosis, and hematuria have been observed (24). BCG dissemination and urosepsis are the

major complications of intracavitary instillation of BCG; nevertheless, these events are uncommon (26).

Overall, primary BCG therapy for UTUCs with a high-risk CIS, has proved efficacy and is a favorable treatment option. BCG as an adjuvant treatment for low-risk UTUC, on the other hand, is contentious and is less frequently utilized in this situation. Accordingly, urologists often prefer MMC or BCG with interferon over BCG alone as an adjuvant treatment (26).

### BCG-interferon

The combination of BCG and interferon alpha-2B (BCG-IFN) is a well-established treatment for patients with superficial bladder cancer (15). Its usage as a treatment for UTUC is, however, novel. IFN is a cytokine that improves the action of BCG by enhancing the immune system, hence decreasing the amount of BCG required for a therapeutic effect (15). Katz *et al.* published the first report of utilizing this combination as an adjuvant therapy for UTUC between 2000 and 2006 (15). Eleven renal units diagnosed with upper tract transitional cell carcinoma received biopsy and ablation of papillary lesions, followed by a 6-week course of topical retrograde induction with BCG-IFN. Eight patients had a full response, of which six required maintenance medication, and two patients had a partial response. Despite the small sample size, this initial experience with BCG-IFN for UTUC was positive, particularly in terms of its acceptable safety and convenience of administration.

In a subsequent study Shapiro *et al.* reported their experience in treating 11 patients with UTUC-CIS with retrograde BCG-IFN instillation for 6 weeks (31). Eight (73%) patients had an initial full response, and none of them developed a recurrence over the whole 13.5-month follow-up period. Together, these trials demonstrate the effectiveness and safety of intraluminal BCG-IFN therapy for UTUC. However, existing research is restricted by small retrospective populations and brief periods of follow-up. Therefore, more research is required to investigate the possible benefits of BCG-IFN in the treatment of UTUC.

### Mitomycin C (MMC)

The most recent EAU recommendations suggest adjuvant topical MMC is a well-tolerated, feasible, and potentially beneficial approach in the management of low-risk UTUC (6,32). However, the true benefit of MMC as an adjuvant treatment remains controversial as most studies of MMC

have relied on noncomparative studies involving small patient cohorts (32,33). Accordingly, this review seeks to summarize the most up to date information on the management of UTUC with MMC.

Since its introduction, the oncological outcomes of MMC for the treatment of UTUC has been assessed in several case series along with some prospective studies. Similar to BCG, the efficacy of MMC as an adjuvant therapy for UTUC has been highly variable. In one of the most recent studies on MMC for UTUC, Gallioli *et al.* conducted the first prospective nonrandomized trial on adjuvant prophylactic MMC treatment after endoscopic management of UTUC (33). The researchers identified a reduction in risk of local or bladder recurrence in the MMC population when compared to those not receiving any adjuvant topical treatment (local recurrence: 20% *vs.* 35.3%; bladder recurrence: 23% *vs.* 26.7%). Notably, adjuvant MMC therapy reduced the risk of UTUC recurrence 7.7-fold on a multivariate analysis ( $P=0.013$ ). However, the recurrence rates presented in this study represented one of the more favorable studies on adjuvant MMC for UTUC. Indeed, local recurrence rates have been reported as high as 53% following adjuvant treatment with MMC (34). Additionally, in a 2012 retrospective case/control study, Cutress *et al.* demonstrated that adjuvant MMC did not change the 5-year local recurrence-free survival of UTUC (35). A select summary of studies (32-34,36-38) reporting the efficacy of adjuvant MMC can be seen in *Table 2*.

Together, these studies show that MMC has variable efficacy in low-grade UTUC patients, with local recurrence rates ranging from 20% to 53%. It is important to note that delivery, timing, and dosage of MMC differ significantly across these studies, making it difficult to draw conclusions about the true efficacy of MMC (39,40). Additionally, the method of delivery of MMC for treatment of UTUC has not been standardized (32). For instance, when Foerster *et al.* conducted a literature review in patients with low-grade UTUC, they found no differences in terms of recurrence, progression, CSS, or OS based on whether administration was delivered antegrade or retrograde (41). Despite these study limitations, however, current evidence generally demonstrates that MMC administration in patients with low-grade UTUC may reduce the risk of local recurrence. Accordingly, the EAU guidelines include MMC among the recommended adjuvant therapies for UTUC (6).

In terms of safety, complication rates are variable but certain complications remain consistent across studies. Specifically, common complications experienced by low-



**Table 2** Summary of select studies investigating adjuvant MMC treatment for low-risk UTUC

Study Author	Year	Participants, N	Mean follow-up, months	Upper tract recurrence (%)
Eastham <i>et al.</i> (37)	1993	7	7.4	29
Keeley <i>et al.</i> (38)	1997	19	30	42
Goel <i>et al.</i> (34)	2003	15	64	53
Aboumarzouk <i>et al.</i> (36)	2013	19	24	35
Metcalfe <i>et al.</i> (32)	2017	27	19	39
Gallioli <i>et al.</i> (33)	2020	24	20.7	20

MMC, mitomycin C; UTUC, upper urinary tract urothelial carcinoma.

grade UTUC patients receiving MMC include recurrent urinary tract infection, ureteral stricture, severe bladder spasms, and pyelonephritis (42). Additionally, an instance of death resulting from MMC extravasation following upper tract instillation was described by Martínez-Piñero *et al.* (27). Due to this experience, several authors recommend suggest performing a retrograde pyelography before the instillation of MMC to exclude patients with contrast extravasation (6,33). Overall, treatment of low-grade UTUC with MMC following KSS appears to be potentially beneficial and generally well-tolerated despite relying on small studies with inherent limitations such as nonrandomization or the lack of a comparison arm.

## UGN-101

The US Food and Drug Administration (FDA) recently approved UGN-101 (JELMYTO<sup>®</sup>, formerly MitoGel, UroGen Pharma, Israel) for low-risk UTUC (43). UGN-101 is an MMC-containing reverse thermal gel that is applied topically as a primary chemo ablative treatment for endoscopically-managed UTUC (44). In general, the main challenge of intracavitary treatment is pelvic and ureteral peristalsis which results in rapid drainage of urine (43). Since dwell time and drug concentration at the target-site are critical to successful intracavitary treatment of UTUC, continuous drug dilution from urine flow reduces exposure of the urothelium to the topical agent (45-47). This poor drug interface is especially important for aqueous MMC as several studies have demonstrated a clear association between exposure time and optimal pharmacological activity (48,49).

UGN-101 set out to solve this inherent problem of aqueous topical agents in the treatment of UTUC. At low temperatures during administration, the MMC gel behaves as a liquid thermosensitive polymer, but when heated to

body temperature following instillation, it solidifies into a semi-solid gel (42). Normal urine flow dissolves the UGN-101 gel, resulting in a slow, sustained delivery of MMC to the urothelium over a period of 4–6 h (1,46).

The FDA approval of UGN-101 stemmed from favorable results from the OLYMPUS trial, a multicenter, single-arm, phase 3 trial in patients with treatment-naïve or recurrent low-risk UTUC (44). Of the 74 patients enrolled in the trial, 71 (96%) received  $\geq 1$  dose of UGN-101 and 61 (82%) completed the 6 planned weekly instillations (44). At the primary disease evaluation visit 4–6 weeks after the last instillation, 58% of patients achieved complete response (44). Among these 41 patients who achieved a complete response, 23 (56%) remained in complete response for 12 months (46). Notably, there was not a clear association between receiving maintenance therapy and maintaining a complete response (46). In terms of recurrence, from April 2017 (trial initiation) to April 2020 (final database lock) 32% of patients showed no local recurrence (44).

UGN-101 also demonstrated a tolerable safety profile. The most common all-cause AEs were ureteric stenosis (44% of patients), urinary tract infection (32% of patients), hematuria (31% of patients), and flank pain (30% of patients) (6). Among the 71 patients, no treatment-related deaths were identified (6). Overall, the safety profile of UGN-101 was consistent with the known profile of aqueous MMC instillation and no new safety signals were found (44). Interestingly, the incidence of all-cause AEs appeared to increase with the number of maintenance instillations received by the patient (46). Additionally, while ureteral stenosis was frequent, particularly among patients receiving several instillations, stenosis can be minimized via a percutaneous nephrostomy tube for antegrade UGN-101 administration (1,47,50).

While initial data on UGN-101 is promising, the

OLYMPUS trial has limitations. For instance, the study includes only a small sample size of 71 patients, reflecting the rarity of low-risk UTUC (46). Furthermore, its open-label design and lack of a comparator arm make it challenging to draw conclusions about the true benefit of UGN-101 compared to other treatment options (43). Despite limitations, results from the final analysis of the OLYMPUS trial confirm that UGN-101 instillation for low-risk UTUC is effective and clinically meaningful (44). In particular, several researchers contend that UGN-101 is a valuable additional option for patients with multifocal disease, those with tumors difficult to treat endoscopically, or patients with a contraindication to RNU (43,44,47). As we look to the future, the integration of other aqueous agents such as BCG or gemcitabine into a hydrogel formulation is an active area of investigation (47,51).

### Gemcitabine

Gemcitabine intracavitary instillation has been shown to be a safe and effective treatment for urothelial bladder cancer (3). However, its significance as a therapy for UTUC is less apparent. The literature on this topic is quite limited. In their porcine model experiment, Kesch *et al.* retrogradely injected a mucoadhesive polymeric paste-drug formulation containing gemcitabine into the upper urinary system of three pigs (51). This aqueous-free matrix of gemcitabine clings to the kidney pelvis and delivers a high local concentration of the medication to the urothelium. No substantial changes were seen in serum creatinine or blood count in this investigation. Additionally, following a second instillation, no lesions of the upper tract were seen. During the nationwide BCG shortage, one human study with a small sample size was conducted in which gemcitabine instillations were performed on the upper tracts of two individuals (52). One of the two patients had a full response, while the other had refractory disease. The absence of a control group, the limited sample size, and the paucity of human studies indicate that more research is necessary to evaluate the safety and efficacy of topical gemcitabine.

### Docetaxel

Docetaxel topical therapy represents a promising new treatment for bladder cancer, mainly in BCG-refractory bladder urothelial carcinoma (53). Similar to gemcitabine, its role as an intracavitary therapy for UTUC is unique and has been mentioned in the literature very infrequently. The

authors of this review have been the only group so far to report the use of topical docetaxel as a therapy for BCG-resistant CIS of the upper urinary tract (54). In this trial, seven patients (10 renal units) with UT-CIS who were ineligible for RNU and had previously failed BCG therapy received a 6-week course of 80 mg docetaxel induction. If a patient responded to therapy, a following maintenance course was administered. Following an average of 33 months of observation, 6 (60%) renal units shown an initial full response to docetaxel, whereas three (30%) did not. One patient with bilateral disease experienced an early response in just one renal unit and was ultimately treated with bilateral radical nephroureterectomy. In addition, another patient with a 6-year full response in both renal units later developed a high-grade tumor on one side one year after completing the maintenance course. Although this trial reveals a potential advantage of intracavitary docetaxel for BCG-refractory patients, more research is required to evaluate the use of docetaxel in UTUC.

### Drug-eluting stents (DES)

To avoid the inherent issues of current adjuvant intracavitary therapies for UTUC, such as the need for frequent instillations, new avenues for UTUC drug delivery are being developed. One promising development has been the creation of biodegradable DES as an adjuvant treatment for UTUC. In general, a DES consists of a biodegradable ureteral stent impregnated with an anti-cancer agent that offers a sustained local delivery of the drug to the urothelium without need for a follow-up intervention to remove the stent (55). The first major study on DES for UTUC was published in 2016 by Barros *et al.* The researchers successfully impregnated paclitaxel, doxorubicin, epirubicin, and gemcitabine into a DES using supercritical fluid technology (56). In an *in vitro* analysis, total release of the drugs was achieved after 72 h. Additionally, when placed in contact with a urothelial cancer cell line (T24), the chemotherapy agents released from the DES killed 75% of the cancer cells.

Other significant advancements in the development of DES for UTUC come from several studies by Soria *et al.* This research group pioneered a new design of DES that is coated with a silk fibroin matrix and allows for the controlled release of MMC to the urothelium (57). In a similar *in vitro* study to Barros *et al.*, the authors were also able to demonstrate that the MMC released from the DES was able to significantly decrease the cell viability of

a urothelial cancer line (T24) when compared to a control group (58). Furthermore, in 2023, Soria *et al.* also tested their concept via an *in vivo* study in 14 female pigs with a solitary kidney (59). In this study, the group's novel DES provided sustained release of MMC for 12 h. While this experiment did not include an assessment of the efficacy of this novel DES against UTUC, it suggests that a DES may be able to provide consistent drug delivery to the urothelium in a human study. However, their study also elicited several complications including ureteral stricture and the release of obstructive ureteral coating fragments from the DES in several animals. Overall, while *in vitro* and animal models have demonstrated that DES have the potential to be a novel approach for adjuvant UTUC treatment, clinical studies are necessary to further evaluate this technology.

## Conclusions

In recent decades, intracavitary instillations have played an increasingly important role in the management of UTUC. In this study, the most recent research on intraluminal treatments for UTUC have been examined. Collectively, MMC has demonstrated efficacy and is the most common adjuvant treatment for UTUC with limited risk. BCG is effective as a main treatment for CIS, but its efficacy as an adjuvant treatment for low-risk disease is unclear. In the future, BCG-IFN, gemcitabine, docetaxel, and DES may play a larger role in the treatment of UTUC; however, data on these therapies is currently limited. In contrast, UGN-101, which was recently approved by the FDA for the treatment of UTUC, has demonstrated positive outcomes and represents a new paradigm in the treatment of UTUC. While a variety of topical therapies have been demonstrated to be helpful, research on UTUC therapy tend to be few, comprise small sample sizes, and are usually single center retrospective experiences. Accordingly, further clinical trials are needed to evaluate the true benefit of these treatments.

## Acknowledgments

*Funding:* None.

## Footnote

*Provenance and Peer Review:* This article was commissioned by the Guest Editors (Ram A. Pathak and Ashok K. Hemal) for the series "Upper Tract Urothelial Cancer" published

in *Translational Andrology and Urology*. The article has undergone external peer review.

*Peer Review File:* Available at <https://tau.amegroups.com/article/view/10.21037/tau-23-35/prf>

*Conflicts of Interest:* All authors have completed the ICMJE uniform disclosure form (available at <https://tau.amegroups.com/article/view/10.21037/tau-23-35/coif>). The series "Upper Tract Urothelial Cancer" was commissioned by the editorial office without any funding or sponsorship. The authors have no other conflicts of interest to declare.

*Ethical Statement:* The authors are accountable for all aspects of the work in ensuring that questions related to the accuracy or integrity of any part of the work are appropriately investigated and resolved.

*Open Access Statement:* This is an Open Access article distributed in accordance with the Creative Commons Attribution-NonCommercial-NoDerivs 4.0 International License (CC BY-NC-ND 4.0), which permits the non-commercial replication and distribution of the article with the strict proviso that no changes or edits are made and the original work is properly cited (including links to both the formal publication through the relevant DOI and the license). See: <https://creativecommons.org/licenses/by-nc-nd/4.0/>.

## References

1. Chien AL, Chua KJ, Doppalapudi SK, et al. The role of endoscopic management and adjuvant topical therapy for upper tract urothelial cancer. *Front Urol* 2022;2:916259.
2. Siegel RL, Miller KD, Fuchs HE, et al. Cancer Statistics, 2021. *CA Cancer J Clin* 2021;71:7-33.
3. Rouprêt M, Babjuk M, Burger M, et al. European Association of Urology Guidelines on Upper Urinary Tract Urothelial Carcinoma: 2020 Update. *Eur Urol* 2021;79:62-79.
4. Soria F, Shariat SF, Lerner SP, et al. Epidemiology, diagnosis, preoperative evaluation and prognostic assessment of upper-tract urothelial carcinoma (UTUC). *World J Urol* 2017;35:379-87.
5. Cutress ML, Stewart GD, Tudor EC, et al. Endoscopic versus laparoscopic management of noninvasive upper tract urothelial carcinoma: 20-year single center experience. *J Urol* 2013;189:2054-60.
6. Rouprêt M, Babjuk M, Burger M, et al. EAU guidelines

- on upper urinary tract urothelial carcinoma. Presented at the EAU Annual Congress Amsterdam, 2022. ISBN 978-94-92671-16-5.
7. Lughezzani G, Burger M, Margulis V, et al. Prognostic factors in upper urinary tract urothelial carcinomas: a comprehensive review of the current literature. *Eur Urol* 2012;62:100-14.
  8. Ploussard G, Xylinas E, Lotan Y, et al. Conditional survival after radical nephroureterectomy for upper tract carcinoma. *Eur Urol* 2015;67:803-12.
  9. Rouprêt M, Babjuk M, Compérat E, et al. European Association of Urology Guidelines on Upper Urinary Tract Urothelial Carcinoma: 2017 Update. *Eur Urol* 2018;73:111-22.
  10. Rouprêt M, Seisen T, Birtle AJ, et al. European Association of Urology Guidelines on Upper Urinary Tract Urothelial Carcinoma: 2023 Update. *Eur Urol* 2023;84:49-64.
  11. Seisen T, Peyronnet B, Dominguez-Escrig JL, et al. Oncologic Outcomes of Kidney-sparing Surgery Versus Radical Nephroureterectomy for Upper Tract Urothelial Carcinoma: A Systematic Review by the EAU Non-muscle Invasive Bladder Cancer Guidelines Panel. *Eur Urol* 2016;70:1052-68.
  12. Studer UE, Casanova G, Kraft R, et al. Percutaneous bacillus Calmette-Guérin perfusion of the upper urinary tract for carcinoma in situ. *J Urol* 1989;142:975-7.
  13. Thalmann GN, Markwalder R, Walter B, et al. Long-term experience with bacillus Calmette-Guérin therapy of upper urinary tract transitional cell carcinoma in patients not eligible for surgery. *J Urol* 2002;168:1381-5.
  14. Vasavada SP, Strem SB, Novick AC. Definitive tumor resection and percutaneous bacille Calmette-Guérin for management of renal pelvic transitional cell carcinoma in solitary kidneys. *Urology* 1995;45:381-6.
  15. Katz MH, Lee MW, Gupta M. Setting a new standard for topical therapy of upper-tract transitional-cell carcinoma: BCG and interferon-alpha2B. *J Endourol* 2007;21:374-7; discussion 377.
  16. Nishino Y, Yamamoto N, Komeda H, et al. Bacillus Calmette-Guérin instillation treatment for carcinoma in situ of the upper urinary tract. *BJU Int* 2000;85:799-801.
  17. Irie A, Iwamura M, Kadowaki K, et al. Intravesical instillation of bacille Calmette-Guérin for carcinoma in situ of the urothelium involving the upper urinary tract using vesicoureteral reflux created by a double-pigtail catheter. *Urology* 2002;59:53-7.
  18. Seisen T, Colin P, Rouprêt M. Risk-adapted strategy for the kidney-sparing management of upper tract tumours. *Nat Rev Urol* 2015;12:155-66.
  19. Pollard ME, Levinson AW, Shapiro EY, et al. Comparison of 3 upper tract anticarcinogenic agent delivery techniques in an ex vivo porcine model. *Urology* 2013;82:1451.e1-6.
  20. Liu Z, Ng J, Yuwono A, et al. Which is best method for instillation of topical therapy to the upper urinary tract? An in vivo porcine study to evaluate three delivery methods. *Int Braz J Urol* 2017;43:1084-91.
  21. Yossepowitch O, Lifshitz DA, Dekel Y, et al. Assessment of vesicoureteral reflux in patients with self-retaining ureteral stents: implications for upper urinary tract instillation. *J Urol* 2005;173:890-3.
  22. Kresowik TP, Griffith TS. Bacillus Calmette-Guérin immunotherapy for urothelial carcinoma of the bladder. *Immunotherapy* 2009;1:281-8.
  23. Petros FG, Li R, Matin SF. Endoscopic Approaches to Upper Tract Urothelial Carcinoma. *Urol Clin North Am* 2018;45:267-86.
  24. Giannarini G, Kessler TM, Birkhäuser FD, et al. Antegrade perfusion with bacillus Calmette-Guérin in patients with non-muscle-invasive urothelial carcinoma of the upper urinary tract: who may benefit? *Eur Urol* 2011;60:955-60.
  25. Hayashida Y, Nomata K, Noguchi M, et al. Long-term effects of bacille Calmette-Guérin perfusion therapy for treatment of transitional cell carcinoma in situ of upper urinary tract. *Urology* 2004;63:1084-8.
  26. Rastinehad AR, Ost MC, Vanderbrink BA, et al. A 20-year experience with percutaneous resection of upper tract transitional carcinoma: is there an oncologic benefit with adjuvant bacillus Calmette Guérin therapy? *Urology* 2009;73:27-31.
  27. Martínez-Piñero JA, García Matres MJ, Martínez-Piñero L. Endourological treatment of upper tract urothelial carcinomas: analysis of a series of 59 tumors. *J Urol* 1996;156:377-85.
  28. Clark PE, Strem SB, Geisinger MA. 13-year experience with percutaneous management of upper tract transitional cell carcinoma. *J Urol* 1999;161:772-5; discussion 775-6.
  29. Rastinehad AR, Smith AD. Bacillus Calmette-Guérin for upper tract urothelial cancer: is there a role? *J Endourol* 2009;23:563-8.
  30. Schoenberg MP, Van Arsdalen KN, Wein AJ. The management of transitional cell carcinoma in solitary renal units. *J Urol* 1991;146:700-2; discussion 702-3.
  31. Shapiro EY, Lipsky MJ, Cha DY, et al. Outcomes of intrarenal Bacillus Calmette-Guérin/interferon- $\alpha$ 2B for biopsy-proven upper-tract carcinoma in situ. *J Endourol*



- 2012;26:1645-50.
32. Metcalfe M, Wagenheim G, Xiao L, et al. Induction and Maintenance Adjuvant Mitomycin C Topical Therapy for Upper Tract Urothelial Carcinoma: Tolerability and Intermediate Term Outcomes. *J Endourol* 2017;31:946-53.
  33. Gallioli A, Boissier R, Territo A, et al. Adjuvant Single-Dose Upper Urinary Tract Instillation of Mitomycin C After Therapeutic Ureteroscopy for Upper Tract Urothelial Carcinoma: A Single-Centre Prospective Non-Randomized Trial. *J Endourol* 2020;34:573-80.
  34. Goel MC, Mahendra V, Roberts JG. Percutaneous management of renal pelvic urothelial tumors: long-term followup. *J Urol* 2003;169:925-9; discussion 929-30.
  35. Cutress ML, Stewart GD, Wells-Cole S, et al. Long-term endoscopic management of upper tract urothelial carcinoma: 20-year single-centre experience. *BJU Int* 2012;110:1608-17.
  36. Aboumarzouk OM, Somani B, Ahmad S, et al. Mitomycin C instillation following ureterorenoscopic laser ablation of upper urinary tract carcinoma. *Urol Ann* 2013;5:184-9.
  37. Eastham JA, Huffman JL. Technique of mitomycin C instillation in the treatment of upper urinary tract urothelial tumors. *J Urol* 1993;150:324-5.
  38. Keeley FX Jr, Bagley DH. Adjuvant mitomycin C following endoscopic treatment of upper tract transitional cell carcinoma. *J Urol* 1997;158:2074-7.
  39. Cornu JN, Rouprêt M, Carpentier X, et al. Oncologic control obtained after exclusive flexible ureteroscopic management of upper urinary tract urothelial cell carcinoma. *World J Urol* 2010;28:151-6.
  40. Palou J, Piovesan LF, Huguet J, et al. Percutaneous nephroscopic management of upper urinary tract transitional cell carcinoma: recurrence and long-term followup. *J Urol* 2004;172:66-9.
  41. Foerster B, D'Andrea D, Abufaraj M, et al. Endocavitary treatment for upper tract urothelial carcinoma: A meta-analysis of the current literature. *Urol Oncol* 2019;37:430-6.
  42. Jung H, Giusti G, Fajkovic H, et al. Consultation on UTUC, Stockholm 2018: aspects of treatment. *World J Urol* 2019;37:2279-87.
  43. Kokorovic A, Matin SF. UGN-101 (mitomycin gel): a novel treatment for low-grade upper tract urothelial carcinoma. *Ther Adv Med Oncol* 2020;12:1758835920937950.
  44. Matin SF, Pierorazio PM, Kleinmann N, et al. Durability of Response to Primary Chemoablation of Low-Grade Upper Tract Urothelial Carcinoma Using UGN-101, a Mitomycin-Containing Reverse Thermal Gel: OLYMPUS Trial Final Report. *J Urol* 2022;207:779-88.
  45. Donin NM, Duarte S, Lenis AT, et al. Sustained-release Formulation of Mitomycin C to the Upper Urinary Tract Using a Thermosensitive Polymer: A Preclinical Study. *Urology* 2017;99:270-7.
  46. Kleinmann N, Matin SF, Pierorazio PM, et al. Primary chemoablation of low-grade upper tract urothelial carcinoma using UGN-101, a mitomycin-containing reverse thermal gel (OLYMPUS): an open-label, single-arm, phase 3 trial. *Lancet Oncol* 2020;21:776-85.
  47. Patel SR, Lerner SP. Novel Thermo-Sensitive Hydrogel Therapy for Low-Grade Upper Tract Urothelial Carcinoma. *J Urol* 2021;206:191-3.
  48. De Bruijn EA, Sleeboom HP, van Helsdingen PJ, et al. Pharmacodynamics and pharmacokinetics of intravesical mitomycin C upon different dwelling times. *Int J Cancer* 1992;51:359-64.
  49. Schmittgen TD, Wientjes MG, Badalament RA, et al. Pharmacodynamics of mitomycin C in cultured human bladder tumors. *Cancer Res* 1991;51:3849-56.
  50. Rosen GH, Nallani A, Muzzey C, et al. Antegrade Instillation of UGN-101 (Mitomycin for Pyelocalyceal Solution) for Low-Grade Upper Tract Urothelial Carcinoma: Initial Clinical Experience. *J Urol* 2022;207:1302-11.
  51. Kesch C, Schmitt V, Bidnur S, et al. A polymeric paste-drug formulation for local treatment of upper tract urothelial carcinoma. *Urol Oncol* 2021;39:194.e1-7.
  52. Balasubramanian A, Metcalfe MJ, Wagenheim G, et al. Salvage topical therapy for upper tract urothelial carcinoma. *World J Urol* 2018;36:2027-34.
  53. Barlow LJ, McKiernan JM, Benson MC. The novel use of intravesical docetaxel for the treatment of non-muscle invasive bladder cancer refractory to BCG therapy: a single institution experience. *World J Urol* 2009;27:331-5.
  54. Katims AB, Tam AW, Rosen DC, et al. Novel treatment of upper tract urothelial carcinoma in situ with docetaxel in BCG refractory patients. *Urol Oncol* 2021;39:234.e9-234.e13.
  55. Barros AA, Oliveira C, Reis RL, et al. In Vitro and Ex Vivo Permeability Studies of Paclitaxel and Doxorubicin From Drug-Eluting Biodegradable Ureteral Stents. *J Pharm Sci* 2017;106:1466-74.
  56. Barros AA, Browne S, Oliveira C, et al. Drug-eluting biodegradable ureteral stent: New approach for urothelial tumors of upper urinary tract cancer. *Int J Pharm* 2016;513:227-37.
  57. Soria F, Aznar-Cervantes SD, de la Cruz JE, et

- al. Assessment of a Coated Mitomycin-Releasing Biodegradable Ureteral Stent as an Adjuvant Therapy in Upper Urothelial Carcinoma: A Comparative In Vitro Study. *Polymers (Basel)* 2022;14:3059.
58. Soria F, Martínez-Pla L, Aznar-Cervantes SD, et al. Cytotoxicity Assessment of a New Design for a Biodegradable Ureteral Mitomycin Drug-Eluting Stent in Urothelial Carcinoma Cell Culture. *Polymers (Basel)* 2022;14:4081.
59. Soria F, Delacruz JE, Aznar-Cervantes SD, et al. Animal model assessment of a new design for a coated mitomycin-eluting biodegradable ureteral stent for intracavitary instillation as an adjuvant therapy in upper urothelial carcinoma. *Minerva Urol Nephrol* 2023;75:194-202.

**Cite this article as:** Khargi R, Connors C, Ricapito A, Yaghoubian AJ, Gallante BE, Khusid JA, Atallah WM, Gupta M. Adjuvant intraluminal therapies for upper tract urothelial carcinoma. *Transl Androl Urol* 2023;12(9):1439-1448. doi: 10.21037/tau-23-35