



Renal pedicle lymphatic ligation for non-parasitic chyluria via retroperitoneal laparoscopic surgery: a single-center 12-year experience

Kangning Wang^{1,2}, Bingsheng Li^{1,2}, Zewu Zhu^{1,2}, Lina Zhang^{2,3}, Zhiyong Liu^{2,3}, Li Huang^{2,3}, Yunbo He^{1,2}, Zhi Liu^{1,2}, Weiping Xia^{1,2,3}^

¹Department of Urology, Xiangya Hospital, Central South University, Changsha, China; ²National Clinical Research Center for Geriatric Disorders, Xiangya Hospital, Central South University, Changsha, China; ³Department of Intensive Care Medicine, Xiangya Hospital, Central South University, Changsha, China

Contributions: (I) Conception and design: W Xia; (II) Administrative support: W Xia, L Huang; (III) Provision of study materials or patients: K Wang, B Li; (IV) Collection and assembly of data: Z Zhu, L Huang, Y He, Zhi Liu; (V) Data analysis and interpretation: L Zhang, Zhiyong Liu; (VI) Manuscript writing: All authors; (VII) Final approval of manuscript: All authors.

Correspondence to: Weiping Xia, MD. Department of Urology, Xiangya Hospital, Central South University, Xiangya Road 87, Changsha 410008, China; National Clinical Research Center for Geriatric Disorders, Xiangya Hospital, Central South University, Changsha, China; Department of Intensive Care Medicine, Xiangya Hospital, Central South University, Changsha, China. Email: abc635230019@163.com.

Background: Chyluria is a rare disease in which chylous is excreted in the urine. Currently, management of chyluria includes conservative treatments and surgical measures. This study aimed to report our experience in treating non-parasitic chyluria with retroperitoneal laparoscopic ligation of the renal lymphatic vessels.

Methods: Data from 52 patients who underwent retroperitoneoscopic ligation of the renal lymphatic vessels for non-parasitic chyluria between December 2009 and May 2022 were reviewed. After general anesthesia, the patients were passively placed in the healthy lateral decubitus position and underwent three-port retroperitoneal laparoscopy. Detailed medical data, including demographic characteristics, intraoperative outcomes, postoperative data, and complications, were reviewed.

Results: Fifty-two patients received surgery treatment at our institution. The mean disease course was 89.3 months. The mean age was 58.8 years, with females accounting for 57.7% (30/52); the majority of patients (33/52) had the laterality of chyluria on the left and 9 (17.3%) had a history of previous thoracic or abdominal surgery. Compared with the urine and blood data before the operation and on the first day after the operation, urinary protein, urinary tract infection, urinary red blood cells, hemoglobin, albumin, and serum total protein significantly improved 3 months after the operation. However, there were no significant differences in blood creatinine and blood urea nitrogen levels among the three groups. The mean surgery time was about 110.0 minutes, and the estimated total blood loss was 81.2 mL. The postoperative drainage volume was 229.9 mL. The average time to start a liquid diet and to be out of bed were 1.5 and 1.9 days, respectively. Transient postoperative gross hematuria occurred in eight patients, and complications occurred in five patients after surgery. The mean length of hospitalization was 6.6 days. The follow-up duration ranged from 3 to 152 months, and except for three patients who did not respond to treatment, the remaining patients had no recurrence and did not require reoperation.

Conclusions: Our long-term follow-up results showed that renal pedicle lymphatic ligation via retroperitoneal laparoscopic surgery is an effective, safe, and reliable surgical option for patients with non-parasitic chyluria.

^ ORCID: 0000-0001-7873-3878.

Keywords: Non-parasitic chyluria; renal lymphatic vessels; ligation; milky white urine

Submitted May 18, 2023. Accepted for publication Sep 18, 2023. Published online Oct 19, 2023.

doi: 10.21037/tau-23-287

View this article at: <https://dx.doi.org/10.21037/tau-23-287>

Introduction

Chyluria is caused by chylous fluid entering the urinary tract. The appearance of chyluria often results in milky-white urine, which differs from that of normal urine. If it contains more blood, it is called chylous hematuria, which can cause intrinsic ureteral obstruction and symptoms related to nutritional deficiency. The precise etiology of chyluria is not fully understood, but it can be divided into non-parasitic and parasitic types. Non-parasitic chyluria is often caused by lymphatic malformations, malignant thoracic and abdominal tumors, tuberculosis, abdominal trauma, idiopathic causes, and so forth (1-4). Although previous studies have found that 90% of patients with chyluria have lymphatic filariasis (5,6), the number of patients with parasitic chyluria has been significantly reduced owing to continuous economic development and national prevention and control of parasites (7,8). However, the incidence of nonparasitic chyluria appears to be increasing because of the current high incidence of thoracic and abdominal tumors.

The main symptoms of non-parasitic chyluria are milky

white urine, flank pain and macro/micro-hematuria, which can lead to a massive loss of fat bodies and protein in the urine, resulting in anemia, systemic fatigue, body weight loss, hypoalbuminemia, autoimmune diseases, etc. (6). Furthermore, in some cases, fatty meals and exercise, can even aggravate the patient's symptom (9,10). Currently, management of chyluria consists of conservative treatments and surgical measures. Conservative treatments, including bed rest, low-fat diet, high-intensity focused ultrasound (HIFU), and oral medication, can be used for mild chyluria (5,10,11). Surgical treatment includes a variety of surgical methods, such as sclerotherapy with silver nitrate or povidone-iodine (12,13), nephrectomy, and renal pedicle lymphatic ligation. With the continuous development of minimally invasive methods in urology, multiple reports have described retroperitoneal laparoscopic renal pedicle lymphatic disconnection as the most effective treatment strategy for chyluria (4). The remaining lymphatic vessels can be carefully identified and ligated under clear laparoscopic magnification and clipped to prevent postoperative recurrence or lymphatic fistulas. However, there have been few long-term follow-up studies on this technique in the management of non-parasitic chyluria.

In this study, we record our surgical procedures in detail and report our 12 years of experience with this surgical method for the treating non-parasitic chyluria. To our knowledge, this is the longest follow-up study to evaluate the safety and efficacy of retroperitoneal laparoscopic renal pedicle lymphatic ligation for the treatment of non-parasitic chyluria. We present this article in accordance with the TREND reporting checklist (available at <https://tau.amegroups.com/article/view/10.21037/tau-23-287/rc>).

Methods

Patients

From December 2009 to May 2022, we collected data on 59 patients who were diagnosed with non-parasitic chyluria preoperatively, of whom seven patients refused surgery due to the surgical risks; the remaining 52 patients

Highlight box

Key findings

- Retroperitoneal laparoscopic renal pedicle lymphatic ligation is an effective, safe, and reliable surgical option for patients with non-parasitic chyluria.

What is known and what is new?

- Retroperitoneal laparoscopic renal pedicle lymphatic disconnection is one of surgical treatment strategy for chyluria.
- This study is the longest follow-up study to evaluate the safety and efficacy of retroperitoneal laparoscopic renal pedicle lymphatic ligation for the treatment of non-parasitic chyluria.

What is the implication, and what should change now?

- The finding of demonstrate high potential of retroperitoneal laparoscopic renal pedicle lymphatic ligation as a first line treatment in patients with non-parasitic chyluria.
- Increased the exploration of the etiology of non-parasitic chyluria to ensure the effectiveness of surgical treatment.

Table 1 Characteristics of patients

Characteristics	Values
Gender (M/F)	22/30
Mean age (years)	58.8±9.36
BMI (kg/m ²)	21.8±2.5
Side of lesion (L/R)	33/19
History of chronic diseases	7 (13.5)
Previous thoracic and abdominal surgical history	9 (17.3)
Disease course (months)	89.3±136.1
Clinical symptoms	
Milky white urine	20 (38.5)
Chyluria with gross hematuria	10 (19.2)
Chyluria with microscopic hematuria	22 (42.3)

Data are presented as n, mean ± SD, or n (%). M, male; F, female; BMI, body mass index; L, left; R, right; SD, standard deviation.

underwent retroperitoneal laparoscopic ligation of the renal lymphatic vessels, which was performed by three groups of experienced surgeons at our institution. We retrospectively reviewed the patients' medical data. All patients underwent preoperative cystoscopy, chyle urine examination, and computed tomography (CT) to evaluate the laterality of the chyluria. Cystoscopy revealed that chyluria spurting from the ureteral orifice of the diseased side, and urine chyle test results were positive in all patients. Moreover, CT examination results ruled out other diseases of the urinary system. The clinical data of the patients are summarized in *Table 1*.

During the follow-up, all patients underwent routine urinalysis, and urine examination for chyle every 3 months to observe chyluria recurrence during the first year in the outpatient department. Thereafter, telephone follow-ups were performed twice a year. Other means of examination, including cystoscopy, urinary ultrasonography, and CT, were performed whenever necessary during follow-up. Surgical success was evaluated based on the resolution of chyluria and alleviation of symptoms.

The study was conducted in accordance with the Declaration of Helsinki (as revised in 2013). The study was approved by the Ethics Committee of Xiangya Hospital, Central South University (No. 202208195), and informed consent was obtained from all patients.

Operative technique

Endotracheal intubation was performed following general anesthesia, and patients were passively placed in the lateral decubitus position (surgical side up) with slight table flexion. The surgical procedures were as follows: first, the surgical area was disinfected, an arcuate incision of approximately 2 cm was made below the 12th rib in the posterior region, and the muscular layer and lumbodorsal fascia were bluntly divided directly with vascular forceps. The retroperitoneal space was bluntly separated using an index finger. Trocars of 10 and 5 mm were then inserted 2 cm above the superior margin of the iliac crest at the midaxillary line and below the costal margin at the anterior axillary line, respectively. Pneumoretroperitoneum was established using carbon dioxide to maintain a pressure of approximately 12–14 mmHg.

After minimally invasive working access was established, we carefully dissected the retroperitoneal fat and adjacent tissues outside the Gerota's fascia to create a larger working space. After that, the fascia of Gerota was incised longitudinally close to the dorsal side. First, the adipose capsule of the kidney was bluntly or sharply separated from the renal parenchymal surface using an ultrasonic scalpel, and the lower, upper, and anterior surfaces near the hilum were stripped and ligated. Second, the lymphatic vessels and adipose tissue from the upper ureter approximately 4 cm to around the renal pelvis were dissected and ligated by using clips. Third, the lymphatic vessels surrounding the renal vessels (renal artery and vein) were isolated and ligated anatomically by using clips. Detailed ligation procedures for the hilar lymphatic vessels have been described previously by in Zhang *et al.* (14). Subsequently, a few drops of methylene were added to the hilum of the renal tissue to observe if there were any residual lymphatic vessels existing. Finally, the upper polar renal capsule was fixed with non-absorbable sutures to prevent nephroptosis and renal vascular torsion. A retroperitoneal drainage tube was placed after complete examination of the wound. The brief ligation procedure can be seen in *Figure S1*. And the *Figure S1* was created using figdraw (permission ID: RRTSOaaccb).

The drainage tube was removed when the drainage fluid volume was less than 50 mL per day for 2 consecutive days. The Foley urethral catheter was removed 1–3 days after the surgery. A chyle urine examination was performed at 3 days postoperatively.

Table 2 Preoperative and postoperative urine and blood data

Variable	Preoperative (#1)	Postoperative day 1 (#2)	Three months after surgery (#3)	P value	
				#1 vs. #3	#2 vs. #3
Urine protein (negative/positive)	6/46	–	25/27	<0.0001	–
Urine leukocyte (negative/positive)	35/17	–	47/5	0.004	–
Urine erythrocyte (negative/positive)	20/32	–	47/5	<0.0001	–
Hemoglobin (g/L)	129.3±15.2	119.3±14.8	136.7±12.6	0.02	<0.0001
Albumin (g/L)	34.5±5.4	31.3±3.9	43.5±6.0	<0.001	<0.001
Total protein (g/L)	57.2±7.7	53.2±6.3	64.4±6.6	<0.001	<0.001
Blood creatinine (μmol/L)	73.7±16.6	74.3±19.7	74.9±15.6	0.94	0.98
Blood urea nitrogen (mmol/L)	5.1±1.4	4.5±1.3	4.7±1.2	0.36	0.62

Data are presented as n or mean ± standard deviation.

Statistical analysis

Clinical results are presented as the number of participants (n) or percentage (%) and mean ± standard deviation. To test the surgical outcomes of the preoperative and postoperative urine and blood data, a one-way analysis of variance (ANOVA) was performed. We set $P < 0.05$ as statistical significance. Data were analyzed using the Statistical Package for the Social Sciences 24.0 (SPSS, Chicago, IL, USA).

Results

During the 12-year follow-up, 52 patients (male: female, 22:30) underwent surgery for non-parasitic chyluria in our hospital. The characteristics of patients are summarized in *Table 1*. The mean age was 58.8 years (range, 22–79 years), and body mass index (BMI) was about 21.8 ± 2.5 kg/m². In terms of preoperative examination, all patients underwent serological examination of filariasis, cystoscopy, urine examination for chyle, and CT before the operation. The average time from the onset of symptoms to hospitalization was 89.3 ± 136.1 months. Milky-white urine and/or concomitant hematuria were the most common clinical symptoms. In our study, the clinical manifestations of milky-white urine/non-parasitic chyluria with gross hematuria/non-parasitic chyluria with microscopic hematuria were observed in 20 (38.5%), 10 (19.2%), and 22 (42.3%) patients, respectively. Moreover, non-parasitic chyluria was found more frequently on the left (63.5%, 33/52) than on the right (36.5%, 19/52). Seven (13.5%) patients had a history of chronic disease (such as hypertension, diabetes,

and tuberculosis), and 9 (17.3%) patients had a history of thoracic and abdominal surgeries.

The preoperative and postoperative urine and blood data are summarized in *Table 2*. The leukocyte, erythrocyte and protein levels in the urine reexamined 3 months after surgery were significantly relieved compared with those before surgery, with statistical significance between the two groups. Furthermore, serum hemoglobin, albumin, and total protein were significantly higher at 3 months after surgery than before surgery or on the day after surgery, and the differences between the two groups were statistically significant (preoperative *vs.* 3 months after surgery; postoperative day 1 *vs.* 3 months after surgery). Hence, surgical treatment can significantly improve anemia and nutritional status in patients with non-parasitic chyluria. However, our study found that non-parasitic chyluria caused little damage to kidney function and that most patients' kidney function was within the normal range. There were no significant differences in the serum creatinine and urea nitrogen levels preoperatively, on postoperative day 1, or 3 months after discharge.

As shown in *Table 3*, the mean operative time was 110.0 minutes, the estimated blood loss related to the operation was 81.2 mL, the postoperative drainage volume was 229.9 mL, and average time to begin a liquid diet and be out of bed was 1.5 and 1.9 days, respectively. Furthermore, none of the patients required intra- or postoperative blood transfusions. In addition, eight patients had transient gross hematuria postoperatively, which disappeared after conservative treatment. Five patients (9.6%, 5/52) had postoperative complications, including fever (3.8%, 2/52), ureteral injury (1.9%, 1/52),

Table 3 Postoperative data

Variable	Values
Operative time (minutes)	110.0±28.3
Time to liquid diet (days)	1.5±0.7
Time to out of bed (days)	1.9±1.0
Postoperative drainage volume (mL)	229.9±277.1
Estimated blood loss (mL)	81.2±49.0
Postoperative gross hematuria	8 (15.4)
Postoperative complications	5 (9.6)
Length of hospitalization (days)	6.6±2.6
Chyluria test at 3 months after surgery (positive)	3 (5.8)
Follow-up period (months)	75.4±42.6

Data are presented as mean ± SD, or n (%). SD, standard deviation.

and abdominal distension and vomiting (3.8%, 2/52). The fever in the two patients improved and no septic shock occurred after symptomatic supportive treatment and regular antibiotic therapy. One patient with intraoperative ureteral injury showed improvement after ureteral stent implantation. The other two patients experienced abdominal distension and vomiting, which all recovered with symptomatic anti-vomiting and stomach-protecting treatment and prolonged their length of hospitalization. The average length of hospital stay was approximately 6.6 days and the mean follow-up time was about 75.4 months (range, 3–152 months, the median follow-up time was about 78 months). In terms of the recovery of chyluria, we performed a chyluria test 3 months after surgery, and found that the symptoms of chyluria were relieved in all patients except three; no recurrence of chyluria was found during the long-term follow-up by telephone.

Discussion

Chyluria is a rare condition in which chyle is excreted in the urine (13). Chyluria is often caused by pathological changes in lymphatic system dynamics, such as filarial infection, abdominal or retroperitoneal tumors, tuberculosis, and trauma (15), which eventually lead to an increase in lymphatic pressure, and consequently, the formation of chyle in the urine due to the abnormal communication of a fistula between the lymphatic vessels and the tract of urinary (3,16). Due to a large loss of protein and fat in the

urine, non-parasitic chyluria patients often present with hypoproteinemia, malabsorption, general fatigue, and weight loss. In addition, some patients may experience ipsilateral flank pain, frequent urination, urinary tract infection, and urinary retention symptoms (15,17,18). Up to now, targeted treatments for chyluria mainly include conservative treatments and surgery. Conservative treatment, including diet control and HIFU ablation therapy, is mainly suitable for patients with mild chyluria symptoms (5). However, conservative treatment may aggravate the symptoms of chyluria, and HIFU thermal injury may damage the ureter, renal vessels and other adjacent organs (19,20). Based on these thermal injury related complications, surgery is often recommended for non-parasitic chyluria patients who do not respond to conservative dietary treatments. Although retroperitoneal laparoscopic renal pedicle lymphatic ligation is considered the most effective surgical treatment for chyluria (21), very few case series and reports in the literature have shown the long-term follow-up of surgical outcomes, especially in patients with non-parasitic chyluria. Therefore, we recorded the clinical presentation, diagnosis, preoperative and postoperative urine and blood data, surgical outcomes, and long-term follow-up outcomes of this surgical method in detail. We believe that this study comprises the largest number of patients for whom this technique was used to manage non-parasitic chyluria, with the longest follow-up.

Similar to the description in the literature (6), we also found that there was no significant sex difference in non-parasitic chyluria patients, and that most of the patients in our study had a lateral occurrence on the left. The BMI, disease course, and average age of non-parasitic chyluria patients were approximately 21.8 kg/m², 89.3 months, and 58.8 years old, respectively, which are similar to that reported in the literature (14). Moreover, our results showed that approximately 32.7% (17/52) of patients had a urinary tract infection, and approximately 61.5% (32/52) of non-parasitic chyluria patients had microscopic or gross hematuria before surgery. According to the preoperative hemoglobin and albumin data, most non-parasitic chyluria patients were mildly malnourished in our study. Irrespective of urinary tract infection, hematuria, hemoglobin, and albumin expression levels significantly improved 3 months after surgery. Furthermore, the serum creatinine and urea nitrogen levels before surgery, on day 1 after the operation, and 3 months after the operation were in the normal range. And there was no statistically significant difference in renal function over time. Owing to the retroperitoneal

approach, the relevant postoperative data including operation time, bleeding, gastrointestinal recovery time, and postoperative drainage volume, were similar to those of common retroperitoneal laparoscopic surgeries, with no significant differences (22,23). However, renal pedicle lymphatic ligation, the most recognized surgical method for the treatment of chyluria, requires thorough ligation of the lymphatic vessels. It is a delicate and complex laparoscopic procedure that requires highly proficient surgeons. Although the occurrence of postoperative complications, such as fever, gastrointestinal flatulence and other common postoperative complications, was rare in our study, injury to the ureter occurred in one patient; therefore, we should be very careful when performing lymphatic vessel separation and ligation at the renal hilum.

To our knowledge, retroperitoneal laparoscopic renal pedicle lymphatic ligation is a minimally invasive surgical technique that has been applied in the management of non-parasitic chyluria for a long time. However, because the incidence of non-parasitic chyluria is low, most studies are case reports, and there is a lack of long-term follow-up results with a large sample size. Therefore, for the first time, we report the largest single-institution experience using this technique for the treatment of non-parasitic chyluria. During the long-term follow-up, the prognosis was good. Chyluria symptoms were completely relieved in 94.2% (49/52) of the patients 3 months after surgery, and no chyluria recurrence occurred during the long-term follow-up period. In addition, the other three patients who did not respond to the surgery and the long-term follow-up of the chyluria test were still positive without significant remission. We recommend the use of a urine chyluria test for at least 6 months to 1 year after surgery in all patients. Long-term close monitoring results show that recurrence is less likely.

Our study had some limitations. First, as this was a retrospective study, there was some incomplete data, such as a lack of preoperative and postoperative blood lipid data profiles and detailed nutritional status assessment. Second, in terms of the diagnosis of disease etiology, there are still obvious deficiencies in the exploration of the accurate etiology of non-parasitic chyluria in our study, which may also be the cause of poor surgical treatment. Finally, the complex anatomy of the renal pedicle and the complete lymphatic ligation process may damage the renal arteries, veins, and ureters, which limits its widespread application, especially in primary hospitals.

Conclusions

According to our study findings, the retroperitoneal laparoscopic renal pedicle lymphatic ligation technique can be successfully performed in patients with non-parasitic chyluria and achieve good outcomes. This technique also has all the advantages of minimally invasive surgery, such as shorter operative time, less blood loss, and rapid recovery. In conclusion, because this technique is an effective, safe, and reliable surgical choice, we recommend it as the first treatment option for patients with non-parasitic chyluria.

Acknowledgments

Funding: This study was supported by the Natural Science Foundation of Hunan Province Youth Fund (No. S2020JJQNJJ1081 to Li Huang and No.2023JJ40999 to Weiping Xia).

Footnote

Reporting Checklist: The authors have completed the TREND reporting checklist. Available at <https://tau.amegroups.com/article/view/10.21037/tau-23-287/rc>

Data Sharing Statement: Available at <https://tau.amegroups.com/article/view/10.21037/tau-23-287/dss>

Peer Review File: Available at <https://tau.amegroups.com/article/view/10.21037/tau-23-287/prf>

Conflicts of Interest: All authors have completed the ICMJE uniform disclosure form (available at <https://tau.amegroups.com/article/view/10.21037/tau-23-287/coif>). LH reports the funding from the Natural Science Foundation of Hunan Province Youth Fund (No. S2020JJQNJJ1081). WX reports the funding from the Natural Science Foundation of Hunan Province Youth Fund (No. 2023JJ40999). The other authors have no conflicts of interest to declare.

Ethical Statement: The authors are accountable for all aspects of the work, including ensuring that issues related to the accuracy or integrity of any part of the work have been appropriately investigated and resolved. The study was conducted in accordance with the Declaration of Helsinki (as revised in 2013). The study was approved by the Ethics Committee of Xiangya Hospital, Central South University (No. 202208195), and informed consent was obtained from

all patients.

Open Access Statement: This is an Open Access article distributed in accordance with the Creative Commons Attribution-NonCommercial-NoDerivs 4.0 International License (CC BY-NC-ND 4.0), which permits the non-commercial replication and distribution of the article with the strict proviso that no changes or edits are made and the original work is properly cited (including links to both the formal publication through the relevant DOI and the license). See: <https://creativecommons.org/licenses/by-nc-nd/4.0/>.

References

1. Kaur H, Matin SF, Javadi S, et al. Chyluria after radiofrequency ablation of renal tumors. *J Vasc Interv Radiol* 2011;22:924-7.
2. Weening AA, Schurink B, Ruurda JP, et al. Chyluria and chylothorax after posterior selective fusion for adolescent idiopathic scoliosis. *Eur Spine J* 2018;27:2088-92.
3. Eisner BH, Tanrikut C, Dahl DM. Chyluria secondary to lymphorenal fistula. *Kidney Int* 2009;76:126.
4. Zhang X, Ye ZQ, Chen Z, et al. Comparison of open surgery versus retroperitoneoscopic approach to chyluria. *J Urol* 2003;169:991-3.
5. Xiao J, Sun T, Zhang S, et al. HIFU, a noninvasive and effective treatment for chyluria: 15 years of experience. *Surg Endosc* 2018;32:3064-9.
6. Stainer V, Jones P, Juliebø SØ, et al. Chyluria: what does the clinician need to know? *Ther Adv Urol* 2020;12:1756287220940899.
7. Yajima A, Ichimori K. Progress in the elimination of lymphatic filariasis in the Western Pacific Region: successes and challenges. *Int Health* 2020;13:S10-6.
8. Bizhani N, Hashemi Hafshejani S, Mohammadi N, et al. Lymphatic filariasis in Asia: a systematic review and meta-analysis. *Parasitol Res* 2021;120:411-22.
9. Triffoni-Melo AT, Diez-Garcia RW, Barros Silva GE, et al. Good response of low-fat/high-protein diet in a patient with chyluria. *Ren Fail* 2014;36:453-6.
10. Wang YC, Wu CC. Chyluria. *Nephrology (Carlton)* 2014;19:172.
11. Mendu DR, Sternlicht H, Ramanathan LV, et al. Two cases of spontaneous remission of non-parasitic chyluria. *Clin Biochem* 2017;50:886-8.
12. Goel S, Mandhani A, Srivastava A, et al. Is povidone iodine an alternative to silver nitrate for renal pelvic instillation sclerotherapy in chyluria? *BJU Int* 2004;94:1082-5.
13. Abeygunasekera AM, Sutharshan K, Balagobi B. New developments in chyluria after global programs to eliminate lymphatic filariasis. *Int J Urol* 2017;24:582-8.
14. Zhang X, Zhu QG, Ma X, et al. Renal pedicle lymphatic disconnection for chyluria via retroperitoneoscopy and open surgery: report of 53 cases with followup. *J Urol* 2005;174:1828-31.
15. Faraj J, Mander J, Burnett JR, et al. Filiarial chyluria with nephrotic-range proteinuria and associated hypoalbuminaemia and hypogammaglobulinaemia secondary to bilateral lymphorenal fistulae. *BMJ Case Rep* 2017;2017:bcr2017221114.
16. Sabbah A, Koumako C, El Mouhadi S, et al. Chyluria: non-enhanced MR lymphography. *Insights Imaging* 2023;14:119.
17. Shah UH, Ngoc H, Gupta S. Milky White Urine After Relief of Urinary Retention. *J Emerg Med* 2020;58:e149-52.
18. Barman N, Palese M. Robotic surgery for treatment of chyluria. *J Robot Surg* 2016;10:1-4.
19. Ker CR, Ou KY, Long CY, et al. Acute renal insufficiency and thrombocytopenia after high-intensity focused ultrasound (HIFU) ablation for uterine myomas. *Taiwan J Obstet Gynecol* 2020;59:594-7.
20. Ko JKY, Seto MTY, Cheung VYT. Thermal bowel injury after ultrasound-guided high-intensity focused ultrasound treatment of uterine adenomyosis. *Ultrasound Obstet Gynecol* 2018;52:282-3.
21. You W, Luan B, Cheng T, et al. The efficacy and safety of retroperitoneoscopic renal pedicle ligation of lymphatic disconnection versus open surgery in the treatment of chyluria: A systematic review and meta-analysis. *Clin Nephrol* 2019;91:211-21.
22. Jiang J, Zhu F, Jin F, et al. Retroperitoneoscopic renal pedicle lymphatic disconnection for chyluria. *Chin Med J (Engl)* 2003;116:1746-8.
23. Xia W, Chen X, Liu L, et al. Comparison of modified hand-assisted retroperitoneoscopic laparoscopic nephrectomy and open nephrectomy in patients with benign inflammatory non-functioning kidney diseases. *Transl Androl Urol* 2021;10:2027-34.

Cite this article as: Wang K, Li B, Zhu Z, Zhang L, Liu Z, Huang L, He Y, Liu Z, Xia W. Renal pedicle lymphatic ligation for non-parasitic chyluria via retroperitoneal laparoscopic surgery: a single-center 12-year experience. *Transl Androl Urol* 2023;12(10):1511-1517. doi: 10.21037/tau-23-287

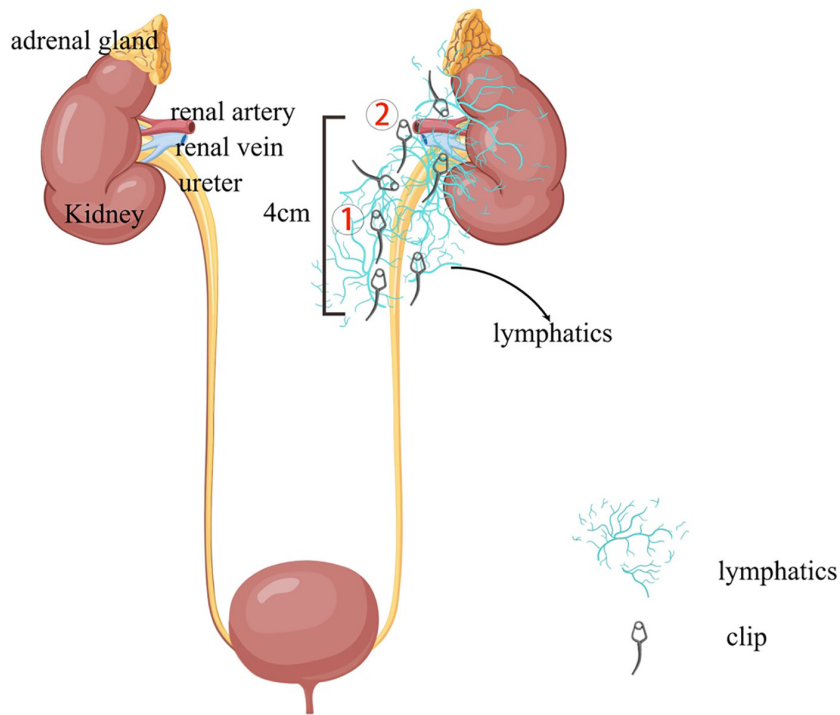


Figure S1 A brief procedure for ligature. After the fascia of Gerota was incised longitudinally close to the dorsal side, the adipose capsule of the kidney was separated from the lower, upper, and anterior surfaces near the hilum. The lymphatic vessels and adipose tissue from the upper ureter approximately 4 cm to around the renal pelvis were dissected and ligated (①). And then the lymphatic vessels surrounding the renal vessels (renal artery and vein) were isolated and ligated (②). The original figure was created using figdraw (www.figdraw.com) (permission ID: RRTSOaacb).