



A novel nomogram to predict testicular torsion in children with acute scrotal pain: a single-center retrospective study in western China

Chenghao Zhanghuang^{1,2,3,#}, Jinkui Wang^{2,#}, Yu Hang¹, Fengming Ji¹, Zhigang Yao¹, Rui Mao⁴, Zhiwei Wang¹, Guiping Yao¹, Ling Liu⁵, Bing Yan^{1,3}

¹Department of Urology, Kunming Children's Hospital Affiliated to Kunming Medical University, Kunming, China; ²Department of Urology, Children's Hospital of Chongqing Medical University, Chongqing, China; ³Yunnan Key Laboratory of Children's Major Disease Research, Yunnan Province Clinical Research Center for Children's Health and Disease, Kunming Children's Hospital Affiliated to Kunming Medical University, Kunming, China; ⁴Department of Information, Kunming Children's Hospital Affiliated to Kunming Medical University, Kunming, China; ⁵Department of Neonatology, Kunming Children's Hospital Affiliated to Kunming Medical University, Kunming, China

Contributions: (I) Conception and design: C Zhanghuang; (II) Administrative support: L Liu, B Yan; (III) Provision of study materials or patients: B Yan, R Mao, Y Hang, F Ji; (IV) Collection and assembly of data: Z Wang, G Yao, Z Yao; (V) Data analysis and interpretation: J Wang, C Zhanghuang; (VI) Manuscript writing: All authors; (VII) Final approval of manuscript: All authors.

[#]These authors contributed equally to this work as co-first authors.

Correspondence to: Prof. Ling Liu, BS. Department of Neonatology, Kunming Children's Hospital Affiliated to Kunming Medical University, 288 Qianxing Road, Kunming 650228, China. Email: ynl12012@163.com; Prof. Bing Yan, MM. Department of Urology, Kunming Children's Hospital Affiliated to Kunming Medical University, 288 Qianxing Road, Kunming 650228, China; Yunnan Key Laboratory of Children's Major Disease Research, Yunnan Province Clinical Research Center for Children's Health and Disease, Kunming Children's Hospital Affiliated to Kunming Medical University, Kunming, China. Email: ybwcy@163.com.

Background: Acute scrotal pain (ASP) is the most common urological emergency in pediatrics, and its causes include testicular torsion (TT), testicular appendage torsion, and epididymo-orchitis. Among them, TT requires prompt and accurate diagnosis and urgent surgical exploration to prevent testicular loss. Conservative anti-infective treatment is recommended for epididymo-orchitis, and surgery is considered only when scrotal abscess formation and sepsis occur. Improving the understanding of TT in primary care doctors, early diagnosis, and timely surgical exploration are essential to improve the survival rate of TT and avoid excessive treatment. This study aimed to explore the risk factors for TT in children with ASP and construct a predictive model.

Methods: Clinical data of children who presented with ASP and underwent emergency scrotal exploration surgery were retrospectively analyzed, including general information, physical examination, laboratory tests, and color Doppler ultrasonography (CDU) findings. Based on surgical exploration, the outcomes were categorized as confirmed TT or not.

Results: A total of 283 children were included in this study, among whom 134 had TT. The mean age of all patients was 105±47.9 months, with the majority being of Han ethnicity (87.6%) and residing in urban areas (83%). Most patients had normal C-reactive protein levels and negative results in urine routine white blood cell tests (63.3%). After conducting univariate and multivariate logistic regression analyses, we identified laterality, neutrophil count, mean erythrocyte sedimentation rate, epididymal blood flow signal, testicular parenchymal echogenicity, and testicular blood flow signal as independent risk factors influencing the occurrence of TT in ASP patients.

Conclusions: This study is the report with the largest sample size on the construction of prediction models for ASP in children in southwestern China. The predictive model we developed demonstrated excellent performance and higher accuracy in predicting TT in children compared to the traditional Testicular Workup for Ischemia and Suspected Torsion (TWIST) score. It can assist pediatric surgeons in diagnosing and treating children with ASP.

Keywords: Nomogram; testicular torsion (TT); children; acute scrotal pain (ASP); western China

Submitted Dec 07, 2023. Accepted for publication Mar 10, 2024. Published online May 17, 2024.

doi: 10.21037/tau-23-634

View this article at: <https://dx.doi.org/10.21037/tau-23-634>

Introduction

Background

Acute scrotal pain (ASP) refers to testicular pain with or without swelling and is the most common urological emergency in pediatric patients (1). The etiology of ASP varies in different reports, mainly including testicular torsion (TT), torsion of the testicular appendage, and epididymal-orchitis (2). In a study of 238 children with ASP, the incidence rates of TT, torsion of the testicular appendage, and epididymitis were 16%, 46%, and 35%, respectively (3). TT, also known as spermatic cord torsion, refers to the vascular compromise of the testicle, epididymis, and other structures due to torsion, resulting in sudden scrotal pain as the main symptom. It requires timely and accurate diagnosis as emergency surgical exploration is the only way to prevent testicular loss (4). However, conservative antimicrobial therapy is the recommended

treatment for epididymal orchitis, and surgery is only considered when scrotal abscess formation and septicemia occur (5). Similarly, once torsion of the testicular appendage is confirmed, it can be managed with conservative anti-infection administration and sufficient analgesics without surgical intervention (6). The disease can heal itself or causes only mild epididymitis with no obvious adverse consequences during conservative treatment because it is self-limiting and testicular appendage has no physiological function. When it causes epididymitis, anti-infective treatment is needed at the same time. Therefore, improving the recognition of TT by primary care physicians, early diagnosis, and timely surgical exploration are crucial for improving testicular survival rates.

Studies have shown that surgical exploration is one of the significant risk factors affecting testicular function (7). Therefore, surgical exploration is not recommended if TT is not present due to the potential risk of testicular atrophy (8). Moreover, surgery significantly increases the incidence of scrotal infection and hematoma (1).

The diagnosis of TT requires a comprehensive assessment based on the patient's medical history, physical examination, and color Doppler ultrasonography (CDU) findings. However, TT still has a high misdiagnosis rate. After being misdiagnosed as orchitis or testicular appendage torsion, conservative observation is used, which delays the timing of surgery and leads to a high rate of testicular loss. A recent analysis of 301 TT patients from a medical center in China found that only a quarter of patients were accurately diagnosed and received timely treatment at the initial visit (9). TT is often misdiagnosed as epididymal-orchitis or torsion of the testicular appendage, mainly due to an inadequate understanding of the disease, overreliance on a single ultrasound result, and insufficient history inquiry and detailed physical examination (10).

A nomogram is constructed based on multivariable regression analysis. It integrates multiple predictive indicators through regression analysis and uses scaled lines to express the relationships among variables in the predictive model. It has been widely used in clinical outcome prediction for various malignant solid tumors and

Highlight box

Key findings

- In this study, a nomogram for predicting testicular torsion (TT) was constructed using multivariate logistic regression analysis, and its accuracy and reliability were evaluated using a validation set. The results show that the established prediction model can effectively assist pediatric surgeons in diagnosis and treatment.

What is known and what is new?

- Acute scrotal pain (ASP) is the most common emergency in pediatric urology. At present, there are a number of clinical studies on the occurrence of TT in children with ASP. However, there are limitations such as low accuracy and incomplete inclusion factors.
- This study is the first to combine the clinical information, physical examination, laboratory examination and imaging findings of patients to construct a prediction model. It is the largest study of TT in children in the southwest.

What is the implication, and what should change now?

- It is time to change the approach to diagnosis and treatment of ASP in children by adopting the nomogram predictive model for risk assessment and considering the risk of surgical exploration and the risk of potential testicular atrophy.

has shown good predictive performance (11-13). However, there is limited research on predictive models for TT. Takeshita *et al.* developed a nomogram to predict TT in Japanese patients with ASP based on physical examination and environmental factors (14). Still, they overlooked the role of important ancillary tests such as CDU in diagnosing TT. Chen and other researchers conducted a retrospective analysis of TT patients over 12 years in a single center, constructing a predictive model based on hematological indicators such as white blood cells, lymphocytes, and monocytes (15). However, this predictive model focused solely on hematological indicators, which may introduce certain biases in the results. Therefore, it is crucial to establish and construct a highly accurate nomogram in identifying TT and predicting the probability of TT in children with ASP.

This study included pediatric patients who visited Kunming Children's Hospital between 2014 and 2022 and underwent surgical exploration for ASP. Collecting data on patient's physical examinations, general conditions, laboratory tests, and imaging results, we conducted a comprehensive analysis with a large sample size and multiple factors. We constructed a nomogram and performed external validation to provide reference and guidance for clinical decision-making by healthcare professionals. This manuscript is written following TRIPOD reporting checklist (available at <https://tau.amegroups.com/article/view/10.21037/tau-23-634/rc>).

Methods

Patient collection and screening

We collected data from all pediatric patients who underwent ASP management at our hospital between 2014 and 2022. This is a retrospective case study. This study was approved by the Ethics Committee of Kunming Children's Hospital (No. 2023-03-101-K01). Our study was conducted in accordance with the Declaration of Helsinki (as revised in 2013). Furthermore, this study is retrospective and did not use identifiable information from the patients. Therefore, informed consent from the parents/guardians of children was not required.

All pediatric patients who underwent surgical exploration for ASP were included in this study. Inclusion criteria were: (I) age <18 years; (II) diagnosis between 2014 and 2022; (III) admission diagnosis of ASP. Exclusion criteria were: (I) age less than 6 months; (II) patients who did not undergo

surgery. Cases with missing data were eliminated. The flow chart of this study is shown in *Figure 1*.

Definition of variables

The variables included in this study comprised general patient characteristics (age, ethnicity, place of residence, laterality, triggering factors, presence of nausea/vomiting, duration of symptoms), physical examination findings (thickening of the spermatic cord, presence of cremasteric reflex, high-positioned testis, testicular swelling, hardening of the testis, tenderness on elevation), laboratory test results (blood routine parameters including neutrophils, lymphocytes, neutrophil-lymphocyte ratio (NLR), platelets, platelet-lymphocyte ratio (PLR), monocytes, eosinophils, monocyte-eosinophil ratio (MER), mean platelet volume (MPV), basophils, C-reactive protein; routine urine parameters including leukocytes, red blood cells), and CDU findings (epididymal size, echogenicity, and blood flow signals, testicular parenchymal echo texture, testicular blood flow signals, scrotal wall edema, testicular microlithiasis). The outcomes for the children were categorized as surgical confirmation of TT or no torsion of the testis.

Development and validation of the nomogram

All patients were divided into training and validation sets in a 7:3 ratio. In the training set, we first analyzed univariate logistic regression to identify factors associated with TT. It was determined that there were no differences in settings, eligibility criteria, outcomes, and predictors between the training and validation sets. Factors with a P value less than 0.05 were then included in the multivariate logistic regression analysis to obtain independent risk factors for TT in pediatric patients with ASP. Based on these risk factors, we used R software and the logistic regression function to construct a predictive model for TT in ASP patients. Subsequently, we validated the accuracy and reliability of the nomogram using calibration curves, the concordance index, and the area under the curve (AUC). Additionally, we compared the clinical performance of the nomogram with the Testicular Workup for Ischemia and Suspected Torsion (TWIST) score using the AUC and C-index.

Statistical analysis

Categorical variables were described using frequencies, and

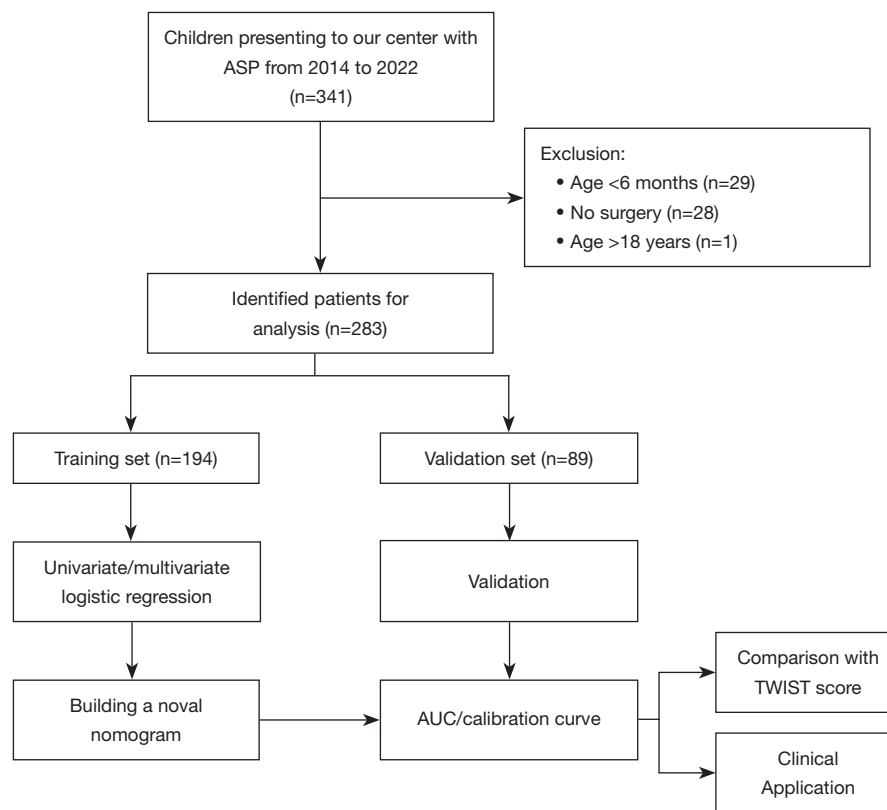


Figure 1 Flowchart for inclusion and exclusion of patients with ASP. The included cases were divided into a training set and a validation set. The training set was used to construct the nomogram, the AUC and calibration curve was used to evaluate the accuracy of the model. The validation set was used for validation. The results were compared with TWIST score, the previous gold standard for TT. ASP, acute scrotal pain; AUC, area under the curve; TWIST, Testicular Workup for Ischemia and Suspected Torsion; TT, testicular torsion.

group differences were assessed using Chi-squared tests. The continuous variables were tested for normal distribution. The measurement data conforming to normal distribution were expressed as mean \pm standard deviation (s.d.), and the *t*-test was used for comparison between groups. Non-parametric *U* tests were used for those that did not satisfy a normal distribution. Univariate and multivariate logistic regression analyses were performed to identify factors associated with TT in pediatric patients. All analyses were conducted using SPSS, version 26.0 (IBM Corp., Armonk, NY, USA) and R statistical software (version 4.1.0; R Foundation for Statistical Computing, Vienna, Austria). $P < 0.05$ were considered statistically significant.

Results

General patient characteristics

A total of 283 patients were included in this study, of which

134 patients experienced TT. The mean age of all patients was 105 ± 47.9 months, and most were of Han ethnicity (87.6%) and resided in urban areas (83%). Most patients had C-reactive protein levels between 1–10 $\mu\text{g/mL}$, and most had negative leukocyte findings in routine urine tests (63.3%). The variables of all patients are presented in *Table 1*, with no significant differences observed between the training and validation sets.

Univariate and multivariate logistic regression analysis

We first conducted a univariate logistic regression analysis, which revealed that laterality, neutrophils, NLR, PLR, monocytes, eosinophils, MER, basophils, epididymal enlargement, epididymal parenchymal echo texture, epididymal blood flow, testicular parenchymal echo texture, testicular blood flow signals, thickening of the spermatic cord, tenderness on elevation, presence of cremasteric

Table 1 Clinicopathological characteristics of patients

Factors	All (N=283)	Training cohort (N=194)	Validation cohort (N=89)	P
Location				>0.99
Urban	235 (83.0)	161 (83.0)	74 (83.1)	
Rural	48 (17.0)	33 (17.0)	15 (16.9)	
Race				0.84
Han nationality	248 (87.6)	169 (87.1)	79 (88.8)	
Ethnic minorities	35 (12.4)	25 (12.9)	10 (11.2)	
Age (months)	105 (47.9)	109 (48.3)	96.6 (46.2)	0.047
Laterality				0.50
Left	165 (58.3)	110 (56.7)	55 (61.8)	
Right	118 (41.7)	84 (43.3)	34 (38.2)	
Precipitating factor				0.40
Conscious and no obvious trigger	213 (75.3)	143 (73.7)	70 (78.7)	
Sleep	54 (19.1)	41 (21.1)	13 (14.6)	
After trauma or exercise	16 (5.6)	10 (5.2)	6 (6.7)	
Neutrophils (10 ⁹ /L)	5.67 (2.82)	5.78 (3.05)	5.43 (2.24)	0.28
Lymphocytes (10 ⁹ /L)	2.98 (1.68)	2.99 (1.72)	2.94 (1.60)	0.80
NLR	2.70 (2.66)	2.85 (2.96)	2.37 (1.81)	0.10
Platelet (10 ⁹ /L)	319 (86.8)	319 (80.8)	319 (99.3)	0.99
PLR	134 (76.3)	136 (81.2)	129 (64.6)	0.41
Monocytes (10 ⁹ /L)	0.51 (0.28)	0.51 (0.27)	0.51 (0.29)	0.96
Eosinophils (10 ⁹ /L)	0.14 (0.15)	0.13 (0.13)	0.16 (0.17)	0.12
MER	16.0 (27.0)	17.3 (28.5)	13.0 (23.3)	0.18
MPV (fL)	9.64 (0.94)	9.57 (0.88)	9.80 (1.04)	0.07
Basophils (10 ⁹ /L)	0.02 (0.02)	0.02 (0.02)	0.02 (0.02)	0.78
C reactive protein (mg/L)				0.51
≤10	273 (96.5)	188 (96.9)	85 (95.5)	
>10	10 (3.5)	6 (3.1)	4 (4.5)	
Urine routine white blood cells				0.26
Positive	32 (11.3)	26 (13.4)	6 (6.7)	
Negative	179 (63.3)	120 (61.9)	59 (66.3)	
Unknown	72 (25.4)	48 (24.7)	24 (27.0)	
Urinalysis red blood cells				0.65
Positive	22 (7.77)	17 (8.76)	5 (5.62)	
Negative	188 (66.4)	128 (66.0)	60 (67.4)	
Unknown	73 (25.8)	49 (25.3)	24 (27.0)	

Table 1 (continued)

Table 1 (continued)

Factors	All (N=283)	Training cohort (N=194)	Validation cohort (N=89)	P
Epididymal size				0.85
Enlargement	160 (56.5)	108 (55.7)	52 (58.4)	
Normal	70 (24.7)	48 (24.7)	22 (24.7)	
Unclear results	53 (18.7)	38 (19.6)	15 (16.9)	
Echogenicity of epididymal parenchyma				0.60
Heterogeneous	125 (44.2)	82 (42.3)	43 (48.3)	
Uniform	103 (36.4)	72 (37.1)	31 (34.8)	
Unclear results	55 (19.4)	40 (20.6)	15 (16.9)	
Epididymal blood flow				0.77
Abundant	66 (23.3)	45 (23.2)	21 (23.6)	
Normal	104 (36.7)	69 (35.6)	35 (39.3)	
Absent or loss	55 (19.4)	37 (19.1)	18 (20.2)	
Disappear or not clear	58 (20.5)	43 (22.2)	15 (16.9)	
Testicular parenchymal echo				0.15
Heterogeneous	123 (43.5)	86 (44.3)	37 (41.6)	
Uniform	153 (54.1)	101 (52.1)	52 (58.4)	
Unclear results	7 (2.47)	7 (3.61)	0	
Testicular blood flow				0.23
Abundant	24 (8.48)	17 (8.76)	7 (7.87)	
Normal	145 (51.2)	94 (48.5)	51 (57.3)	
Absent or loss	107 (37.8)	76 (39.2)	31 (34.8)	
Disappear or not clear	7 (2.47)	7 (3.61)	0	
Scrotal edema				0.91
Yes	60 (21.2)	42 (21.6)	18 (20.2)	
No/unknown	223 (78.8)	152 (78.4)	71 (79.8)	
Spermatic cord				0.54
Torsion or enlarged	25 (8.83)	19 (9.79)	6 (6.7)	
Normal	258 (91.2)	175 (90.2)	83 (93.3)	
Testicular microlithiasis				0.45
Yes	19 (6.71)	15 (7.73)	4 (4.5)	
No	264 (93.3)	179 (92.3)	85 (95.5)	
Lifting pain				0.33
Yes	35 (12.4)	21 (10.8)	14 (15.7)	
No/unknown	248 (87.6)	173 (89.2)	75 (84.3)	

Table 1 (continued)

Table 1 (continued)

Factors	All (N=283)	Training cohort (N=194)	Validation cohort (N=89)	P
Cremasteric reflex				0.92
Disappear	37 (13.1)	26 (13.4)	11 (12.4)	
Exist	29 (10.2)	19 (9.79)	10 (11.2)	
Unclear	217 (76.7)	149 (76.8)	68 (76.4)	
Testicular sclerosis				0.76
Yes	123 (43.5)	86 (44.3)	37 (41.6)	
No	160 (56.5)	108 (55.7)	52 (58.4)	
Testicular swelling				0.50
Yes	105 (37.1)	75 (38.7)	30 (33.7)	
No	178 (62.9)	119 (61.3)	59 (66.3)	
High testicular position				0.55
Yes	20 (7.07)	12 (6.19)	8 (8.99)	
No	263 (92.9)	182 (93.8)	81 (91.0)	
Nausea vomiting				>0.99
Yes	18 (6.36)	12 (6.19)	6 (6.74)	
No	265 (93.6)	182 (93.8)	83 (93.3)	
Duration of symptoms (hours)	49.8 (55.4)	47.9 (51.4)	54.1 (63.4)	0.42

Data are presented as n (%) and means (standard deviations). NLR, neutrophil-lymphocyte ratio; PLR, platelet-lymphocyte ratio; MER, monocyte-eosinophil ratio; MPV, mean platelet volume.

reflex, testicular microlithiasis, testicular swelling, and high-positioned testis were factors affecting the occurrence of TT in patients with ASP. Subsequently, these risk factors were included in the multivariate logistic regression analysis, which revealed that laterality, neutrophils, MER, epididymal blood flow signals, testicular parenchymal echo texture, and testicular blood flow signals were independent risk factors influencing the occurrence of TT in pediatric patients with ASP (Table 2).

Development of the nomogram for predicting TT

Based on the independent risk factors selected through multivariate logistic regression analysis, we developed a nomogram to predict the probability of TT in pediatric patients with ASP. We found that side, neutrophil count, MER, epididymal blood flow signal on ultrasound, testicular parenchyma echo, and testicular blood flow signal were independent risk factors for predicting TT in children with scrotal emergency, and were included in the construction of

the final prediction model. As shown in Figure 2, patients with left-sided occurrence had a higher probability of TT, and those with weakened or absent epididymal blood flow signals, uneven testicular parenchymal echo texture, and weakened or absent testicular blood flow signals had a higher risk of TT.

Validation of the nomogram

We employed a series of validation methods to assess the accuracy and discriminative ability of the nomogram. The concordance index (C-index) results showed that the nomogram had a C-index of 0.981 [95% confidence interval (CI): 0.965–0.996] in the training set and 0.985 (95% CI: 0.962–0.997) in the validation set, indicating good discriminative ability. The AUC values for the training and validation sets also demonstrated the strong discriminative power of the nomogram (Figure 3). Furthermore, calibration curves were used to assess the accuracy of the model, and the results showed a high level of consistency

Table 2 Univariate and multivariate analyses in training cohort

Factors	Univariate			Multivariate		
	HR	95% CI	P	HR	95% CI	P
Location						
Urban	Reference					
Rural	2.010	0.930–4.350	0.08	–	–	–
Race						
Han nationality	Reference					
Ethnic minorities	1.350	0.580–3.140	0.49	–	–	–
Age	1.010	1.000–1.010	0.09	–	–	–
Laterality						
Left	Reference					
Right	0.370	0.210–0.670	0.001	23.061	4.184–127.115	0.001
Precipitating factor						
Conscious and no obvious trigger	Reference					
Sleep	0.690	0.340–1.390	0.30	–	–	–
After trauma or exercise	0.220	0.050–1.070	0.06	–	–	–
Neutrophils	1.550	1.330–1.800	0.001	0.702	0.558–0.882	0.002
Lymphocytes	0.860	0.720–1.020	0.08	–	–	–
NLR	1.780	1.410–2.250	0.001	–	–	–
Platelet	1.000	1.000–1.000	0.76	–	–	–
PLR	1.010	1.000–1.020	0.001	–	–	–
Monocytes	6.360	1.960–20.630	0.001	–	–	–
Eosinophils	0.020	0–0.260	0.001	–	–	–
MER	1.050	1.020–1.080	0.001	0.976	0.947–1.005	0.01
MPV	0.990	0.720–1.360	0.93	–	–	–
Basophils	0	0–0.250	0.03	–	–	–
C reactive protein, mg/L						
≤10	Reference					
>10	17,042,592.860	0–Inf	0.99	–	–	–
Urine routine white blood cells						
Positive	Reference					
Negative	0.780	0.330–1.810	0.56	–	–	–
Unknown	0.930	0.360–2.430	0.88	–	–	–

Table 2 (continued)

Table 2 (continued)

Factors	Univariate			Multivariate		
	HR	95% CI	P	HR	95% CI	P
Urinalysis red blood cells						
Positive	Reference					
Negative	0.810	0.290–2.230	0.68	–	–	–
Unknown	1.000	0.330–3.030	0.99	–	–	–
Epididymal size						
Enlargement	Reference					
Normal	0.710	0.350–1.440	0.34	–	–	–
Unclear results	6.920	2.670–17.920	0.001	–	–	–
Echogenicity of epididymal parenchyma						
Heterogeneous	Reference					
Uniform	0.530	0.270–1.010	0.050	–	–	–
Unclear results	4.200	1.730–10.200	0.001	–	–	–
Epididymal blood flow						
Abundant	Reference					
Normal	0.890	0.360–2.230	0.80	0.395	0.080–1.950	0.25
Absent or loss	126.000	15.310–1,036.840	0.001	23.500	2.100–265.500	0.003
Disappear or not clear	18.000	6.160–52.590	0.001	4.010	1.050–44.100	0.001
Testicular parenchymal echo						
Uniform	Reference					
Heterogeneous	0.06	0.030–0.120	0.001	9.166	2.681–31.339	0.001
Unclear results	1.370	0.150–12.200	0.78	4.412	0.120–162.295	0.42
Testicular blood flow						
Abundant	Reference					
Normal	1.420	0.290–6.880	0.66	0.055	0.006–0.53	0.01
Absent or loss	182.500	28.003–1,188.040	0.001	2.154	0.255–18.183	0.48
Disappear or not clear	45.000	3.410–594.140	0.001	1.254	1.102–2.785	0.004
Scrotal edema						
Yes	Reference					
No/unknown	1.100	0.560–2.180	0.78	–	–	–
Spermatic cord						
Torsion or enlarged	Reference					
Normal	0.160	0.040–0.560	0.001	–	–	–

Table 2 (continued)

Table 2 (continued)

Factors	Univariate			Multivariate		
	HR	95% CI	P	HR	95% CI	P
Testicular microlithiasis						
Yes	Reference					
No	2.070	0.680–6.290	0.20	–	–	–
Lifting pain						
Yes	Reference					
No/unknown	3.550	1.250–10.120	0.02	–	–	–
Cremasteric reflex						
Disappear	Reference					
Exist	0.010	0–0.100	0.001	–	–	–
Unclear	0.170	0.060–0.530	0.001	–	–	–
Testicular sclerosis						
Yes	Reference					
No	0.070	0.040–0.150	0.001	–	–	–
Testicular swelling						
Yes	Reference					
No	0.140	0.070–0.270	0.001	–	–	–
High testicular position						
Yes	Reference					
No	0.180	0.040–0.840	0.03	–	–	–
Nausea vomiting						
Yes	Reference					
No	0	0–Inf	0.99	–	–	–

HR, hazard ratio; CI, confidence interval; NLR, neutrophil-lymphocyte ratio; PLR, platelet-lymphocyte ratio; MER, monocyte-eosinophil ratio; MPV, mean platelet volume; Inf, infinity.

between the predicted and actual values in both the training and validation sets, confirming the model’s accuracy (Figure 4). We also plotted the AUC curves for the five factors related to the TWIST score (Figure S1). The C-index of the TWIST score was 0.878 (95% CI: 0.837–0.920) in the training set and 0.855 (95% CI: 0.802–0.908) in the validation set.

Strengths, Weaknesses, Opportunities and Threats (SWOT) analysis

The establishment of predictive models is of great strategic

significance in the selection of treatment options for children with acute scrotum. Through SWOT analysis, we will evaluate the strengths, weaknesses, opportunities, and threats of the program.

Strengths: (I) technical expertise—the team has leading data analysis technology, which provides a solid foundation for the accuracy of the prediction model. (II) Innovation ability—continue to pay attention to the trends of medical research to ensure that the prediction model always stays in the leading position. (III) Industry experience—the team has rich experience in the medical industry, and can accurately grasp the market demand and competition situation.

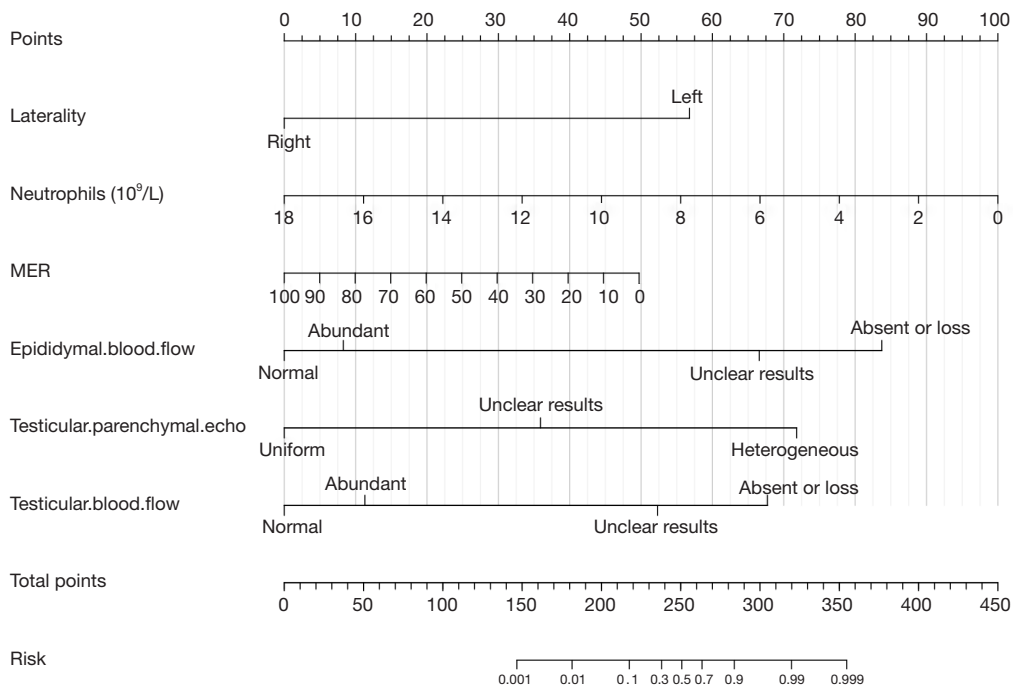


Figure 2 The nomograms for predicting TT in ASP patients. MER, monocyte-eosinophil ratio; TT, testicular torsion; ASP, acute scrotal pain.

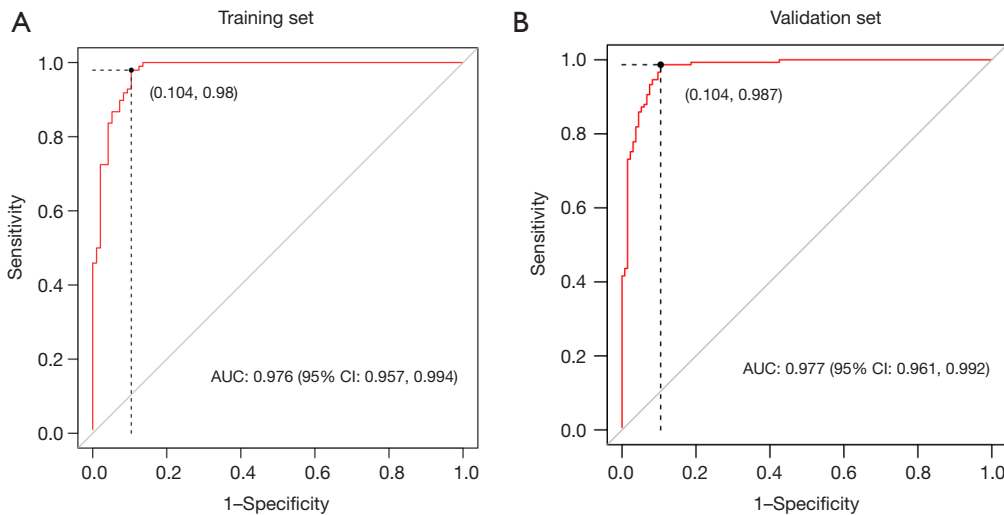


Figure 3 AUC for predicting TT in ASP patients. (A) The AUC for TT in the training set. (B) The AUC for TT in the validation set. The abscissa represents the FPR, and the ordinate represents the TPR. The dotted line in the figure indicates that the value corresponding to this point reaches the maximum area under the curve of the model. AUC, area under the curve; CI, confidence interval; TT, testicular torsion; ASP, acute scrotal pain; FPR, false positive rate; TPR, true positive rate.

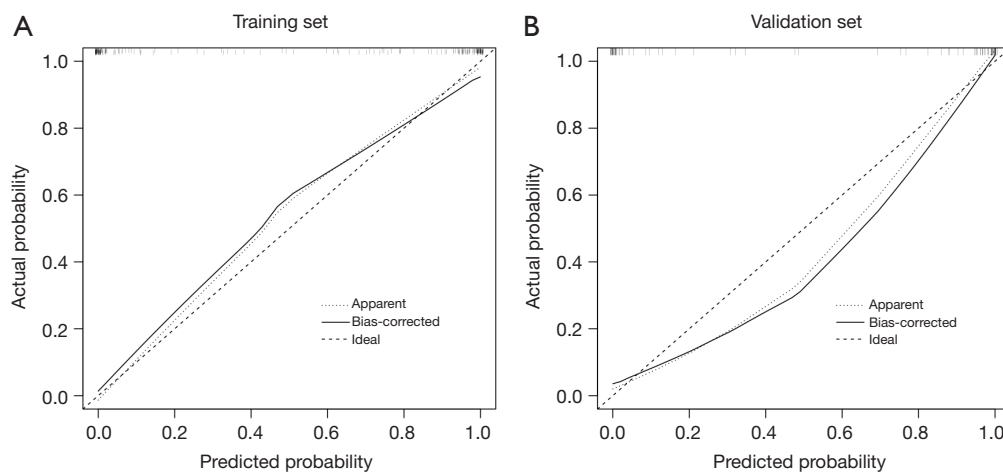


Figure 4 Calibration curve of the nomogram for predicting TT in ASP patients. (A) Calibration curve of the nomogram for predicting TT in the training set. (B) Calibration curve of the nomogram for predicting TT in the validation set. The horizontal axis is the predicted value in the nomogram, and the vertical axis is the observed value. TT, testicular torsion; ASP, acute scrotal pain.

Weaknesses: (I) data resource limitation—limited data sources may limit the training and prediction effect of the model. (II) High cost—data collection and processing require a large amount of resources. (III) Market awareness—the market awareness of the new model needs to be improved, and the marketing efforts need to be intensified.

Opportunities: (I) market demand growth—the public’s attention to children’s health issues has increased, and the market demand shows an increasing trend. (II) Technological progress—technological development provides possibilities for the improvement of model accuracy. (III) Policy support—may obtain policy support from the government or relevant institutions to promote the development of the project.

Threats: (I) competitors—other medical institutions may develop similar predictive models and become strong competitors. (II) Regulatory risk—regulatory changes may affect project implementation and promotion. (III) Technical risk—the emergence of new technologies may bring uncertainty, which may affect the stability and reliability of the model.

Discussion

Men of all ages may develop TT, but it is most common in children. The incidence of TT in men under 25 years old is about 1/4,000, and the incidence of left side is higher than that of right side (16). Long or absent gubernaculum

testis, high connection point between parietal layer of tunica vaginalis of testis and spermatic cord, resulting in “pendulum-like malformation”, cryptorchidism and other congenital dysplasia or malformations are risk factors for TT (17). Exercise and trauma may cause testicular compression or collision, excessive activity of the cremaster muscle induces torsion, vagus nerve excitation during sleep, and contraction or spasm of the cremaster muscle may induce TT (18).

This study retrospectively analyzed 283 cases of ASP in pediatric patients who underwent emergency exploratory surgery at our medical center. A nomogram was constructed to predict the probability of TT in ASP patients. It was found that left-sided occurrence decreased neutrophil count, decreased ratio of monocytes to eosinophils, heterogeneous testicular parenchymal echoes indicated by preoperative color flow Doppler (CFD) ultrasound examination, and weakened or absent blood flow signals in the testicles and epididymis were independent risk factors for predicting TT in ASP patients. Based on these factors, a nomogram was developed and validated using an internal and external validation set, confirming the model’s good predictive performance.

Laterality has been considered important in predicting TT. Rub *et al.*, through a study on the relationship between seasonal variation and TT, found that the occurrence of TT is closely associated with lower environmental temperatures (<15 °C), and left-sided torsion is more predominant in both children and adolescents (19). Marulaiah *et al.*, through a

12-year retrospective analysis at a single center, found that TT and testicular atrophy resulting from TT occurred more frequently on the left side (20). Similarly, Tanaka *et al.*, by collecting clinical information from 165 pediatric ASP patients at a single center, identified left-sided laterality as an independent risk factor for TT in ASP patients (21). Chang *et al.* also concluded that left-sided ASP is more likely to induce TT (22). Consistent with previous reports, this study found that left-sided ASP is more likely to lead to TT.

In recent years, hematological indicators have gradually become an important reference factor for diagnosing various diseases due to their reliable results, easy accessibility, and low-cost advantages. TT is no exception (15). In 2019, Yucel and other researchers conducted a retrospective multicenter study to clarify the application of hematological indicators in the differential diagnosis of TT and epididymal-orchitis. They found that compared to the normal control group, patients with ASP had significantly elevated neutrophil count, platelet count, leukocyte count, NLR, MER, and PLR values. Importantly, the predictive value of NLR for predicting TT reached a level similar to CDU (23). Yilmaz and others found through multivariate logistic regression analysis that monocyte count was the only factor significantly different between the TT and ASP groups (24). This study's smaller MER value indicated a higher likelihood of TT diagnosis. In addition, lower neutrophil count was associated with TT. This may be due to the fact that epididymo-orchitis is usually accompanied by a systemic inflammatory response such as fever, which in children with TT is usually not manifested or appears at an advanced stage of the disease. Interestingly, there are significant differences in the results reported by the existing studies of hematological indicators. This may be related to the limited reports of relevant studies and the insufficient sample size of included patients. At the same time, there is a lack of relevant research reports on children (25).

CFD ultrasound has been recommended as the preferred examination for ASP due to its convenience, low cost, and high accuracy. Among them, high-frequency ultrasound is still the preferred imaging method, providing excellent sensitivity and specificity in diagnosing TT, epididymal-orchitis, and testicular appendage torsion (26). CDU can rapidly evaluate potential urogenital emergencies. Although grayscale imaging is helpful, CFD ultrasound is the preferred examination for imaging the scrotum and testicles (27). However, the diagnostic accuracy of ultrasound and the subjective judgment of the examiner

are closely related. In a retrospective study of ultrasound examination results in 215 patients with ASP, Hendrikx and others found a misdiagnosis rate of 2.33% (5/215) among ultrasound specialists (28). A meta-analysis involving 2,116 patients showed an overall sensitivity of 86% and specificity of 95% for CFD ultrasound in diagnosing TT (29). Studies have shown that the echo and blood flow signals of the testicles and epididymis are important factors in the initial diagnosis of TT (9,10,15). However, some researchers have reported different views. Tian and others found that although testicular blood flow signals have high sensitivity and specificity for imaging the affected testicle, they are not related to the prognosis of TT. However, the uneven echo of the testicular parenchyma should be taken seriously because it is a sign of persistent ischemia or necrosis of the testicular parenchyma tissue (30). This study found that the blood flow signals of the epididymis and testicles and the echo of the testicular parenchyma have good predictive value for the diagnosis of TT. Uneven echo of the testicular parenchyma and reduced or absent blood flow signals in the epididymis and testicles indicate a high possibility of TT, and active surgical exploration should be considered.

The TWIST score is a 7-point tool to assess ASP. The parameters include testicular swelling, hard testicle, high-riding testicle, absent cremasteric reflex, and nausea/vomiting. It is considered an important basis for clinicians to make initial judgments of TT during physical examination of pediatric patients before completing hematological and imaging examinations such as CFD ultrasound. It can effectively reduce reliance on examination and test results (31). Sheth and other researchers also found that low-risk patients under the TWIST score do not require an ultrasound to rule out torsion. High-risk patients can proceed directly to surgery, avoiding ultrasound examinations in over 50% of patients (32). However, Feng and others analyzed clinical presentations, physical examination, laboratory data, and CDU findings in 136 patients. They found that physical examination results are not risk factors for TT (17). Hisamatsu *et al.* also confirmed that although the TWIST score can diagnose TT, its clinical value is lower than ultrasound (33). This study found, through univariate logistic regression of the included factors, that apart from nausea/vomiting, the other four indicators in the TWIST score (increased reflex, testicular swelling, hard testicle, and high-riding testicle) are all associated factors in predicting TT. However, unfortunately, after balancing the interactions between multiple factors, none of the TWIST-related indicators

were included as independent risk factors for predicting TT occurrence in the multivariate logistic regression. The AUC curve and C-index were significantly lower than those of the predictive model we constructed. This indicates that our nomogram has better predictive performance than the traditional TWIST score. A physical examination can be the initial approach for ASP but cannot replace hematological and ultrasound examinations.

Our study has some limitations worth noting. Firstly, the retrospective design of this study may have inevitable recall and selection biases. Secondly, the number of cases included in our study is limited, and further large-sample and prospective multicenter studies are needed to validate the existing research results. However, our study has the largest number of pediatric ASP cases in the southwestern region of China and has certain representativeness and reference value.

Conclusions

In conclusion, this study collected clinical indicators of pediatric patients who visited Kunming Children's Hospital for ASP for 9 years and underwent surgical treatment. Logistic regression analysis was conducted to identify independent risk factors for TT and construct a nomogram. A series of validation methods were used to confirm the accuracy and discriminatory power of the nomogram. This study is the largest sample size reported for constructing a prediction model in southwestern China, and the validation results demonstrate the excellent performance of the constructed model. It can assist pediatric surgeons in the diagnosis and treatment of pediatric ASP.

Acknowledgments

Funding: This study was supported by Yunnan Education Department of Science Research Fund (Nos. 2023J0295, 2020J0228), Kunming City Health Science and Technology Talent "1000" Training Project [No. 2020-SW (Reserve)-112], Department of Science and Technology of Yunnan Province Kunming Medicine Joint Special Project (No. 202301AY070001-108), Famous Doctors of Yunnan Province "Xingdian Talents Support Program" (No. XDYC-MY-2022-0096), and Open Research Fund of Clinical Research Center for Children's Health and Diseases of Yunnan Province (No. 2022-ETYY-YJ-03). The funding bodies played no role in the study's design and collection, data analysis and interpretation, and manuscript writing.

Footnote

Reporting Checklist: The authors have completed the TRIPOD reporting checklist. Available at <https://tau.amegroups.com/article/view/10.21037/tau-23-634/rc>

Data Sharing Statement: Available at <https://tau.amegroups.com/article/view/10.21037/tau-23-634/dss>

Peer Review File: Available at <https://tau.amegroups.com/article/view/10.21037/tau-23-634/prf>

Conflicts of Interest: All authors have completed the ICMJE uniform disclosure form (available at <https://tau.amegroups.com/article/view/10.21037/tau-23-634/coif>). The authors have no conflicts of interest to declare.

Ethical Statement: The authors are accountable for all aspects of the work in ensuring that questions related to the accuracy or integrity of any part of the work are appropriately investigated and resolved. This study was approved by the Ethics Committee of Kunming Children's Hospital (No. 2023-03-101-K01). Our study was conducted in accordance with the Declaration of Helsinki (as revised in 2013). Furthermore, this study is retrospective and did not use identifiable information from the patients. Therefore, informed consent from the parents/guardians of children was not required.

Open Access Statement: This is an Open Access article distributed in accordance with the Creative Commons Attribution-NonCommercial-NoDerivs 4.0 International License (CC BY-NC-ND 4.0), which permits the non-commercial replication and distribution of the article with the strict proviso that no changes or edits are made and the original work is properly cited (including links to both the formal publication through the relevant DOI and the license). See: <https://creativecommons.org/licenses/by-nc-nd/4.0/>.

References

1. Jefferies MT, Cox AC, Gupta A, et al. The management of acute testicular pain in children and adolescents. *BMJ* 2015;350:h1563.
2. Ford KE, Cooper LL, Thenabadu S. Acute testicular pain in children: collaboration in timely management. *Eur J Emerg Med* 2015;22:55-7.
3. Lewis AG, Bukowski TP, Jarvis PD, et al. Evaluation of

- acute scrotum in the emergency department. *J Pediatr Surg* 1995;30:277-81; discussion 281-2.
4. Keays M, Rosenberg H. Testicular torsion. *CMAJ* 2019;191:E792.
 5. Zhang X, Zhang J, Cai Z, et al. Effect of unilateral testicular torsion at different ages on male fertility. *J Int Med Res* 2020;48:300060520918792.
 6. Thakkar HS, Yardley I, Kufeji D. Management of Paediatric Testicular Torsion - Are we adhering to Royal College of Surgeons (RCS) recommendations. *Ann R Coll Surg Engl* 2018;100:397-400.
 7. Zhao LC, Lautz TB, Meeks JJ, et al. Pediatric testicular torsion epidemiology using a national database: incidence, risk of orchiectomy and possible measures toward improving the quality of care. *J Urol* 2011;186:2009-13.
 8. Hu S, Guo M, Xiao Y, et al. Mapping trends and hotspot regarding testicular torsion: A bibliometric analysis of global research (2000-2022). *Front Pediatr* 2023;11:1121677.
 9. Yu C, Zhao J, Lu J, et al. Demographic, clinical, and socioeconomic factors associated with delayed diagnosis and management of pediatric testicular torsion in West China: a retrospective study of 301 cases in a single tertiary children's hospital. *BMC Pediatr* 2021;21:553.
 10. Chen P, Yang Z, Chen N, et al. Diagnosis and treatment of cryptorchid testicular torsion in children: A 12-year retrospective study. *Front Pediatr* 2022;10:968997.
 11. Cao G, Li Y, Wang J, et al. Gleason score, surgical and distant metastasis are associated with cancer-specific survival and overall survival in middle aged high-risk prostate cancer: A population-based study. *Front Public Health* 2022;10:1028905.
 12. Zhanghuang C, Wang J, Yao Z, et al. Development and Validation of a Nomogram to Predict Cancer-Specific Survival in Elderly Patients With Papillary Renal Cell Carcinoma. *Front Public Health* 2022;10:874427.
 13. Wang J, Zhanghuang C, Jin L, et al. Development and validation of a nomogram to predict cancer-specific survival in elderly patients with papillary thyroid carcinoma: a population-based study. *BMC Geriatr* 2022;22:736.
 14. Takeshita H, Tachibana K, Sugiyama H, et al. Nomogram predicting testicular torsion in Japanese patients with acute scrotal pain using physical examination findings and environmental conditions: Development and prospective external validation. *Int J Urol* 2022;29:42-8.
 15. Chen P, Huang W, Liu L, et al. Predictive value of hematological parameters in testicular salvage: A 12-year retrospective review. *Front Pediatr* 2022;10:989112.
 16. Castañeda-Sánchez I, Tully B, Shipman M, et al. Testicular torsion: A retrospective investigation of predictors of surgical outcomes and of remaining controversies. *J Pediatr Urol* 2017;13:516.e1-4.
 17. Feng S, Yang H, Lou Y, et al. Clinical Characteristics of Testicular Torsion and Identification of Predictors of Testicular Salvage in Children: A Retrospective Study in a Single Institution. *Urol Int* 2020;104:878-83.
 18. Zvizdic Z, Aganovic A, Milisic E, et al. Duration of symptoms is the only predictor of testicular salvage following testicular torsion in children: A case-control study. *Am J Emerg Med* 2021;41:197-200.
 19. Rub R, Lidawi G, Laukhina E, et al. Impact of seasonal variations on incidence and laterality of testicular torsion. *Int J Biometeorol* 2023;67:857-63.
 20. Marulaiah M, Gilhotra A, Moore L, et al. Testicular and paratesticular pathology in children: a 12-year histopathological review. *World J Surg* 2010;34:969-74.
 21. Tanaka K, Ogasawara Y, Nikai K, et al. Acute scrotum and testicular torsion in children: a retrospective study in a single institution. *J Pediatr Urol* 2020;16:55-60.
 22. Chang CD, Lin JW, Lee CC, et al. Acute Epididymo-orchitis-Related Global Testicular Infarction: Clinical and Ultrasound Findings With an Emphasis on the Juxta-epididymal String-of-Bead Sign. *Ultrasound Q* 2016;32:283-9.
 23. Yucel C, Ozlem Ilbey Y. Predictive value of hematological parameters in testicular torsion: retrospective investigation of data from a high-volume tertiary care center. *J Int Med Res* 2019;47:730-7.
 24. Yilmaz M, Sahin Y, Hacibey I, et al. Should haematological inflammatory markers be included as an adjuvant in the differential diagnosis of acute scrotal pathologies? *Andrologia* 2022;54:e14374.
 25. Delgado-Miguel C, García A, Muñoz-Serrano AJ, et al. The role of neutrophil-to-lymphocyte ratio as a predictor of testicular torsion in children. *J Pediatr Urol* 2022;18:697.e1-6.
 26. Gupta A, Dogra V. Role of color flow Doppler ultrasound in the evaluation of acute scrotal pain. *Andrology* 2021;9:1290-7.
 27. Atkinson GO Jr, Patrick LE, Ball TI Jr, et al. The normal and abnormal scrotum in children: evaluation with color Doppler sonography. *AJR Am J Roentgenol* 1992;158:613-7.
 28. Hendrikx AJ, Dang CL, Vroegindeweij D, et al. B-mode and colour-flow duplex ultrasonography: a useful adjunct

- in diagnosing scrotal diseases? *Br J Urol* 1997;79:58-65.
29. Ota K, Fukui K, Oba K, et al. The role of ultrasound imaging in adult patients with testicular torsion: a systematic review and meta-analysis. *J Med Ultrason* (2001) 2019;46:325-34.
 30. Tian XM, Tan XH, Shi QL, et al. Risk Factors for Testicular Atrophy in Children With Testicular Torsion Following Emergent Orchiopexy. *Front Pediatr* 2020;8:584796.
 31. Qin KR, Qu LG. Diagnosing with a TWIST: Systematic Review and Meta-Analysis of a Testicular Torsion Risk Score. *J Urol* 2022;208:62-70.
 32. Sheth KR, Keays M, Grimsby GM, et al. Diagnosing Testicular Torsion before Urological Consultation and Imaging: Validation of the TWIST Score. *J Urol* 2016;195:1870-6.
 33. Hisamatsu E, Haruna A, Sugita Y, et al. Validation of testicular workup for ischemia and suspected torsion score in patients with acute scrotum. *J Pediatr Urol* 2022;18:684-90.

Cite this article as: Zhanghuang C, Wang J, Hang Y, Ji F, Yao Z, Mao R, Wang Z, Yao G, Liu L, Yan B. A novel nomogram to predict testicular torsion in children with acute scrotal pain: a single-center retrospective study in western China. *Transl Androl Urol* 2024;13(5):776-791. doi: 10.21037/tau-23-634

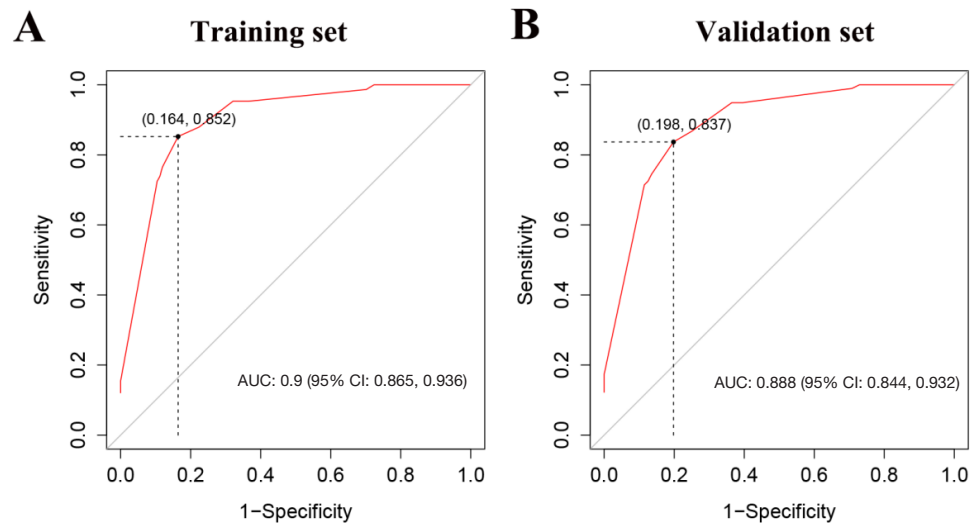


Figure S1 AUC for TWIST score to predicting TT in ASP patients. (A) The AUC for TWIST score in the training set. (B) The AUC for TWIST score in the validation set. AUC, area under the curve; CI, confidence interval; TWIST, Testicular Workup for Ischemia and Suspected Torsion; TT, testicular torsion; ASP, acute scrotal pain.