



Trichobezoar with acute necrotizing pancreatitis: a case description

Jie Ma[^], Guanqiao Jin[^]

Department of Radiology, Guangxi Medical University Cancer Hospital, Nanning, China

Correspondence to: Guanqiao Jin, PhD. Department of Radiology, Guangxi Medical University Cancer Hospital, 71 Hedi Road, Nanning, China. Email: 1251840017@qq.com.

Submitted Dec 07, 2022. Accepted for publication Apr 14, 2023. Published online May 11, 2023.

doi: 10.21037/qims-22-1284

View this article at: <https://dx.doi.org/10.21037/qims-22-1284>

Introduction

Bezoars are foreign bodies in the gastrointestinal tract that increase in size by accretion of nonabsorbable food or fibers. The main types of gastrolithiasis are lactobezoars, phytobezoars, pharmacobezoars, and trichobezoars. Trichobezoars are relatively rare cases, often occurring in young females, with 90% of patients suffering from psychiatric disorders or abnormal fetishes (e.g., trichologia, trichophagy) (1). The condition is caused by a foreign body consisting of swallowed hair and undigested food debris. Trichobezoars are primarily limited to the stomach. However, in a few cases, the hairy mass could extend through the pylorus and into the duodenum, small intestine, and even colon by gastrointestinal peristalsis. This rare and severe condition of trichobezoar called Rapunzel syndrome was defined as a hairy ball extending at least into the jejunum by Vaughan in 1968 (2-4).

The initial size of the bezoar is small. As it increases in size, symptoms such as nausea, vomiting, anorexia nervosa, abdominal pain, weight loss, gastrointestinal bleeding, gastrointestinal perforation, gastrointestinal obstruction, and pancreatitis may occur. Trichobezoar diagnoses are based on detailed history taking and careful clinical examination. The underdiagnosis of trichobezoars is due to the physicians' low level of suspicion (1).

Pancreatitis is an infrequent complication of trichobezoar. To our knowledge, only ten such cases have been reported. We present a case of a child with trichobezoar complicated

with acute necrotizing pancreatitis and review the clinical presentation, imaging findings, and clinical management.

Case description

All procedures performed in this study were in accordance with the ethical standards of the institutional and/or national research committee(s) and with the Helsinki Declaration (as revised in 2013). Written informed consent was obtained from the patient's parents for publication of this case report and accompanying images. A copy of the written consent is available for review by the editorial office of this journal.

Medical history

An 8-year-old girl was admitted to the Guangxi Medical University Cancer Hospital because of 7 hours of fever and whole abdominal pain. She began to experience nausea and vomiting 4 years prior, accompanied by loss of appetite and epigastric pain, which resolved spontaneously after fasting. The girl's mother complained that the child had developed a habit of eating hair, fingernails, and toenails since the age of 1. The child was emotionally excited and liked to scratch her skin, which could lead to multiple ulcers and bleeding. One year prior, the child went abroad with her mother after her parents divorced and then lived with her stepfather. The symptoms above occurred more frequently and worsened compared with before. The duration of

[^] ORCID: Guanqiao Jin, 0000-0003-2142-9001; Jie Ma, 0000-0002-5830-3261.

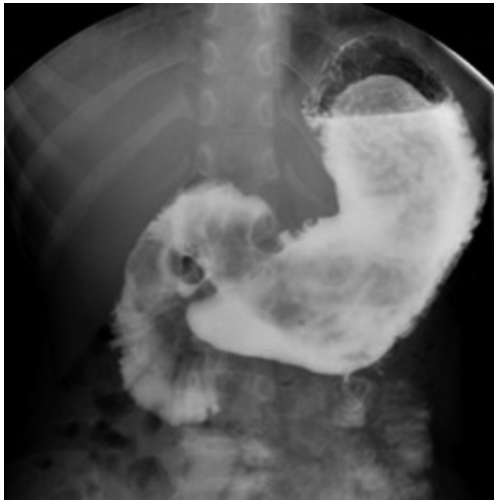


Figure 1 Gastrointestinal tract radiography imaging. Multiple filling defects in the gastric body and sinus region.

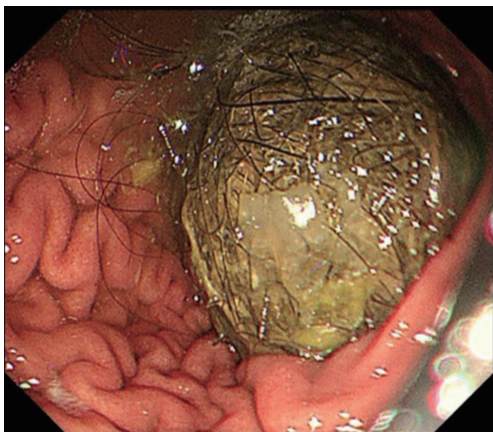


Figure 2 Gastroscopy image. Gastric stone in the body of the stomach.

symptoms was longer than before, lasting 7–10 days. The foreign family doctor advised her to drink more water to promote defecation, but those symptoms did not improve significantly. The child had been a picky eater for a long time and had lost approximately 5 kg in weight the previous year.

Physical examination and laboratory tests

The patient had an acute ill-looking and anemic appearance. Physical examination on admission revealed that the abdomen was distended, with guarding, rigidity,

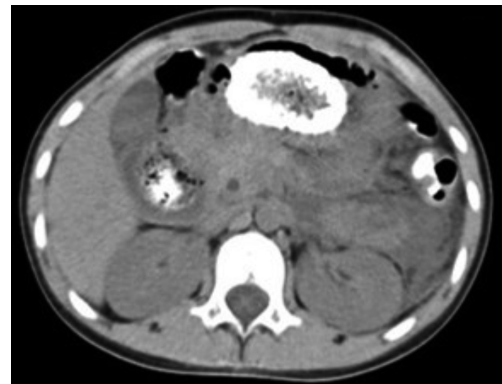

Figure 3 CT scan imaging. Plain scan imaging shows mixed high-density and gas-density masses in the gastric body and pylorus. CT, computed tomography.

tenderness, and rebound tenderness. The bowel sounds were hypoactive. Laboratory investigations showed increased leukocytosis (21.23×10^9 cells/L), neutrophilia (90.5%), serum amylase (720 U/L), lipase (911 U/L), and C-reactive protein (6.9 mg/L).

Upper gastrointestinal tract radiography was performed initially and showed several small planes of liquid and gas on standing abdominal fluoroscopy. The gastric mucosa was thickened and disturbed. Multiple round-like or irregular filling defects were observed in the gastric body, sinus, pylorus, and duodenal bulb (*Figure 1*), with irregular patches and spots of contrast medium coating on the surface of the filling defect. The position variation of those defects appeared with postural changes. The contrast agent passed slowly, and the pyloric canal slightly enlarged. Gastrointestinal tract radiography was considered a high probability for trichobezoar.

Gastroscopy showed a vast yellow-green gastric stone with many strands of tangled hair on the surface (*Figure 2*) extending from the gastric body and sinus to the descending duodenum. The pylorus was deformed with poor peristalsis and surrounded by flaky shallow ulcers, draped with white moss, and swollen surrounding mucosa.

A computed tomography (CT) enhancement scan showed multiple mixed-density masses (–106 to 68 HU) in the gastric lumen and duodenal intestinal canal appearing as round-like mixed gas-density and low-density masses enclosed by a high-density region (*Figure 3*). The pancreas was diffusely enlarged, and the tail of the pancreas was heterogeneously dense with blurred margins and peripancreatic fat. Fluid accumulated around the tail

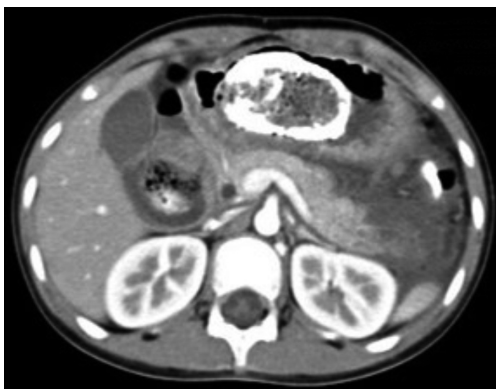

Figure 4 CT scan imaging. Enhancement scan imaging shows heterogeneous density and blurred margins of the pancreatic tail with blurred peripancreatic fat and fluid accumulation. CT, computed tomography.

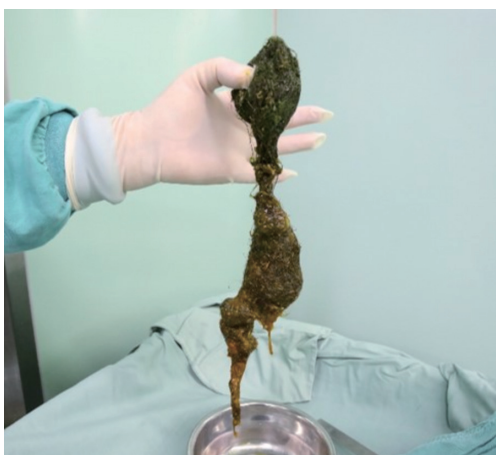

Figure 5 Surgical gross pathology. Foreign bodies such as hair and nails form a short “tail” distally.

of the pancreas. On the contrast-enhanced CT scan, the pancreatic tail was heterogeneously enhanced, and the left prerenal fascia was thickened (*Figure 4*). CT examination confirmed the diagnosis of trichobezoar and acute necrotizing pancreatitis.

Treatment

Considering the large size of the bezoar combined with acute necrotizing pancreatitis, the decision was to proceed with exploratory laparotomy, surgical removal of the bezoars, and intraoperative gastroscopy with the placement

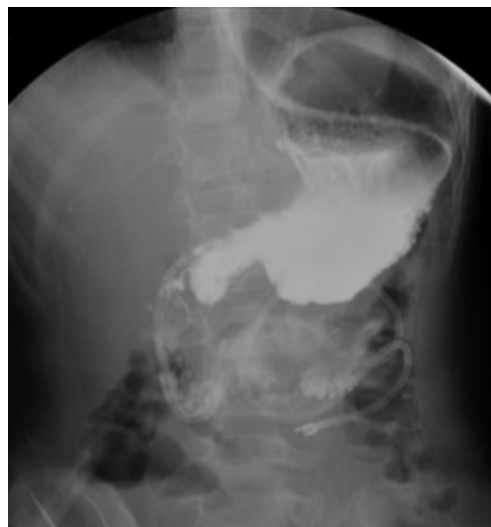

Figure 6 Postoperative gastrointestinal tract radiography imaging. No filling defect in the stomach or duodenum.

of a triple-lumen feeding tube. Intraoperative exploration of the stomach and duodenum showed marked dilatation. The pancreatic tail was found to be blackened and necrotic, measuring 3 cm × 4 cm in size, with exudation and no active bleeding. There were many saponified spots in the greater omentum and a small amount of yellowish-white fluid in the pelvis. The gastric stone weighed approximately 1 kilogram (*Figure 5*). Upper gastrointestinal tract radiography was performed postoperatively with no evidence of filling defects or contrast leakage (*Figure 6*). The patient did not have any signs of wound infection or complications postoperatively.

Discussion

Trichobezoar is rare and may be combined with various complications; thus, it is critical to select appropriate examinations to fully evaluate the condition of patients with suspected trichobezoar. Endoscopy is regarded as the most definitive examination for diagnosing trichobezoar, but it is invasive and uncomfortable, which makes it unsuitable for children unless anesthesia is used. Gastrointestinal tract radiography can outline the general shape and mobility of the bezoar and show gastrointestinal peristalsis and obstruction. CT displays the density mixing pattern of bezoars and identifies any comorbidities (5). Ultrasound and magnetic resonance imaging are of limited significance due to the effect of the gas. In this case, emergency

contrast-enhanced CT was performed immediately after gastrointestinal tract radiography because the patient had increased abdominal pain and elevated leukocytes and blood amylase. The CT scan showed the gastric stone as a rounded mass with mixed high-density and gas-density areas owing to the residual gastrografin on the surface of the gastric stone. CT without previous gastrointestinal tract radiography usually shows a mass of soft tissue density (generally less than 100 HU) interspersed with patches of low-density gas. Gastrografin improves the contrast between the gastric stone and the rest of the gastric contents on CT images and helps clarify the diagnosis and extension of bezoars.

We gained some valuable experience from this case. When patients with abdominal pain and upper gastrointestinal obstruction present to the clinic, gastrointestinal tract radiography may be the preferred option to rule out acute abdominal conditions such as intestinal obstruction and perforation and to display gastrointestinal tract function. Filling defects in the gastric could suggest the initial diagnosis of trichobezoar. Moreover, gastrointestinal tract radiography is essential to comprehensive preoperative imaging and postoperative radiographic evaluation, as gastrointestinal tract radiography rather than CT is often performed after surgery, especially for surgical patients with risks of anastomotic leak. If clinical symptoms and laboratory tests suggest suspected trichobezoar with other complications, enhanced CT can be performed after gastrointestinal imaging. Such an examination sequence not only clarifies whether trichobezoars are combined with other conditions but also increases the detection rate of bezoars (the surface covered with high-density contrast has a more apparent suggestive effect, especially for inexperienced radiologists). In addition, endoscopic examination is performed depending on the patient's tolerance, and endoscopic procedures are performed simultaneously when the bezoar is small.

Pancreatitis is an infrequent complication of trichobezoars. Trichobezoar-caused pancreatitis is usually induced by the bezoar blocking the opening of the pancreatic duct or inflammatory irritation causing major duodenal papilla edema leading to partial reflux of bile into the pancreatic duct (6). The former mechanism may better explain the cause of pancreatitis in this case, as the surgeon found the bezoar to be blocking the opening of the pancreatic duct. Several studies found that the altered biochemical parameters returned to normal after surgical removal of the bezoar, suggesting a causal relationship (7,8).

Treatment of trichobezoar includes surgical extraction, endoscopic lithotripsy, and chemical lithotripsy. Endoscopic procedures are only suitable for small bezoars or those that can be dissected and removed with multiple repetitions of endoscopy. Patients with Rapunzel syndrome may require multiple gastrotomies, and it is difficult to remove all the hairs completely and safely. In this case, because the bezoar was too large to remove by endoscopy and laparoscopy, it had to be removed by opening the retroperitoneum, which would simultaneously manage the pancreatitis. Notably, this patient requires aggressive behavioral intervention and psychological treatment to avoid re-emergence of the disease (4,9).

Conclusions

Trichobezoar-caused pancreatitis is a rare case. Gastrointestinal tract radiography and subsequent contrast-enhanced CT can improve the detection rate of trichobezoars and determine the location of bezoars and complications. Recovery from pancreatitis caused by bezoars is smooth following surgical removal of bezoars. Psychiatric assessment may help to verify the mental disorder and prevent recurrence.

Acknowledgments

Funding: None.

Footnote

Conflicts of Interest: Both authors have completed the ICMJE uniform disclosure form (available at <https://qims.amegroups.com/article/view/10.21037/qims-22-1284/coif>). The authors have no conflicts of interest to declare.

Ethical Statement: The authors are accountable for all aspects of the work in ensuring that questions related to the accuracy or integrity of any part of the work are appropriately investigated and resolved. All procedures performed in this study were in accordance with the ethical standards of the institutional and/or national research committee(s) and with the Helsinki Declaration (as revised in 2013). Written informed consent was obtained from the patient's parents for publication of this case report and accompanying images. A copy of the written consent is available for review by the editorial office of this journal.

Open Access Statement: This is an Open Access article distributed in accordance with the Creative Commons Attribution-NonCommercial-NoDerivs 4.0 International License (CC BY-NC-ND 4.0), which permits the non-commercial replication and distribution of the article with the strict proviso that no changes or edits are made and the original work is properly cited (including links to both the formal publication through the relevant DOI and the license). See: <https://creativecommons.org/licenses/by-nc-nd/4.0/>.

References

1. Imran M, Sughra U, Khan A. Huge Gastric and Ileal Trichobezoars Causing Small Bowel Obstruction. *J Coll Physicians Surg Pak* 2018;28:63-65.
2. Altonbary AY, Bahgat MH. Rapunzel syndrome. *J Transl Int Med* 2015;3:79-81.
3. Vellaisamy R, Iyer S, Chandramohan SM, Harikrishnan S. Rapunzel syndrome with cholangitis and pancreatitis - A rare case report. *Open Med (Wars)* 2020;15:1137-42.
4. Gorter RR, Kneepkens CM, Mattens EC, Aronson DC, Heij HA. Management of trichobezoar: case report and literature review. *Pediatr Surg Int* 2010;26:457-63.
5. Hamid M, Chaoui Y, Mountasser M, Sabbah F, Raiss M, Hrorra A, Alaoui M, Ahallat M, Chaouch S, Ouazzani H. Giant gastric trichobezoar in a young female with Rapunzel syndrome: case report. *Pan Afr Med J* 2017;27:252.
6. AlQaseer A, AlHarmi RAR, AbuAli N, Ahmed M. Rare case of trichobezoar causing pancreatitis in a young woman. *BMJ Case Rep* 2019;12:e229173.
7. Suzuki N, Furuya R, Otsuka T, Miyazaki H, Okano H, Komatsu T, Yamada E, Yamaguchi Y. Acute pancreatitis caused by duodenal bezoar and treated with endoscopic procedures. *Acute Med Surg* 2022;9:e797.
8. Ebrahimian S, Ebrahimian S, Nadri S. Intraluminal bezoar caused obstruction and pancreatitis: A case report. *Clin Case Rep* 2019;7:1040-2.
9. Haggui B, Hidouri S, Ksia A, Oumaya M, Mosbahi S, Messaoud M, Youssef SB, Sahnoun L, Mekki M, Belghith M, Nouri A. Management of trichobezoar: About 6 cases. *Afr J Paediatr Surg* 2022;19:102-4.

Cite this article as: Ma J, Jin G. Trichobezoar with acute necrotizing pancreatitis: a case description. *Quant Imaging Med Surg* 2023;13(7):4737-4741. doi: 10.21037/qims-22-1284