Letter to the Editor

Comprehensive imaging analysis of a patient with neurofibromatosis type 1 combined with hypophosphatemic osteomalacia: a case description

Ying Liu[1,2#], Zhaoliang Zhang[3#], Meie Liang[1,2], Yang Liu[1,2], Na Zhang[1,2], Ke Xu[1,2]

[1]Department of Rheumatology and Immunology, Shanxi Bethune Hospital, Shanxi Academy of Medical Sciences, Tongji Shanxi Hospital, Third Hospital of Shanxi Medical University, Taiyuan, China; [2]Tongji Hospital, Tongji Medical College, Huazhong University of Science and Technology, Wuhan, China; [3]Department of Immunology, Shanxi Medical University, Taiyuan, China

[#]These authors contributed equally to this work.

Correspondence to: Ke Xu, MD. Department of Rheumatology and Immunology, Shanxi Bethune Hospital, No. 99 Longcheng Street, Taiyuan 030030, China. Email: zhaoxuke@hotmail.com.

Submitted Nov 04, 2022. Accepted for publication Apr 18, 2023. Published online May 19, 2023.
doi: 10.21037/qims-22-1217
View this article at: https://dx.doi.org/10.21037/qims-22-1217

Introduction

Neurofibromatosis type 1 (NF1), traditionally known as von Recklinghausen disease, is an autosomal dominant disorder of the nervous system caused by mutations in the *NF1* gene. Typical clinical symptoms of NF1 include café-au-lait spots, multiple neurofibromas, and axillary or inguinal freckles, with neurofibromas being one of the most common and characteristic symptoms.

Diagnosis of NF1 in clinical practice is based on the clinical criteria established by the National Institutes of Health (NIH) at the 1987 consensus conference. In 2021, the International Consensus Group on Diagnostic Criteria for Neurofibromatosis (I-NF-DC) proposed amendments to the NF1 diagnostic criteria developed in 1987, mainly adding genetic diagnosis (1).

Patients with NF1 have a 10–25% chance of developing skeletal deformities. Skeletal developmental deformities are common in neurofibromas; they appear early and are the result of mesodermal dysplasia nut are not associated with disturbances in calcium and phosphate metabolism. Conversely, hypophosphatemic osteochondrosis is rare in neurofibromas, often occurring in middle age, and is associated with this calcium and phosphate metabolism disorder.

Unlike skeletal abnormalities, hypophosphatemic osteomalacia is rarely encountered in NF1, with fewer than 50 such cases reported to date (2). These cases usually develop in late adulthood, and these patients often present with severe bone pain, muscle weakness, and fractures. The biochemistry usually reflects hypophosphatemia with normal or low calcium levels, elevated alkaline phosphatase, and increased urinary phosphate excretion. Imaging may reveal osteoporosis, multiple fractures and/or pseudofractures. The presence of multiple symmetrical pseudofractures (Looser's zone) has also been noted (3). We describe a patient with NF1 with hypophosphatemia, osteomalacia and elevated plasma fibroblast growth factor 23 (FGF23) but no neurofibroma.

Case presentation

A 23-year-old woman presented in October 2018 with a 2-year duration of progressive bone pain and difficulty in walking. At the age of 6, she began to develop café-au-lait spots on her back. The patient was in good health, without skeletal symptoms. Until the age of 21, she experienced progressive bone aches, affecting the chest, back and double hip joint, which worsened when walking and made it difficult to squat and stand up. She was bedridden 4 months prior to her presentation (*Figure 1*). Her mother was diagnosed with NF1 at the age of 20 with cutaneous

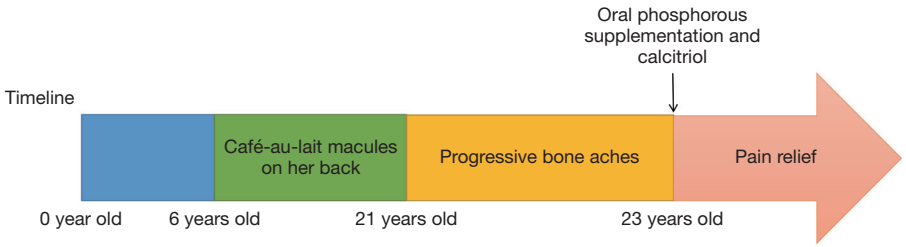

Figure 1 Timeline of relevant events in the patient's medical history.

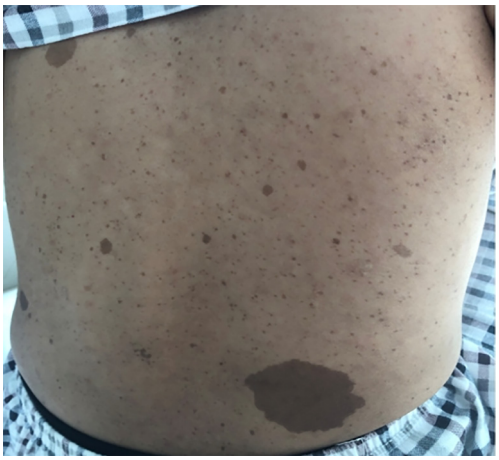

Figure 2 Café-au-lait spots over the patient's back.

neurofibroma without multisystem involvement. The patient was not visually or hearing impaired. The absence of systemic symptoms suggests malignancy. She had no history of kidney, liver, or gastrointestinal disease.

On physical examination, the female patient had medium stature (159 cm with body mass index of 20.57 cm/kg^2) with no neurofibromas on the face, trunk, and extremities. Numerous café-au-lait macules over 5 mm in greatest diameter were also observed over her back (*Figure 2*). The patient had scoliosis and positive tenderness in both hips. Neuromuscular examination was unremarkable.

The Laboratory data obtained at our institute were as follows: serum calcium 2.33 mmol/L (normal 2.11–2.52 mmol/L); serum phosphorus 0.52 mmol/L (normal 0.85–0.51 mmol/L); alkaline phosphatase level 286.4 IU/L (normal 35–100 IU/L); 24-hour urinary excretion of phosphorus 51.86 mmol/24 hours (normal 12.9–42 mmol/24 hours); 24-hour urinary excretion of calcium 2.6 mmol/24 hours (normal: 2.5–7.5 mmol/24 hours); 25-(OH) Vitamin D 10.8 ng/mL (normal 12.8–49 ng/mL); parathyroid hormone (PTH) level 71.6 pg/mL (normal: 12–88 pg/mL); and serum FGF23 (KingMed Diagnostics, China) 100 pg/mL (reference range: 23.3–95.4 pg/mL).

She had severe osteoporosis [Z score at the lumbar spine −3.7 and hip joint −3.0 on dual energy X-ray absorptiometry (DXA) scan]. A radiograph of the pelvis with the lumbar spine showed scoliosis of the lumbar spine, and the Cobb angle of the scoliosis was 8° (*Figure 3A*). A radiograph of the pelvis revealed pseudofractures (Looser's zone) in the bilateral femoral neck (*Figure 3B*). Bilateral hip computed tomography (CT) suggested bilateral femoral neck bone cortical discontinuity and a visible pseudofracture line (*Figure 3C*). Bilateral sacroiliac joint CT scans showed bilateral iliac flanges, symphysis pubic articular surfaces, and bilateral femoral neck cortex sparseness (*Figure 3D*). Whole-body bone scan showed fractured ribs on the left 1st rib, left 2nd rib and right 6th, 7th and 9th side (*Figure 3E*) and bead-like changes in the bilateral rib heads, and increased metabolism in the bilateral shoulder, elbow and sacroiliac joints (*Figure 4*). Positron emission CT revealed no signs of abnormal hypermetabolic tumors throughout the body. Whole-body MRI did not show plexiform neurofibroma.

Next-generation sequencing (Chigene Translational Medical Research Center. Ltd., China) revealed a genetic mutation in exon 17 of the *NF1* gene in the proband [c.1885(exon17)G>A]. She was diagnosed with NF1 due to pathognomonic cutaneous manifestations and a positive family history according to the revised diagnostic criteria for NF1 (1).

The combination of normal levels of and serum calcium and concomitant presence of low serum and increased urine secretion of phosphate, as well as the association with bone defects, led us to the diagnosis of HO. Excluding ketoacidosis, primary hyperparathyroidism, metabolic acidosis, and history of special medications, we diagnosed the patient with neurofibroma causing hypophosphatasia chondrodysplasia.

The patient was treated with oral phosphorous

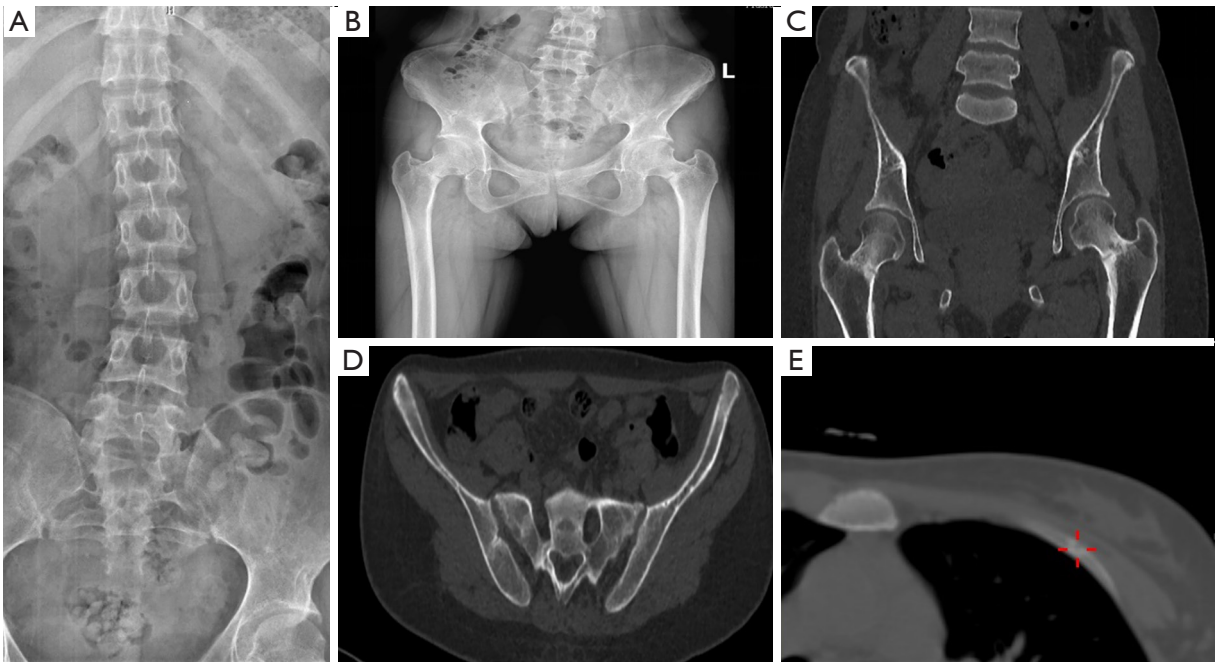

Figure 3 Imaging features of the patient. (A) Radiography of the pelvis with the lumbar spine showed scoliosis of the lumbar spine. (B) A radiograph of the pelvis showing pseudofractures (Looser's zone) in the pseudofracture in the bilateral femoral neck. (C) Computed tomography of both hips showed bilateral femoral neck pseudofracture lines. (D) Bilateral computed tomography of the sacroiliac joints revealed bilateral iliac wing margins, joint surfaces of the pubic symphysis and bilateral femoral neck osteochondral grossness. (E) Whole-body bone scanning indicated multiple rib fractures.

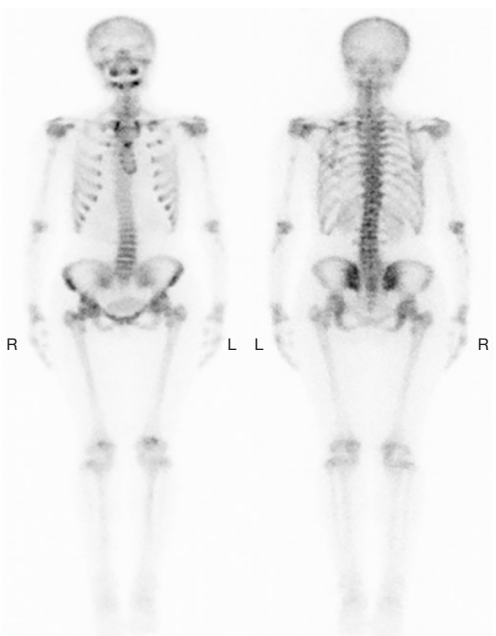

Figure 4 Whole-body bone scan showed bead-like changes in the bilateral rib heads and increased metabolism in the bilateral shoulder, elbow and sacroiliac joints.

supplementation (2 gm/d) and calcitriol (0.75 μg/d) in November 2018. The patient was then referred to the orthopedic department for closed reduction hollow nail internal fixation of bilateral pathological fractures of the femoral neck (*Figure 5A*). The patient was followed for 2 years, with semiannual follow-ups. There were no adverse or unanticipated events. After two months, her symptoms improved considerably, and she is currently ambulatory without requiring any support and able to perform her daily activities. After one year, laboratory findings also demonstrated a significant decline in her plasma levels of phosphatase (50 IU/L) and slight improvement in levels of serum phosphorus (0.8–1.2 mmol/L). Radiological healing of osteomalacia was noted (*Figure 5B,5C*). A repeat DXA scan in April 2022 showed marked improvement in BMD (Z score –2.8 at the lumbar spine).

All procedures performed in this study were in accordance with the ethical standards of the Medical Ethics Committee of Bethune Hospital in Shanxi Province (No. YXLL-2022-114) and with the Helsinki Declaration (as revised in 2013). Written informed consent was obtained from the patient for publication of this case report and

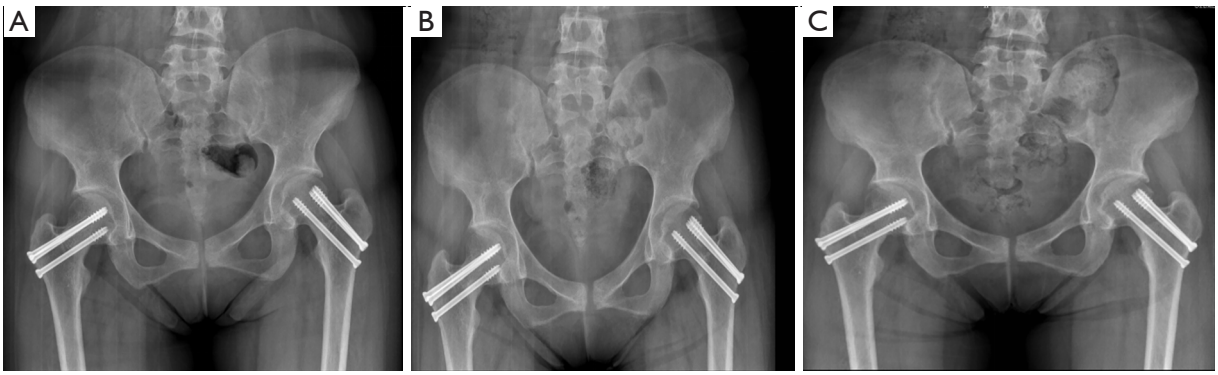

Figure 5 X-ray follow-up after 2 years of treatment. (A) The patient was then referred to the orthopedic department for closed reduction hollow nail internal fixation of bilateral pathological fractures of the femoral neck on December 5, 2019. (B) Pelvic orthostasis revealed no pseudofracture in the bilateral femoral neck on September 8, 2020. (C) Pelvic orthostasis revealed no pseudofracture in the bilateral femoral neck on February 8, 2022.

accompanying images. A copy of the written consent is available for review by the editorial office of this journal.

Discussion

We present a patient with hypophosphatemic osteochondrosis in NF1 who had elevated plasma FGF23 levels.

In 1918, Grould *et al.* first reported patients with NF1 combined with hypophosphorous chondromalacia, but hypophosphatemic osteomalacia is rarely encountered in NF1, with fewer than 40 such cases reported until 1990 (4). We collected a total of 10 cases from 1990 to 2022 from PubMed using the keywords "neurofibromatosis type 1" and "hypophosphoric chondromalacia". The results are summarized in *Table 1*.

These patients tend to be middle-aged at the time of onset. The most common clinical symptom is bone pain. Some patients may experience unstable walking, muscle weakness and shorter height. Their biochemistry typically reflects hypophosphatemia with normal or low calcium levels, elevated alkaline phosphatase (ALP), and increased urinary phosphate excretion.

A skeletal survey with plain radiographs demonstrated sparse and blurred bone with a hairy glassy appearance. There is a tendency toward development of skeletal deformities with inversion or valgus of the knee, a trilobar pelvis with acetabular invagination (6,9,10), biconcave deformity of the upper and lower edges of the vertebrae (5,10) and kyphosis. Adult patients with hypophosphatemic osteochondrosis often present with early-onset osteoarthritis of the spine, hip and knee (osteochondrosis or thinning of articular cartilage at the joint margins) and/or attachment point disease (e.g., osteophytes or calcification of ligaments at the site of ligament attachment). Osteochondrosis-related fractures are also not uncommon. The most characteristic is pseudofracture (4-6,9,10) in a striped hyaline area called Looser's zone, which is usually symmetrically distributed.

X-rays and bone imaging may suggest osteoporosis, scoliosis, bead-like changes in the ribs, multiple rib, bilateral iliac, pubic and femoral neck fractures, which need to be differentiated from metabolic bone diseases such as primary osteoporosis, hyperparathyroidism and low phosphorus osteochondrosis (11). Primary osteoporosis is most commonly seen in elderly and menopausal women, with reduced blood calcium on laboratory tests and compression fractures in weight-bearing areas such as the lower thoracic and lumbar spine on imaging, none of which were consistent in this case. Primary hyperparathyroidism presents with markedly increased PTH, hypercalcemia and osteoporosis. In severe cases, imaging may reveal characteristic changes such as fibrous osteitis, brown tumors, pathological fractures, ectopic calcification and superb bone imaging. Hypophosphatemia is a group of diseases characterized by poor bone mineralization, osteochondrosis or rickets caused by hypophosphatemia and insufficient active vitamin D (12). Clinical manifestations include widespread bone pain and muscle weakness, low blood phosphorus, high urinary phosphorus and elevated ALP in laboratory tests, and normal blood calcium; imaging may reveal osteoporosis, multiple fractures and/or pseudofractures. The clinical symptoms, laboratory tests and imaging findings in this case support the diagnosis of hypophosphatasia osteochondrosis.

Table 1 PubMed literature review (1990–2022) on cases and treatment

References	N	Age, years	Sex	Serum phosphate, mg/dL	PTH	Serum FGF23, pg/mL	Serum 25OH-Vitamin D, ng/dL	NF1	Skeletal symptoms	Imaging	Treatment
Kaspiris *et al.*, 2022, Greece (2)	1	29	F	1.8 (range, 2.5–4.5)	Normal	–	Normal	Multiple facial cutaneous nodules	Progressive bone aches, muscle weakness	Moderate periosteal, endosteal reactions with cortical thickening, stress fracture, Scoliosis of the thoracic spine	Phosphorous supplementation (2.0 g/d) + calcitriol (1 mg/d)
Makhlouf *et al.*, 2021, Tunisia (5)	1	67	M	0.51	PTH levels were six times normal	–	Normal	Café-au-lait spots, multiple cutaneous neurofibromas	Progressive bone pain and difficulty walking	Hypertransparent fuzzy bone structure at the pelvis and Looser's zone fractures of the upper shafts of both femurs, biconcave vertebrae	High-dose calcitriol and oral phosphate
Sahoo *et al.*, 2019, Japan (6)	1	34	F	1.6 (range, 2.5–4.5)		112 and 150 (reference range, 10–50)	53 (range, 16–53)	widespread neurofibromas	Low-back pain, generalized bony aches, height loss of 32 cm progressive bowing of all 4 extremities	Fractures at neck of femur, multiple pseudofractures in the long bones and both hands, bowing of long bones, tri-radiate pelvis and kyphoscoliosis	Phosphorous supplementation (1.0 g/d) + calcitriol (0.5 mg/d)
Obo *et al.*, 2020, Japan (7)	1	65	F	1.9 (range, 2.7–4.6)	123 (range, 10–65)	57.0 (<30)	14.0 (range, 20–60)	Neurofibroma	Chest pain	Spinal compression fracture, multiple rib fractures	Phosphorous supplementation + calcitriol
Nagaratnam, 2020, Malaysia (8)	1	44	F	0.31–0.56	46.4	–	25	Café au lait patches and numerous small neurofibromas	Bone pain, progressive weakness	Fractured ribs, kyphoscoliosis with compression fracture of L1	A high dose of calcitriol and oral phosphate
Gupta *et al.*, 2015, India (9)	1	43	F	1.5 (range, 2.5–4.5)	Normal	–	Normal	Multiple cutaneous nodules	Progressive bone pain	Osteopenia, coarse trabeculations, Looser's zone pseudofractures, fractures, triradiate pelvis	–
Chadha *et al.*, 2009, India (10)	1	46	F	1.7 (range, 2.7–4.5)	70 (range, 10–69)	–	Normal	Multiple skin nodules and café au lait spots	Generalized aches and pains	Fracture, Looser's zone, resorption of multiple phalanges, triradiate pelvis, spine revealed a rugger Jersey spine with fish mouth vertebrae	Neutral phosphate 500 mg thrice daily + calcitriol at 0.25 mg thrice daily + l calcium 1 g twice daily
Weinstein *et al.*, 1990, USA (3)	1	61	F	1.5	2675 (<640)	–	25.5 (range, 15–64)	Multiple cafe-au-lait spots and cutaneous neurofibromas of the face and torso	Generalized bone pain, muscle weakness	Lumbar kyphosis, diffuse osteopenia	A single 50,000 U dose of ergocalciferol on Day 35 and an additional 100,000 U dose on Day 91

Table 1 (*continued*)

Table 1 (*continued*)

References	N	Age, years	Sex	Serum phosphate, mg/dL	PTH	Serum FGF23, pg/mL	Serum 25OH-Vitamin D, ng/dL	NF1	Skeletal symptoms	Imaging	Treatment
Konishi *et al.*, 1991, Japan (4)	1	40	F	1.02	0.4	–	14.5	Cafe au lait spots	Generalized bone pain	Mild dorsal kyphoscoliosis, triradiate shape pelvis, multiple Looser-Milkman's, pseudofractures, and ribs	Phosphate (1.2 g as elementary phosphorus per day in divided doses initially and increased to 2.12 g per day) and 1-a-hydroxy cholecalciferol (0.5 mg per day initially)

PTH, parathyroid hormone.

The mechanism by which NF1 leads to hypophosphatasia is unclear. Parathyroid overactivity has been reported to occur in some cases of NF1 secondary to osteomalacia (3,9). Secondary parathyroid overactivity may exacerbate increased renal tubular phosphorus excretion. Gupta *et al.* (9) speculated that putative melatonin deficiency in cases of NF 1 might play a role in the pathogenesis of hyperphosphatemia by decreasing sodium-phosphate cotransport, and increasing the level of cyclic adenosine monophosphate (cAMP), the inhibitory unantagonized effect of dopamine on phosphate reabsorption and glucocorticoid levels.

FGF23 may be involved in the pathogenesis of bone destruction and bone deformity of NF1 combined with low-phosphate chondropathy. Some studies (6,7) have found that patients with NF1 have elevated circulating FGF23. FGF23 mainly reduces renal phosphorus reabsorption by inhibiting expression of sodium-phosphorus cotransport proteins 2a and 2c (NaPi-2a and NaPi-2c) in proximal tubules of the kidney, leading to increased transrenal phosphorus loss. On the other hand, iFGF23 can inhibit production of active vitamin D-1,25(OH)2D by inhibiting hydroxylase and promoting the action of 24 hydroxylase, which in turn inhibits phosphorus absorption in the intestine (13). However, the source of the elevated FGF23 in neurofibromas is not clear.

Some mesenchymal tumors can be cryptic in bone and oversecrete fibroblast growth factor 23, leading to tumor-associated hypophosphorous bone chondrogenesis (14). Recent studies (7,15) have found that the elevated FGF is not caused by neurofibromas. Obo *et al.* (7) reported that tumor cells in neurofibroma tissues do not stain for FGF23 by IHC. No neurofibromas were found in our patient, but FGF-5 was elevated in her serum. A recent study showed that bone is the source of FGF23 in the Nf1 cKO mouse model (15). However, the exact mechanism is not yet known. Sahoo *et al.* (6) speculated that activation of *RAS* and its downstream signaling pathways in NF1 may result in excess and autonomous production of FGF23 from osteocytes and that *RAS* may be the missing link in some cases of FGF23-mediated hypophosphatemia.

Treatment involves daily pharmacological doses of phosphorus and 25-OH vitamin D, which corrects the disappearance of phosphatemia and bone pain. Clinical improvement is usually observed during the first 2 months of treatment while significantly increasing the calcification component of the bone for complete fracture healing and bone density restoration.

We present a patient with HO in NF1 who had elevated plasma FGF23 without neurofibromas. She exhibited typical bone defects and imaging manifestations, such as pseudofractures, rib fractures, scoliosis, and osteoporosis. However, our study was limited by the fact that the patient did not agree to undergo bone histopathology for FGF23 and that we did not dynamically monitor the patient for FGF23 during follow-up.

In conclusion, reports of NF1 combined with hypophosphatemic osteomalacia have been documented only rarely. FGF23 may be involved in the pathogenesis of bone destruction and bone deformity of NF1 combined with low-phosphate chondropathy. Imaging may reveal osteoporosis, multiple fractures and/or pseudofractures.

Acknowledgments

We would like to thank Guo Dongqiang of the Imaging Department of the Shanxi Bethune Hospital for his guidance in imaging.

Funding: This work was supported by grants from the National Natural Science Foundation of China (No. 81871292) and the Key Research and Development (R&D) Projects of Shanxi Province (No. 201803D31136).

Footnote

Conflicts of Interest: All authors have completed the ICMJE uniform disclosure form (available at https://qims.amegroups.com/article/view/10.21037/qims-22-1217/coif). The authors have no conflicts of interest to declare.

Ethical Statement: The authors are accountable for all aspects of the work in ensuring that questions related to the accuracy or integrity of any part of the work are appropriately investigated and resolved. All procedures performed in this study were in accordance with the ethical standards of the Medical Ethics Committee of Bethune Hospital in Shanxi Province (No. YXLL-2022-114) and with the Helsinki Declaration (as revised in 2013). Written informed consent was obtained from the patient for publication of this case report and accompanying images. A copy of the written consent is available for review by the editorial office of this journal.

References

1. Legius E, Messiaen L, Wolkenstein P, Pancza P, Avery RA, Berman Y, et al. Revised diagnostic criteria for neurofibromatosis type 1 and Legius syndrome: an international consensus recommendation. Genet Med 2021;23:1506-13.
2. Kaspiris A, Vasiliadis E, Melissaridou D, Iliopoulos ID, Papagelopoulos PJ, Savvidou OD. Hypophosphatemic osteomalacia in neurofibromatosis 1 associated with intracranial gliomas and congenital renal agenesis: A rare case report and review of the literature. J Orthop Case Rep 2022;12:23-9.
3. Weinstein RS, Harris RL. Hypercalcemic hyperparathyroidism and hypophosphatemic osteomalacia complicating neurofibromatosis. Calcif Tissue Int 1990;46:361-6.
4. Konishi K, Nakamura M, Yamakawa H, Suzuki H, Saruta T, Hanaoka H, Davatchi F. Hypophosphatemic osteomalacia in von Recklinghausen neurofibromatosis. Am J Med Sci 1991;301:322-8.
5. Makhlouf Y, Boussaid S, Ajlani H, Jemmali S, Rekik S, Sehli H, Eleuch M. A Rare Case of Hypophosphataemic Osteomalacia in von Recklinghausen Neurofibromatosis. Eur J Case Rep Intern Med 2021;8:002618.
6. Sahoo SK, Kushwaha P, Bharti N, Khedgikar V, Trivedi R, Agrawal V, Ahmad N, Zaidi G, Pal L, Ito N, Bhatia E. Elevated FGF23 in a patient with hypophosphatemic osteomalacia associated with neurofibromatosis type 1. Bone 2019;129:115055.
7. Obo T, Koriyama N, Tokito A, Ogiso K, Nishio Y. Neurofibromatosis type 1 associated with hypophosphatemic osteomalacia due to hypersecretion of fibroblast growth factor 23: a case report. J Med Case Rep 2020;14:56.
8. Nagaratnam S, Karupiah M, Mustafa N. Debilitating Pain and Fractures: a Rare Case of Hypophosphatemic Osteomalacia with Concomitant Vitamin D Deficiency in Neurofibromatosis Type 1. J ASEAN Fed Endocr Soc 2020;35:105-8.
9. Gupta A, Dwivedi A, Patel P, Gupta S. Hypophosphatemic

osteomalacia in von Recklinghausen neurofibromatosis: Case report and literature review. Indian J Radiol Imaging 2015;25:63-6.
10. Chadha M, Singh AP, Singh AP. Hypophosphataemic osteomalacia in neurofibromatosis. Acta Orthop Belg 2009;75:847-50.
11. Chang CY, Rosenthal DI, Mitchell DM, Handa A, Kattapuram SV, Huang AJ. Imaging Findings of Metabolic Bone Disease. Radiographics 2016;36:1871-87.
12. Goldsweig BK, Carpenter TO. Hypophosphatemic rickets: lessons from disrupted FGF23 control of phosphorus homeostasis. Curr Osteoporos Rep 2015;13:88-97.
13. Martin A, David V, Laurence JS, Schwarz PM, Lafer EM, Hedge AM, Rowe PS. Degradation of MEPE, DMP1, and release of SIBLING ASARM-peptides (minhibins): ASARM-peptide(s) are directly responsible for defective mineralization in HYP. Endocrinology 2008;149:1757-72.
14. Chong WH, Molinolo AA, Chen CC, Collins MT. Tumor-induced osteomalacia. Endocr Relat Cancer 2011;18:R53-77.
15. Berglund JA, Gafni RI, Wodajo F, Cowen EW, El-Maouche D, Chang R, Chen CC, Guthrie LC, Molinolo AA, Collins MT. Tumor-induced osteomalacia in association with PTEN-negative Cowden syndrome. Osteoporos Int 2018;29:993-7.

Cite this article as: Liu Y, Zhang Z, Liang M, Liu Y, Zhang N, Xu K. Comprehensive imaging analysis of a patient with neurofibromatosis type 1 combined with hypophosphatemic osteomalacia: a case description. Quant Imaging Med Surg 2023;13(7):4777-4784. doi: 10.21037/qims-22-1217

