



# The application of contrast-enhanced ultrasound for sentinel lymph node evaluation and mapping in breast cancer patients

Yuanjian Fan<sup>1#</sup>, Jia Luo<sup>2#</sup>, Ying Lu<sup>2</sup>, Caixin Huang<sup>2</sup>, Manying Li<sup>2</sup>, Yunjian Zhang<sup>1</sup>, Nan Shao<sup>1</sup>, Shenming Wang<sup>1</sup>, Yanling Zheng<sup>2#</sup>, Ying Lin<sup>1#</sup>, Zhen Shan<sup>1#</sup>

<sup>1</sup>Breast Disease Center, The First Affiliated Hospital of Sun Yat-sen University, Guangzhou, China; <sup>2</sup>Department of Ultrasound, The First Affiliated Hospital of Sun Yat-sen University, Guangzhou, China

*Contributions:* (I) Conception and design: Z Shan, J Luo, Y Lu, Y Zheng; (II) Administrative support: Y Lin, S Wang; (III) Provision of study materials or patients: Y Lin, Y Zhang, N Shao, S Wang, J Luo, M Li, Y Zheng; (IV) Collection and assembly of data: Y Fan, C Huang; (V) Data analysis and interpretation: Y Fan, Z Shan; (VI) Manuscript writing: All authors; (VII) Final approval of manuscript: All authors.

#These authors contributed equally to this work.

*Correspondence to:* Zhen Shan, MD, PhD. Breast Disease Center, The First Affiliated Hospital of Sun Yat-sen University, No. 58, Zhong Shan Er Lu, Guangzhou 510080, China. Email: shanzh@mail.sysu.edu.cn; Ying Lin, MD, PhD. Breast Disease Center, The First Affiliated Hospital of Sun Yat-sen University, No. 58, Zhong Shan Er Lu, Guangzhou 510080, China. Email: linying3@mail.sysu.edu.cn; Yanling Zheng, MD, PhD. Department of Ultrasound, The First Affiliated Hospital of Sun Yat-sen University, No. 58, Zhong Shan Er Lu, Guangzhou 510080, China. Email: zhyanl@mail.sysu.edu.cn.

**Background:** To retrospectively investigate the application of contrast-enhanced ultrasound on sentinel lymph node (SLN-CEUS) for SLN evaluation and mapping in breast cancer patients.

**Methods:** Patients diagnosed with breast cancer at the First Affiliated Hospital of Sun Yat-sen University from June 2019 to March 2021 were conveniently evaluated by SLN-CEUS. The results of SLN-CEUS and B mode-ultrasound (BUS) were collected and compared. For patients who only underwent SLN-CEUS, we conducted a 1:1 propensity score matching (PSM). The diagnostic parameters, including sensitivity, specificity, positive predictive value (PPV), negative predictive value (NPV), false negative rate (FNR), false positive rate (FPR), and proportion of undetermined diagnoses were compared between the SLN-CEUS and BUS cohorts. The identification rate and FNR of sentinel lymph node biopsy (SLNB) were also assessed.

**Results:** There were 327 patients in each of the SLN-CEUS and BUS cohorts. Among the entire cohort, both NPV [90.2% (95% CI, 85.4–93.5%) *vs.* 83.5% (95% CI, 77.8–88.0%),  $P=0.048$ ] and accuracy [80.7% (95% CI, 76.5–85.0%) *vs.* 73.7% (95% CI, 68.9–78.5%),  $P<0.001$ ] of SLN-CEUS were significantly higher than those of BUS. In non-neoadjuvant treatment (NAT) patients, the NPV [94.7% (95% CI, 89.9–97.4%) *vs.* 85.5% (95% CI, 79.1–90.2%),  $P=0.007$ ] and accuracy [87.6% (95% CI, 83.2–92.0%) *vs.* 76.0% (95% CI, 70.4–81.5%),  $P<0.001$ ] of SLN-CEUS were significantly higher than those of BUS. In NAT patients, no difference in diagnostic efficacy was found. The proportion of undetermined diagnoses of SLN-CEUS was significantly lower than that of BUS (5.8% *vs.* 15.3%,  $P<0.001$ ). The identification rate of SLN-CEUS in overall patients, non-NAT patients, and NAT patients was 94.2%, 96.3%, and 89.9%, respectively. The FNR of SLNB with the blue-dye tracer in combination with SLN-CEUS in overall patients, non-NAT patients, and NAT patients was 7.3%, 4.0%, and 12.5%, respectively.

**Conclusions:** Compared to BUS, SLN-CEUS is a better technique for diagnosing SLNs in early breast cancer patients, showing superiority in multiple diagnostic parameters. However, the diagnostic value of SLN-CEUS in NAT patients is still undetermined. SLN-CEUS is a promising mapping method in SLNB, with a high identification rate and a low FNR when used in combination with a blue-dye tracer.

**Keywords:** Breast cancer; contrast-enhanced ultrasound (CEUS); sentinel lymph node (SLN)

Submitted Sep 01, 2022. Accepted for publication May 09, 2023. Published online Jun 15, 2023.

doi: 10.21037/qims-22-901

View this article at: <https://dx.doi.org/10.21037/qims-22-901>

## Introduction

Breast cancer is the most common cancer type in women, accounting for approximately 31% of female cancers (1). Sentinel lymph node biopsy (SLNB) has been widely used for staging the axilla in early breast cancer patients. The sentinel lymph node (SLN) is defined as the first lymph node that receives lymphatic flow from the primary tumor, and SLNB has been shown to be a safe, reliable, and precise method for evaluation of axillary lymph nodes pathological status, with minimal surgical trauma and complications (2-5). However, evaluating lymph nodes with imaging examination before surgery is still of great significance in our clinical practice.

Axillary B mode-ultrasound (BUS) is one of the most common technologies used for the evaluation of axillary lymph nodes status; however, BUS shows variable accuracy at different centers (6,7). Moreover, BUS is unable to distinguish a SLN from other axillary lymph nodes, which makes it difficult to locate and diagnose the SLN.

Recently, contrast-enhanced ultrasound on sentinel lymph node (SLN-CEUS) has shown promising results in the location and diagnosis of the SLN. The SLN-CEUS allows tracing of the lymphatic flow and the location of the SLN using a contrast agent. With advances in CEUS imaging, such as the patterns of enhancement and infusion, SLN-CEUS can also better describe axillary lymph nodes status. In previous studies, CEUS has been shown to be a reliable technology in lymph nodes evaluation and SLNs mapping (8-14); however, most studies have involved small sample sizes (sample sizes range from 72 to 217) and are lack of comparison with BUS. Besides, none of the studies have enrolled the patients who had received neoadjuvant treatments (NATs), which makes an unclear use of CEUS in NAT patients. Moreover, although previous studies have reported the identification rate of SLN-CEUS, few have reported on the false negative rate (FNR) of SLNB with SLN-CEUS mapping. In this retrospective study, we aimed to investigate the application of SLN-CEUS in axillary lymph nodes evaluation and mapping for SLNB in breast cancer patients. We present this article in accordance with the STARD reporting checklist (available at <https://qims.amegroups.com/article/view/10.21037/qims-22-901/rc>).

## Methods

### *Study design and patients*

Patients who were diagnosed with breast cancer and conveniently evaluated by SLN-CEUS at the First Affiliated Hospital of Sun Yat-sen University (FAH-SYSU, Guangzhou, China) from June 2019 to March 2021 were included. Three sonographers in the Department of Ultrasound at the FAH-SYSU reviewed the sonography results of all patients. The exclusion criteria were as follows: (I) patients with stage IV tumor grade; (II) patients who had not undergone axillary surgery at the center; (III) patients with unclear tumor-node-metastasis (TNM) status. Notably, patients who underwent NAT were also eligible. The study was conducted in accordance with the Declaration of Helsinki (as revised in 2013) and approved by the Clinical Research Ethics Committee of the First Affiliated Hospital, Sun Yat-sen University. Individual consent for this retrospective analysis was waived.

Clinical data were collected, including age, gender, surgical history of the breast or axilla, neoadjuvant status, TNM stage, surgery details, result of sonography, pathology information, and numbers of SLNs. The results of both SLN-CEUS and BUS from each patient were collected and compared. For patients who only received SLN-CEUS, we conducted a 1:1 propensity score matching (PSM) with the center's clinical database to minimize bias. The matching of baseline characteristics for PSM included age, gender, surgical history of the breast or axilla, neoadjuvant status, T stage, N stage, and TNM tumor stage grouping. A multivariate logistic regression model was used to assess the patients' propensity scores, with a caliper width of 0.02 in matching.

### *Working process of SLN-CEUS*

SLN-CEUS was performed before NAT and before surgery, and patients' clinical information were available to the sonographers. The working process of SLN-CEUS is detailed herein. First, sonographers generally evaluated the breast and axilla using BUS; the ultrasound systems included ACUSON Sequoia Redwood (Siemens Medical Systems, Erlangen, Germany) equipped with linear array

probes (10L4), Resona 7 (Mindray, Shenzhen, China) equipped with linear array probes (L9-3), iU22 (Phillips, Andover, MA, USA) equipped with linear array probes (L9-3). All scanners were equipped with contrast pulse sequences (CPS). To reduce microbubble destruction, low mechanical index values were applied (<0.15). Sonographers dissolved SonoVue (Bracco, Milan, Italy) in 3.0 mL normal saline to a compound contrast medium, and intradermally injected 0.5–1.0 mL of the contrast medium into the outer upper quadrant of the areola. After that, lymphatic flow was traced through the CPS. The first lymph node observed to be enhanced was defined as SLN. The direction of the lymphatic vessel and the localization of the SLN was marked on patients' skin, and the sonographers evaluated the metastatic status of the SLN according to the size, shape, enhancement patterns and other characteristics.

There were some equivocal results in both modalities, including 'unidentified' in the SLN-CEUS cohort, and 'undefined', 'enlargement', 'reduction', 'transformation after NAT', and 'suspect' in the BUS cohort. These equivocal results made diagnosis and treatment difficult, leading to overtreatment or missed diagnosis. Therefore, we defined the indicator 'proportion of undetermined results' which was regarded as one of the significant indicators in diagnosis.

$$\text{The proportion of undetermined results} = \frac{\text{Number of undetermined results}}{\text{Number of patients underwent SLN-CEUS or BUS}} \times 100\% \quad [1]$$

### *Surgical management*

Surgery was usually performed 1 day after SLN-CEUS. After disinfection, surgeons intradermally injected 0.2–0.5 mL of methylene blue into the outer upper quadrant of the areola. The whole breast was then massaged for 5–10 minutes. Next, SLNB was performed via the incision at the lateral border of the pectoralis major muscle, tracing the blue-dyed lymphatic vessel and identifying the blue-dyed SLN. During the process of SLNB, the direction of the blue-dye tracer and the marker on the skin were compared. The blue-dyed SLN was dissected and the resected specimen was sent to the pathology department for pathological diagnosis. Patients' results of SLN-CEUS and other imaging examinations were unavailable to the pathologists.

### *Statistical analysis*

Statistical analysis was performed using the R software (R Foundation of Statistical Computing, Vienna, Austria). PSM was performed using the 'Matchit' package in R. Continuous variable data conforming to normality were represented by " $\bar{x} \pm s$ ", and comparison between groups was performed using an independent samples *t*-test. Chi-square tests were used to compare groups on categorical variables. A bilateral *P* value of <0.05 was considered statistically significant.

Compared with the final pathology of SLN, the positive predictive value (PPV), negative predictive value (NPV), FNR, false positive rate (FPR), sensitivity, specificity and accuracy of diagnosis using BUS and SLN-CEUS methods were calculated using the following formulas:

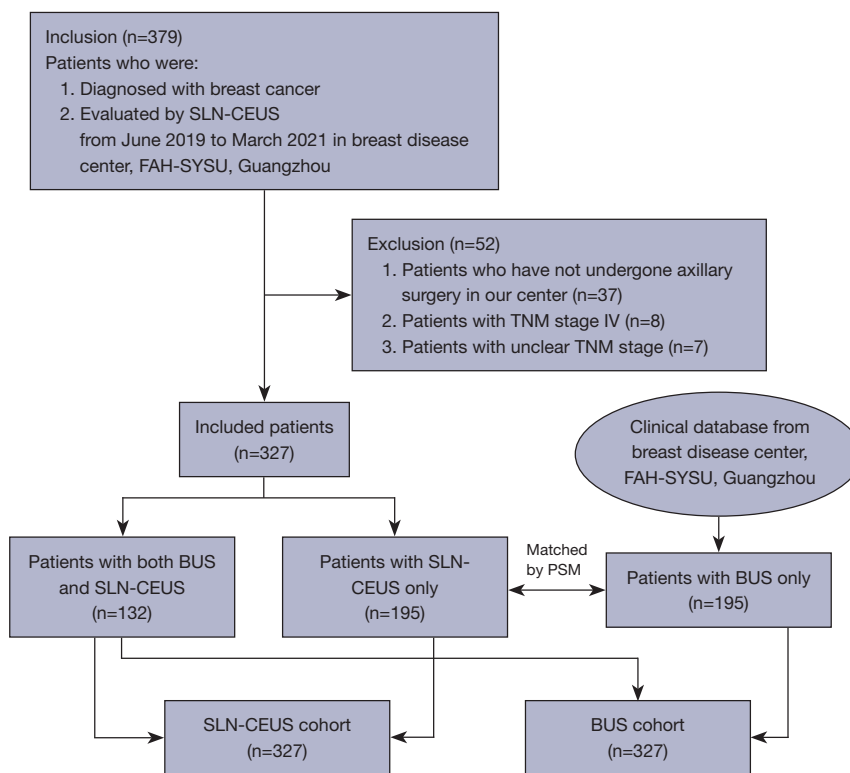
$$\text{Sensitivity} = \frac{\text{Number of true positives}}{\text{Number of true positives} + \text{Number of false negatives}} \times 100\% \quad [2]$$

$$\text{Specificity} = \frac{\text{Number of true negatives}}{\text{Number of true negatives} + \text{Number of false positives}} \times 100\% \quad [3]$$

$$\text{PPV} = \frac{\text{Number of true positives}}{\text{Number of true positives} + \text{Number of false positives}} \times 100\% \quad [4]$$

$$\text{NPV} = \frac{\text{Number of true negatives}}{\text{Number of true negatives} + \text{Number of false negatives}} \times 100\% \quad [5]$$

$$\text{FNR} = \frac{\text{Number of false negatives}}{\text{Number of true positives} + \text{Number of false negatives}} \times 100\% \quad [6]$$



**Figure 1** Flow diagram of patients included, excluded and matching. SLN-CEUS, contrast-enhanced ultrasound of sentinel lymph node; FAH-SYSU, First Affiliated Hospital of Sun Yat-sen University; TNM, tumor-node-metastasis; BUS, B-mode ultrasound; PSM, propensity score matching.

$$FPR = \frac{\text{Number of false positives}}{\text{Number of true negatives} + \text{Number of false positives}} \times 100\% \quad [7]$$

$$\text{Accuracy} = \frac{\text{Number of true positives} + \text{Number of true negatives}}{\text{Number of true positives} + \text{Number of true negatives} + \text{Number of false positives} + \text{Number of false negatives}} \times 100\% \quad [8]$$

As for evaluating the efficacy of SLN mapping using SLN-CEUS, the identification rate and FNR of SLNB were calculated using the following formulas:

$$\text{Identification rate} = \frac{\text{Number of patients with identified SLN}}{\text{Number of patients received SLN}} - \text{CEUS} \times 100\% \quad [9]$$

$$\text{FNR of SLNB} = \frac{\text{Number of false negatives of SLNB}}{\text{Number of true positives of SLNB} + \text{Number of false negatives of SLNB}} \times 100\% \quad [10]$$

## Results

A total of 379 patients were recruited. After exclusion, 327 patients were enrolled. Among them, 132 patients underwent both BUS and SLN-CEUS, whereas 195 patients only received SLN-CEUS. For these SLN-CEUS-only patients, 1:1 PSM was conducted using the clinical database of our center, matching to 195 patients who only received BUS. Eventually, both cohorts

**Table 1** Baseline demographic and disease characteristics before propensity score matching

Characteristic	Overall (N=1,091)	BUS (n=764)	SLN-CEUS (n=327)	P value*
Age, mean (SD)	50.98 (11.35)	51.53 (11.40)	49.68 (11.15)	0.013
Patients underwent NAT, n (%) <sup>†</sup>	207 (18.97)	98 (12.83)	109 (33.33)	<0.001
T stage, n (%)				0.372
0	226 (20.71)	158 (20.68)	68 (20.80)	
1	620 (56.83)	422 (55.24)	198 (60.55)	
2	218 (19.98)	164 (21.47)	54 (16.51)	
3	13 (1.19)	10 (1.31)	3 (0.92)	
4	14 (1.28)	10 (1.31)	4 (1.22)	
N stage, n (%)				0.286
0	794 (72.78)	546 (71.47)	248 (75.84)	
1	177 (16.22)	128 (16.75)	49 (14.98)	
2	90 (8.25)	65 (8.51)	25 (7.64)	
3	30 (2.75)	25 (3.27)	5 (1.53)	
Tumor stage group, n (%)				0.124
0	225 (20.62)	162 (21.20)	63 (19.27)	
I	459 (42.07)	306 (40.05)	153 (46.79)	
II	278 (25.48)	197 (25.79)	81 (24.77)	
III	129 (11.82)	99 (12.96)	30 (9.17)	

\*, P values are from the *t*-test, comparing BUS group and SLN-CEUS group; <sup>†</sup>, percentages are rounded to 2 decimal places. BUS, B-mode ultrasound; SLN-CEUS, contrast-enhanced ultrasound of sentinel lymph node; NAT, neoadjuvant treatment.

(BUS cohort and SLN-CEUS cohort) had 327 patients, with well-balanced baseline characteristics (*Figure 1*).

### Baseline characteristics

Patients' baseline characteristics before (*Table 1*) and after (*Table 2*) PSM were summarized. No statistically significant difference was found between the 2 cohorts after PSM. Both the histogram plots and Jitter plot from R showed that PSM greatly minimized the imbalance between cohorts (*Figure 2*).

### Diagnostic efficacy

Overall, both the NPV [90.2% (95% CI, 85.4–93.5%) vs. 83.5% (95% CI, 77.8–88.0%), *P*=0.048] and accuracy [80.7% (95% CI, 76.5–85.0%) vs. 73.7% (95% CI, 68.9–78.5%), *P*<0.001] of SLN-CEUS were significantly higher than BUS. Other diagnostic efficacy measures showed no statistically significant difference (*P*>0.05). In non-

NAT patients, sensitivity [76.9% (95% CI, 60.3–88.3%) vs. 51.9% (95% CI, 37.8–65.8%), *P*=0.026], NPV [94.7% (95% CI, 89.9–97.4%) vs. 85.5% (95% CI, 79.1–90.2%), *P*=0.007], FNR [23.1% (95% CI, 11.7–39.7%) vs. 48.1% (95% CI, 34.2–62.2%), *P*=0.026] and accuracy [87.6% (95% CI, 83.2–92.0%) vs. 76.0% (95% CI, 70.4–81.5%), *P*<0.001] all showed superiority in the SLN-CEUS cohort in comparison to the BUS cohort. Other diagnostic efficacy measures showed no statistically significant difference. In NAT patients, no significant difference (*P*>0.05) in diagnostic efficacy was found between SLN-CEUS and BUS, including sensitivity, specificity, PPV, NPV, FNR, FPR and accuracy (*Table 3*).

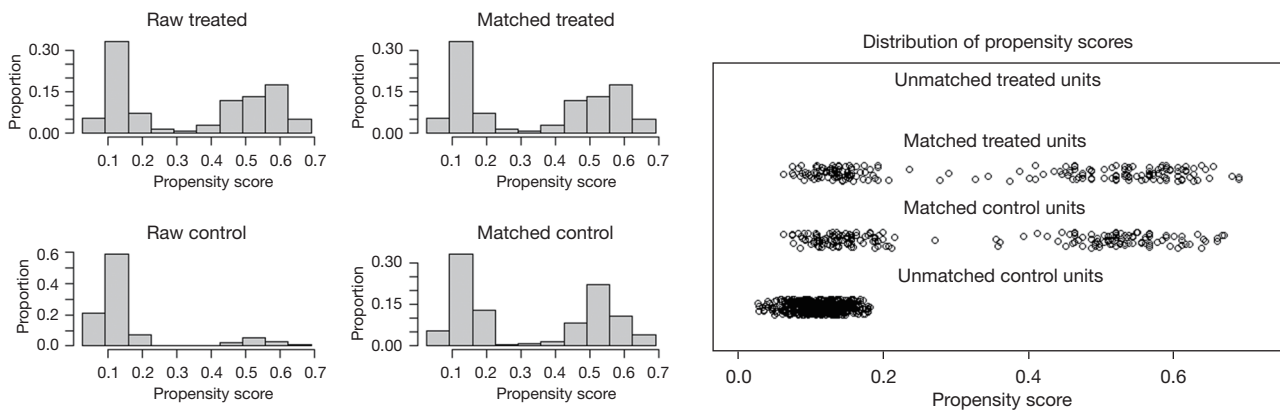
### Proportion of undetermined diagnoses

The proportion of undetermined diagnoses in the SLN-CEUS cohort and the BUS cohort were compared (*Table 4*), showing a significantly lower proportion undetermined

**Table 2** Baseline demographic and disease characteristics after propensity score matching

Characteristic	Overall (n=654)	BUS (n=327)	SLN-CEUS (n=327)	P value*
Age, mean (SD)	49.60 (11.26)	49.53 (11.38)	49.68 (11.15)	0.862
Patients underwent NAT, n (%) <sup>†</sup>	207 (31.65)	98 (29.97)	109 (33.33)	0.401
T stage, n (%)				0.875
0	127 (19.42)	59 (18.04)	68 (20.80)	
1	405 (61.93)	207 (63.30)	198 (60.55)	
2	110 (16.82)	56 (17.13)	54 (16.51)	
3	5 (0.76)	2 (0.61)	3 (0.92)	
4	7 (1.07)	3 (0.92)	4 (1.22)	
N stage, n (%)				0.604
0	510 (77.98)	262 (80.12)	248 (75.84)	
1	89 (13.61)	40 (12.23)	49 (14.98)	
2	45 (6.88)	20 (6.12)	25 (7.64)	
3	10 (1.53)	5 (1.53)	5 (1.53)	
Tumor stage group, n (%)				0.768
0	121 (18.50)	58 (17.74)	63 (19.27)	
I	318 (48.62)	165 (50.46)	153 (46.79)	
II	160 (24.46)	79 (24.16)	81 (24.77)	
III	55 (8.41)	25 (7.65)	30 (9.17)	

\*, P values are from the *t*-test, comparing BUS group and SLN-CEUS group; <sup>†</sup>, percentages are rounded to 2 decimal places. BUS, B-mode ultrasound; SLN-CEUS, contrast-enhanced ultrasound of sentinel lymph node; NAT, neoadjuvant treatment.



**Figure 2** Histogram plots and Jitter plot of PSM. (A) Histogram plots before and after PSM. ‘Treated’ group refers to ‘SLN-CEUS’ group and ‘Control’ group refers to ‘BUS’ group. (B) Jitter plots before and after PSM. Each ‘Treated Unit’ refers to one ‘patient underwent SLN-CEUS’ group and each ‘Control Unit’ refers to one ‘patient underwent BUS’. All ‘Treated Units’ are matched so the ‘Unmatched Treated Units’ are blank. PSM, propensity score matching; SLN-CEUS, contrast-enhanced ultrasound of sentinel lymph node; BUS, B-mode ultrasound.

**Table 3** Comparison of the diagnostic test between SLN-CEUS and BUS

Metric	Overall patients			Non-NAT patients			NAT patients		
	SLN-CEUS	BUS	P value*	SLN-CEUS	BUS	P value*	SLN-CEUS	BUS	P value*
Sensitivity	69.7% (53/76); (95% CI, 58.0– 79.5%)	59.3% (54/91); (95% CI, 48.5– 69.4%)	0.218	76.9% (30/39); (95% CI, 60.3– 88.3%)	51.9% (27/52); (95% CI, 37.8– 65.8%)	0.026	62.2% (23/37); (95% CI, 44.8– 77.1%)	69.2% (27/39); (95% CI, 52.3– 82.5%)	0.910
Specificity	84.1% (211/251); (95% CI, 78.8– 88.2%)	79.2% (187/236); (95% CI, 73.4– 84.1%)	0.208	89.9% (161/179); (95% CI, 84.3– 93.8%)	83.1% (147/177); (95% CI, 76.5– 88.1%)	0.080	69.4% (50/72); (95% CI, 57.3– 79.5%)	67.8% (40/59); (95% CI, 54.2– 79.0%)	>0.99
PPV	57.0% (53/93); (95% CI, 46.3– 67.1%)	52.4% (54/103); (95% CI, 42.4– 62.3%)	0.619	62.5% (30/48); (95% CI, 47.3– 75.7%)	47.4% (27/57); (95% CI, 34.2– 60.9%)	0.176	51.1% (23/45); (95% CI, 36.0– 66.1%)	58.7% (27/46); (95% CI, 43.3– 72.7%)	0.606
NPV	90.2% (211/234); (95% CI, 85.4– 93.5%)	83.5% (187/224); (95% CI, 77.8– 88.0%)	0.048	94.7% (161/170); (95% CI, 89.9– 97.4%)	85.5% (147/172); (95% CI, 79.1– 90.2%)	0.007	78.1% (50/64); (95% CI, 65.7– 87.1%)	76.9% (40/52); (95% CI, 62.8– 87.0%)	>0.99
FNR	30.3% (23/76); (95% CI, 20.5– 42.0%)	40.7% (37/91); (95% CI, 30.6– 51.5%)	0.218	23.1% (9/39); (95% CI, 11.7– 39.7%)	48.1% (25/52); (95% CI, 34.2– 62.2%)	0.026	37.8% (14/37); (95% CI, 22.9– 55.2%)	30.8% (12/39); (95% CI, 17.5– 47.7%)	0.684
FPR	15.9% (40/251); (95% CI, 11.8– 21.2%)	20.8% (49/236); (95% CI, 15.9– 26.6%)	0.208	10.1% (18/179); (95% CI, 6.2– 15.7%)	16.9% (30/177); (95% CI, 11.9– 23.5%)	0.080	30.6% (22/72); (95% CI, 20.5– 42.7%)	32.2% (19/59); (95% CI, 21.0– 45.8%)	0.990
Accuracy	80.7% (264/327); (95% CI, 76.5– 85.0%)	73.7% (241/327); (95% CI, 68.9– 78.5%)	<0.001	87.6% (191/218); (95% CI, 83.2– 92.0%)	76.0% (174/229); (95% CI, 70.4– 81.5%)	<0.001	67.0% (73/109); (95% CI, 58.1– 75.8%)	68.4% (67/98); (95% CI, 59.2– 77.6%)	0.948

\*, P values are from the chi-square test or Fisher exact test, as appropriate. SLN-CEUS, contrast-enhanced ultrasound of sentinel lymph node; BUS, B-mode ultrasound; PPV, positive predictive value; NPV, negative predictive value; FNR, false negative rate; FPR, false positive rate.

**Table 4** Proportion of undetermined diagnoses in SLN-CEUS and BUS

Undetermined diagnoses <sup>†</sup>	SLN-CEUS	BUS	P value*
Number	19	50 <sup>†</sup>	–
Proportion	5.8% (19/327)	15.3% (50/327)	<0.001

\*, P values are from the chi-square test. <sup>†</sup>50 cases of 'undetermined diagnoses' in BUS group includes 18 cases of 'undefined', 11 cases of 'enlargement', 1 case of 'reduction', 3 cases of 'transformation after NAT' and 17 cases of 'suspect'. <sup>†</sup>Undetermined diagnoses' includes 'unidentified' in SLN-CEUS group and 'undefined', 'enlargement', 'reduction', 'transformation after NAT' and 'suspect' in BUS group. SLN-CEUS, contrast-enhanced ultrasound of sentinel lymph node; BUS, B-mode ultrasound.

**Table 5** Identification rate of SLN-CEUS and subgroup analysis

Patients	Detected (n)	Undetected (n)	Identified rate
Overall	308	19	94.2% (308/327)
Subgroup			
Non-NAT	210	8	96.3% (210/218)
NAT	98	11	89.9% (98/109)
P value*			0.037
Subgroup			
Surgery history <sup>†</sup>	36	1	97.3% (36/37)
No surgery history	272	18	93.8% (272/290)
P value*			0.708

\*, P values are from the chi-square test or Fisher exact test, as appropriate; <sup>†</sup>Surgery history includes ipsilateral breast or axillary surgery history. Fine needle aspiration biopsy is not included. SLN-CEUS, contrast-enhanced ultrasound of sentinel lymph node; NAT, neoadjuvant treatment.

diagnoses in the SLN-CEUS cohort compared to the BUS cohort (5.8% *vs.* 15.3%,  $P < 0.001$ ). The undetermined diagnoses in the SLN-CEUS cohort included 19 cases of unidentified SLN. In the BUS cohort, 50 cases of undetermined results included 18 cases of 'undefined', 11 cases of 'enlargement', 1 case of 'reduction', 3 cases of 'transformation after NAT' and 17 cases of 'suspect'.

Among the 50 patients with undetermined diagnoses in the BUS group, 26 patients underwent SLN-CEUS; 25 of 26 patients were then successfully detected by SLN-CEUS. Among the 25 cases detected, SLNs in 23 patients were correctly evaluated by SLN-CEUS, with an accuracy rate of

92.0% (23/25).

### Identification rate

The identification rate was only calculated in the SLN-CEUS cohort, as BUS cannot locate SLNs. SLNs were successfully detected in 308 patients in the SLN-CEUS cohort. The overall identification rate of SLN-CEUS in our study was 94.2% (308/327). Among the 19 patients who were unable to detect SLN, 9 patients were found to have metastasis after surgery (*Table 5*). In the subgroup analysis, the identification rate in non-NAT patients was significantly higher than that in NAT patients [96.3% (210/218) *vs.* 89.9% (98/109),  $P = 0.037$ ].

A total of 37 patients had previously undergone ipsilateral breast and/or axillary surgery previously, including 13 who had undergone ultrasound-guided Mammotome (Ethicon Endo-surgery, Inc., Cincinnati, OH, USA) rotatory biopsy, 23 who had undergone lumpectomy and 1 resection of axillary hematoma. In patients with surgical history, the identification rate was 97.3% (36/37). In patients without surgical history, the identification rate was 93.8% (272/290). No difference was found between the two groups in identification rate (97.3% *vs.* 93.8%,  $P = 0.708$ ).

### FNR of SLNB

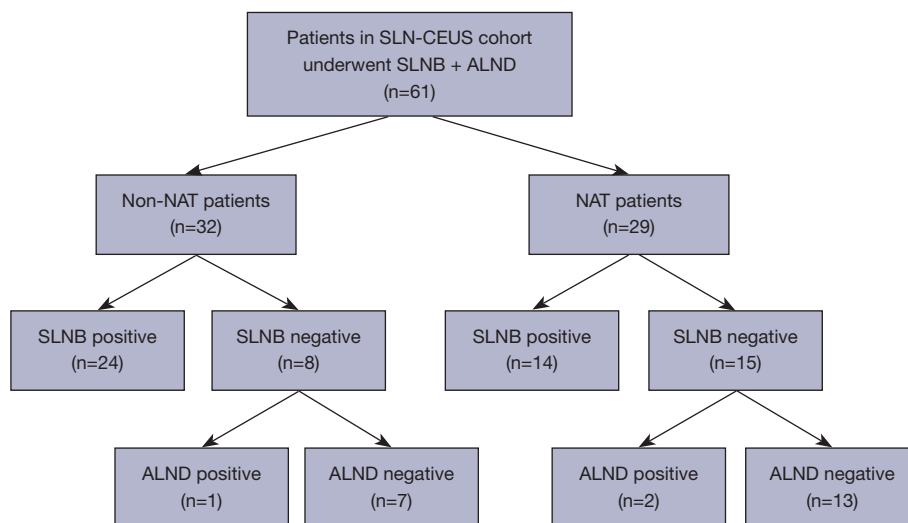
A total of 61 patients who were planned to undergo axillary lymph node dissection (ALND) in the SLN-CEUS cohort underwent both SLNB and ALND (*Figure 3*), including 29 NAT patients and 32 non-NAT patients. A total of 23 of 61 patients were diagnosed as negative by SLNB, among whom 3 were confirmed with axillary lymph node metastasis by ALND. The FNR of SLNB in overall patients was 7.3% (3/41). Among 32 non-NAT patients, 8 were diagnosed as negative by SLNB, of whom 1 was confirmed with axillary lymph node metastasis by ALND. The FNR of SLNB in non-NAT patients in the SLN-CEUS cohort was 4.0% (1/25). Among the 29 NAT patients, 15 were diagnosed as negative by SLNB, of whom 2 were confirmed as positive by ALND. The FNR of SLNB in NAT patients in the SLN-CEUS cohort was 12.5% (2/16).

## Discussion

### Diagnostic efficacy

The diagnostic accuracy of SLN-CEUS in overall patients





**Figure 3** Patients in SLN-CEUS cohort underwent SLNB and ALND. SLN-CEUS, contrast-enhanced ultrasound of sentinel lymph node; SLNB, sentinel lymph node biopsy; ALND, axillary lymph node dissection; NAT, neoadjuvant treatment.

and non-NAT patients was 80.7% and 87.6% respectively, which was significantly higher than the 73.7% and 76.0% seen, respectively, in the BUS cohort. The NPV was high (>90%) in both overall patients and non-NAT patients, suggesting low rates of misdiagnosis. Diagnostic efficacy was consistent with previous studies of CEUS in assessing SLN in non-NAT patients, with the NPV ranging from 90.3% to 100.0% and the accuracy ranging from 64.9% to 91.7% (8,9,11,15). Compared to previous studies of BUS, the diagnostic efficacy of SLN-CEUS was much higher, with the NPV of BUS ranging from 64.4% to 83.7% and the accuracy ranging from 66.7% to 76.4% respectively (16-19). Both the higher accuracy and NPV of SLN-CEUS can lead to a more accurate evaluation and a more accurate strategy for surgical treatment.

The advantages of SLN-CEUS are as follows. First, Sonographer can locate the SLN and assess it exclusively using SLN-CEUS mapping, improving diagnostic efficacy. Second, the additional imaging characteristics of SLN, such as the patterns of enhancement and infusion, also increased diagnostic efficacy. Previous studies have shown that the pattern of enhancement of SLNs can be classed into 3 types: homogenous enhancement, heterogenous enhancement and no enhancement. Generally speaking, SLNs with homogenous enhancement are usually considered negative nodes, and SLNs with another two types of enhancement models are usually considered metastasis (8). These imaging characteristics are all unavailable in BUS.

In NAT patients, no difference in diagnostic efficacy was found between SLN-CEUS and BUS. We hypothesized the

following reasons for this. First, after NAT, the lymph node structure had changed, which made it difficult to diagnose the lymph node status by BUS. Furthermore, the small sample size of NAT patients (109 in the SLN-CEUS cohort and 98 in the BUS cohort) may have led to insufficient statistical power. In saying this, when compared to previous studies, the NPV (78.1%) and accuracy (67.0%) of SLN-CEUS in NAT patients of our study was relatively high; In the Z1071 trial, the NPV and accuracy of BUS in NAT patients were 43.7% and 51.9%, respectively (20), and the SN-FNAC trial showed sensitivity, specificity, PPV, NPV, accuracy, and FNR of BUS after NAT to be 52.8%, 78.3%, 82.4%, 46.2%, 61.5%, and 47.2%, respectively. In our study, the sensitivity, specificity, NPV, FNR and accuracy of SLN-CEUS were all better than those of BUS in the SN-FNAC trial (21). The practical application of SLN-CEUS for diagnosis in NAT patients is still promising. More studies are needed to further evaluate the diagnostic efficacy of SLN-CEUS in NAT patients.

#### *Proportion of undetermined diagnoses*

Due to the differences in equipment, heterogeneity in the patient population, and variable sonographer experience, it is not always possible to provide conclusive findings on ultrasound. Equivocal results present difficulties for clinical practice, therefore, achieving a lower proportion of undetermined results can facilitate better guidance for diagnosis and treatment. The results of our study showed that the proportion of undetermined results in the SLN-

CEUS cohort (5.8%) was significantly lower than that of the BUS cohort (15.3%).

Moreover, of the patients with undetermined axillary lymph nodes results in the BUS group, 92% (23/25) were accurately and precisely evaluated using SLN-CEUS. This result shows superior diagnostic efficacy of SLN-CEUS compared to BUS, suggesting that SLN-CEUS is a promising option for patients who are unable to be diagnosed precisely by BUS.

### *Identification rate*

Identification rate is one of the most important indicators for SLNB. Based on the NASBP B-32 trial, the detection rate of SLNB >90% has been widely accepted (5). In previous research, the combination method of blue-dye tracer and radiotracer has displayed high detection rates in non-NAT patients, reaching 92% (22,23). However, the detection rate of using only 1 tracer is relatively low, at 83% for blue-dye alone and 89% for radiotracer alone (3,24). Regardless, the application of radiotracer for SLNB is not approved in China. Finding a new tracer that can combine with blue-dye as dual tracer in SLNB is necessary.

In our study, sonographers marked the direction of the lymphatic vessel and the localization of SLN on patients' skin with the guidance of the real-time imaging of CPS. During surgery, surgeons could trace the lymphatic channels (LCs) according to the marker on skin and accurately dissect all SLNs. A prospective study that enrolled 144 patients achieved an identification rate of 100% in SLNB with the combination of blue-dye tracer and CEUS (11). In our study, the identification rate of SLN-CEUS in overall patients and non-NAT patients was 94.2% and 96.3%. Therefore, SLN-CEUS is a promising technique to replace radiotracer and play the role as a new tracer for SLNB.

In NAT patients, the identification rate of SLN-CEUS in our study was only 89.9%, significantly lower than non-NAT patients. Previous studies have shown that NAT will lead to lower detection rates of SLNs. This is mainly because of the change of lymphatic flows after NAT, including fibrosis and obstruction of LCs (3,24-27). In the Z1071, SENTINA and SN FNAC studies, the identification rate of SLNB with dual tracer was 92.7%, 80.1% and 87.6% (21,24,28). Our results indicated that the identification rate of SLN-CEUS mapping only was similar to that of SLNB with dual tracer.

Most of the previous studies on CEUS have excluded patients with a surgical history, suggesting that ipsilateral

breast or axillary surgery would destroy the lymphatic flows, leading to misdetection of SLNs (8-10,15). However, in our study, there was no statistical difference regarding the identification rate of patients who underwent ipsilateral breast and/or axilla surgery or not. This result is consistent with some previous studies, suggesting that previous breast or axilla surgery does not affect the detection rate of the SLNB if using CEUS mapping (29,30).

### *FNR of SLNB*

FNR is another important indicator for the use of SLNB. An FNR of less than 10% for SLNB is considered acceptable (5). With the combination of blue-dye tracer and radiotracer, the FNR of SLNB in non-NAT patients is 4.5% (22,23). In our study, the FNR of SLNB in overall patients was 7.3% using SLN-CEUS and blue-dye dual-tracer mapping; in non-NAT patients, the FNR was only 4.0% for the same methods.

Moreover, we found some anatomic variations of lymphatic drainage in some patients. In one of our patients, lymphatic drainage was tracked using CEUS and 2 LCs were found, which were then injected into two different SLNs. If the anatomical variation was not detected by CEUS, it is likely that only the superficial SLN would have been resected and the deep one would have been missed, resulting in a false negative result. In another patient, we found an SLN which was distant from the conventional SLNB incision. In such cases, conventional SLNB is also likely to miss the SLN, resulting in missed detection and false negative results. Compared with other tracers, SLN-CEUS can achieve preoperative and visualized tracing of the SLN, which will improve both surgical accuracy and identification rate, and at the same time will also reduce surgical trauma and the FNR of SLNB.

For patients who underwent NAT, the FNR of SLNB with dual-tracer (blue-dye tracer and radiotracer) in the SENTINA and Z1071 trials was 8.6% and 10.8%, respectively (24,28). In our study, 29 NAT patients used SLN-CEUS and blue-dye for dual tracer mapping, with an FNR of 12.5% (2/16), which is closed to the 10%. However, due to small sample size in our study, the results require further validation. More trials are needed to investigate the FNR of SLN-CEUS combined with blue-dye tracer for dual tracer mapping in NAT patients.

### *Limitations*

This study had some limitations. Firstly, due to the

retrospective and single-center nature of the study, selection bias and study scope limitations are inevitable. Furthermore, the small sample size of some subgroups was also a limitation. For example, the sample size of NAT patients (109 in SLN-CEUS cohort and 98 in BUS cohort) is not adequate to compare the diagnostic efficacy between SLN-CEUS and BUS; and the sample size while counting FNR of SLNB (61 in total) is also too small to evaluate the efficacy of SLN mapping. Finally, there is no unified operating procedure and diagnostic criteria of SLN-CEUS so far, which may cause different results in different centers. More work is needed to lead to its standardization.

## Conclusions

Compared to BUS, SLN-CEUS is a better technique for axillary lymph nodes evaluation, with superior diagnostic efficacy on several measures. SLN-CEUS is a promising mapping method in SLNB, with its high identification rate and low FNR when combined with blue-dye tracer.

## Acknowledgments

We are grateful to the sonographers in our center for their technical support.

*Funding:* None.

## Footnote

*Reporting Checklist:* The authors have completed the STARD reporting checklist. Available at <https://qims.amegroups.com/article/view/10.21037/qims-22-901/rc>

*Conflicts of Interest:* All authors have completed the ICMJE uniform disclosure form (available at <https://qims.amegroups.com/article/view/10.21037/qims-22-901/coif>). The authors have no conflicts of interest to declare.

*Ethical Statement:* The authors are accountable for all aspects of the work in ensuring that questions related to the accuracy or integrity of any part of the work are appropriately investigated and resolved. The study was conducted in accordance with the Declaration of Helsinki (as revised in 2013) and approved by the Clinical Research Ethics Committee of the First Affiliated Hospital, Sun Yat-sen University. Individual consent for this retrospective analysis was waived.

*Open Access Statement:* This is an Open Access article distributed in accordance with the Creative Commons Attribution-NonCommercial-NoDerivs 4.0 International License (CC BY-NC-ND 4.0), which permits the non-commercial replication and distribution of the article with the strict proviso that no changes or edits are made and the original work is properly cited (including links to both the formal publication through the relevant DOI and the license). See: <https://creativecommons.org/licenses/by-nc-nd/4.0/>.

## References

1. Siegel RL, Miller KD, Fuchs HE, Jemal A. Cancer statistics, 2022. *CA Cancer J Clin* 2022;72:7-33.
2. Helms G, Kühn T, Moser L, Rimmel E, Kreienberg R. Shoulder-arm morbidity in patients with sentinel node biopsy and complete axillary dissection--data from a prospective randomised trial. *Eur J Surg Oncol* 2009;35:696-701.
3. Kim T, Giuliano AE, Lyman GH. Lymphatic mapping and sentinel lymph node biopsy in early-stage breast carcinoma: a metaanalysis. *Cancer* 2006;106:4-16.
4. Kootstra JJ, Hoekstra-Weebers JE, Rietman JS, de Vries J, Baas PC, Geertzen JH, Hoekstra HJ. A longitudinal comparison of arm morbidity in stage I-II breast cancer patients treated with sentinel lymph node biopsy, sentinel lymph node biopsy followed by completion lymph node dissection, or axillary lymph node dissection. *Ann Surg Oncol* 2010;17:2384-94.
5. Krag DN, Anderson SJ, Julian TB, Brown AM, Harlow SP, Ashikaga T, Weaver DL, Miller BJ, Jalovec LM, Frazier TG, Noyes RD, Robidoux A, Scarth HM, Mammolito DM, McCready DR, Mamounas EP, Costantino JP, Wolmark N; . Technical outcomes of sentinel-lymph-node resection and conventional axillary-lymph-node dissection in patients with clinically node-negative breast cancer: results from the NSABP B-32 randomised phase III trial. *Lancet Oncol* 2007;8:881-8.
6. Swinson C, Ravichandran D, Nayagam M, Allen S. Ultrasound and fine needle aspiration cytology of the axilla in the pre-operative identification of axillary nodal involvement in breast cancer. *Eur J Surg Oncol* 2009;35:1152-7.
7. Marino MA, Avendano D, Zapata P, Riedl CC, Pinker K. Lymph Node Imaging in Patients with Primary Breast Cancer: Concurrent Diagnostic Tools. *Oncologist* 2020;25:e231-42.
8. Xie F, Zhang D, Cheng L, Yu L, Yang L, Tong F, Liu H,

- Wang S, Wang S. Intradermal microbubbles and contrast-enhanced ultrasound (CEUS) is a feasible approach for sentinel lymph node identification in early-stage breast cancer. *World J Surg Oncol* 2015;13:319.
9. Zhao J, Zhang J, Zhu QL, Jiang YX, Sun Q, Zhou YD, Wang MQ, Meng ZL, Mao XX. The value of contrast-enhanced ultrasound for sentinel lymph node identification and characterisation in pre-operative breast cancer patients: A prospective study. *Eur Radiol* 2018;28:1654-61.
  10. Luo J, Feng L, Zhou Q, Chen Q, Liu J, Wu C, Luo J, Chen J, Wu H, Deng W. The value of contrast-enhanced ultrasound in determining the location of sentinel lymph nodes in breast cancer. *Cancer Imaging* 2021;21:28.
  11. Wang X, Tang L, Huang W, Cui Z, Hu D, Zhong Z, Wu X. The combination of contrast-enhanced ultrasonography with blue dye for sentinel lymph node detection in clinically negative node breast cancer. *Arch Gynecol Obstet* 2021;304:1551-9.
  12. Qiao J, Li J, Wang L, Guo X, Bian X, Lu Z. Predictive risk factors for sentinel lymph node metastasis using preoperative contrast-enhanced ultrasound in early-stage breast cancer patients. *Gland Surg* 2021;10:761-9.
  13. Zhu Y, Fan X, Yang D, Dong T, Jia Y, Nie F. Contrast-Enhanced Ultrasound for Precise Sentinel Lymph Node Biopsy in Women with Early Breast Cancer: A Preliminary Study. *Diagnostics (Basel)* 2021.
  14. Zhu Y, Jia Y, Pang W, Duan Y, Chen K, Nie F. Ultrasound contrast-enhanced patterns of sentinel lymph nodes: predictive value for nodal status and metastatic burden in early breast cancer. *Quant Imaging Med Surg* 2023;13:160-70.
  15. Liu J, Liu X, He J, Gou B, Luo Y, Deng S, Wen H, Zhou L. Percutaneous contrast-enhanced ultrasound for localization and diagnosis of sentinel lymph node in early breast cancer. *Sci Rep* 2019;9:13545.
  16. Bedrosian I, Bedi D, Kuerer HM, Fornage BD, Harker L, Ross MI, Ames FC, Krishnamurthy S, Edeiken-Monroe BS, Meric F, Feig BW, Akins J, Singletary SE, Mirza NQ, Hunt KK. Impact of clinicopathological factors on sensitivity of axillary ultrasonography in the detection of axillary nodal metastases in patients with breast cancer. *Ann Surg Oncol* 2003;10:1025-30.
  17. Damera A, Evans AJ, Cornford EJ, Wilson AR, Burrell HC, James JJ, Pinder SE, Ellis IO, Lee AH, Macmillan RD. Diagnosis of axillary nodal metastases by ultrasound-guided core biopsy in primary operable breast cancer. *Br J Cancer* 2003;89:1310-3.
  18. Deurloo EE, Tanis PJ, Gilhuijs KG, Muller SH, Kröger R, Peterse JL, Rutgers EJ, Valdés Olmos R, Schultze Kool LJ. Reduction in the number of sentinel lymph node procedures by preoperative ultrasonography of the axilla in breast cancer. *Eur J Cancer* 2003;39:1068-73.
  19. Sapino A, Cassoni P, Zanon E, Fraire F, Croce S, Coluccia C, Donadio M, Bussolati G. Ultrasonographically-guided fine-needle aspiration of axillary lymph nodes: role in breast cancer management. *Br J Cancer* 2003;88:702-6.
  20. Boughey JC, Ballman KV, Hunt KK, McCall LM, Mittendorf EA, Ahrendt GM, Wilke LG, Le-Petross HT. Axillary Ultrasound After Neoadjuvant Chemotherapy and Its Impact on Sentinel Lymph Node Surgery: Results From the American College of Surgeons Oncology Group Z1071 Trial (Alliance). *J Clin Oncol* 2015;33:3386-93.
  21. Morency D, Dumitra S, Parvez E, Martel K, Basik M, Robidoux A, Poirier B, Holloway CMB, Gaboury L, Sideris L, Meterissian S, Boileau JF. Axillary Lymph Node Ultrasound Following Neoadjuvant Chemotherapy in Biopsy-Proven Node-Positive Breast Cancer: Results from the SN FNAC Study. *Ann Surg Oncol* 2019;26:4337-45.
  22. Albertini JJ, Lyman GH, Cox C, Yeatman T, Balducci L, Ku N, Shivers S, Berman C, Wells K, Rapaport D, Shons A, Horton J, Greenberg H, Nicosia S, Clark R, Cantor A, Reintgen DS. Lymphatic mapping and sentinel node biopsy in the patient with breast cancer. *JAMA* 1996;276:1818-22.
  23. Radovanovic Z, Golubovic A, Plzak A, Stojiljkovic B, Radovanovic D. Blue dye versus combined blue dye-radioactive tracer technique in detection of sentinel lymph node in breast cancer. *Eur J Surg Oncol* 2004;30:913-7.
  24. Boughey JC, Suman VJ, Mittendorf EA, Ahrendt GM, Wilke LG, Taback B, et al. Sentinel lymph node surgery after neoadjuvant chemotherapy in patients with node-positive breast cancer: the ACOSOG Z1071 (Alliance) clinical trial. *JAMA* 2013;310:1455-61.
  25. Boileau JF, Poirier B, Basik M, Holloway CM, Gaboury L, Sideris L, Meterissian S, Arnaout A, Brackstone M, McCready DR, Karp SE, Trop I, Lisbona A, Wright FC, Younan RJ, Provencher L, Patocskaï E, Omeroglu A, Robidoux A. Sentinel node biopsy after neoadjuvant chemotherapy in biopsy-proven node-positive breast cancer: the SN FNAC study. *J Clin Oncol* 2015;33:258-64.
  26. Boughey JC, Ballman KV, Le-Petross HT, McCall LM, Mittendorf EA, Ahrendt GM, Wilke LG, Taback B, Feliberti EC, Hunt KK. Identification and Resection of Clipped Node Decreases the False-negative Rate of

- Sentinel Lymph Node Surgery in Patients Presenting With Node-positive Breast Cancer (T0-T4, N1-N2) Who Receive Neoadjuvant Chemotherapy: Results From ACOSOG Z1071 (Alliance). *Ann Surg* 2016;263:802-7.
27. Classe JM, Loaec C, Gimbergues P, Alran S, de Lara CT, Dupre PF, Rouzier R, Faure C, Paillocher N, Chauvet MP, Houvenaeghel G, Gutowski M, De Blay P, Verhaeghe JL, Barranger E, Lefebvre C, Ngo C, Ferron G, Palpacuer C, Champion L. Sentinel lymph node biopsy without axillary lymphadenectomy after neoadjuvant chemotherapy is accurate and safe for selected patients: the GANEA 2 study. *Breast Cancer Res Treat* 2019;173:343-52.
  28. Kuehn T, Bauerfeind I, Fehm T, Fleige B, Hausschild M, Helms G, Lebeau A, Liedtke C, von Minckwitz G, Nekljudova V, Schmatloch S, Schrenk P, Staebler A, Untch M. Sentinel-lymph-node biopsy in patients with breast cancer before and after neoadjuvant chemotherapy (SENTINA): a prospective, multicentre cohort study. *Lancet Oncol* 2013;14:609-18.
  29. Renaudeau C, Lefebvre-Lacoeuille C, Champion L, Dravet F, Descamps P, Ferron G, Houvenaeghel G, Giard S, Tunon de Lara C, Dupré PF, Fritel X, Ngô C, Verhaeghe JL, Faure C, Mezzadri M, Damey C, Classe JM. Evaluation of sentinel lymph node biopsy after previous breast surgery for breast cancer: GATA study. *Breast* 2016;28:54-9.
  30. Zetterlund L, Gabrielson S, Axelsson R, de Boniface J, Frisell J, Olsson A, Celebioglu F. Impact of previous surgery on sentinel lymph node mapping: Hybrid SPECT/CT before and after a unilateral diagnostic breast excision. *Breast* 2016;30:32-8.

**Cite this article as:** Fan Y, Luo J, Lu Y, Huang C, Li M, Zhang Y, Shao N, Wang S, Zheng Y, Lin Y, Shan Z. The application of contrast-enhanced ultrasound for sentinel lymph node evaluation and mapping in breast cancer patients. *Quant Imaging Med Surg* 2023;13(7):4392-4404. doi: 10.21037/qims-22-901