



# Catheter misplacement from an implantable central venous access port into the internal thoracic vein: a case description

Min-Quan Yao<sup>1^</sup>, Yan-Yan Jiang<sup>2</sup>

<sup>1</sup>Department of Gastrointestinal Surgery, Tongxiang First People's Hospital, Jiaxing, China; <sup>2</sup>Department of Clinical Laboratory, Tongxiang First People's Hospital, Jiaxing, China

*Correspondence to:* Yan-Yan Jiang, BS. Department of Clinical Laboratory, Tongxiang First People's Hospital, No. 1918 Jiaochang East Road, Jiaxing 314500, China. Email: saiyaoren1986@126.com.

Submitted Mar 16, 2023. Accepted for publication Jun 26, 2023. Published online Jul 07, 2023.

doi: 10.21037/qims-23-338

View this article at: <https://dx.doi.org/10.21037/qims-23-338>

## Introduction

An implantable central venous access port (CVport) has the advantages of a low risk of infection, long-term use, unrestricted daily activities, and avoidance of peripheral phlebitis and vascular sclerosis. In recent years, CVports have been increasingly used in patients undergoing chemotherapy, and they have been shown to improve the quality of life of patients with cancer. However, CVports are also associated with complications such as infection, pneumothorax, thrombosis, catheter misplacement, and rupture (1). The right internal jugular vein is the most commonly used approach for CVport placement (2). Catheter misplacement is an early complication of CVport implantation and often occurs in the internal jugular vein, brachiocephalic vein, subclavian vein, azygos vein, or right atrium (3). Catheter misplacement into the internal thoracic vein (ITV) is rare (4).

On February 10, 2023, a patient in our hospital underwent implantation of a CVport via the right internal jugular vein, and the catheter became misplaced and entered the right ITV. We herein summarize our diagnosis and treatment experience with a review of the literature.

## Case presentation

All procedures performed in this study were in accordance with the ethical standards of the relevant institutional and/

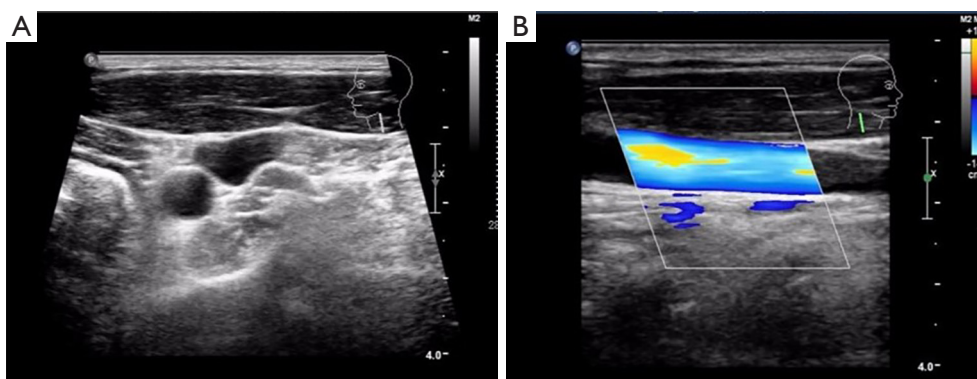
or national research committee(s) and with the Helsinki Declaration (as revised in 2013). Written informed consent was obtained from the patient for publication of this study and any accompanying images. A copy of the written consent is available for review by the editorial office of this journal.

A 53-year-old man was admitted to the hospital due to a 3-week history of confirmed sigmoid carcinoma with hepatic metastases. The patient had been treated in our hospital for intestinal obstruction 3 weeks prior. Colonoscopy showed adenocarcinoma of the sigmoid colon, and abdominal enhanced computed tomography (CT) showed multiple metastatic tumors in the liver. The patient underwent transverse colostomy and liver tumor biopsy under general anesthesia. The pathologic examination revealed infiltration of adenocarcinoma in the liver tissue, which was consistent with metastasis of colon adenocarcinoma.

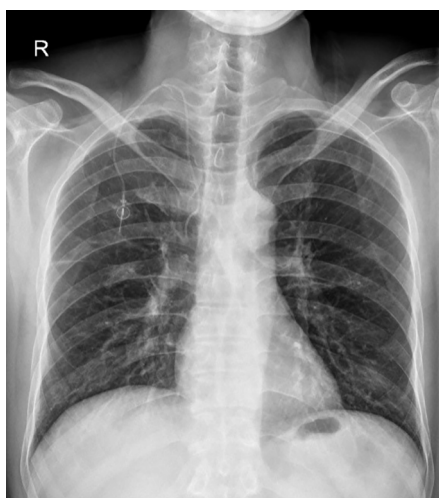The patient's height was 175 cm, and his weight was 68 kg. He was conscious, his superficial lymph nodes were not enlarged, and no abnormalities were found in heart or lung examinations. His abdomen was soft and flat with no tenderness or rebound pain, and no palpable lumps were found; however, a stoma was visible in his abdomen. No lumps were found during anal examination.

Laboratory examinations showed a white blood cell count of  $7.0 \times 10^9/L$ , red blood cell count of  $4.60 \times 10^{12}/L$ , hemoglobin concentration of 138 g/L, and platelet count of  $283.0 \times 10^9/L$ . Carcinoembryonic antigen was

<sup>^</sup> ORCID: 0000-0001-8567-9021.



**Figure 1** Vascular ultrasound. The bilateral internal jugular veins were found to be patent as shown by vascular ultrasound (A,B).



**Figure 2** Anteroposterior chest X-ray film. The end of the catheter was located in lateral superior vena cava projection area, with the head end slightly bent.

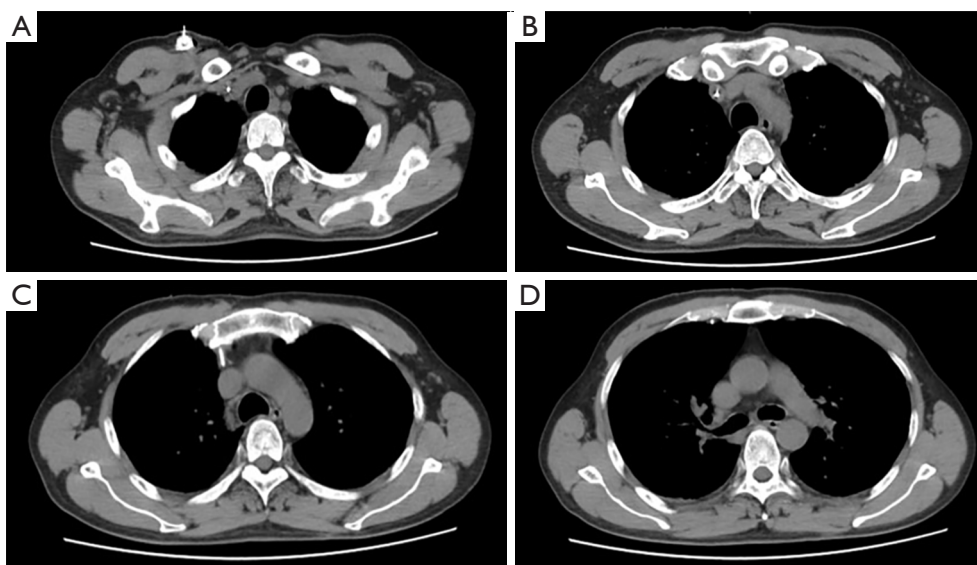
298.9 ng/mL, cancer antigen 199 was 643.7 ng/mL, and alpha-fetoprotein was 1,811.3 ng/mL. Abdominal enhanced CT showed thickening of the sigmoid colon wall and multiple intrahepatic metastases. Ultrasound showed patency of the bilateral internal jugular veins (*Figure 1*).

The patient underwent ultrasound-guided implantation of a right internal jugular venous access port under local anesthesia. The depth of the catheter with the Seldinger technique was 14.5 cm, and no obvious abnormality was found in the position of the catheter with C-arm X-ray examination during the operation. After the subcutaneous tunnel was established, the catheter was connected to the injection base. During the operation, normal saline was injected and blood was pumped back smoothly. After the

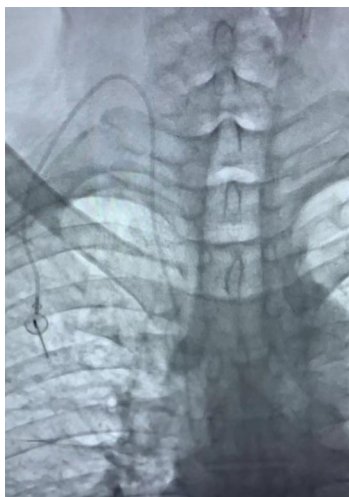
operation, the patient received folinic acid, fluorouracil, and oxaliplatin (FOLFOX) chemotherapy, during which he experienced obvious pain in the right chest and back. The chemotherapy was suspended; there was no blood return in the access port when suction was conducted, but normal saline was injected smoothly. We considered the possibility of catheter misplacement into the ITV. Anteroposterior chest X-ray examination showed that the end of the catheter was located on the lateral side of the superior vena cava (SVC) (*Figure 2*), and chest CT showed that the distal end of the catheter had entered the right ITV (*Figure 3*). Under fluoroscopy, the catheter was withdrawn 6 cm through the incision at the puncture site of the right neck and then reinserted with no resistance. Fluoroscopy showed that the catheter was located at the SVC (*Figure 4*). The patient successfully completed the chemotherapy, and the pain in his right chest and back disappeared. Two weeks later, the patient returned to the hospital for chemotherapy, and anteroposterior chest X-ray examination showed that the end of the catheter was located on the level of the upper margin of the sixth thoracic vertebra after reinsertion (*Figure 5*).

## Discussion

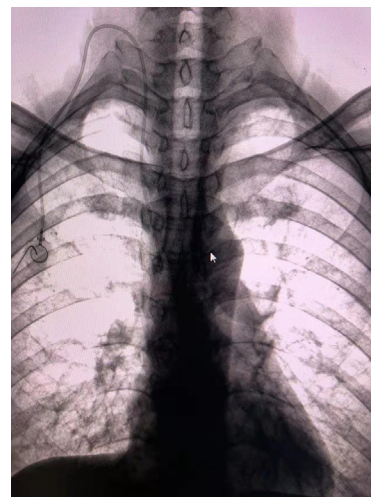
A CVport is a closed infusion device that is completely implanted within the human body, providing safe and reliable venous access for patients undergoing long-term infusion treatment and chemotherapy and improving patients' quality of life (5). The veins used for CVport implantation mainly include the internal jugular vein, subclavian vein, femoral vein, and cephalic vein; ultrasound-guided implantation via the right internal jugular vein is the most common and safest approach (2). However, CVport



**Figure 3** Chest computed tomography. The distal end of the catheter had entered the right internal thoracic vein (A-D).



**Figure 4** Anteroposterior perspective. The catheter was located in the superior vena cava projection area.



**Figure 5** Anteroposterior chest X-ray film. The catheter was located in the superior vena cava projection area.

implantation is also associated with certain complications, including arteriovenous fistula, nerve injury, pneumothorax, air embolism, arrhythmia, catheter misplacement, rupture, detachment, and blockage (1). Catheter misplacement is an early complication of CVport implantation. Ideally, the CVport catheter tip should be positioned between the middle and lower part of the SVC to the cavo-atrial junction (6). Correct catheter positioning is essential to ensuring normal catheter function and reducing complications.

It is rare for the catheter to enter the small branches of the central vein, including the internal thoracic, superior intercostal, pericardiophrenic, inferior thyroid, azygos, and hemiazygos veins. In most cases, the catheter is misplaced in this manner when the left internal jugular vein is used for CVport implantation, and one reason this occurs is that the left cephalic brachial vein is longer and has more small branches than does the right cephalic brachial vein. The ITV is a small branch of the innominate vein and

is accompanied by the ipsilateral internal thoracic artery behind the sternum. Zheng *et al.* (7) reported only 2 cases of catheter misplacement in the ITV among 28,307 patients with peripherally inserted central catheters. Before the catheter is washed or continuous infusion of hypertonic fluid is performed, patients usually have no symptoms. Chest pain during catheter washing is a typical symptom of misplacement in the ITV, and the pain usually increases as the infusion flow rate increases (8). Wang *et al.* (9) reported that radiation of chest pain from the sternum to the back during infusion of hypertonic fluid was the most common symptom of catheter misplacement into the ITV. The right ITV is located in the radiation projection area of the right cephalic brachial vein and SVC, and it is easily ignored on anteroposterior X-ray film. Therefore, the presence of a seemingly correct catheter position on anteroposterior X-ray film cannot completely rule out the possibility of catheter misplacement into the right ITV. The anteroposterior X-ray film in our case showed that the catheter was located on the lateral side of the SVC shadow, and the lateral film showed that the tip of the catheter was located behind the sternum. Lateral fluoroscopy during CVport implantation can prevent the catheter from inadvertently entering the ITV (10). Tristão *et al.* (11) suggested lateral and oblique X-ray examination for postoperative central venous catheter dysfunction. In addition to lateral and oblique fluoroscopy, venography through the catheter is also helpful for determining the position of the catheter end. Atrial electrocardiograph can also be used to detect catheter misplacement. Compared with lateral chest radiographs, CT scans can accurately show the catheter position and whether the catheter is in the blood vessel. The incidence of catheter misplacement into the ITV can be reduced by limiting the insertion depth of the guide wire during catheter insertion, using a J-tip guide wire, and selecting left subclavian vein catheterization when left-side central vein catheterization is required.

In conclusion, CVport catheter misplacement into the right ITV is a relatively rare complication. When the blood is not smoothly returned in the early stage and when the anteroposterior X-ray examination shows that the catheter is located on the lateral side of the SVC with local bending, the possibility of catheter misplacement into the ITV should be highly suspected. Lateral and oblique X-ray examination or CT examination should be performed to clarify the situation. The catheter position can be adjusted through the incision at the neck puncture under fluoroscopy for confirmation of catheter misplacement.

## Acknowledgments

*Funding:* None.

## Footnote

*Conflicts of Interest:* Both authors have completed the ICMJE uniform disclosure form (available at <https://qims.amegroups.com/article/view/10.21037/qims-23-338/coif>). The authors have no conflicts of interest to declare.

*Ethical Statement:* The authors are accountable for all aspects of the work in ensuring that questions related to the accuracy or integrity of any part of the work are appropriately investigated and resolved. All procedures performed in this study were in accordance with the ethical standards of the institutional and/or national research committee(s) and with the Helsinki Declaration (as revised in 2013). Written informed consent was obtained from the patient for publication of this study and any accompanying images. A copy of the written consent is available for review by the editorial office of this journal.

*Open Access Statement:* This is an Open Access article distributed in accordance with the Creative Commons Attribution-NonCommercial-NoDerivs 4.0 International License (CC BY-NC-ND 4.0), which permits the non-commercial replication and distribution of the article with the strict proviso that no changes or edits are made and the original work is properly cited (including links to both the formal publication through the relevant DOI and the license). See: <https://creativecommons.org/licenses/by-nc-nd/4.0/>.

## References

1. Tashjian BC, Schoor ME, Grant M. Cannulation of the Internal Mammary Vein With a Single-Lumen Infusion Catheter in a Patient With Portal Hypertension: A Case Report. *A A Pract* 2019;12:122-4.
2. Liu W, Han Q, Li L, Chi J, Liu X, Gu Y. Catheter malposition analysis of totally implantable venous access port in breast cancer patients. *Front Surg* 2022;9:1061826.
3. Pelagatti F, Pinelli F. Time to abandon chest X-rays in favor of intracavitary ECG or echocardiography for central venous access tip location: A case of a malpositioned CICC into the internal mammary vein. *J Vasc Access* 2022. [Epub ahead of print]. doi: 10.1177/11297298221074751.
4. Goodin P, Jain N, Jeelani HM, Bharat A. Accidental

- Central Venous Catheter Placement in the Internal Thoracic Vein: A Case Report. *Cureus* 2020;12:e9255.
5. Yanık F, Karamustafaoğlu YA, Karataş A, Yörük Y. Experience in totally implantable venous port catheter: Analysis of 3,000 patients in 12 years. *Türk Gogus Kalp Damar Cerrahisi Derg* 2018;26:422-8.
  6. Fukunaga T. Catheter Malposition into the Internal Thoracic Vein. *Chonnam Med J* 2022;58:140-1.
  7. Zheng XZ, Zheng SH, Huang HY, Chen Z, Chen H. Treatment plan and cause analysis of ectopic PICC catheter to internal thoracic vein in one case. *Contemporary Nurse* 2022;29:105-8.
  8. Tanrikulu N, Haspolat A, Koprulu AS. Very rare malposition of central venous catheter in cardiac surgery patients. *Cardiovasc J Afr* 2023. [Epub ahead of print]. doi: 10.5830/CVJA-2022-062.
  9. Wang L, Liu ZS, Wang CA. Malposition of Central Venous Catheter: Presentation and Management. *Chin Med J (Engl)* 2016;129:227-34.
  10. Machat S, Eisenhuber E, Pfarl G, Stübler J, Koelblinger C, Zacherl J, Schima W. Complications of central venous port systems: a pictorial review. *Insights Imaging* 2019;10:86.
  11. Tristão FR, Moreira RCR, Valle CED, Neves GCS. Inadvertent insertion of a venous catheter into the internal thoracic vein: a word of caution. *J Vasc Bras* 2019;18:e20190097.

**Cite this article as:** Yao MQ, Jiang YY. Catheter misplacement from an implantable central venous access port into the internal thoracic vein: a case description. *Quant Imaging Med Surg* 2023;13(9):6338-6342. doi: 10.21037/qims-23-338