



Cosmetic evaluation in type II congenital scoliosis with long-spanned curve: a case-matched comparison with adolescent idiopathic scoliosis

Yanjie Xu¹, Changwei Liu², Dongyue Li², Yinqi Cai², Zongshan Hu¹, Zezhang Zhu^{1,2}, Yong Qiu^{1,2}, Zhen Liu^{1,2}

¹Division of Spine Surgery, Department of Orthopedic Surgery, Nanjing Drum Tower Hospital, The Affiliated Hospital of Nanjing University Medical School, Nanjing, China; ²Division of Spine Surgery, Department of Orthopedic Surgery, Drum Tower Hospital Clinical College of Nanjing Medical University, Nanjing, China

Contributions: (I) Conception and design: Y Xu, Z Zhu, Y Qiu, Z Liu; (II) Administrative support: Z Zhu, Y Qiu, Z Liu; (III) Provision of study materials or patients: Z Hu, Z Zhu, Y Qiu, Z Liu; (IV) Collection and assembly of data: Y Xu, C Liu, D Li; (V) Data analysis and interpretation: D Li, Y Cai; (VI) Manuscript writing: All authors; (VII) Final approval of manuscript: All authors.

Correspondence to: Zhen Liu, MD. Division of Spine Surgery, Department of Orthopedic Surgery, Nanjing Drum Tower Hospital, The Affiliated Hospital of Nanjing University Medical School, Zhongshan Road 321, Nanjing 210008, China; Division of Spine Surgery, Department of Orthopedic Surgery, Drum Tower Hospital Clinical College of Nanjing Medical University, Nanjing, China. Email: drliuzhen@163.com.

Background: There is an acknowledged discrepancy between radiographic and cosmetic parameters for patients with adolescent idiopathic scoliosis (AIS). However, no study has specifically evaluated cosmesis in patients with congenital scoliosis (CS). Therefore, the purpose of this study was to identify the cosmetic differences between patients with CS and case-matched patients with AIS and to investigate the correlation between radiological measurements and clinical cosmetic assessment indices.

Methods: A total of 37 adolescents with CS and 37 sex-, age-, and curve magnitude-matched patients with AIS were included. Cobb angle, shoulder height difference (SHD), coronal balance (CB), T1 tilt, first rib angle (FRA), clavicle angle (CA), clavicle-rib cage intersection (CRCI), and apical vertebra translation (AVT) were measured in the full X-ray of the spine. Shoulder area index 1 (SAI1), shoulder area index 2 (SAI2), shoulder angle (SA), axilla angle (AA), thoracolumbar area index (TLAI), and right and left waist angle difference (RLWAD) were measured on the clinical images from a posterior view. Hump index (HI) was measured in the forward bending photography. All patients completed the Scoliosis Research Society-22 (SRS-22) questionnaire.

Results: No significant difference was noted in the radiographic parameters between the AIS and CS groups ($P > 0.05$). However, patients with CS exhibited significantly lower SAI1 (0.91 *vs.* 0.98; $P = 0.002$) and SAI2 (0.85 *vs.* 0.95; $P = 0.001$) than did the patients with AIS. The SRS-22 scores for self-image and mental health in patients with CS were significantly lower than those in patients with AIS ($P < 0.05$). The correlation coefficients with statistical significance between radiographic and cosmetic measurements in patients with CS and those with AIS ranged from -0.493 to 0.534 and from -0.653 to 0.717 , respectively. None of the correlation coefficients exceeded 0.8, indicating that the current radiological indices only exhibited a limited level of consistency with patients' cosmesis.

Conclusions: As compared with age-, gender-, and curve pattern-matched patients with AIS, patients with CS exhibited worse cosmesis and had clinically significantly lower SRS-22 scores despite having relatively small clinical differences. Although the radiographic parameters may not always align with clinical presentation, this discrepancy could be observed in both patients with CS and those with AIS.

Keywords: Congenital scoliosis (CS); adolescent idiopathic scoliosis (AIS); thoracic curve; radiographic; cosmesis

Submitted Jan 30, 2023. Accepted for publication Jul 19, 2023. Published online Jul 25, 2023.

doi: 10.21037/qims-23-116

View this article at: <https://dx.doi.org/10.21037/qims-23-116>

Introduction

The impairment of cosmetic appearance is a serious concern for patients with scoliosis and their parents (1). Accordingly, achieving better cosmesis constitutes a major goal of surgical intervention (2). Traditionally, the severity of the deformity was assessed and documented via radiography (3,4). However, scoliosis is a three-dimensional (3D) deformity, and the radiographic indices have inherent limitations due to the two-dimensional (2D) single-plane characteristics. Therefore, to obtain a more accurate and comprehensive assessment of the deformity, more attention should be paid to physical asymmetries.

Congenital scoliosis (CS) is a lateral curvature of the spine arising from developmental defects of the axial skeleton (5,6). Typically, CS is classified into 3 types: failures of formation (type I), failures of segmentation (type II), and a combination of both (type III) (7). Type II, which accounts for approximately 9–46% of CS cases, typically has poor prognosis toward progressive deformity (8,9). In clinical practice, patients with CS with failures of segmentation often exhibit a similar radiographic pattern to patients with adolescent idiopathic scoliosis (AIS). However, patients' perceptions regarding their physical appearance differ according to the scoliosis subtype (10). These observations suggest that the cosmetic deformation may vary between patients who otherwise may have a similar radiographic appearance. In addition, previous studies have demonstrated that the current radiological parameters cannot completely reflect the cosmesis in patients with AIS (11,12), underscoring the necessity of quantifying such asymmetries in clinical photographs. To the best of our knowledge, no study has specifically evaluated the cosmesis of patients with type II CS. Therefore, it is still not clear whether the current radiographic parameters could be applied for evaluating the cosmesis of these patients with CS. Consequently, this study was conducted to compare the cosmetic differences and health-related quality of life (HRQoL) between patients with type II CS with long-spanned right-thoracic curve and case-matched patients with AIS and to investigate the correlation between radiologic measurements and clinical cosmetic assessment indices.

Methods

Participants

We retrospectively reviewed patients with CS and failures of segmentation from our database from January 2015 to December 2020. The inclusion criteria were as follows: (I) diagnosed as type II CS with right thoracic curve as the main curve (apex between T5 and T12), (II) with normal sagittal profile (thoracic kyphosis $<50^\circ$ measured from T2 to T12), (III) aged between 10 and 18 years, and (IV) body mass index (BMI) $<25 \text{ kg/m}^2$. The exclusion criteria were as follows: (I) patients with incomplete preoperative radiographic or photographic data, (II) patients with congenital leg-length discrepancy or other deformities that might affect the evaluation of cosmesis, and (III) patients with CS with intraspinal deformities that might influence the evaluation of patient-reported outcomes.

We additionally performed a retrospective review of patients with AIS with right thoracic curves treated in the same period. Individuals in the AIS group were well matched with those in CS group in terms of age, sex, apex, involving segments, and the Cobb angle of the main curve (within 5°).

This study was conducted in accordance with the provisions of the Declaration of Helsinki (as revised in 2013) and was approved by the institutional review board of Nanjing Drum Tower Hospital (No. 2021-LCYJ-DBZ-05). All volunteers were fully informed about the methods, purposes, and risks involved in the study protocol and signed informed consent.

Radiographic parameters

All patients were required to receive a full-spine posterior-anterior (PA) radiograph preoperatively. Parameters of shoulder and trunk balance that are widely used in previous studies were measured with Surgimap software (Nemaris Inc., New York, NY, USA). For radiographic shoulder balance, shoulder height difference (SHD), T1 tilt, first rib angle (FRA), clavicle angle (CA), and clavicle-rib cage intersection (CRCI) difference were measured. SHD was defined as the height difference of the soft tissue shadows

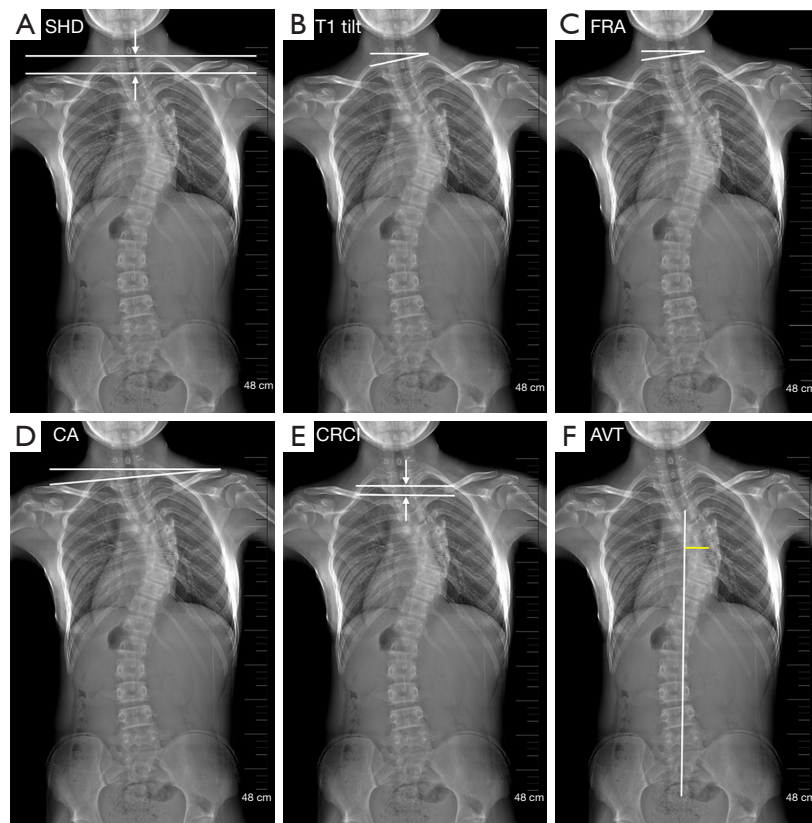


Figure 1 Radiographic parameters. (A) SHD (the two arrows indicate the horizontal lines passing through the soft tissue shadows superior to the acromioclavicular joints); (B) T1 tilt; (C) FRA; (D) CA; (E) CRCI (the two arrows indicate the horizontal lines passing through the intersection between the clavicle and the outer face of the rib cage); (F) AVT. SHD, shoulder height difference; FRA, first rib angle; CA, clavicle angle; CRCI, clavicle-rib cage intersection; AVT, apical vertebra translation.

directly superior to the acromioclavicular joints (*Figure 1A*). T1 tilt was defined as the angle between the horizontal line and the line through the upper endplate of the T1 (*Figure 1B*). FRA was defined as the tilt of a tangential line connecting both the superior borders of first ribs (*Figure 1C*). CA was defined as the angle between the horizontal line and the tangential line connecting the highest 2 points of each clavicle (*Figure 1D*). CRCI was defined as the clavicle intersecting the outer face of the rib cage to a variable height (*Figure 1E*). For trunk balance, the Cobb angle of the major curve, coronal balance (CB), and the apical vertebral translation (AVT) were measured. AVT was defined as the distance from the center of the apex to the central sacral vertical line (*Figure 1F*).

Cosmetic parameters

The clinical photographs were taken simultaneously

with radiographs under the approval of the patients. An experienced technician was assigned to take photos of patients from the back. The patients were photographed in a relaxed, neutral position on level ground with their shoes removed. They were then requested to bend forward up to 90°, and another image was taken with their arms drooping naturally and knees in full extension. The photographs were processed, and the following cosmetic parameters were measured using Image-Pro Plus 6.0 software (Media Cybernetics, Rockville, MD, USA).

- (I) Shoulder area index 1 (SAI1): the area enclosed by the line connecting the inflection points between the shoulder and neck on both sides (s), the horizontal line through the higher axilla (l_1), the superior margins of the shoulders, and the outer margin of the upper arms was divided by the plumb line through the midpoint of the neck into left thoracic area (LTA) and right thoracic area

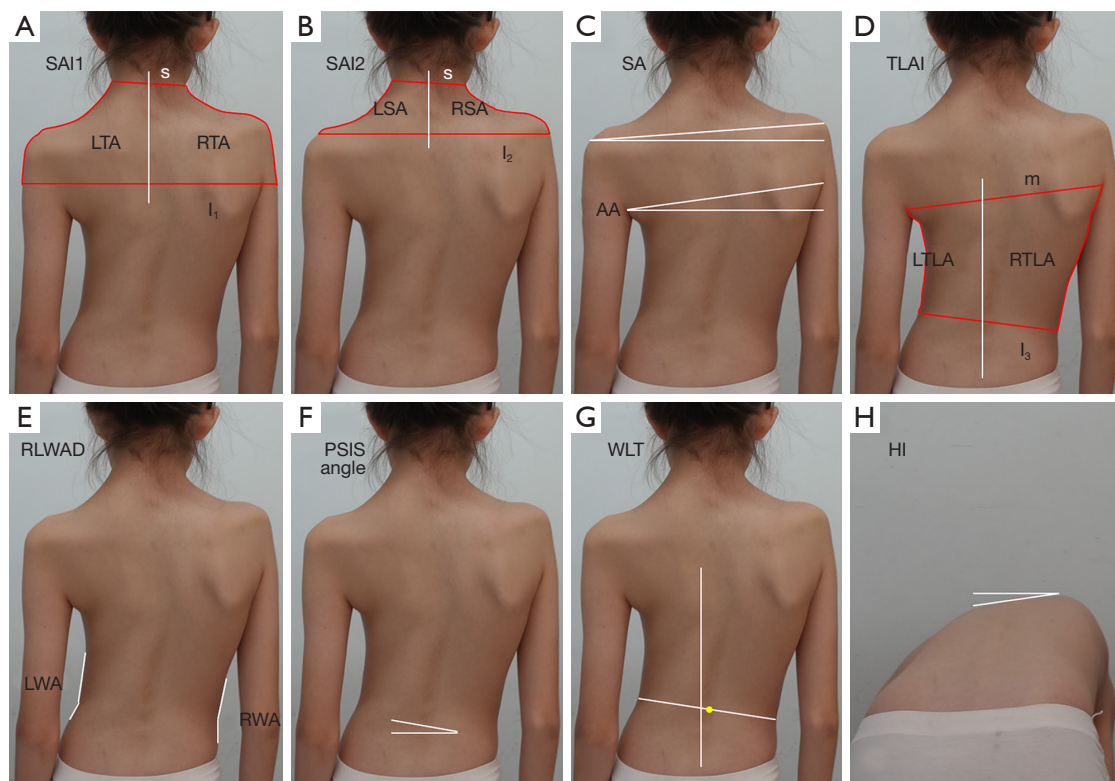


Figure 2 Cosmetic parameters. (A) SAI1, defined as the ratio of LTA to RTA. (B) SAI2, defined as the ratio of LSA to RSA. (C) SA and AA. (D) TLAI, defined as the ratio of the LTLA to the RTLA. (E) RLWAD, defined as the difference between the RWA and LWA. (F) PSIS angle. (G) WLT. (H) HI. These images are published with the patient's parents' consent. s, the line connecting the inflection points between the shoulder and neck on both sides; m, the line joining the inflection point of the left and right axilla; l_1 , the horizontal line through the higher axilla; l_2 , the horizontal line through the lower inflection point between the shoulder and the upper arm; l_3 , the superior margins of the waist, and the line joining the inflection point of the waist in both sides. SAI1, shoulder area index 1; LTA, left thoracic area; RTA, right thoracic area; SAI2, shoulder area index 2; LSA, left shoulder area; RSA, right shoulder area; SA, shoulder angle; AA, axilla angle; TLAI, thoracolumbar area index; LTLA, left thoracolumbar area; RTLA, right thoracolumbar area; RLWAD, right and left waist angle difference; LWA, left waist angle; RWA, right waist angle; PSIS, posterior superior iliac spine; WLT, waistline translation; HI, hump index.

- (RTA). The LTA:RTA ratio was defined as SAI1 (Figure 2A) (11).
- (II) Shoulder area index 2 (SAI2): the area enclosed by s, the horizontal line through the lower inflection point between the shoulder and the upper arm (l_2), and the superior margins of the shoulders was divided by the plumb line through the midpoint of the neck into the area left shoulder area (LSA) and right shoulder area (RSA). The LSA:RSA ratio was defined as SAI2 (Figure 2B) (11).
- (III) Shoulder angle (SA): the angle between the horizontal line and the line through 2 inflection points of the shoulders and upper arms was defined as SA. Positive SA indicates the left shoulder up and the right shoulder down (Figure 2C) (13).
- (IV) Axilla angle (AA): the angle between the horizontal line and the line through both axillae was defined as the AA. Positive AA indicated that the left axilla was up and the right axilla was down (Figure 2C) (13).
- (V) Thoracolumbar area index (TLAI): the area enclosed by the line joining the inflection point of the left and right axilla (m), the superior margins of the waist, and the line joining the inflection point of the waist in both sides (l_3) was divided by the vertical line through the superior point of the natal cleft (CNVL) into the left thoracolumbar area (LTLA) and right thoracolumbar area (RTLTA). The LTLA:RTLTA ratio was defined as

Table 1 Demographic and radiographic characteristics of the 2 groups

Demographic and radiographic data	CS (n=37)	AIS (n=37)	P value
Age (years)	14.2±1.9	14.8±1.8	0.250
Sex (male/female), n	8/29	8/29	–
Cobb angle (°)	56.2±11.4	55.4±10.7	0.739
CB (mm)	–1.3±16.3	–0.7±18.8	0.891
SHD (mm)	–5.3±14.1	–6.6±11.7	0.663
T1 tilt (°)	–2.7±12.1	0.1±5.8	0.214
FRA (°)	–1.8±8.2	–2.0±5.4	0.864
CA (°)	–1.6±3.3	–1.6±2.4	0.948
CRCI (mm)	–4.9±9.6	–5.1±7.8	0.944
AVT (mm)	44.9±19.9	40.6±34.6	0.510

Data are expressed as mean ± standard deviation. CS, congenital scoliosis; AIS, adolescent idiopathic scoliosis; CB, coronal balance; SHD, shoulder height difference; FRA, first rib angle; CA, clavicle angle; CRCI, clavicle-rib cage intersection; AVT, apical vertebra translation.

the TLAI (*Figure 2D*) (14).

- (VI) Right and left waist angle difference (RLWAD): the waist angle was defined as the angle between the line of the lateral part of the chest wall and the tangent line to the iliac crest relief with the vertex at the concavity of the waist on both sides. The difference between the right waist angle (RWA) and left waist angle (LWA) was considered to be the RLWAD (*Figure 2E*) (14).
- (VII) Posterior superior iliac spine (PSIS) angle: the PSIS angle was considered to be the angle between the horizontal and the PSIS line (*Figure 2F*) (15).
- (VIII) Waistline translation (WLT): the WLT was considered to be displacement of the midpoint of the line joining the deepest margins of the right and left curves of the waist with respect to CNVL (*Figure 2G*) (16).
- (IX) Hump index (HI): in the forward-bending photograph, the angle between the horizontal line and the tangential line through the 2 highest points on the left and right lumbar back was defined as the HI (*Figure 2H*) (12).

All the radiographic and cosmetic parameters were measured by 2 experienced surgeons independent of this study, and the average values were applied for further analysis.

Patient-reported outcomes

Patients in both groups were required to completed the Scoliosis Research Society-22 (SRS-22) questionnaire

preoperatively, which evaluates HRQoL across 5 domains, including pain, function, self-image, and mental health.

Statistical analysis

All statistical analyses were carried out using SPSS version 22.0 (IBM Corp., Armonk, NY, USA), and the statistical data are presented as mean ± standard deviation (SD). The interobserver reproducibility and consistency were estimated via the intraclass correlation coefficient (ICC). Radiographic and cosmetic parameters were compared between groups with paired-sample *t*-tests, chi-squared tests, and Fisher exact tests, based on the parametric qualities of the parameters analyzed. Pearson correlation analysis was applied to assess the correlation between radiographic parameters and cosmetic parameters in both groups. A *P* value of <0.05 was considered statistically significant.

Results

Demographic Data

A total of 37 patients with type II with CS were matched to 37 patients with AIS in terms of age, sex, and curve magnitude. The mean age was 14.2±1.9 years old in those with CS and 14.8±1.8 years in those with AIS (*P*=0.250; *Table 1*). Both groups included 8 male patients and 29 female patients. All the patients with CS had a long-spanned right thoracic curve due to unilateral unsegmented bar. The unsegmented bar was located at the

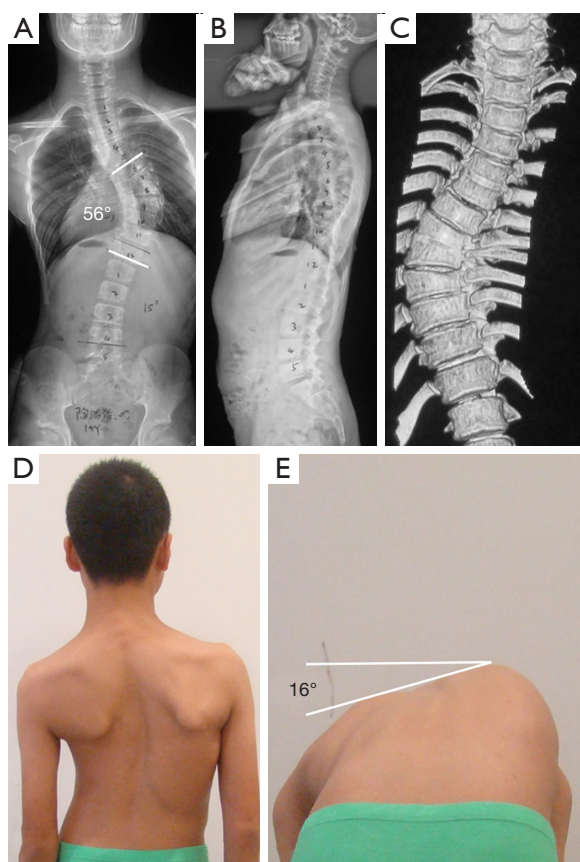


Figure 3 Radiographs and photographs of a 14-year-old boy with main thoracic congenital scoliosis secondary to T7–8 failures of segmentation. (A–C) The apex was at T9, and 7 segments were involved in the major curve. The Cobb angle of the main curve was 56°. (D,E) The cosmetic parameters measure on the photographs including SAI1, SAI2, SA, AA, TLAI, RLWAD, PSIS angle, WLT, and HI, were 0.71, 0.60, -6.1° , -7.5° , 0.49, -13° , 14° , 22.9 mm, and -15.3° , respectively. Images D and E are published with the patient's parents' consent. SAI1, shoulder area index 1; SAI2, shoulder area index 2; SA, shoulder angle; AA, axilla angle; TLAI, thoracolumbar area index; RLWAD, right and left waist angle difference; PSIS, posterior superior iliac spine; WLT, waistline translation; HI, hump index.

midthoracic or lower thoracic vertebra, and the mean level of affected vertebra was 2.9.

Comparison of the patient-reported outcomes and radiographic and cosmetic data between the groups

Patients with type II CS with long-spanned right thoracic curves were matched with patients with AIS with respect to

the location of the apex, involving segments, and the major curve magnitude (Figures 3,4). In addition, comparisons of other radiological parameters that were intended to evaluate patients' cosmesis in radiographs, including CB, SHD, T1 tilt, FRA, CA, CRCI, and AVT, did not differ between the 2 groups ($P>0.05$; Table 1).

The cosmetic data are summarized in Table 2. The average SA was $-0.4^\circ \pm 2.7^\circ$ in the CS group and $-0.1^\circ \pm 2.4^\circ$ in the AIS group ($P=0.582$). The average AA was $-2.3^\circ \pm 3.3^\circ$ in the CS group and $-0.1^\circ \pm 2.4^\circ$ in the AIS group ($P=0.128$). However, SAI1 was significantly lower in patients with CS than in patients with AIS (0.91 ± 0.09 vs. 0.98 ± 0.08 ; $P=0.002$). Similarly, SAI2 was also significantly lower in the CS group than in the AIS group (0.85 ± 0.14 vs. 0.95 ± 0.09 ; $P=0.001$), which indicates that patients with CS exhibited a more prominent areal imbalance between the left and right shoulders as compared to the patients with AIS. With regard to the general thoracolumbar areal symmetry, TLAI was significantly lower in the CS group than in the AIS group (0.70 ± 0.14 vs. 0.84 ± 0.12 ; $P<0.001$). The average RLWAD was $1.6^\circ \pm 11.7^\circ$ in the CS group and $-0.2^\circ \pm 6.3^\circ$ in the AIS group ($P=0.404$). The average PSIS angle was $7.9^\circ \pm 8.0^\circ$ in the CS group and $6.9^\circ \pm 7.0^\circ$ in the AIS group ($P=0.558$). The average WLT was 7.2 ± 6.8 mm in the CS group and 5.5 ± 6.6 mm in the AIS group ($P=0.264$). As for the rib hump deformity, a comparison of HI showed no significant difference between the CS and AIS groups ($-6.8^\circ \pm 8.1^\circ$ vs. $-7.7^\circ \pm 5.2^\circ$; $P=0.552$; Table 2). The interobserver ICC for the above-mentioned measurements ranged from 0.75 to 0.92, suggesting good interobserver consistency and conformity of all parameters between the 2 observers.

The SRS-22 scores of each domain for both groups are shown in Figure 5. No significant differences were noted in the function domain or pain domain between groups ($P>0.05$). However, the SRS-22 self-image scores (3.5 ± 0.7 vs. 3.8 ± 0.7 ; $P=0.033$) and mental health scores (3.4 ± 0.6 vs. 3.7 ± 0.4 ; $P=0.020$) in patients with CS were significantly lower than those in patients with AIS.

Correlation between radiographic and cosmetic measurements

Pearson correlation coefficient analysis was further performed to evaluate the correlations between radiographic and cosmetic measurements in both groups. For patients with CS, the correlation coefficients with statistical significance between radiographic and cosmetic parameters ranged between -0.493 and 0.534 (Table 3). Among these

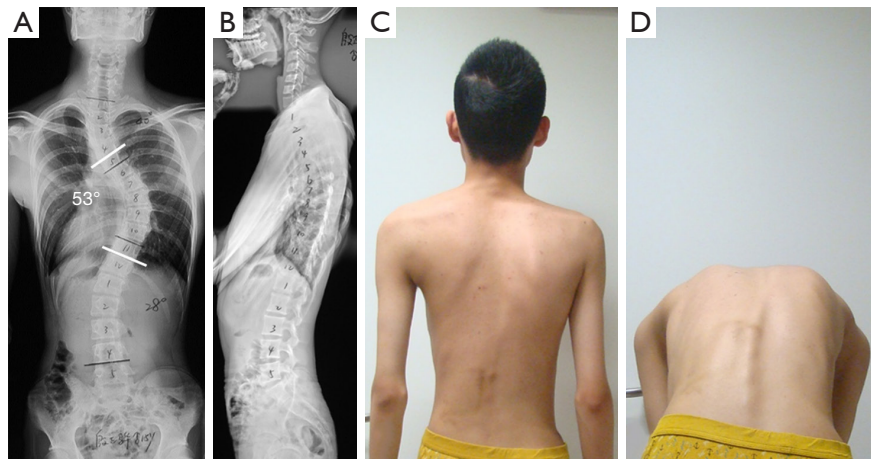


Figure 4 Radiographs and photographs of a 15-year-old boy with main thoracic idiopathic scoliosis. (A,B) The apex was at the T9, and 7 segments were involved in the major curve. The Cobb angle of the main curve was 53°. (C,D) The cosmetic parameters measure on the photographs including SAI1, SAI2, SA, AA, TLAI, RLWAD, PSIS angle, WLT, and HI were 1.06, 1.08, 1.3°, -5.1°, 0.93, -7°, 8°, 6.4 mm, and -3.3°, respectively. Despite exhibiting similar radiographic curve patterns, patients with AIS demonstrated better cosmesis and trunk symmetry. Images C and D are published with the patient's parents' consent. SAI1, shoulder area index 1; SAI2, shoulder area index 2; SA, shoulder angle; AA, axilla angle; TLAI, thoracolumbar area index; RLWAD, right and left waist angle difference; PSIS, posterior superior iliac spine; WLT, waistline translation; HI, hump index; AIS, adolescent idiopathic scoliosis.

Table 2 Comparison of cosmetic characteristics between groups

Cosmetic data	CS (n=37)	AIS (n=37)	P value
SAI1	0.91±0.09	0.98±0.08	0.002
SAI2	0.85±0.14	0.95±0.09	0.001
SA (°)	-0.4±2.7	-0.1±2.4	0.582
AA (°)	-2.3±3.3	-0.1±2.4	0.128
TLAI	0.70±0.14	0.84±0.12	<0.001
RLWAD (°)	1.6±11.7	-0.2±6.3	0.404
PSIS angle (°)	7.9±8.0	6.9±7.0	0.558
WLT (mm)	7.2±6.8	5.5±6.6	0.264
HI (°)	-6.8±8.1	-7.7±5.2	0.552

Data are expressed as mean ± standard deviation. CS, congenital scoliosis; AIS, adolescent idiopathic scoliosis; SAI1, shoulder area index 1; SAI2, shoulder area index 2; SA, shoulder angle; AA, axilla angle; TLAI, thoracolumbar area index; RLWAD, right and left waist angle difference; PSIS, posterior superior iliac spine; WLT, waistline translation; HI, hump index.

parameters, the highest correlation ($r=0.534$) was found between FRA and SAI2, while the lowest correlation ($r=0.374$) was found between T1 tilt and AA. Regarding shoulder balance, T1 tilt was significantly correlated with AA ($r=0.374$; $P=0.023$). FRA was significantly correlated with SAI1 ($r=0.521$, $P=0.001$) and SAI2 ($r=0.534$; $P=0.001$), and CA also showed a significant correlation with SAI1

($r=0.386$; $P=0.020$) and SAI2 ($r=0.509$; $P=0.002$). CRCI exhibited a significant positive correlation with AA ($r=0.504$; $P=0.001$). Regarding trunk balance, only AVT exhibited a significant correlation with TLAI ($r=-0.493$; $P=0.019$), PSIS angle ($r=0.311$; $P=0.007$), and WLT ($r=0.512$; $P=0.021$).

For patients with AIS, the correlation coefficients with statistical significance between radiographic and cosmetic

parameters ranged between -0.653 and 0.717 (Table 4). Of these parameters, the highest correlation ($r=0.717$) was found between CRCI and SA, while the lowest correlation ($r=0.338$) was found between T1 tilt and SAI1. Regarding shoulder balance, CA had the significantly highest correlation with SAI1 ($r=0.549$; $P=0.014$), followed by FRA ($r=0.424$; $P=0.005$), CRCI ($r=0.387$; $P=0.018$), and T1 tilt ($r=0.338$; $P=0.041$). Additionally, CA also exhibited the highest correlation with SAI2 ($r=0.559$; $P=0.027$), followed by CRCI ($r=0.473$; $P=0.002$), T1 tilt ($r=0.385$; $P=0.018$), and FRA ($r=0.377$; $P=0.021$). Furthermore, SA had a significant positive correlation with CRCI ($r=0.717$; $P<0.001$), FRA

($r=0.589$; $P<0.001$), and T1 tilt ($r=0.532$; $P=0.001$). AA had a significant positive correlation with T1 tilt ($r=0.661$; $P<0.001$) and CRCI ($r=0.716$; $P<0.001$). Regarding trunk balance, CRCI had significant positive correlation with TLAI ($r=0.420$; $P=0.010$), while AVT exhibited a significant correlation with TLAI ($r=-0.653$; $P=0.003$), PSIS angle ($r=0.457$; $P=0.004$), and WLT ($r=0.549$; $P=0.014$).

However, for both the CS and AIS groups, none of the correlation coefficients between radiographic and cosmetic parameters were greater than 0.8, indicating that the radiographic parameters only partially reflected patients' cosmesis.

Discussion

A comprehensive assessment of the cosmesis of patients with scoliosis is integral to the surgical decision-making process (13). To date, this is the first study that has systematically evaluated the cosmetic indices of patients with CS with segmentation defects and compared them with those of case-matched patients with AIS. We report that patients with CS were more likely to have worse cosmetic asymmetry compared with curve-matched patients with AIS and that radiographic parameters could not fully reflect patients' cosmetic appearance.

A disturbance in body image might be the primary reason for patients with scoliosis to seek medical consultation (17). Despite this, the clinical management and surgical strategies are routinely based on a single

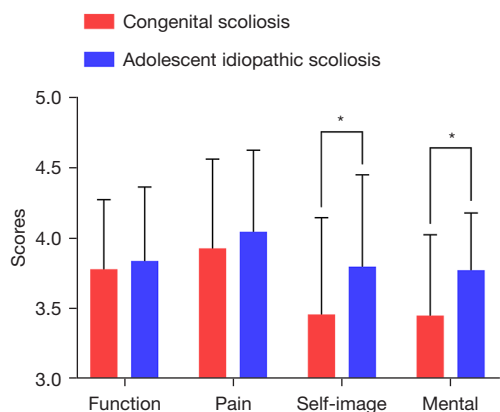


Figure 5 Comparison of SRS-22 outcome scores between groups. *, P value <0.05 versus patients with AIS. AIS, adolescent idiopathic scoliosis; SRS-22, Scoliosis Research Society-22.

Table 3 Correlations between radiographic and cosmetic measurements in patients with CS

Variables	Cobb	CB	SHD	T1 tilt	FRA	CA	CRCI	AVT
SAI1	0.074	-0.041	0.104	0.194	0.521**	0.386*	0.083	0.303
SAI2	0.128	-0.089	0.010	0.157	0.534**	0.509**	0.099	0.265
SA	0.245	-0.214	-0.218	0.250	0.177	0.071	0.299	0.380
AA	0.079	-0.024	-0.039	0.374*	-0.058	0.071	0.504**	0.269
TLAI	-0.013	-0.251	-0.245	0.317	0.363	0.287	0.341	-0.493*
RLWAD	0.232	0.264	-0.080	-0.155	0.196	0.030	-0.194	-0.042
PSIS angle	-0.193	0.184	-0.112	-0.112	-0.062	-0.045	-0.083	0.311**
WLT	0.241	0.112	-0.047	0.144	0.080	0.177	0.236	0.512*
HI	-0.272	-0.129	-0.128	0.127	0.118	0.333*	0.042	0.121

*, significant at $P<0.05$; **, significant at $P<0.01$. CS, congenital scoliosis; CB, coronal balance; SHD, shoulder height difference; FRA, first rib angle; CA, clavicle angle; CRCI, clavicle-rib cage intersection; AVT, apical vertebra translation; SAI1, shoulder area index 1; SAI2, shoulder area index 2; SA, shoulder angle; AA, axilla angle; TLAI, thoracolumbar area index; RLWAD, right and left waist angle difference; PSIS, posterior superior iliac spine; WLT, waistline translation; HI, hump index.

Table 4 Correlations between radiographic and cosmetic measurements in patients with AIS

Variables	Cobb	CB	SHD	T1 tilt	FRA	CA	CRCI	AVT
SAI1	-0.124	0.019	0.262	0.338*	0.424**	0.549*	0.387*	0.218
SAI2	-0.079	-0.051	0.148	0.385*	0.377*	0.559*	0.473**	0.193
SA	0.025	0.115	-0.180	0.532**	0.589**	0.176	0.717**	0.144
AA	-0.033	-0.034	-0.254	0.661**	0.188	0.200	0.716**	-0.432
TLAI	-0.358	-0.281	0.174	0.245	0.276	0.277	0.420*	-0.653**
RLWAD	0.258	0.169	0.214	0.016	-0.250	-0.164	-0.013	-0.148
PSIS angle	-0.278	0.217	-0.169	0.092	-0.006	-0.089	-0.194	0.457**
WLT	0.139	0.147	-0.084	0.014	-0.039	-0.020	-0.148	0.549*
HI	-0.282	-0.033	-0.065	0.468	0.223	0.427	0.150	-0.054

*, significant at $P < 0.05$; **, significant at $P < 0.01$. AIS, adolescent idiopathic scoliosis; CB, coronal balance; SHD, shoulder height difference; FRA, first rib angle; CA, clavicle angle; CRCI, clavicle-rib cage intersection; AVT, apical vertebra translation; SAI1, shoulder area index 1; SAI2, shoulder area index 2; SA, shoulder angle; AA, axilla angle; TLAI, thoracolumbar area index; RLWAD, right and left waist angle difference; PSIS, posterior superior iliac spine; WLT, waistline translation; HI, hump index.

perspective, namely radiographic deformity. The association between radiographic patterns and the cosmetic deformity is not well-documented. In clinical practice, patients with similar radiographic curvatures may have markedly different cosmetic appearances, highlighting the necessity of evaluating and quantifying patients' physical appearance. However, thus far, no study has reported the cosmetic features of patients with CS and compared them with those of patients with AIS.

We performed a case-matched study between patients with CS and AIS. To ensure the comparability between the 2 groups, only patients with type II CS were included because this type of patient typically shows regular arch-shaped scoliosis, similarly to patients with AIS. In addition, to minimize the measurement bias in cosmetic images, it was ensured that demographic data, including age, gender, and BMI, were comparable between the 2 groups. Furthermore, patients with CS were well matched with patients with AIS with respect to the Cobb angle, the location of the apex, and the involving scoliotic segments. In this study, 5 radiographic parameters (SHD, T1 tilt, FRA, CA, and CRCI) were employed to reflect the radiographic shoulder balance, while CB and AVT were used to assess the radiographic alignment of the head and waist over the pelvic balance, respectively. The results showed that no significant difference was observed in the radiographic indices between the 2 groups, suggesting a similar radiographic appearance between the 2 different scoliosis types.

In the comparison of cosmetic deformity, SAI1 and

SAI2, serving as supplementary indices to assess the gross view of areal shoulder balance, were significantly lower in patients with CS than in patients with AIS ($P < 0.05$). Moreover, in the evaluation of cosmetic trunk balance, TLAI, a parameter for indicating patients' waistline asymmetries, was significantly lower in the CS group than in the AIS group. This finding might be related to the inherent developmental characteristics of patients with CS. The contracture of soft tissues in the concave sides and the asymmetrical growth potential of convex and concave sides in patients with CS may contribute to the significant bilateral shoulder areal discrepancy (5). Consequently, our results revealed that the asymmetry of patients with CS cosmesis was more severe and prominent compared with that of case-matched patients with AIS, especially as it relates to the shoulder imbalance.

In the study performed by Qiu *et al.* (11), the consistency between the radiological and cosmetic appearance of patients with AIS with double thoracic curves was investigated for the first time. In the study's results, none of the correlation coefficients were above 0.8, indicating the presence of discrepancies between radiographic and cosmetic shoulder balance. Similarly, in our study of patients with AIS, significant correlation coefficients were observed between radiological and cosmetic measurements, ranging between -0.653 and 0.717, which is consistent with earlier findings (11,16,18-20). With respect to curve pattern-matched patients with CS, significant correlation coefficients between radiographic and cosmetic indices

were found, ranging from -0.493 to 0.534 and with the highest correlation ($r=0.534$) identified between FRA and SAI2. Nevertheless, none of the coefficients were higher than 0.6 (less than excellent), suggesting that radiographic indices are only partially parallel cosmetic deformities. Notably, the Cobb angle, the most commonly used parameter in assessing the radiographic deformity of scoliosis, demonstrated a poor association with all cosmetic parameters in both patients with AIS and those with CS. In fact, cosmetic symmetry incorporates a variety of visual cues, with each varying significantly in different patients. Consequently, these findings inform surgeons that merely relying on the radiographic indices may not be prudent when evaluating patients' overall deformities.

Matamalas *et al.* (20) reported there to be a poor correlation between objective measurements and subjective patients' perceived cosmesis. Thus, gathering patient input in the surgical planning phase is critical to ensuring a favorable postoperative outcome (21-23). The SRS-22 questionnaire, currently the most widely used tool for assessing health measures across different clinical domains, has been validated among different types of patients with scoliosis (24,25). In this study, we found that patients with CS exhibited significantly lower scores in self-image and mental health domains than those in patients with AIS. We speculate that the lower scores of self-image and mental health in patients with CS may be attributed to the more severe cosmetic deformities. Furthermore, previous studies have reported that the progression rates for individuals with type II CS, characterized by an unsegmented bar located at the thoracic spine, range from 2° to 6.5° per year (26,27). Therefore, being born with a congenital disease, experiencing rapid deterioration rates, and undergoing long-term repeated hospital visits may be factors that contribute to a decline of HRQoL in patients with CS.

There are several limitations in our study. First, despite photographs being the most commonly used tool for assessing patients' cosmesis, they may still be inadequate in accurately depicting a 3D deformity due to their inherent 2D nature, especially in patients with higher vertebral rotation (28). Second, in order to minimize measurement error, 1 trained investigator was assigned to take all photographs. Additionally, we selected patients with CS and those with AIS with comparable BMIs to eliminate the interference of the soft tissue occlusion. However, measurement bias may still exist due to the variation in patients' postures. Third, to protect patients'

privacy, we only evaluated cosmesis from the posterior view. Introducing novel parameters that are taken from the anterior and lateral view may contribute to a more comprehensive evaluation of cosmesis. In addition, due to the cross-sectional study design, the radiographs and photographs of our cohorts were taken simultaneously. Further longitudinal studies will help clinicians monitor the transformation of deformity over time.

Conclusions

As compared with age-, gender-, and curve pattern-matched patients with AIS, patients with CS are more likely to have worse cosmesis despite the clinical differences being relatively small. In addition, the radiographic parameters may not always align with clinical presentation, with a similar discrepancy being observed in patients with CS as in patients with AIS.

Acknowledgments

Funding: This work was supported by the National Natural Science Foundation of China (No. 82072518 to Z Liu), the Affiliated Drum Tower Hospital, Medical School of Nanjing University (No. 2022-LCYJ-MS-22 to Z Liu), and the Jiangsu Provincial Medical Innovation Center of Orthopedic Surgery (No. CXZX202214 to Y Qiu).

Footnote

Conflicts of Interest: All authors have completed the ICMJE uniform disclosure form (available at <https://qims.amegroups.com/article/view/10.21037/qims-23-116/coif>). ZL received support from the National Natural Science Foundation of China (No. 82072518) and the Affiliated Drum Tower Hospital, Medical School of Nanjing University (No. 2022-LCYJ-MS-22). YQ received the research support from Jiangsu Provincial Medical Innovation Center of Orthopedic Surgery (No. CXZX202214). The other authors have no conflicts of interest to declare.

Ethical Statement: The authors are accountable for all aspects of the work in ensuring that questions related to the accuracy or integrity of any part of the work are appropriately investigated and resolved. The current study was conducted conformed to the provisions of the Declaration of Helsinki (as revised in 2013) and was approved by the institutional

review board of Nanjing Drum Tower Hospital (No. 2021-LCYJ-DBZ-05). All volunteers were fully informed about the methods, purposes, and risks involved in the study protocol and signed the informed consent.

Open Access Statement: This is an Open Access article distributed in accordance with the Creative Commons Attribution-NonCommercial-NoDerivs 4.0 International License (CC BY-NC-ND 4.0), which permits the non-commercial replication and distribution of the article with the strict proviso that no changes or edits are made and the original work is properly cited (including links to both the formal publication through the relevant DOI and the license). See: <https://creativecommons.org/licenses/by-nc-nd/4.0/>.

References

- Chan CYW, Chong JSL, Lee SY, Ch'ng PY, Chung WH, Chiu CK, Hasan MS, Kwan MK. Parents'/Patients' Perception of the Informed Consent Process and Surgeons' Accountability in Corrective Surgery for Adolescent Idiopathic Scoliosis: A Prospective Study. *Spine (Phila Pa 1976)* 2020;45:1661-7.
- Menon KV, Tahasildar NS. What Constitutes Shoulder Imbalance in Adolescent Idiopathic Scoliosis? Aesthetic Threshold for Surgical Correction. *World Neurosurg* 2020;138:e827-38.
- Han SM, Yang C, Wen JX, Cao L, Wu HZ, Wu TH, Yang HH, Zhao HY, Chen LL, Li NN, Yu BH, Gao BL, Wu WJ, Guo Z. Morphology and deformity of the shoulder and pelvis in the entire spine radiographs of adolescent idiopathic scoliosis. *Quant Imaging Med Surg* 2023;13:3266-78.
- Wu C, Ou W, Gao M, Li J, Liu Q, Kang Z, Wang H, Li Z, Wang X, Zhang S, Zhang Y, Jin F, Zhang K, Li X. Digital measurement and correlation analysis of coronal and sagittal anatomic parameters in the radiographs of adolescent patients with idiopathic scoliosis. *Eur Spine J* 2023;32:1161-72.
- Mackel CE, Jada A, Samdani AF, Stephen JH, Bennett JT, Baaj AA, Hwang SW. A comprehensive review of the diagnosis and management of congenital scoliosis. *Childs Nerv Syst* 2018;34:2155-71.
- Wu N, Liu L, Zhang Y, Wang L, Wang S, Zhao S, Li G, Yang Y, Lin G, Shen J, Wu Z, Qiu G, Zhang TJ. Retrospective Analysis of Associated Anomalies in 636 Patients with Operatively Treated Congenital Scoliosis. *J Bone Joint Surg Am* 2023;105:537-48.
- Wang S, Chai X, Yan Z, Zhao S, Yang Y, Li X, Niu Y, Lin G, Su Z, Wu Z, Zhang TJ, Wu N. Novel FGFR1 Variants Are Associated with Congenital Scoliosis. *Genes (Basel)* 2021.
- Sebaaly A, Daher M, Salameh B, Ghoul A, George S, Roukoz S. Congenital scoliosis: a narrative review and proposal of a treatment algorithm. *EFORT Open Rev* 2022;7:318-27.
- Liu Z, Cheng Y, Hai Y, Chen Y, Liu T. Developments in Congenital Scoliosis and Related Research from 1992 to 2021: A Thirty-Year Bibliometric Analysis. *World Neurosurg* 2022;164:e24-44.
- Hsu PC, Feng CK, Huang SH, Chiu JW, Chou CL, Yang TF. Health-related quality of life in children and adolescent with different types of scoliosis: A cross-sectional study. *J Chin Med Assoc* 2019;82:161-5.
- Qiu XS, Ma WW, Li WG, Wang B, Yu Y, Zhu ZZ, Qian BP, Zhu F, Sun X, Ng BK, Cheng JC, Qiu Y. Discrepancy between radiographic shoulder balance and cosmetic shoulder balance in adolescent idiopathic scoliosis patients with double thoracic curve. *Eur Spine J* 2009;18:45-51.
- Qiu Y, Qiu XS, Ma WW, Wang B, Yu Y, Zhu ZZ, Qian BP, Zhu F, Sun X, Ng BK, Cheng JC. How well do radiological measurements correlate with cosmetic indices in adolescent idiopathic scoliosis with Lenke 5, 6 curve types? *Spine (Phila Pa 1976)* 2010;35:E882-8.
- Matamalas A, Bagó J, D'Agata E, Pellisé F. Reliability and validity study of measurements on digital photography to evaluate shoulder balance in idiopathic scoliosis. *Scoliosis* 2014;9:23.
- Matamalas A, Bagó J, D'Agata E, Pellisé F. Validity and reliability of photographic measures to evaluate waistline asymmetry in idiopathic scoliosis. *Eur Spine J* 2016;25:3170-9.
- Patias P, Grivas TB, Kaspiris A, Aggouris C, Drakoutos E. A review of the trunk surface metrics used as Scoliosis and other deformities evaluation indices. *Scoliosis* 2010;5:12.
- Sharma S, Bünger CE, Andersen T, Sun H, Wu C, Hansen ES. Do postoperative radiographically verified technical success, improved cosmesis, and trunk shift corroborate with patient-reported outcomes in Lenke 1C adolescent idiopathic scoliosis? *Eur Spine J* 2015;24:1462-72.
- Suresh S, Perera P, Izatt MT, Labrom RD, Askin GN, Little JP. Development and validation of a semi-automated measurement tool for calculating consistent and reliable surface metrics describing cosmesis in Adolescent Idiopathic Scoliosis. *Sci Rep* 2023;13:5574.
- Chung WH, Chiu CK, Ng SJ, Goh SH, Chan CYW,

- Kwan MK. How Common Is Medial and Lateral Shoulder Discordance in Lenke 1 and 2 Curves?: A Preoperative Analysis of Medial and Lateral Shoulder Balance Among 151 Lenke 1 and 2 Adolescent Idiopathic Scoliosis Patients. *Spine (Phila Pa 1976)* 2019;44:E480-6.
19. Sharma S, Andersen T, Wu C, Sun H, Wang Y, Hansen ES, Bünger CE. How well do Radiologic Assessments of Truncal and Shoulder Balance Correlate With Cosmetic Assessment Indices in Lenke 1C Adolescent Idiopathic Scoliosis? *Clin Spine Surg* 2016;29:341-51.
 20. Matamalas A, Bagó J, D'Agata E, Pellisé F. Does patient perception of shoulder balance correlate with clinical balance? *Eur Spine J* 2016;25:3560-7.
 21. Li J, Tseng C, Yuan Y, Jiang D, Qian Z, Hu Z, Zhu Z, Qiu Y, Liu Z. Determining the association between the radiographic parameters and the SRS-22 scores in Chinese female patients with adolescent idiopathic scoliosis: does curve pattern matter? *Br J Neurosurg* 2021. [Epub ahead of print]. doi: 10.1080/02688697.2021.1875396.
 22. Albayrak A, Buyuk AF, Ucpunar H, Balioglu MB, Kargin D, Kaygusuz MA. Pre- and postoperative photographs and surgical outcomes in patients with Lenke type 1 adolescent idiopathic scoliosis. *Spine (Phila Pa 1976)* 2015;40:469-74.
 23. Albayrak A, Balioglu MB, Misir A, Kargin D, Tacal MT, Atici Y, Kaygusuz MA. Preoperative and Postoperative Photographs and Surgical Outcomes of Patients With Kyphosis. *Spine (Phila Pa 1976)* 2016;41:E1185-90.
 24. Farley FA, Li Y, Jong N, Powell CC, Speers MS, Childers DM, Caird MS. Congenital scoliosis SRS-22 outcomes in children treated with observation, surgery, and VEPTR. *Spine (Phila Pa 1976)* 2014;39:1868-74.
 25. Stone LE, Upasani VV, Pahys JM, Fletcher ND, George SG, Shah SA, Bastrom TP, Bartley CE, Lenke LG, Newton PO, Kelly MP; Harms Study Group. SRS-22r Self-Image After Surgery for Adolescent Idiopathic Scoliosis at 10-year Follow-up. *Spine (Phila Pa 1976)* 2023;48:683-7.
 26. Marks DS, Qaimkhani SA. The natural history of congenital scoliosis and kyphosis. *Spine (Phila Pa 1976)* 2009;34:1751-5.
 27. Hu B, Wang L, Song Y, Yang X, Liu L, Zhou C. Multiple Hemivertebrae: The Natural History and Treatment of 50 Patients. *Orthop Surg* 2023;15:1579-89.
 28. Hurtado-Avilés J, León-Muñoz VJ, Sanz-Mengibar JM, Santonja-Renedo F, Andújar-Ortuño P, Collazo-Diéguez M, Ferrer-López V, Roca-González J, Kurochka KS, Cabañero-Castillo M, Alcaraz-Belzunces J, Ruiz-Cambra NA, Fuentes-Santos VE, Ponce-Garrido AB, González-Ballester M, Sánchez-Martínez FJ, Campuzano-Melgarejo A, Fiorita PG, Santonja-Medina F. Validity and reliability of a computer-assisted system method to measure axial vertebral rotation. *Quant Imaging Med Surg* 2022;12:1706-15.

Cite this article as: Xu Y, Liu C, Li D, Cai Y, Hu Z, Zhu Z, Qiu Y, Liu Z. Cosmetic evaluation in type II congenital scoliosis with long-spanned curve: a case-matched comparison with adolescent idiopathic scoliosis. *Quant Imaging Med Surg* 2023;13(9):6164-6175. doi: 10.21037/qims-23-116