



Artery of Huebner stroke chameleon presenting as central nervous system lymphoma: a case description

Carlo Augusto Mallio^{1,2^}, Federica Vaccarino^{1,2}, Marco Parillo^{1,2}, Ombretta Annibali^{1,3}, Luigi Rigacci^{1,3}, Guido M. Meduri^{1,4}, Fabio Pilato^{1,5}, Bruno Beomonte Zobel^{1,2}, Vincenzo Di Lazzaro^{1,5}

¹Fondazione Policlinico Universitario Campus Bio-Medico, Roma, Italy; ²Research Unit of Radiology, Department of Medicine and Surgery, Università Campus Bio-Medico di Roma, Roma, Italy; ³Research Unit of Hematology and Stem Cell Transplantation, Department of Medicine and Surgery, Università Campus Bio-Medico di Roma, Roma, Italy; ⁴Research Unit of Nuclear Medicine, Department of Medicine and Surgery, Università Campus Bio-Medico di Roma, Roma, Italy; ⁵Research Unit of Neurology, Department of Medicine and Surgery, Università Campus Bio-Medico di Roma, Roma, Italy

Correspondence to: Carlo Augusto Mallio, MD, PhD. Fondazione Policlinico Universitario Campus Bio-Medico, Via Alvaro del Portillo, 200, 00128 Rome, Italy; Research Unit of Radiology, Department of Medicine and Surgery, Università Campus Bio-Medico di Roma, Roma, Italy. Email: c.mallio@policlinicocampus.it.

Submitted Apr 03, 2023. Accepted for publication Aug 02, 2023. Published online Aug 21, 2023.

doi: 10.21037/qims-23-437

View this article at: <https://dx.doi.org/10.21037/qims-23-437>

Introduction

Stroke of the anterior cerebral artery or its branches is uncommon and the clinical manifestations can be variable, and sometimes not typical for stroke (1). Heubner's artery and medial striate artery infarction typically presents with contralateral face and arm weakness, as they supply the anterior limb of internal capsule, the anterior portion of the caudate nucleus, and the anterior perforated substance (2). However, other more subtle symptoms can be present including abulia, akinetic mutism, and neglect syndromes (1,2).

Central nervous system (CNS) lymphoma can be encountered as primary CNS lymphoma an extra-nodal form of lymphoma without systemic involvement or, more commonly, as secondary CNS lymphoma in patients with systemic diseases in aggressive subtypes of non-Hodgkin lymphomas (3,4).

In this paper, we provide the first description of how a stroke of the Heubner's artery can be misdiagnosed as CNS lymphoma.

Case presentation

A 71-year-old man was admitted to the emergency department due to the slowly progressive onset of cognitive-motor impairment, abulia, and drowsiness over the last week. The patient had unremarkable past medical history.

Unenhanced head computed tomography (CT) scan showed no intracranial hemorrhage and two small hypodensities at the head of right caudate nucleus (*Figure 1A*). Three days later, the patient underwent brain magnetic resonance imaging (MRI), showing focal lesion at the head of right caudate nucleus, with high signal on Fluid-Attenuated Inversion Recovery sequence (*Figure 1B*), and foci of restricted diffusion within the lesion (*Figure 1C, 1D*). Gadolinium-based contrast agent enhanced brain MRI and spectroscopy were also performed. The examination revealed intralesional inhomogeneous contrast-enhancement (*Figure 1E*), decreased levels of N-acetyl-aspartate (NAA) and choline (Cho) peak (Cho/NAA ratio =2.10). Based on the suspect of CNS lymphoma, the patient

[^] ORCID: 0000-0002-0149-0801.

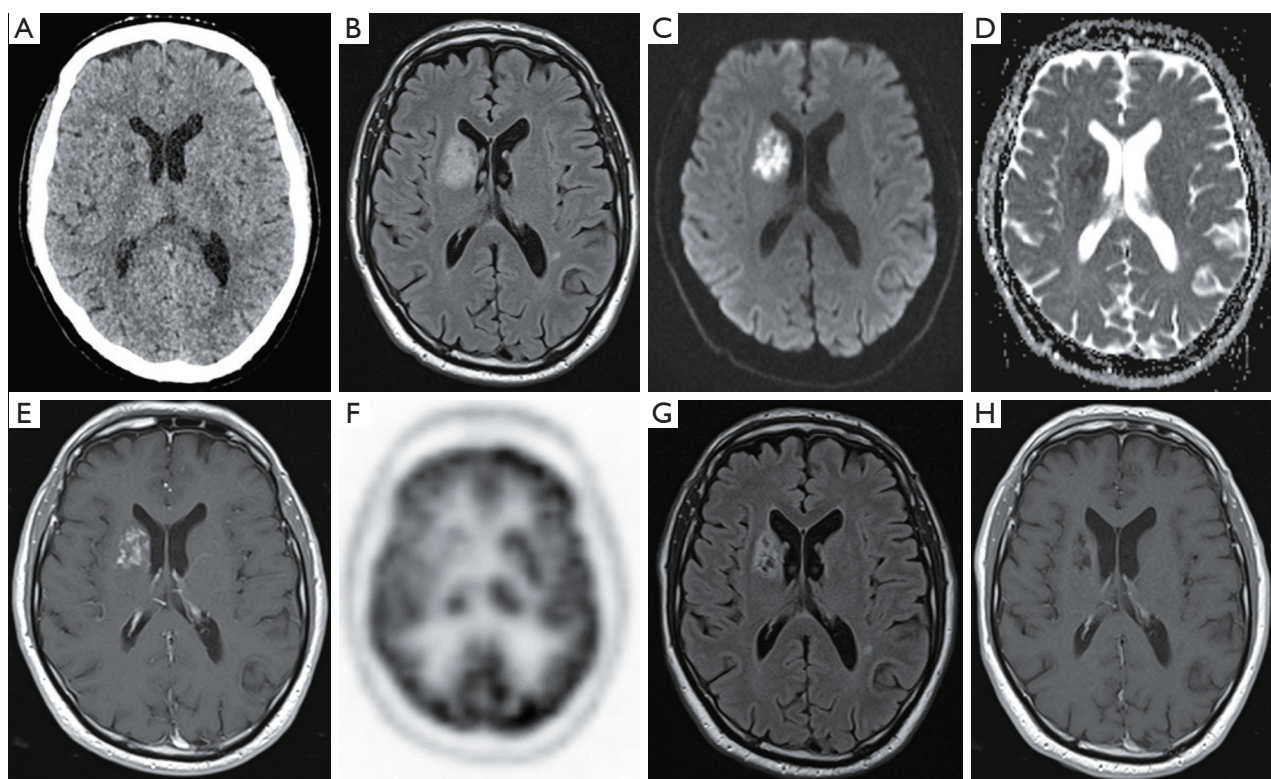


Figure 1 Unenhanced head CT showing small hypodensities at the right caudate nucleus head (A). Unenhanced brain MRI (B-D) demonstrating a wider right caudate nucleus lesion with high signal at Fluid-attenuated inversion recovery sequence (B) and intralésional foci of restricted diffusion (C,D). T1-weighted sequence after gadolinium-based contrast agent administration showing inhomogeneous contrast-enhancement of the lesion (E). ^{18}F -FDG PET depicting asymmetric reduction of tracer uptake of the right caudate nucleus (F). Follow-up brain MRI performed after 2 months demonstrated gliotic-malacic evolution of the lesion, without any contrast-enhancement (G,H). CT, computed tomography; MRI, magnetic resonance imaging; ^{18}F -FDG PET, ^{18}F -fluorodeoxyglucose positron emission tomography.

underwent ^{18}F -fluorodeoxyglucose positron emission tomography (^{18}F -FDG PET), which showed asymmetric reduction of uptake of the right caudate nucleus (Figure 1F), strongly against the diagnosis of CNS lymphoma. The patients' symptoms progressively improved and a follow-up brain MRI, performed after two months, showed a gliotic-malacic area without contrast-enhancement, consistent with sequelae of ischemic stroke (Figure 1G,1H). Remarkably, the patient didn't receive any chemotherapy in between the admission and the MRI follow-up. Thus, the final diagnosis of artery of Heubner stroke was made. All procedures performed in this study were in accordance with the ethical standards of the institutional and/or national research committee(s) and with the Helsinki Declaration (as revised in 2013). Written informed consent was obtained from the patient for publication of this case report and accompanying images. A copy of the written consent is available for review

by the editorial office of this journal.

Discussion

In the present case, the atypical clinical and MRI picture, in terms of morphologic, and signal characteristics led to raise the diagnostic hypothesis of CNS lymphoma.

The clinical presentation was with slowly progressive onset of cognitive-motor impairment, abulia, and drowsiness. These symptoms are not typical for stroke but can be observed in the context of artery of Heubner stroke (1,2). Thus, the clinical picture was the first confounder in this case.

At MRI, the lesion was in the basal ganglia, was periventricular in location, showed diffusion restriction and contrast-enhancement after injection of gadolinium-based contrast agent. All these features are typical for CNS

lymphoma but also for stroke (1-4). Indeed, subacute stroke may still present diffusion restriction together with contrast-enhancement due to blood-brain barrier damage. Decreased levels of NAA and choline peak at MR spectroscopy is not atypical for cerebral infarction and can be also observed in CNS lymphoma which usually presents a high peak of choline (5,6). The overlapping imaging appearance between CNS lymphoma and stroke was another important cause of misclassification in the present case. Moreover, the lesion was not fully hypodense at the first CT but rather it was isodense with just two small intralesional hypodensities and showed larger size at MRI performed just three days later. This finding, which might be due to a fogging effect sometimes observed in subacute stroke, was also a confounder because CNS lymphoma might be isodense or slightly hyperdense at CT (3,7).

The negative ^{18}F -FDG uptake of the right caudate nucleus substantially ruled out the diagnosis of CNS lymphoma. The follow-up brain MRI at 2 months finally confirmed an evolution of lesion consistent with the diagnosis of ischemic stroke.

Perfusion weighted imaging would have been essential in this case to confirm the diagnosis of stroke by showing reduced values of relative cerebral blood flow within the lesion, avoiding diagnostic delays and possibly unnecessary brain biopsies (8-10).

In conclusion, physicians should keep in mind that subacute artery of heubner stroke can be a chameleon presenting as CNS lymphoma.

Acknowledgments

Funding: None.

Footnote

Conflicts of Interest: All authors have completed the ICMJE uniform disclosure form (available at <https://qims.amegroups.com/article/view/10.21037/qims-23-437/coif>). CAM currently serves as an unpaid editorial board member of *Quantitative Imaging in Medicine and Surgery*. The other authors have no conflicts of interest to declare.

Ethical Statement: The authors are accountable for all aspects of the work in ensuring that questions related to the accuracy or integrity of any part of the work are appropriately investigated and resolved. All procedures performed in this study were in accordance with the ethical

standards of the institutional and/or national research committee(s) and with the Helsinki Declaration (as revised in 2013). Written informed consent was obtained from the patient for publication of this case report and accompanying images. A copy of the written consent is available for review by the editorial office of this journal.

Open Access Statement: This is an Open Access article distributed in accordance with the Creative Commons Attribution-NonCommercial-NoDerivs 4.0 International License (CC BY-NC-ND 4.0), which permits the non-commercial replication and distribution of the article with the strict proviso that no changes or edits are made and the original work is properly cited (including links to both the formal publication through the relevant DOI and the license). See: <https://creativecommons.org/licenses/by-nc-nd/4.0/>.

References

1. Munakomi S, M Das J. Neuroanatomy, Recurrent Artery of Heubner. In: StatPearls. Treasure Island (FL): StatPearls Publishing; 2023.
2. Toyoda K. Anterior cerebral artery and Heubner's artery territory infarction. *Front Neurol Neurosci* 2012;30:120-2.
3. Mallio CA, Bernetti C, Castiello G, Gangemi E, Tomarchio V, Annibali O, Rigacci L, Van Goethem J, Parizel PM, Beomonte Zobel B, Quattrocchi CC. Neuroradiology of acute pathologies in adults with hematologic malignancies: a pictorial review. *Quant Imaging Med Surg* 2023. doi: 10.21037/qims-22-1201
4. Wang J, Yan H, Tian S, Qin L, Ma Y. Unexpected discovery of prostatic diffuse large B-cell lymphoma after thulium laser vaporization in a patient with Waldenstrom macroglobulinemia. *Quant Imaging Med Surg* 2022;12:862-7.
5. Ambady P, Hu LS, Politi LS, Anzalone N, Barajas RF Jr. Primary central nervous system lymphoma: advances in MRI and PET imaging. *Ann Lymphoma* 2021;5:27.
6. Zacharia TT, Law M, Naidich TP, Leeds NE. Central nervous system lymphoma characterization by diffusion-weighted imaging and MR spectroscopy. *J Neuroimaging* 2008;18:411-7.
7. Skriver EB, Olsen TS. Transient disappearance of cerebral infarcts on CT scan, the so-called fogging effect. *Neuroradiology* 1981;22:61-5.
8. Vilela P, Rowley HA. Brain ischemia: CT and MRI techniques in acute ischemic stroke. *Eur J Radiol* 2017;96:162-72.

9. Haldorsen IS, Espeland A, Larsson EM. Central nervous system lymphoma: characteristic findings on traditional and advanced imaging. *AJNR Am J Neuroradiol* 2011;32:984-92.
10. Parillo M, Mallio CA, Pileri M, Dirawe D, Romano A, Bozzao A, Weinberg B, Quattrocchi CC. Interrater reliability of Brain Tumor Reporting and Data System (BT-RADS) in the follow up of adult primary brain tumors: a single institution experience in Italy. *Quantitative Imaging in Medicine and Surgery* 2023. doi: 10.21037/qims-22-850

Cite this article as: Mallio CA, Vaccarino F, Parillo M, Annibali O, Rigacci L, Meduri GM, Pilato F, Beomonte Zobel B, Di Lazzaro V. Artery of Huebner stroke chameleon presenting as central nervous system lymphoma: a case description. *Quant Imaging Med Surg* 2023;13(11):7646-7649. doi: 10.21037/qims-23-437