



# A unique case of gliomatosis peritonei after resection of a retroperitoneal immature teratoma in an infant

Shuyi Liu<sup>1</sup>, Qiu Gao<sup>2</sup>, Yuelin Hu<sup>1</sup>

<sup>1</sup>Department of Radiology, Guangzhou Women and Children's Medical Center, Guangzhou Medical University, Guangdong Provincial Clinical Research Center for Child Health, Guangzhou, China; <sup>2</sup>Department of Pathology, Guangzhou Women and Children's Medical Center, Guangzhou Medical University, Guangdong Provincial Clinical Research Center for Child Health, Guangzhou, China

*Correspondence to:* Yuelin Hu, BA. Department of Radiology, Guangzhou Women and Children's Medical Center, Guangzhou Medical University, Guangdong Provincial Clinical Research Center for Child Health, No. 9 Jinsui Road, Tianhe District, Guangzhou 510623, China. Email: 2514885537@qq.com.

Submitted Jun 04, 2023. Accepted for publication Sep 11, 2023. Published online Oct 25, 2023.

doi: 10.21037/qims-23-798

View this article at: <https://dx.doi.org/10.21037/qims-23-798>

## Introduction

Gliomatosis peritonei (GP) is a rare disease described as implants of mature glial tissue distributed throughout the peritoneum and omentum, mostly arising from immature ovarian teratomas (1-3). To date, only a few cases of GP related to extragonadal teratomas have been reported (1,4-6). These included retroperitoneal immature teratomas (IMTs), accounting for only 2–5% of all pediatric teratomas (7,8). Cases of GP caused by retroperitoneal IMTs are extremely rare. Here, we report on an infant diagnosed with GP originating from a recurrent mature teratoma after resection of a retroperitoneal IMT on computed tomography (CT) images.

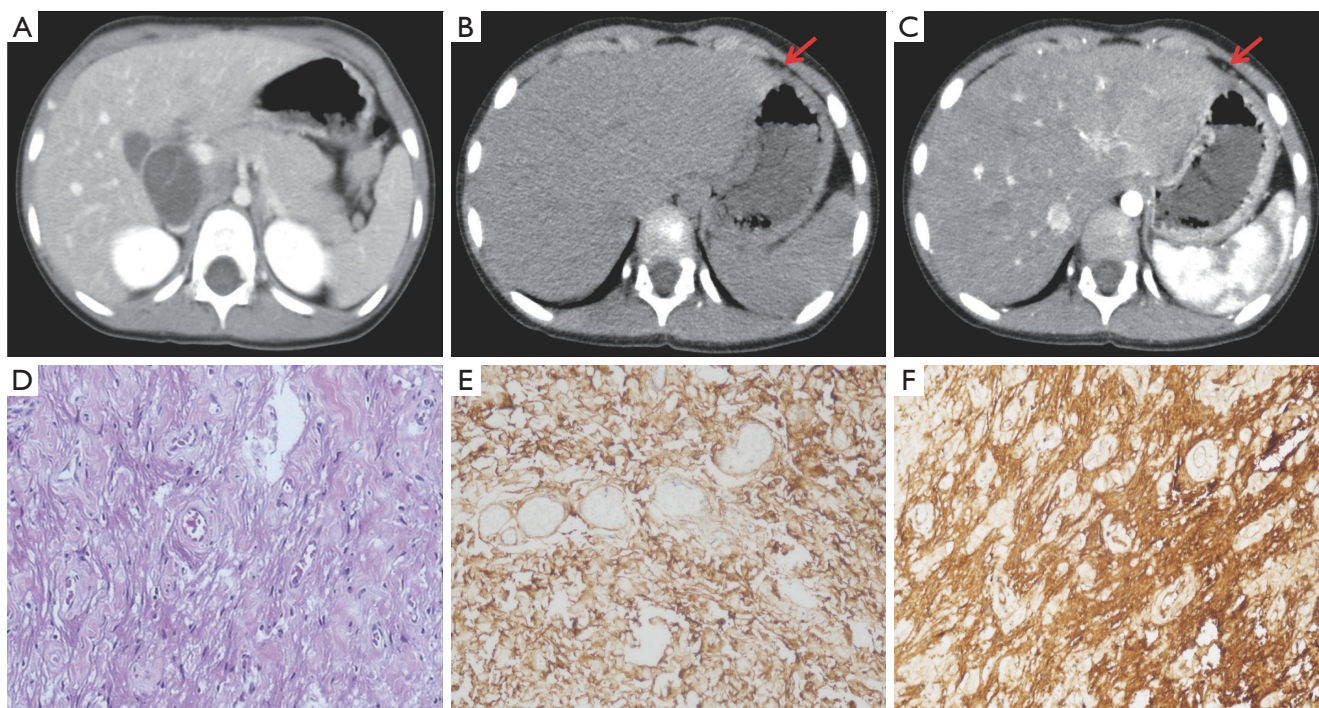
## Case presentation

All procedures performed in this study were in accordance with the ethical standards of the institutional and national research committee(s) and with the Helsinki Declaration (as revised in 2013). Written informed consent was obtained from the patient's parents for publication of this case report and accompanying images. A copy of the written consent is available for review by the editorial office of this journal.

A 1-month-old girl was brought to the hospital owing to increasing abdominal distension persisting since birth and vomiting persisting for 3 days. CT revealed a large, lobulated, cystic-solid mass with a mixture of patchy, high-density shadow and fat fraction in the right retroperitoneum

(Figure S1A). The wall of the tumor was slightly enhanced (Figure S1B). The right kidney was markedly deformed and displaced owing to compression (Figure S1C). The cancer antigen (CA) 125 concentration was elevated (184.90 U/mL; normal range, <35 U/mL), as were the CA 19-9 (77.21 U/L; normal range, <37 U/mL) and alpha-fetoprotein (AFP; 3,638.14 ng/mL; normal range, <8.78 ng/mL) concentrations. On July 17, 2018, the patient underwent surgery for the first time. The lateral peritoneum was detached, and blunt dissection was performed along the surface of the tumor. The upper boundary of the tumor was separated from the liver and gallbladder, the central boundary was separated from the intestines and the superior mesenteric artery, and the lower boundary was separated from the right kidney. Finally, the whole tumor was surgically removed and sent for pathological examination. The gross tumor characteristics were as follows: it was an irregular, soft tissue mass of cystic-solid tissue, 11 cm × 9 cm × 6 cm in size, with an incomplete capsule and a greyish-red color. Microscopic pathology revealed that the tumor contained bone, cartilage, skin, intestine, mature fat (Figure S1D), immature neural tissues, and the development of a neural tube (Figure S1E). Finally, the tumor was pathologically diagnosed as a right retroperitoneal, grade II IMT. No postoperative chemotherapy was performed.

On March 25, 2022, the child was admitted to the hospital again owing to abdominal distension persisting for one month. Abdominal CT revealed multiple oval/



**Figure 1** The recurrent mature teratoma during the second surgery with GP. (A) Abdominal contrast-enhanced CT reveals that multiple oval cystic lesions are located behind the gallbladder without obvious enhancement. (B,C, red arrow) Small nodules are distributed in peritoneum with mild enhancement on CT images. (D) Glial components are found on the surface of peritoneal and omental (hematoxylin-eosin staining,  $\times 10$ ). The glial component (brown) shows positive immunostaining for glial fibrillary acidic protein ( $\times 20$ ) (E) and S-100 ( $\times 20$ ) (F). GP, gliomatosis peritonealis; CT, computed tomography.

round cystic lesions on the surface of liver, behind the gallbladder, and in the ileocecal region to the right of the ascending colon (*Figure 1A*). Moreover, a few small nodules were distributed throughout the peritoneum (*Figure 1B*) with mild enhancement (*Figure 1C*). The patient's AFP was normal. Three years and 9 months after the first surgery, the patient underwent a second surgery. Intraoperatively, we observed that the omentum adhered to the lower edge of the right lobe of the liver and the peritoneal mass. We also observed numerous miliary nodules on the surface of the omentum and peritoneum, and masses of approximately 1.5–5 cm in the abdomen. A relatively large mass (approximately 5 cm  $\times$  3 cm) was observed behind the gallbladder. During detachment, that mass ruptured, releasing yellowish-white viscous tissue and hair. The masses, peritoneum covered with nodules, and omental adhesion were removed as completely as possible via blunt and sharp dissection. The masses and nodules were diagnosed as mature teratomas, complicated with GP, with glial nodules scattered throughout the omentum and

peritoneum (*Figure 1D*). The specimens were positive for immunohistochemical staining for glial fibrillary acidic protein (GFAP) (*Figure 1E*) and S-100 protein (*Figure 1F*). Two weeks after the operation, the patient was treated with two consecutive chemotherapy regimens of cisplatin, etoposide, and bleomycin (PEB). The PEB regimens were administered in 3-week cycles, with 20 mg/m<sup>2</sup> cisplatin and 100 mg/m<sup>2</sup> etoposide on days 1–5, and 15,000 IU/m<sup>2</sup> bleomycin on day 5. No recurrence was detected at the 6-month follow-up visit.

## Discussion

In this report, we presented a rare case of a 1-month-old infant in whom a large retroperitoneal teratoma was resected and who was subsequently treated for recurrence of a mature teratoma with GP. To our knowledge, this is the first case of a retroperitoneal teratoma with GP in an infant. Most of the reported cases of GP associated with extragonadal congenital IMT involved tunica vaginalis

gliomatosis (1,4-6). Patra *et al.* reported that a 1-month-old infant developed isolated gliomatosis involving the tunica vaginalis after excision of a retroperitoneal IMT (5). Very rarely, GP manifests as extratesticular masses arising from gastric and mesenteric IMTs in infancy (4,6). No chemotherapy was administered in any of the abovementioned cases, nor was recurrence observed during the follow-up period. Embryonically, the tunica vaginalis is an extension of the peritoneum through the inguinal canal, thus providing a route for extratesticular gliomatosis (5). The different locations of implantation may explain the differences in gliomas between this case and previous cases. GP exhibits heterogeneous intermediate signal intensity upon T2-weighted magnetic resonance imaging (MRI) and isointensity upon T1-weighted MRI with intense enhancement. Upon CT, GP is observed as miliary peritoneal nodules (9,10). For most deposits of glial tissue smaller than 3 mm, GP is difficult to be detected via CT (10). Immunohistochemical staining of GFAP and S-100 protein are critical for the diagnosis of GP (11). One of the main pathogenies of GP is the implantation of immature nerves or mature glial tissue in the peritoneum or the spread via angiolymphatic channels owing to an incomplete capsule or spontaneous rupture of the teratoma (12). During operation, complete resection of the teratoma should be performed to the most possible extent to avoid such implantation and metastasis of tumor contents. Furthermore, a retroperitoneal tumor may increase the risk of peritoneal implantation of glial cells. Most GP cases are diagnosed during the first surgery, whereas a few are discovered during a subsequent surgery, as in this case. Therefore, once IMT relapses, GP should be considered.

Notably, the recurrent tumor in the present case was a mature teratoma rather than an IMT. IMTs were previously reported to transform into mature teratomas after the completion of resection and chemotherapy, termed “growing teratoma syndrome (GTS)” (13). As GTS mainly results from chemotherapy (14-16), it is also known as “chemotherapeutic retroconversion” (14). Umekawa *et al.* (15) determined that GTS might be a type of GP, as both are associated with benign peritoneal glial implants, despite the malignancy of the primary tumor. However, Wang *et al.* (17) discussed several differences between the two. Noumoff *et al.* (18) reported a case of an IMT in which the karyotypes of the primary tumor and recurrent mature teratoma were identical after chemotherapy, with cytogenetic abnormalities remaining unaltered, especially with respect to a dicentric chromosome 1 and monosomy

of chromosome 4. As in the case of our patient that she did not receive chemotherapy after the first surgery, benign transformation cannot be attributed only to chemotherapy, but may also occur spontaneously over time.

As described here and in other reports, recurrent teratoma is characterized by transformation of tumor tissue towards maturity, and the pathological grading gradually decreases over time, which strongly supports that chemotherapy is not required for children with pure IMT; complete surgical resection alone is the primary treatment regardless of the grade of IMT (19-21). Additionally, although IMTs with GP relapse more frequently, the prognosis of such IMTs is often much more favorable regardless of the grade (10,22,23), and the presence of mature glial implants is not a risk factor for poor prognosis.

## Conclusions

We discussed a rare case of pediatric GP in the form of a recurrent mature teratoma following excision of a retroperitoneal IMT. The benign transformation of IMT was determined a natural transformation, and surgery alone is curative for children with pure IMT initially. More importantly, the tumour should be resected as thoroughly as possible in surgery to avoid its implantation. When a child develops a teratoma with multiple nodules in the peritoneum or omentum, GP should be considered. As glial nodules are not easily evaluated with CT, once large teratomas are detected arising from the retroperitoneum, MRI is preferable.

## Acknowledgments

**Funding:** This study was supported by the Plan on Enhancing Scientific Research in GMU, Research Foundation of Guangzhou Women and Children's Medical Center for Clinical Doctor (No. 2023BS028).

## Footnote

**Conflicts of Interest:** All authors have completed the ICMJE uniform disclosure form (available at <https://qims.amegroups.com/article/view/10.21037/qims-23-798/coif>). The authors have no conflicts of interest to declare.

**Ethical Statement:** The authors are accountable for all aspects of the work in ensuring that questions related to the accuracy or integrity of any part of the work are

appropriately investigated and resolved. All procedures performed in this study were in accordance with the ethical standards of the institutional and national research committee(s) and with the Helsinki Declaration (as revised in 2013). Written informed consent was obtained from the patient's parents for publication of this case report and accompanying images. A copy of the written consent is available for review by the editorial office of this journal.

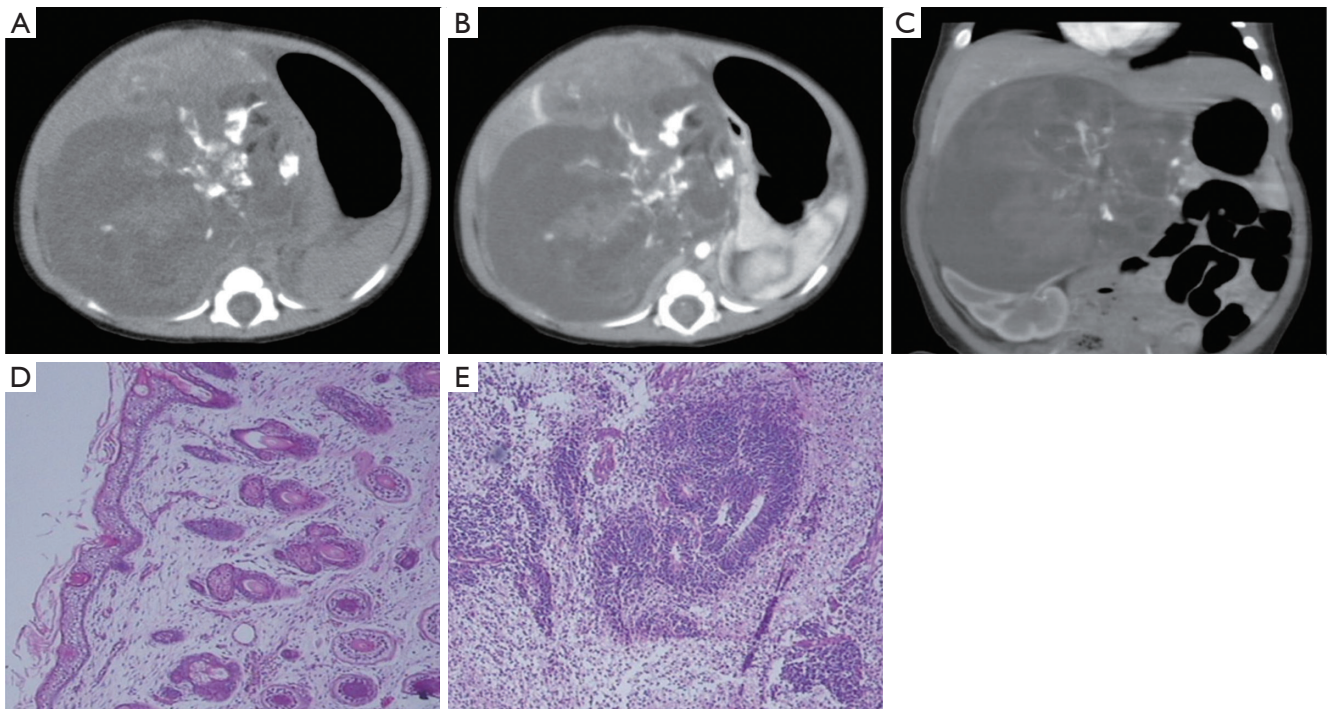
**Open Access Statement:** This is an Open Access article distributed in accordance with the Creative Commons Attribution-NonCommercial-NoDerivs 4.0 International License (CC BY-NC-ND 4.0), which permits the non-commercial replication and distribution of the article with the strict proviso that no changes or edits are made and the original work is properly cited (including links to both the formal publication through the relevant DOI and the license). See: <https://creativecommons.org/licenses/by-nc-nd/4.0/>.

## References

1. Coulson WF. Peritoneal gliomatosis from a gastric teratoma. *Am J Clin Pathol* 1990;94:87-9.
2. Kim NR, Lim S, Jeong J, Cho HY. Peritoneal and nodal gliomatosis with endometriosis, accompanied with ovarian immature teratoma: a case study and literature review. *Korean J Pathol* 2013;47:587-91.
3. Müller AM, Söndgen D, Strunz R, Müller KM. Gliomatosis peritonei: a report of two cases and review of the literature. *Eur J Obstet Gynecol Reprod Biol* 2002;100:213-22.
4. Li J, Li S, Xiao D, Song J, Mao J, Yin J. Extratesticular gliomatosis peritonei after mesenteric teratoma: a case report and literature review. *J Int Med Res* 2021;49:3000605211047076.
5. Patra S, Chakravorty S, Chatterjee U, Saha K. Tunical Gliomatosis: An Uncommon Histological Entity. *Fetal Pediatr Pathol* 2022;41:330-3.
6. Yeo DM, Lim GY, Lee YS, Sohn DW, Chung JH. Gliomatosis peritonei of the scrotal sac associated with an immature gastric teratoma. *Pediatr Radiol* 2010;40:1288-92.
7. Gatcombe HG, Assikis V, Kooby D, Johnstone PA. Primary retroperitoneal teratomas: a review of the literature. *J Surg Oncol* 2004;86:107-13.
8. De Backer A, Madern GC, Hazebroek FW. Retroperitoneal germ cell tumors: a clinical study of 12 patients. *J Pediatr Surg* 2005;40:1475-81.
9. Levy AD, Shaw JC, Sobin LH. Secondary tumors and tumorlike lesions of the peritoneal cavity: imaging features with pathologic correlation. *Radiographics* 2009;29:347-73.
10. England RA, deSouza NM, Kaye SB. Gliomatosis peritonei: MRI appearances and its potential role in follow up. *Br J Radiol* 2007;80:e101-4.
11. Gheorghisan-Galateanu A, Terzea DC, Carsote M, Poiana C. Immature ovarian teratoma with unusual gliomatosis. *J Ovarian Res* 2013;6:28.
12. Lobotesis K, U-King-Im JM, Cross JJ, Gillard JH, Antoun NM. Gliomatosis peritonei associated with a ventriculo-peritoneal shunt. *Clin Radiol* 2009;64:95-9.
13. Logothetis CJ, Samuels ML, Trindade A, Johnson DE. The growing teratoma syndrome. *Cancer* 1982;50:1629-35.
14. Merard R, Ganesan R, Hirschowitz L. Growing Teratoma Syndrome: A Report of 2 Cases and Review of the Literature. *Int J Gynecol Pathol* 2015;34:465-72.
15. Umekawa T, Tabata T, Tanida K, Yoshimura K, Sagawa N. Growing teratoma syndrome as an unusual cause of gliomatosis peritonei: a case report. *Gynecol Oncol* 2005;99:761-3.
16. Hsieh YL, Liu CS. Progression from an immature teratoma with miliary gliomatosis peritonei to growing teratoma syndrome with nodular gliomatosis peritonei. *Pediatr Neonatol* 2009;50:78-81.
17. Wang D, Jia CW, Feng RE, Shi HH, Sun J. Gliomatosis peritonei: a series of eight cases and review of the literature. *J Ovarian Res* 2016;9:45.
18. Noumoff JS, LiVolsi VA, Deger RB, Montone KT, Faruqi SA. Chromosome analysis and comparison of the benign cystic and malignant squamous component of an ovarian teratoma. *Cancer Genet Cytogenet* 2001;125:59-62.
19. Cushing B, Giller R, Ablin A, Cohen L, Cullen J, Hawkins E, Heifetz SA, Krailo M, Lauer SJ, Marina N, Rao PV, Rescorla F, Vinocur CD, Weetman RM, Castleberry RP. Surgical resection alone is effective treatment for ovarian immature teratoma in children and adolescents: a report of the pediatric oncology group and the children's cancer group. *Am J Obstet Gynecol* 1999;181:353-8.
20. Marina NM, Cushing B, Giller R, Cohen L, Lauer SJ, Ablin A, Weetman R, Cullen J, Rogers P, Vinocur C, Stolar C, Rescorla F, Hawkins E, Heifetz S, Rao PV, Krailo M, Castleberry RP. Complete surgical excision is effective treatment for children with immature teratomas with or without malignant elements: A Pediatric Oncology Group/Children's Cancer Group Intergroup Study. *J Clin Oncol* 1999;17:2137-43.

21. Mann JR, Gray ES, Thornton C, Raafat F, Robinson K, Collins GS, Gornall P, Huddart SN, Hale JP, Oakhill A; UK Children's Cancer Study Group Experience. Mature and immature extracranial teratomas in children: the UK Children's Cancer Study Group Experience. *J Clin Oncol* 2008;26:3590-7.
22. Liang L, Zhang Y, Malpica A, Ramalingam P, Euscher ED, Fuller GN, Liu J. Gliomatosis peritonei: a clinicopathologic and immunohistochemical study of 21 cases. *Mod Pathol* 2015;28:1613-20.
23. Yoon NR, Lee JW, Kim BG, Bae DS, Sohn I, Sung CO, Song SY. Gliomatosis peritonei is associated with frequent recurrence, but does not affect overall survival in patients with ovarian immature teratoma. *Virchows Arch* 2012;461:299-304.

**Cite this article as:** Liu S, Gao Q, Hu Y. A unique case of gliomatosis peritonei after resection of a retroperitoneal immature teratoma in an infant. *Quant Imaging Med Surg* 2023;13(12):8859-8863. doi: 10.21037/qims-23-798



**Figure S1** A retroperitoneum immature teratoma during the first surgery. (A) An axial image of non-contrast abdominal CT shows a large lobulated cystic-solid mass on the right retroperitoneum, with clear boundary and mixed density. Patchy high-density shadow and fat fraction can be seen in the lesion, with a CT value of approximately 320 and -36 HU. (B) CT enhancement scan shows the solid lesion and the wall of the tumor and is slightly enhancement. (C) The right kidney is significant deformed and displaced due to compression. (D) Microscopic shows that the tumor is composed of mature skin tissue, covered squamous epithelium and skin appendages (hematoxylin-eosin staining ×10). (E) The retroperitoneal immature teratoma shows the primitive neuroepithelial structure, presented with a rosette-like formation and tubular arrangement (hematoxylin-eosin staining ×10). CT, computed tomography; HU, Hounsfield unit.