



# Contrast-enhanced computed tomography of retromandibular vein position and course patterns relative to the mandible during sagittal split ramus osteotomy

Keisuke Sugahara<sup>1,2,3#^</sup>, Koki Oiwa<sup>1#</sup>, Satoru Matsunaga<sup>2,4</sup>, Kento Odaka<sup>2,5</sup>, Hidetomo Hirouchi<sup>4</sup>, Masahide Koyachi<sup>1</sup>, Norio Kasahara<sup>2,6</sup>, Chie Tachiki<sup>7</sup>, Yasushi Nishii<sup>7</sup>, Klaus-Dietrich Wolff<sup>3</sup>, Akira Katakura<sup>1,2</sup>

<sup>1</sup>Department of Oral Pathobiological Science and Surgery, Tokyo Dental College, Tokyo, Japan; <sup>2</sup>Oral Health Science Center, Tokyo Dental College, Tokyo, Japan; <sup>3</sup>Department of Oral and Maxillofacial Surgery, Technical University Munich, Klinikum Rechts der Isar, München, Germany; <sup>4</sup>Department of Anatomy, Tokyo Dental College, Tokyo, Japan; <sup>5</sup>Department of Oral and Maxillofacial Radiology, Tokyo Dental College, Tokyo, Japan; <sup>6</sup>Department of Histology and Developmental Biology, Tokyo Dental College, Tokyo, Japan; <sup>7</sup>Department of Orthodontics, Tokyo Dental College, Tokyo, Japan

*Contributions:* (I) Conception and design: K Sugahara, K Oiwa, Y Nishii, KD Wolff, A. Katakura; (II) Administrative support: K Sugahara, K Oiwa, M Koyachi, C Tachiki; (III) Provision of study materials or patients: K Sugahara, M Koyachi, C Tachiki; (IV) Collection and assembly of data: K Sugahara, K Oiwa, S Matsunaga, H Hirouchi, N Kasahara, C Tachiki; (V) Data analysis and interpretation: K Sugahara, K Oiwa, S Matsunaga, H Hirouchi, N Kasahara; (VI) Manuscript writing: All authors; (VII) Final approval of manuscript: All authors.

#These authors contributed equally to this work as co-first authors.

*Correspondence to:* Keisuke Sugahara, DDS, PhD, FIBCSOMS. Department of Oral Pathobiological Science and Surgery, Tokyo Dental College, 2-9-18, Kanda Misaki-cho, Chiyoda-ku, Tokyo, Japan; Oral Health Science Center, Tokyo Dental College, Tokyo, Japan; Department of Oral and Maxillofacial Surgery, Technical University Munich, Klinikum Rechts der Isar, München, Germany. Email: ksugahara@tdc.ac.jp.

**Background:** Sagittal split ramus osteotomy is an established procedure used in oral and maxillofacial surgery. Major bleeding is representative intraoperative complication involves vessels such as the inferior alveolar, facial, and maxillary arteries and accompanying veins, in particular the retromandibular vein (RMV). We previously described the RMV course patterns using embalmed cadavers. However, owing to the possible influence of formalin fixation and unclear skeletal classification of the jaws, the present study aimed to use contrast-enhanced computed tomography to confirm the RMV in patients with defined jaw deformities.

**Methods:** Twenty patients with orthognathic jaw deformities (40 sides) were included. The RMV and the lateral and posterior views of the mandible were evaluated using contrast-enhanced computed tomography. Course patterns and RMV positions were classified as previously reported.

**Results:** Three patterns were identified in the lateral view. Type A: RMV posterior to the posterior border of the ramus (n=25; 62.5%). Type B: adjoining the posterior border of the ramus (n=12; 30.0%). Type C: anterior to the posterior border of the ramus (n=3; 7.5%). Five course patterns were identified in the posterior view. Pattern I: rectilinear course running medial to the posterior border of the ramus (n=3; 7.5%). Pattern II: diagonal course running medially from immediately posterior to posterior border of the ramus (n=11; 27.5%). Pattern III: rectilinear course running immediately posterior to the posterior border of the ramus (n=12; 30.0%). Pattern IV: diagonal course running from lateral to medial relative to the posterior border of the ramus (n=8; 20.0%). Pattern V: diagonal course running from lateral to immediately posterior relative to the posterior border of the ramus (n=6; 15.0%). In the no-course pattern group, the RMV inferior

<sup>^</sup> ORCID: 0000-0002-0260-396X.

to the lingula was lateral to its position and superior to that of the lingula. In half of the cases, the left and right sides exhibited different running patterns. We observed no correlation between the skeletal patterns of jaw deformities and the course of the RMV.

**Conclusions:** Type B/Pattern II that runs in a straight line bordering the posterior margin of the ramus requires the most attention during surgery. These findings suggest the possibility of predicting intraoperative bleeding risk.

**Keywords:** Retromandibular vein (RMV); contrast-enhanced computer tomography (CECT); blood vessel running direction; mandibular ramus; sagittal split ramus osteotomy (SSRO)

Submitted Sep 12, 2023. Accepted for publication Dec 06, 2023. Published online Jan 11, 2024.

doi: 10.21037/qims-23-1301

View this article at: <https://dx.doi.org/10.21037/qims-23-1301>

## Introduction

Surgical correction of either congenic or acquired jaw deformities still are associated with certain risks, although recent developments such as ultrasonic cutting devices. As such, orthognathic surgery is a standardized worldwide procedure in oral and maxillofacial surgery. Sagittal split ramus osteotomy (SSRO) is the most commonly performed and established surgical procedure. As well, SSRO represents the most common type of mandibular osteotomy performed in our hospital (1). Intraoperative complications, such as major bleeding, lower lip paresthesia, lingual nerve paresthesia and unfavorable fractures are frequently encountered (2-5). Thorough preoperative evaluation of surgical risks is important to reduce surgical time and intraoperative blood loss and to achieve favorable outcomes. The incidence of unfavorable fractures and inferior alveolar nerve injury can be decreased by preoperative computed tomography (CT) to evaluate bone tissue and morphology. On the other hand, the risk of intraoperative bleeding caused by jeopardizing one of the vessels running through the soft tissue with unpredictable course can only be predicted preoperatively using contrast-enhanced computed tomography (CECT). In addition, the courses of various blood vessels in patients with jaw deformities differ from those in healthy individuals (6,7).

In our previous study (8), we determined the retromandibular vein (RMV) position and course patterns relative to the posterior border of the ramus using 15 cadavers (15 sides). We identified three-course patterns in the lateral view and five in the posterior view (8).

Therefore, herein, we aimed to investigate the location and pattern of RMV courses in patients with defined jaw deformities using CECT.

## Methods

### *Study population*

From October 2018 to October 2019, twenty patients aged 17–45 years were included. Skeletal classification was performed using cephalometric analysis. Patients with a cleft palate or craniofacial abnormalities were excluded. This study was conducted in accordance with the Declaration of Helsinki (as revised in 2013). The study was approved by the Ethics Committee of Tokyo Dental College (Nos. 794 and 844). Written informed consent was obtained from patients or patient's parents for the publication of this study and any accompanying images.

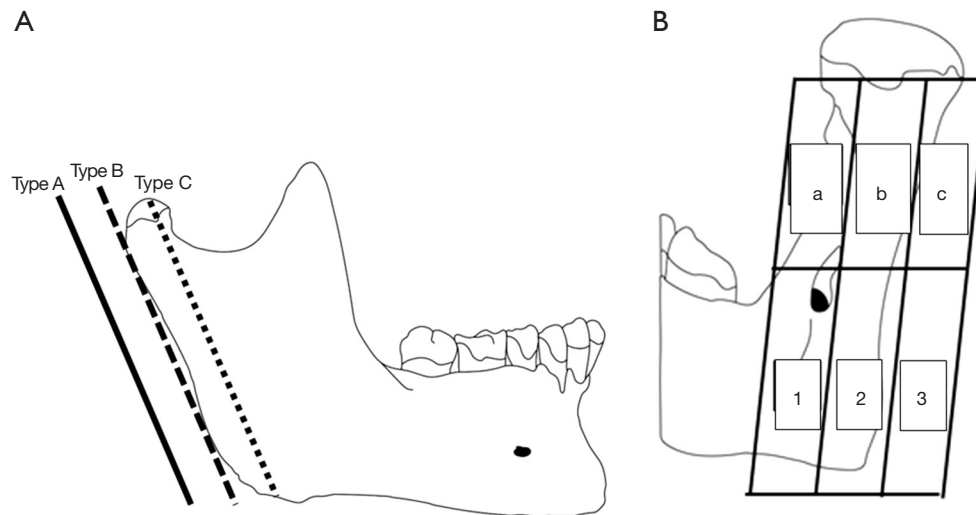
### *RMV course categorization and measurement parameters*

CT scans (SOMATOM Definition AS, Siemens, Forchheim, Germany) were obtained one month before surgery, and the CT images were formatted as Digital Imaging and Communications in Medicine (DICOM) data. The CT DICOM and digital impression data were transferred to Minimics (Materialize, Leuven, Belgium) and segmented.

A baseline was created based on 5 mm above the mandibular ligula.

The types were classified based on the positional relationship between the RMV and the posterior border of the ramus on the lateral view as follows: Type A, RMV posterior to the posterior border of the ramus; Type B, RMV adjoining the posterior border of the ramus; and Type C, RMV anterior to the posterior border of the ramus (*Figure 1A*).

In the posterior view, the images were divided into three buccolingual sections comprising the posterior border and



**Figure 1** Classifications of the RMV. (A) Classifications of the positional relationship between the RMV and the posterior border of the mandibular ramus when viewed laterally. Type A: RMV positioned posterior to the posterior border of the ramus; Type B: RMV adjoining the posterior border of the ramus; Type C: RMV positioned anterior to the posterior border of the ramus. (B) RMV course patterns on the posterior view of the mandibular ramus. Images were divided into three buccolingual sections relative to the ramus. Each section was subsequently divided horizontally at the height of the mandibular lingula. The upper region was divided into three parts [a, b, c], and the lower region was divided into three parts [1, 2, 3]. The driving was classified running pattern by combining one each in the upper and lower parts. RMV, retromandibular vein.

the buccal and lingual aspects of the ramus. These were then divided into superior and inferior sections at the height of the lingula. Based on these sections, the RMV course patterns were classified into one of nine possible categories (*Figure 1B*) (8). Differences in the running patterns between the left and right sides and skeletal classifications were also investigated.

### Statistical analysis

Chi-square tests were compared using binomial logistic regression analysis. Differences were considered statistically significant at  $P < 0.05$ . All data were processed using the IBM SPSS software package ver. 23 (SPSS ver. 23).

## Results

### Participant characteristics

Participant characteristics are presented in *Table 1*. Twenty patients aged 17–45 years (mean age: 26.0 years) were included.

### Course patterns

This classification of course patterns is the same as our previously reported classification of the posterior and lateral aspects of the ramus.

#### Course patterns lateral view (*Table 1, Figure 2*)

A Type A pattern (RMV positioned posterior to the posterior border of the ramus) was observed on 25 sides (62.5%), Type B (RMV adjoining the posterior border of the ramus) on 12 sides (30.0%), and Type C (RMV positioned anterior to the posterior border of the ramus) on three sides (7.5%). There were 14 cases (70.0%) of Type in which the left and right sides were the same.

#### Course patterns posterior view (*Figure 3*)

Dividing the posterior view images into three buccolingual sections comprising the posterior border and buccal and lingual aspects of the ramus, which were then divided into upper and lower sections at the height of the lingula, and classifying course patterns into one of nine possible categories, no course patterns included Block 3—inferior

**Table 1** Clinical information and RMV patterns

Case No.	Age (years)	Sex	Diagnosis	Left side		Right side	
				Type	Pattern	Type	Pattern
1	24	F	Mandibular protrusion + maxillary retrusion	A	IV	A	II
2	27	F	Mandibular protrusion + maxillary retrusion	A	II	A	III
3	24	F	Mandibular protrusion + maxillary retrusion	A	II	A	IV
4	25	F	Mandibular protrusion + maxillary retrusion	A	IV	A	IV
5	20	F	Mandibular protrusion + maxillary retrusion	A	V	B	V
6	26	F	Mandibular protrusion + maxillary retrusion	B	III	B	III
7	30	F	Mandibular protrusion + maxillary retrusion	C	III	A	II
8	21	M	Mandibular protrusion + maxillary retrusion	B	IV	B	IV
9	23	F	Mandibular retrusion + maxillary protrusion	A	III	A	III
10	20	F	Mandibular retrusion + maxillary protrusion	B	V	A	II
11	19	F	Mandibular retrusion + maxillary protrusion	C	I	B	II
12	32	M	Mandibular retrusion + maxillary protrusion	B	IV	A	IV
13	28	F	Mandibular protrusion + maxillo-mandibular asymmetry + open bite	A	II	A	II
14	24	F	Mandibular protrusion + maxillo-mandibular asymmetry + open bite	A	V	A	III
15	19	F	Mandibular protrusion + maxillary retrusion + maxillo-mandibular asymmetry	C	II	A	III
16	17	F	Mandibular retrusion + maxillary protrusion + open bite	A	III	A	III
17	19	F	Mandibular retrusion + maxillary protrusion + open bite	B	I	B	I
18	26	F	Maxillo-mandibular asymmetry	B	V	B	V
19	17	F	Maxillo-mandibular asymmetry + cross bite	A	II	A	II
20	45	F	Maxillo-mandibular asymmetry + open bite	A	III	A	III

RMV, retromandibular vein; F, female; M, male.

to the lingula and lateral to the posterior border of the ramus—regardless of the position of the course superior to the lingula. Five course patterns were identified.

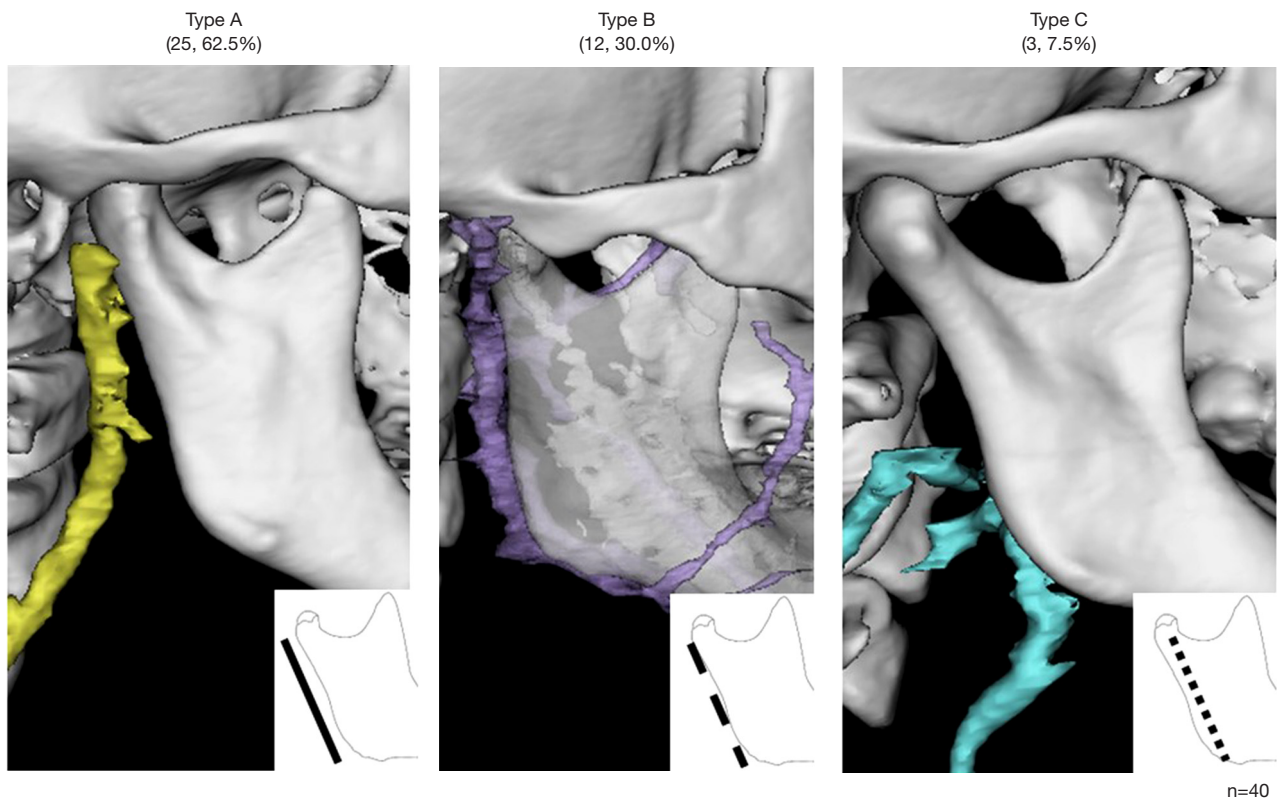
- ❖ Pattern I (a-1): rectilinear course running medial to the posterior border of the ramus (n=3; 7.5%).
- ❖ Pattern II (b-1): diagonal course running medially from immediately posterior to the posterior border of the ramus (n=11; 27.5%).
- ❖ Pattern III (b-2): rectilinear course running immediately posterior to the posterior border of the ramus (n=12; 30.0%).

- ❖ Pattern IV (c-1): diagonal course running from lateral to medial in relation to the posterior border of the ramus (n=8; 20.0%).

- ❖ Pattern V (c-2): diagonal course running from lateral to immediately posterior in relation to the posterior border of the ramus (n=6; 15.0%).

In the no-course pattern, the RMV inferior to the lingula was lateral to its position and superior to that of the lingula. The bilateral type was identical in all 12 cases (60.0%).

No significant differences were observed between men and women in any of the data items, including skeletal



**Figure 2** Position of the posterior border of the mandible and posterior veins of the mandible. Type A was the most common type, accounting for 62.5% of the cases. However, 37.5% of the RMVs were located in contact with or medial to the mandibular ramus. RMV, retromandibular vein.

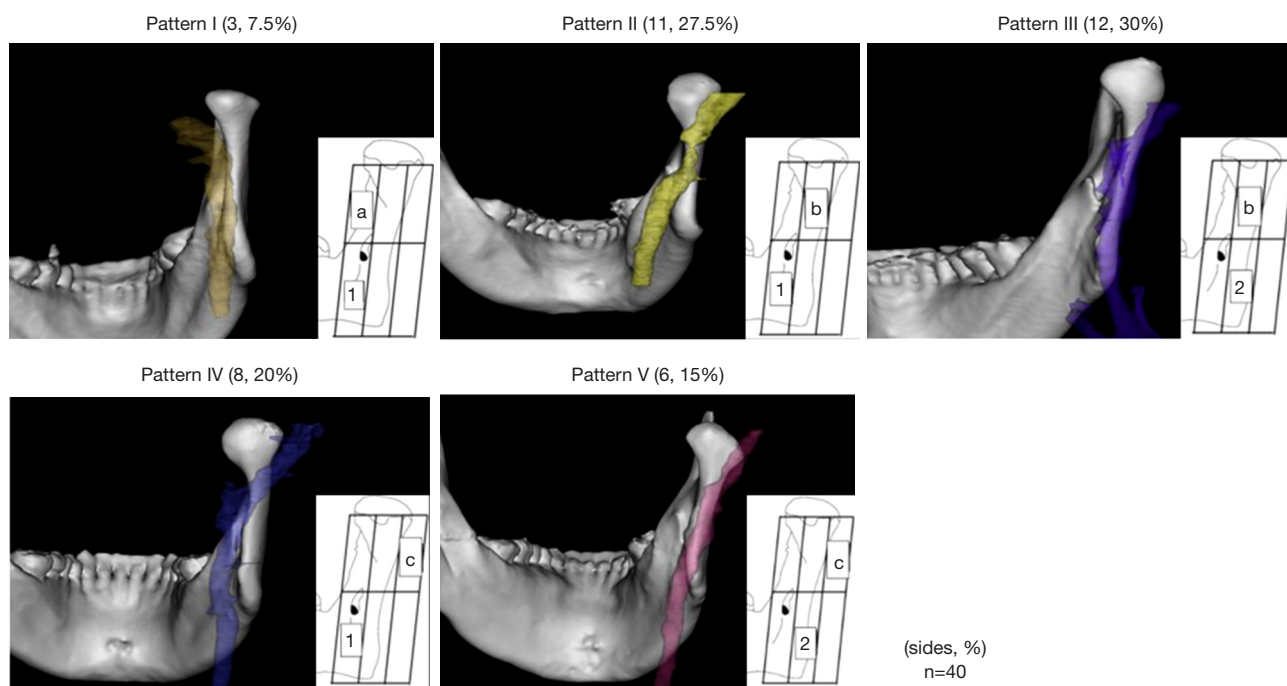
classification.

The most common combinations of type and pattern were Type A/Pattern II and Type A/Pattern on nine sides each (22.5%). Type B/Pattern II bleeding that runs in a straight line bordering the posterior margin of the ramus requires the most attention during surgery. Both type and pattern matched in 10 cases (50%), type alone matched in 14 cases (70%), and pattern alone matched in 12 cases (60%) in the lateral and posterior views. Complete discordance was observed in 4 cases (20%). Half of the patients showed a discrepancy in the running pattern between the left and right sides. In mandibular protrusion, type and pattern were completely matched in 4 of 11 cases (36.4%), whereas only type was matched in 9 of 11 cases (81.8%). In the case of mandibular retrusion, the type and pattern matched perfectly in 3 of the 6 cases (50.0%), whereas only the type matched in 3 of the 6 cases (50.0%). The degree of accordance was higher in mandibular protrusion cases. No statistically significant relationship was found between the

type of jaw deformity and the RMV course.

## Discussion

Orthognathic surgery is widely recognized for its efficacy in oral and maxillofacial surgery in Japan. SSRO is the most commonly performed type of orthognathic surgery (1). The first surgical approach for SSRO was reported by Trauner and Obwegeser (9) in 1957. Piñeiro-Aguilar *et al.* (10) reported a correlation between operation time and intraoperative blood loss in SSRO. Thorough preoperative evaluation of surgical risks is important to reduce surgical time and intraoperative blood loss and to improved surgical safety. In a previous study, we investigated the location and course patterns of RMV in cadavers (8). However, in cadavers, deviations may occur due to the method and circumstances of fixation. In addition, many of the cadavers were too old and had missing teeth to enable skeletal classification. Therefore, in this study, we used CECT in patients with jaw



**Figure 3** Posterior view of the course pattern of the RMV and the posterior border of the mandibular ramus. Five patterns were observed. The most common pattern was a linear presence at the posterior margin of the mandibular ramus. RMV, retromandibular vein.

deformities to identify the anatomy of RMV. The running patterns in both lateral and posterior views were similar in patients with jaw deformities.

In a previous study we described the RMV position and course patterns relative to the posterior border of the ramus using cadavers to facilitate the preoperative evaluation of bleeding risk in SSRO (8).

RMV course patterns have also been reported by other authors; however, most of these studies focused on its position relative to the facial nerve during parotid gland tumor resection (11,12). To date, no study has investigated the running pattern and position of the RMV in patients with jaw deformities. Focusing on orthognathic surgery, the present study examined the RMV course patterns lateral and posterior to the ramus using CECT in patients with jaw deformities. Based on measurements of the distance between the RMV and posterior border of the ramus, the levels of risk for intraoperative bleeding were also classified. In a previous study (8), we observed the same types and patterns of RMV. Type A was the most common type in cadavers, and the same was observed in patients with jaw deformities. Nevertheless, Type B was more common in our patients with jaw deformities than in our cadaver

study. Pattern I, which was more common in cadavers, was less common in patients with jaw deformities, and the percentages of Patterns II and III were higher in cadavers. These results indicated that Type A-Pattern I was more common in cadavers, whereas Type A-Pattern II, followed by Type A-Pattern III, was more common in patients with jaw deformities, indicating a difference. The courses of various blood vessels in patients with jaw deformities differ from those in healthy individuals (6,7).

The RMVs below the mandibular fontanel were positioned laterally above the mandibular fontanel. Ten patients (50.0%) had the same position and running pattern in both lateral and posterior views on the left and right sides. Lohn *et al.* and Koh *et al.* reported that the facial arteries showed a discordant pattern on the left and right sides in 47% and 45.5% of cases, respectively (13,14). In the present study, half of the patients exhibited discordant running patterns of the RMV. To date, no studies have reported left-right differences of the RMV using the mandible as a reference point.

The present study focused on orthognathic surgery and examined the RMV course patterns to the ramus. On 12 sides (30%), the RMV was adjacent, whereas in others,

it was positioned anterior to the posterior border of the ramus. If the RMV is damaged during SSRO, it is difficult to stop the bleeding. Pressure hemostasis is also ineffective in such situations. This demonstrates the need for a careful clearly subperiosteal approach before performing the horizontal cut at the medial aspect of the ramus during SSRO.

As in our previous cadaver investigation (8), no participant of our study exhibited a pattern involving the RMV running lateral to the ramus inferior to the lingula, which is the position of the lateral cut according to Trauner and Obwegeser's method (9). These anomalies pose a potential risk for intraoperative bleeding. Furthermore, the high incidence of vascular variations in jaw deformity patients (6,7) necessitates extra care during mandibular osteotomy, regardless of the particular approach, such as Trauner and Obwegeser's or Obwegeser's methods.

Additionally, in cases of severe mandibular prognathism needing a long medial cut during osteotomy, the distal bone segment may be positioned posterior to the posterior border of the ramus during mandibular fixation. There were differences in both the types and patterns between the left and right sides observed for the first time in this study, and half of the cases were discordant. This indicates that even if the problem is confined to one side, the other side may exhibit a greater risk of bleeding. These findings indicate the need to preoperatively consider whether a short lingual split should be created for the medial cut in patients with a large posterior displacement.

Orthognathic surgery is a type of plastic surgery that does not usually result in serious complications. However, there are many variations in the blood vessels traveling within soft tissues, and care must be taken throughout the entire surgical process. During SSRO, the periosteum should be carefully dissected for preservation and firmly protected with a Prognathie-hook. However, in cases with large posterior mandibular movement, the choice of medial osteotomy and post-sagittal division treatment postoperative treatment should be carefully considered. The classification of these RMV types and patterns would be useful for intraoral vertical ramus osteotomy, tumor surgery, open reduction, and internal fixation.

Although the number of cases in this study was low, this is the first report on RMV running patterns and positions in patients with jaw deformities. In the future, we will increase the number of cases; investigate the relationship between skeletal classification, mandibular branch morphology, and RMV running pattern and position, and identify cases

requiring urgent attention during surgery.

## Conclusions

We identified three types of positional relationship between the RMV and the posterior border of the ramus and five RMV course patterns using CECT in jaw deformity patients in this study. Although CECT must be taken preoperatively, the findings suggest it may be possible to predict correlations with intraoperative bleeding risk. Furthermore, additional study of a larger patient series should be conducted to validate these results.

## Acknowledgments

We would like to thank the members of the Department of Oral Pathobiological Science and Surgery, Tokyo Dental College, for their cooperation. And we would like to thank Editage ([www.editage.jp](http://www.editage.jp)) for English language editing.

*Funding:* None.

## Footnote

*Conflicts of Interest:* All authors have completed the ICMJE uniform disclosure form (available at <https://qims.amegroups.com/article/view/10.21037/qims-23-1301/coif>). The authors have no conflicts of interest to declare.

*Ethical Statement:* The authors are accountable for all aspects of the work in ensuring that questions related to the accuracy or integrity of any part of the work are appropriately investigated and resolved. This study was conducted in accordance with the Declaration of Helsinki (as revised in 2013). The study was approved by the Ethics Committee of Tokyo Dental College (Nos. 794 and 844). Written informed consent was obtained from patients or patients' parents for the publication of this study and any accompanying images.

*Open Access Statement:* This is an Open Access article distributed in accordance with the Creative Commons Attribution-NonCommercial-NoDerivs 4.0 International License (CC BY-NC-ND 4.0), which permits the non-commercial replication and distribution of the article with the strict proviso that no changes or edits are made and the original work is properly cited (including links to both the formal publication through the relevant DOI and the license). See: <https://creativecommons.org/licenses/by-nc-nd/4.0/>.

## References

1. Hamada Y, Sugahara K, Yoshida S, Watanabe A, Bessho H, Kasahara K, Takano M, Saito C, Shibahara T, Katakura A. A 27-year retrospective clinical analysis of 2640 orthognathic surgery cases in the Tokyo Dental College. *J Oral Maxillofac Surg Med Pathol* 2019;31:305-10.
2. Bays RA, Bouloux GF. Complications of orthognathic surgery. *Oral Maxillofac Surg Clin North Am* 2003;15:229-42.
3. Dos Santos VDB, Queiroz SIML, da Silva AC, Silva S, da Silva JSP, Fernandes GVO, Germano AR. Evaluation of the Anatomic Position of the Mandibular Canal Regarding to the Segments of the Mandibular Sagittal Split Ramus Osteotomy to Diminish the Possibility of Injuries: a Pilot Study. *J Oral Maxillofac Res* 2022;13:e2.
4. Panula K, Finne K, Oikarinen K. Incidence of complications and problems related to orthognathic surgery: a review of 655 patients. *J Oral Maxillofac Surg* 2001;59:1128-36; discussion 1137.
5. Patel PK, Morris DE, Gassman A. Complications of orthognathic surgery. *J Craniofac Surg* 2007;18:975-85; Quiz 986-8.
6. Lanigan DT, Hey JH, West RA. Major vascular complications of orthognathic surgery: false aneurysms and arteriovenous fistulas following orthognathic surgery. *J Oral Maxillofac Surg* 1991;49:571-7.
7. Jackson IT, Jack CR, Aycock B, Dubin B, Irons GB. The management of intraosseous arteriovenous malformations in the head and neck area. *Plast Reconstr Surg* 1989;84:47-54.
8. Sugahara K, Matsunaga S, Yamamoto M, Noguchi T, Morita S, Koyachi M, Koyama Y, Koyama T, Kasahara N, Abe S, Katakura A. Retromandibular vein position and course patterns in relation to mandible: anatomical morphologies requiring particular vigilance during sagittal split ramus osteotomy. *Anat Cell Biol* 2020;53:444-50.
9. TRAUNER R, OBWEGESER H. The surgical correction of mandibular prognathism and retrognathia with consideration of genioplasty. I. Surgical procedures to correct mandibular prognathism and reshaping of the chin. *Oral Surg Oral Med Oral Pathol* 1957;10:677-89; contd.
10. Piñeiro-Aguilar A, Somoza-Martín M, Gandara-Rey JM, García-García A. Blood loss in orthognathic surgery: a systematic review. *J Oral Maxillofac Surg* 2011;69:885-92.
11. Touré G, Vacher C. Relations of the facial nerve with the retromandibular vein: anatomic study of 132 parotid glands. *Surg Radiol Anat* 2010;32:957-61.
12. Babademez MA, Acar B, Gunbey E, Karabulut H, Karasen RM. Anomalous relationship of the retromandibular vein to the facial nerve as a potential risk factor for facial nerve injury during parotidectomy. *J Craniofac Surg* 2010;21:801-2.
13. Lohn JW, Penn JW, Norton J, Butler PE. The course and variation of the facial artery and vein: implications for facial transplantation and facial surgery. *Ann Plast Surg* 2011;67:184-8.
14. Koh KS, Kim HJ, Oh CS, Chung IH. Branching patterns and symmetry of the course of the facial artery in Koreans. *Int J Oral Maxillofac Surg* 2003;32:414-8.

**Cite this article as:** Sugahara K, Oiwa K, Matsunaga S, Odaka K, Hirouchi H, Koyachi M, Kasahara N, Tachiki C, Nishii Y, Wolff KD, Katakura A. Contrast-enhanced computed tomography of retromandibular vein position and course patterns relative to the mandible during sagittal split ramus osteotomy. *Quant Imaging Med Surg* 2024;14(2):1652-1659. doi: 10.21037/qims-23-1301