



Efficacy and safety of laparoscopic vaginoplasty with peritoneal flaps and cervicoplasty in patients with congenital cervical and complete vaginal atresia: a pilot study

Huili Liu^{1,2,3#}, He Zhang^{1#}, Chenman Wang², Qun Dang¹

¹Department of Gynecology, Henan Provincial People's Hospital, Zhengzhou, China; ²Department of Gynecology, People's Hospital of Zhengzhou University, Zhengzhou, China; ³Department of Gynecology, People's Hospital of Henan University, Zhengzhou, China

Contributions: (I) Conception and design: Q Dang; (II) Administrative support: None; (III) Provision of study materials or patients: H Liu, H Zhang; (IV) Collection and assembly of data: C Wang; (V) Data analysis and interpretation: H Liu, H Zhang, C Wang; (VI) Manuscript writing: All authors; (VII) Final approval of manuscript: All authors.

#These authors contributed equally to this work.

Correspondence to: Qun Dang, MB. Department of Gynecology, Henan Provincial People's Hospital, No. 7 Weiwu Road, Zhengzhou 450000, China. Email: Dangjunyang@126.com.

Background: Hysterectomy places a considerable physical and mental burden on young female patients with congenital cervical and complete vaginal atresia. Thus, it is necessary to develop a method to detach the obstruction and simultaneously preserve the vagina and uterus in these patients. This study sought to evaluate the efficacy and safety of laparoscopic vaginoplasty using peritoneal flaps and cervicoplasty in patients with congenital cervical and complete vaginal atresia.

Methods: Between April 2013 and June 2022, nine patients with congenital cervical and complete vaginal atresia at Henan Provincial People's Hospital were enrolled in this prospective study. All patients were treated with laparoscopic vaginoplasty using peritoneal flaps and cervicoplasty. Baseline clinical data (e.g., age and uterus size) were collected. The surgical success rate and adverse events were assessed.

Results: The nine enrolled patients had a median age of 15.0 [interquartile range (IQR), 14.0–18.0] years, and five of these patients had pelvic adhesions. The surgeries were successful in all (9/9) patients, with the vagina, uterus, and a normal menstrual cycle being preserved. After a median follow-up duration of 48 months, the neovaginas had a median length of 7.5 cm. Postoperative complications occurred in three of patients and were cured with the appropriate treatment. The five married patients reported being satisfied with their sex life.

Conclusions: The study preliminarily demonstrated the efficacy of laparoscopic vaginoplasty using peritoneal flaps and cervicoplasty in patients with congenital cervical and complete vaginal atresia. However, due to the small sample size, lack of a control group, and relatively high incidence of adverse events, further studies are still needed to verify these results. Regardless, our findings establish an approach for preserving both the vagina and uterus for patients with congenital cervical and complete vaginal atresia.

Keywords: Cervical atresia; cervicoplasty; complete vaginal atresia; laparoscopic surgery; vaginoplasty

Submitted Aug 28, 2023. Accepted for publication Jan 29, 2024. Published online Feb 23, 2024.

doi: 10.21037/qims-23-1226

View this article at: <https://dx.doi.org/10.21037/qims-23-1226>

Introduction

Congenital vaginal atresia is a rare malformation of the female reproductive tract that can be classified into partial and complete vaginal atresia (1). Congenital vaginal atresia can obstruct menstrual blood flow and may also lead to a series of clinical problems, such as amenorrhea, abdominal pain, pelvic mass, and endometriosis, which require timely surgical dissociation to relieve the obstruction (2). Complete vaginal atresia is usually associated with cervical dysplasia or cervical atresia (1,3,4). Currently, the main surgical method for patients with complete vaginal atresia is vaginoplasty with or without sparing of the uterus (5,6). However, hysterectomy places a massive physical and mental burden on young females and their families (7,8). Thus, it is necessary to develop a method to detach the obstruction, prevent endometriosis, and simultaneously preserve the vagina and uterus.

After the initial paper on the subject was published by Frank (9), several studies have been conducted demonstrating the efficacy and safety of using the vaginal dilation method for the creation of the neovagina. However, in the context of cervicovaginal agenesis, a surgical approach can be adopted, as the patient already requires an operation either for anastomosis or hysterectomy. For instance, some surgical techniques, such as Davydov's laparoscopic technique and the laparoscopic Vecchietti technique, are frequently used in these patients (9-11). However, these surgical techniques are complicated to perform, and a consensus or guideline for clinically guiding the surgical methodology in treating patients with congenital cervical and complete vaginal atresia has not yet been established.

Hence, we conducted a prospective study in order to evaluate the efficacy and safety of laparoscopic vaginoplasty using a peritoneal flap and cervicoplasty in patients with congenital cervical and complete vaginal atresia. We present this article in accordance with the AME Case Series and STROBE reporting checklists (available at <https://qims.amegroups.com/article/view/10.21037/qims-23-1226/rc>).

Methods

Patients

Between April 2013 and June 2022, nine patients with congenital cervical and complete vaginal atresia who underwent surgical treatment in Henan Provincial People's Hospital were enrolled in this prospective, observational study. To be eligible for inclusion in this study, the patients

had to meet the following inclusion criteria: (I) primary amenorrhea in adolescence; (II) a karyotype of 46,XX; (III) a lack of a vaginal orifice according to gynecological examination; (IV) a functional uterus as confirmed with magnetic resonance imaging (MRI) or color Doppler ultrasound (defined as the presence of hematometra in the uterus under MRI); and (V) about to receive laparoscopic vaginoplasty with peritoneal flaps and cervicoplasty. Patients were excluded from the study if they met any of the following exclusion criteria: (I) with part of an upper vaginal segment and/or (II) about to receive vaginoplasty using other material or via hysterectomy. For patients aged older than 18 years, both the patients and their guardians signed the written informed consent form; for patients aged younger than 18 years, their guardians signed the written informed consent form. The study was conducted in accordance with the Declaration of Helsinki (as revised in 2013) and was approved by the medical ethics committee of Henan Provincial People's Hospital.

Surgical procedure

All surgeries were performed by the same experienced surgeon. Patients were placed in the lithotomy position, and general anesthesia was then administered. Next, a laparoscope was used to examine the pelvic cavity, and the corresponding operation was carried out if there were structural abnormalities. Two peritoneal flaps were detached via monopolar electrocautery or with an ultrasonically activated scalpel: (I) one with a length of 8–10 cm and a width of 5 cm from the surface of the bladder at the peritoneal reflection site and (II) one with a length of 8 cm and width of 5 cm in the middle of the bilateral sacroiliac ligament and in front of the rectum. Vaginoplasty was then performed. Specifically, 300 mL of dilute pituitrin (including oxytocin and vasopressin) in normal saline (6 U: 500 mL) was injected into the rectovesical space. The vaginal orifice was transversely incised, and the rectovesical space was dissected bluntly to the cervical site. Next, the cervical location was confirmed via laparoscopic pushing of the uterus toward the neovaginal direction. The surgeon was careful to push the uterus down into the vaginal cavity, and the uterus would exert no resistance during the descent due to the presence of a vaginal cavity. The vesocervical space and rectocervical space were then bluntly dissected to unclog the pelvic cavity. Subsequently, the peritoneal flaps from the surface of the bladder and rectum were transferred to the neovaginal cavity, which was pulled

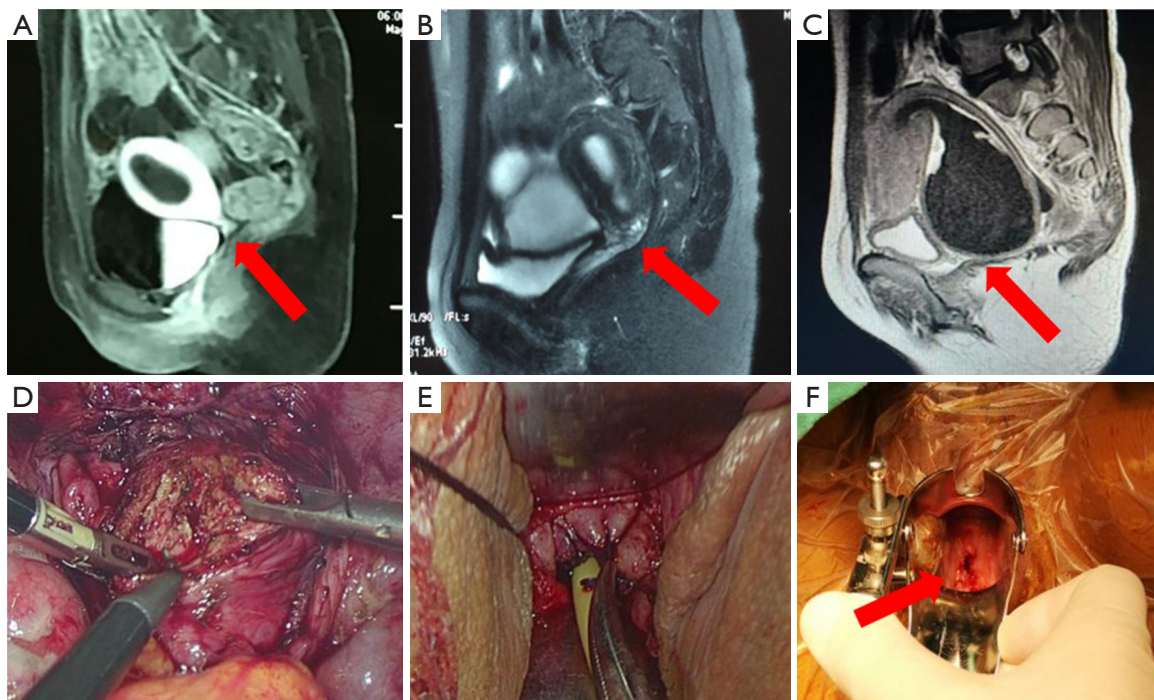


Figure 1 MRI image of a vagina and uterus and the surgical procedure for patients with congenital cervical and complete vaginal atresia. (A) Type A cervical atresia: cervical dysplasia accompanied by hematometra; the red arrow indicates atresia of the cervix. (B) Type B cervical atresia: hematometra concurrent with stenosis, effusion, and partial atresia of the cervical duct; the red arrow indicates atresia of the cervix. (C) Type C cervical atresia: a normal uterus and cervix, with the inferior uterine segment and the cervix being obviously dilated and showing effusion; the red arrow indicates atresia of the cervix. (D) The orifice of the cervix is laparoscopically dissected in the shape of a plus sign, and a No. 12 (millimeters' width) dilator rod is inserted through the cervical orifice. (E) The cervix is pulled down into the neovaginal cavity to form a “vaginal vault”, and the apical vagina is sutured with the superior cervical segment. (F) In one patient, the cervical orifice appeared normal, and the “vaginal vault” disappeared 1 year after the surgery; the red arrow indicates the artificial neocervix. MRI, magnetic resonance imaging.

toward the vaginal orifice with laparoscopic assistance. Following this, the peritoneal flap from the surface of the bladder was sutured and fixed at 2 o'clock and 10 o'clock, respectively, with a No. 7 surgical suture (a nonabsorbable and permanent suture), and the peritoneum flap from the surface of the rectum was sutured and fixed at 4 o'clock and 8 o'clock, respectively, with a No. 7 surgical suture.

Cervicoplasty was then performed. Patients with different uterine or cervical malformations were treated with different types of surgeries. The following three types of uterine or cervical malformations were observed: A-type, characterized by cervical dysplasia concurrent with parenchyma absence and accompanying hematometra (patients 1, 3, and 5; *Figure 1A*); B-type, characterized by cervical dysplasia concurrent with cervical duct incomplete atresia and cervical duct and hematometra that is more

remarkable in the uterus (patients 2, 4, 7, and 9; *Figure 1B*); and C-type, characterized by a normal uterus and cervix but with the external orifice of the cervix being blocked and the cervix being obviously dilated (patients 6 and 8; *Figure 1C*).

The detailed surgical procedure for A- and B-type patients was as follows: the uterus was turned over (The round and broad ligaments of the uterus were very malleable and could be turned over without concern. The blood vessels of the uterus were spiral-tortuous and had excellent elasticity. When the bladder and the uterus were opened and the peritoneum was folded, the ureter detached from the uterine body, so it was impossible to tighten the ureter). The cervix was laparoscopically dissected at the orifice of the cervix in the shape of a plus sign via electrocautery (*Figure 1D*); the uterus was then pulled down into the neovaginal cavity, and the cervix was dilated to drain the

blood in the uterus; a No. 12 (millimeters' width) dilator rod was inserted into the uterine cavity through the cervix, and a No. 1 absorbable suture was applied for suturing. The detailed surgical procedure for C-type patients was as follows: the cervix was dissected at the orifice of the cervix in the shape of a plus sign via electrocautery through the neovaginal cavity, and the remainder of the procedure was the same as that described for the A- and B-type patients. The peritoneal flap and skin at the neovaginal orifice were sutured intermittently with a 2-0 absorbable suture clockwise, and the bilateral walls were sutured intermittently with absorbable sutures to ensure that the peritoneal flap covered the neovaginal cavity completely. The cervix was pulled down into the neovaginal cavity to form a "vaginal vault" (Figure 1E,1F). The anterior and posterior peritoneal flaps of the apical vagina were laparoscopically sutured with the superior cervical segment to fix the uterus and seal the pelvic cavity.

The maintenance of the cervical canal is essential for this procedure. An 18-gauge Foley catheter was placed in the uterine cavity through the neovagina and cervix, which was removed during the subsequent menstrual period. The vaginal mold was placed in the neovagina for 6 months and was substituted each day. The vaginal mold was only placed in the neovagina during the night and not during the day and was removed after the patient resumed sexual activity. The purpose of this was to prevent cervical adhesions and stenosis. The Foley double-cavity catheters were removed after the cervical wound had fully healed, and except for local inflammation, adhesions and stenosis would no longer occur. Patients were required to attend regular follow-up to determine whether there was inflammation in the vagina and, especially in the menstrual period, to assess whether the menstrual blood could flow smoothly. Finally, the uterus was located in the center of the pelvic cavity, with the vesicouterine peritoneal reflexion in the front and the rectouterine peritoneal reflexion in the back. The details of the surgical procedure are presented in Figure 2A-2H.

Data collection and measurement of efficacy and safety outcomes

At baseline, patients' clinical features, including age, reproductive system malformations and lesions, and previous surgical history, were recorded. The primary outcome was the surgical success rate, with success being defined as the creation of a two-finger-wide neovaginal cavity, a neocervix observable with a speculum, and

normal drainage of menstrual period blood. During the intraoperative and postoperative period, patients' vaginal and cervical adhesion atresia status, length of vagina, pelvic cysts (based on a pelvic ultrasound), menstruation discharge status, operation time, intraoperative blood loss, and sexual satisfaction as reflected by the Female Sexual Function Index were also assessed. Furthermore, surgical complications were also recorded, including fever and intraoperative injury. Once surgical complications occurred, symptomatic treatment was administered. The definition of a satisfactory outcome for the patient was as follows: it was not necessary for the patients to remove the uterus, there was a certain length of the vagina. Besides, there was a menses, and the patients were satisfied with their sex life, if there was one.

Statistical analysis

SPSS 24.0 (IBM Corp., Armonk, NY, USA) was used for the statistical analysis. The continuous variables in this paper are presented as the mean \pm standard deviation or the median and interquartile range (IQR), as appropriate. Categorical variables are presented as numerators and denominators.

Results

Patient features

The nine enrolled patients had a median (IQR) age of 15.0 (14.0–18.0) years, a median uterus size of 54.0 (IQR, 33.0–84.7) cm³, and a median duration of abdominal pain of 12.0 (IQR, 1.6–42.0) months. Among the nine patients, five exhibited pelvic adhesions. More patient details information are provided in Table 1. Type A, B, and C cervical atresia according to MRI are presented in Figure 1A-1C.

Surgical information

The median surgical duration was 230.0 (IQR, 182.0–250.0) min, and the median bleeding volume during surgery was 100.0 (IQR, 80.0–200.0) mL. Of the nine patients, seven had their cervixes dissected at the orifice of the cervix in the shape of a plus sign, and a No. 12 (millimeters' width) dilator rod could be inserted into their neocervix. However, in the remaining two patients, only a No. 9 (millimeters' width) dilator rod could be inserted into their neocervix. Endometriosis was observed in four patients, but

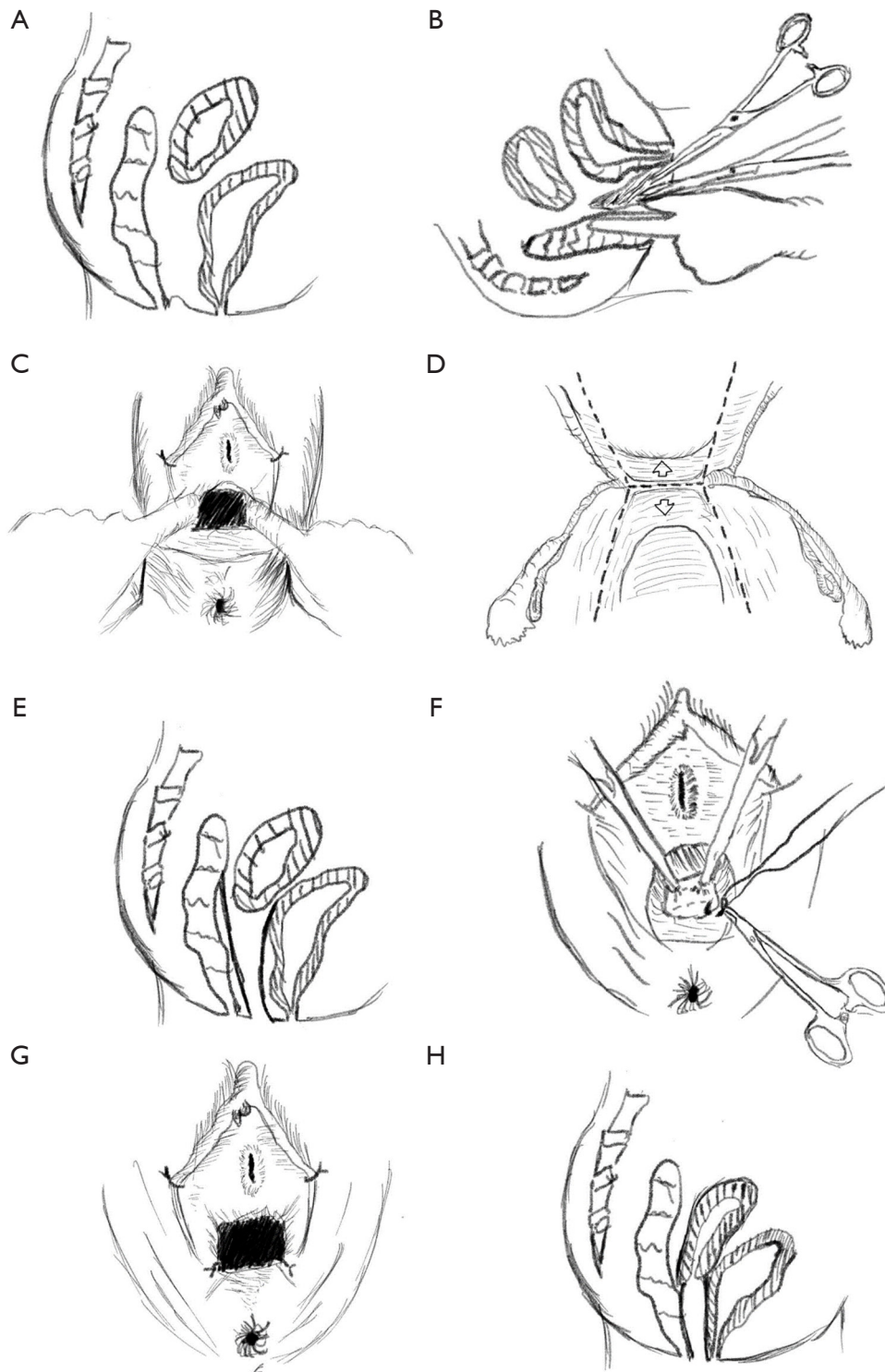


Figure 2 Schematic diagram of vaginoplasty using peritoneal flaps and cervicoplasty. (A) Preoperation. (B) Opening of the vesicorectal space cavity. (C) The formation of the neovaginal orifice. (D) Laparoscopically free vesicoperitoneum and rectoperitoneum in the transverse view. (E) Laparoscopically free vesicoperitoneum and rectoperitoneum in the sagittal view. (F) Pulling of the peritoneum to the neovaginal orifice. (G) Interrupted suturing of the peritoneum and neovaginal orifice for 1 week. (H) The neocervix connected with the neovagina after cervicoplasty.

Table 1 Clinical characteristics of the patients

Items	Values (n=9)
Age (years)	
Median (IQR)	15.0 (14.0–18.0)
Range	11.0–28.0
Uterus size (cm ³)	
Median (IQR)	54.0 (33.0–84.7)
Range	17.9–108.5
Duration of abdominal pain (months)	
Median (IQR)	12.0 (1.6–42.0)
Range	0.1–96.0
Pelvic adhesions, n	5
Uterine or cervical malformations, n	
A-type	3
B-type	4
C-type	2
Follow-up duration (months)	
Median (IQR)	48.0 (34.0–54.0)
Range	12.0–109.0

IQR, interquartile range.

all of them had a functional uterus and hematometra. These four patients were subsequently dissected via excision or electrocautery evaporation. Pelvic adhesion was observed in five patients and was further detached via separation surgery (*Table 2* and *Table S1*).

Adverse events during surgery

Fever occurred in five of the nine patients (*Table 2*). The cause of the fever was aseptic inflammation caused by surgical trauma. Antibiotics were used to prevent infection. Intraoperative injury occurred in two patients. Specifically, bladder injury was observed in one patient with a lesion size of 1.5 cm, which was repaired by neoplasty; thereafter, the bladder was sutured in two layers with a 2-0 absorbable suture. The urethral catheter was removed 2 weeks after the operation, and normal function of the bladder was verified via urinary ultrasound. Another patient experienced an intraoperative rectal injury, and the lesion was 1 cm away from the neovaginal orifice. The patient's rectum was repaired with a 3-0 absorbable suture and with a

Table 2 Surgical information and intraoperative adverse events

Items	Values (n=9)
Surgical information	
Surgical duration (min)	
Median (IQR)	230.0 (182.0–250.0)
Range	105.0–270.0
Bleeding volume (mL)	
Median (IQR)	100.0 (80.0–200.0)
Range	50.0–300.0
Cervical orifice dissection, n	7
Dilator rod usage (mm), n	
No. 12	7
No. 9	2
Pelvic adhesion separation, n	5
Endometriosis excision or electrocautery, n	4
Intraoperative adverse events, n	
Fever	5
Intraoperative injury	2
Bladder injury	1
Rectal injury	1

IQR, interquartile range.

No. 4 suture through the neovagina, and the wound was covered with a peritoneal flap (*Table 2*). For this patient, postoperative rectal decompression and drainage were performed for 5 days with a 26-gauge silicone tube placed in the anus, and the patient was cured following fasting and intravenous infusion with nutrition for 1 week. After a 7- to 10-day hospitalization, all patients were able to exchange the vaginal mold by themselves and were discharged from the hospital.

Surgical outcomes

The median follow-up duration was 48.0 (IQR, 34.0–54.0) months. The surgery was successful in all patients (9/9). During the postoperative follow-up, the vaginal vault disappeared in all patients 1–2 months after the surgery. The neovagina had a median length of 7.5 (IQR, 7.0–7.5) cm. Postoperative complications occurred in three patients with a B-type cervix. Among these three patients,

Table 3 Surgical outcomes

Items	Values (n=9)
Surgical successful rate, n	9
Length of neovagina (cm)	
Median (IQR)	7.5 (7.0–7.5)
Range	6.5–8.0
Satisfaction with sex life, n	
Satisfactory	5
No sex life	4
Postoperative complications, n	3

IQR, interquartile range.

cervical adhesion–induced amenorrhea occurred in one of them 2 years after the surgery, but the patient recovered after 1 month of hysteroscopic dissociation and the preventive use of the No. 18 Foley double-lumen catheter. A reduced menstrual volume accompanied by abdominal pain and cervical stenosis was reported in another patient 2 years after surgery, and the patient was cured after a three-menstrual-cycle dilation of the uterus. Finally, one of the three patients had multiple vaginal polyps with bleeding during sexual intercourse 6 months after the surgery, which was cured via surgical resection (*Table 3*). Those patients with stenosis years after the surgery were cured, and the menstrual blood could flow smoothly without the need for a hysterectomy.

The five who had a sex life reported that they were satisfied with it. The one patient with an A-type cervix became pregnant three times; unfortunately, all pregnancies were terminated due to spontaneous abortion (*Table 3*).

Discussion

Several findings were obtained in this study: (I) the general success rate of our surgery was acceptable; (II) two types of cervical malformations with complete vaginal atresia were observed in this study, and the surgical successful rates were also acceptable; and (III) a peritoneal flap was shown to be a viable alternative material to other allografts or skin grafts for laparoscopic vaginoplasty.

Compared with the traditional open surgery, laparoscopic surgery is associated with some advantages and disadvantages. Specifically, laparoscopic surgery might provide smaller wounds; relatively less pain; faster

postoperative recovery; considerably less postoperative intestinal adhesion, infection, or other phenomena; and only small scars and a good appearance (12). Meanwhile, the disadvantages of laparoscopic surgery include its relatively high technical requirements for surgeon, easy-to-miss lesions, and high expense. However, in this study, the patients were young women with high reproductive and aesthetic demands; thus, laparoscopic surgery was more suitable for these patients.

Complete vaginal atresia is commonly accompanied by cervical dysplasia or cervical atresia (1,13). Patients with complete vaginal atresia consistently experience abdominal pain, fallopian tube dilation, cyst formation, and pelvic endometriosis due to hematocoele in the uterine or cervical duct and the reflux of menstrual blood into the pelvic cavity (3,14). Unfortunately, there are still no non- or less-invasive techniques that can be applied for patients with congenital cervical and complete vaginal atresia. In our study, other treatment modalities, such as hormone blocking, were not implemented in these patients. For pubescent patients, a lack of menstruation with periodic abdominal pain may be ultimately caused by menstrual blood gathering in the uterine cavity and thus not being discharged; therefore, clinicians who recognize these signs can make an early diagnosis and provide treatment, reducing and avoiding the occurrence of endometriosis. Currently, the main treatment method for patients with complete vaginal atresia is surgery. During surgery, the preservation of the uterus is a key desire for females who wish to bear children (15–17).

The surgical method employed in this study was convenient and simple. The uterus and vagina were successfully preserved in all (9/9) patients who underwent laparoscopic peritoneal vaginoplasty plus cervicoplasty, and the patients had satisfactory outcomes after 12 to 109 months of follow-up. The notable surgical outcomes included the management of the cervix and the unclogging of the neovaginas. The novelty of this study is as follows: (I) the plus sign-shaped incision created a sufficiently large cervical orifice into which a No. 12 (millimeters' width) dilator rod could easily be inserted and from which menstrual blood could drain. (II) The formation of a vaginal vault via the pulling down of the cervix into the neovaginal cavity might have prevented cervical retraction and adhesion atresia at the top of the vagina during the process of vaginal peritonealization. (III) The placement of double-lumen balloon tubes in the cervix and uterine cavity after the operation and until the next menstrual cycle promoted the healing and formation of the cervical canal

and might have prevented cervical adhesion atresia. In this procedure, the length of the balloon tube was fixed, the end of the balloon tube was outside the vagina, and the balloon was injected with 3 mL of normal saline. As the normal uterine volume is 5 mL, the injection of 3 mL of normal saline could not only prevent cervical duct adhesion but also prevent the balloon from falling out and compressing the endometrium. (IV) The requirement that the patients strictly follow the clinician's instruction on postoperative management and that they correctly wear the mold might have prevented vaginal adhesion or reatresia.

Rock *et al.* (18) suggested that cervical malformations with complete vaginal atresia can be divided into the following two types: type I, cervical hypoplasia (the complete absence of the cervix without the presence of cervical stroma); and type II, cervical dysplasia. Type II patients can be further divided into the following subtypes: (I) cervical fragmentation (fragmentation of the cervix can be observed); (II) cervical dysplasia (fibrous band or cord, with the diameter of the cord and the characteristics of the matrix potentially varying); and (III) cervical obstruction (an intact cervical body with obstruction of the cervical orifice). In line with a previous study (18), the following three types of cervical and vaginal malformations were observed in the nine patients with complete vaginal atresia as diagnosed by MRI imaging in our study: A-type (cervical dysplasia concurrent with parenchyma absence), B-type (cervical dysplasia concurrent with cervical duct incomplete atresia and cervical duct and hematometra, which was more remarkable in the uterus), and C-type (a normal uterus and cervix but with a blocked external cervical orifice and an obviously dilated cervix). In the A-type patients, the cervical ostomy operation was complicated, and the operation time was long; however, these patients had a regular postoperative menstrual cycle and a satisfactory sex life, and one patient became pregnant. In the B- and C-type patients, the cervical ostomy operation procedure was simple and only included dissection of the external cervix and subsequent suturing. Furthermore, no fibrous cord or band or cervical fragmentation was observed in any of the nine patients.

In previous studies, after the initial fertility preservation operation, some patients still face a high risk of hysterectomy due to vaginal atresia or cervical stenosis atresia caused by repeated operations or infection (19,20). Additionally, the risk of reatresia exists when the wound is not covered with appropriate materials after cervicoplasty and vaginoplasty (21). Currently, the commonly used

materials for covering the vagina include the amniotic membrane, a small intestinal submucosa graft, skin, biological materials, peritoneum, and other flaps (19,21-25). However, most papers on the application of these materials have been case reports, and all of these materials (except the skin and the peritoneum) require the application of allografts. Furthermore, a neovagina that uses skin as a covering can still maintain keratinized epithelial cells, sebaceous glands, and hair even 2 years after the operation (5). In our study, a peritoneal flap was applied instead of other allografts or skin grafts, which might help to reduce the additional damage to the uterus and decrease the expense of surgery.

Despite its novelty, the detailed step-by-step description of the procedure, and long follow-up duration (median time 48 months), this study had some limitations. First, the sample size was small, which limited the type of malformed cervixes. Second, the age of the enrolled patients was young, and consequently, few sex life-related events could be observed; thus, the patient satisfaction with sex life was difficult to ascertain. Third, only one patient became pregnant—this occurred three times with concurrent spontaneous abortions—and no patient reached an intermediate or advanced gestation period. Thus, long-term pregnancy outcomes could not be evaluated. Fourth, a long-term follow-up is needed to further determine the success rate (including successful pregnancies and the patients' satisfaction) of laparoscopic vaginoplasty with peritoneal flaps and cervicoplasty in patients with congenital cervical and complete vaginal atresia.

Conclusions

Laparoscopic vaginoplasty with peritoneal flaps and cervicoplasty is effective and safe in patients with congenital cervical and complete vaginal atresia and can preserve both the vagina and uterus. However, further research with larger sample sizes and longer follow-up periods needs to be conducted to validate the findings of this study and confirm the efficacy of this surgery in improving pregnancy outcomes.

Acknowledgments

Funding: None.

Footnote

Reporting Checklist: The authors have completed the AME

Case Series and STROBE reporting checklists. Available at <https://qims.amegroups.com/article/view/10.21037/qims-23-1226/rc>

Conflicts of Interest: All authors have completed the ICMJE uniform disclosure form (available at <https://qims.amegroups.com/article/view/10.21037/qims-23-1226/coif>). The authors have no conflicts of interest to declare.

Ethical Statement: The authors are accountable for all aspects of the work in ensuring that questions related to the accuracy or integrity of any part of the work are appropriately investigated and resolved. For patients aged older than 18 years, both the patients and their guardians signed the written informed consent form; for patients aged younger than 18 years, their guardians signed the written informed consent form. The study was conducted in accordance with the Declaration of Helsinki (as revised in 2013) and was approved by the medical ethics committee of Henan Provincial People's Hospital.

Open Access Statement: This is an Open Access article distributed in accordance with the Creative Commons Attribution-NonCommercial-NoDerivs 4.0 International License (CC BY-NC-ND 4.0), which permits the non-commercial replication and distribution of the article with the strict proviso that no changes or edits are made and the original work is properly cited (including links to both the formal publication through the relevant DOI and the license). See: <https://creativecommons.org/licenses/by-nc-nd/4.0/>.

References

- Mei L, Zhang H, Chen Y, Niu X. Clinical features of congenital complete vaginal atresia combined with cervical aplasia: A retrospective study of 19 patients and literature review. *Congenit Anom (Kyoto)* 2021;61:127-32.
- Kang J, Zhou Q, Chen N, Liu Z, Zhang Y, Sun J, Ma C, Chen F, Ma Y, Wang L, Zhu L, Wang W. Clinical and Genetic Characteristics of a Cohort with Distal Vaginal Atresia. *Int J Mol Sci* 2022;23:12853.
- Slaoui A, Benzina I, Talib S, Etber A, Zerai N, Lakhdar A, Kharbach A, Baydada A. Congenital vaginal atresia: about an uncommon case. *Pan Afr Med J* 2020;37:69.
- Xu S, Zhang J, Wang S, Yang L, Qian J, Yue S, Zhu D, Yang L, Zhao L, Yang A, Li Y, Xue Q. MRI features and differential diagnoses of congenital vaginal atresia. *Gynecol Endocrinol* 2019;35:777-81.
- Fedele F, Bulfoni A, Parazzini F, Busnelli A. Neovagina creation methods in Müllerian anomalies and risk of malignancy: insights from a systematic review. *Arch Gynecol Obstet* 2024;309:801-12.
- Chen N, Song S, Bao X, Zhu L. Update on Mayer-Rokitansky-Kuster-Hauser syndrome. *Front Med* 2022;16:859-72.
- Kotani Y, Murakami K, Fujishima R, Kanto A, Takaya H, Shimaoka M, Nakai H, Matsumura N. Research Article Quality of life after laparoscopic hysterectomy versus abdominal hysterectomy. *BMC Womens Health* 2021;21:219.
- Pathiraja PDM, Jayawardane A. Evaluation of Peripartum Hysterectomy in a Tertiary Care Unit and Its Effect on Patients' Long-Term Physical and Mental Wellbeing: Quest Is Not Over When You Save the Life. *Obstet Gynecol Int* 2021;2021:5720264.
- Frank RT. The formation of an artificial vagina without operation. *Am J Obstet Gynecol* 1938;35:1053-55.
- Fedele L, Bianchi S, Frontino G, Fontana E, Restelli E, Bruni V. The laparoscopic Vecchietti's modified technique in Rokitansky syndrome: anatomic, functional, and sexual long-term results. *Am J Obstet Gynecol* 2008;198:377.e1-6.
- Fedele L, Frontino G, Restelli E, Ciappina N, Motta F, Bianchi S. Creation of a neovagina by Davydov's laparoscopic modified technique in patients with Rokitansky syndrome. *Am J Obstet Gynecol* 2010;202:33.e1-6.
- De Gouveia De Sa M, Claydon LS, Whitlow B, Dolcet Artahona MA. Laparoscopic versus open sacrocolpopexy for treatment of prolapse of the apical segment of the vagina: a systematic review and meta-analysis. *Int Urogynecol J* 2016;27:3-17.
- Xie Z, Zhang X, Zhang N, Xiao H, Liu Y, Liu J, Chen L, Li L, Zhang L, Zhang Y. Clinical features and surgical procedures of congenital vaginal atresia-A retrospective study of 67 patients. *Eur J Obstet Gynecol Reprod Biol* 2017;217:167-72.
- Regmi DR, Dangal G, Karki A, Pradhan HK, Shrestha R, Bhattachan K, Tiwari KD, Bharati S, Manandhar P, Maharjan S. Vaginal Atresia with Cervical Agenesis, a Rare Congenital Malformation. *Kathmandu Univ Med J (KUMJ)* 2021;19:390-2.
- Kang J, Chen N, Zhang Y, Ma C, Ma Y, Wang Y, Tian W, Zhu L. Laparoscopically Assisted Uterovaginal Canalization and Vaginoplasty for Patients with Congenital Cervical and Vaginal Atresia: A Step-by-

- step Guide and Long-term Outcomes. *J Minim Invasive Gynecol* 2021;28:1203-10.
16. Zhao XW, Ma JY, Wang YX, Zhang H, Zhang J, Kang S. Laparoscopic vaginoplasty using a single peritoneal flap: 10 years of experience in the creation of a neovagina in patients with Mayer-Rokitansky-Kuster-Hauser syndrome. *Fertil Steril* 2015;104:241-7.
 17. Zhao X, Zhang Y, Zhang M, Zhang H, Tian Y, Kang S. Comparison of two laparoscopic vaginoplasties using a single peritoneal flap in patients with Mayer-Rokitansky-Kuster-Hauser syndrome. *Int Urogynecol J* 2022;33:2543-49.
 18. Rock JA, Roberts CP, Jones HW Jr. Congenital anomalies of the uterine cervix: lessons from 30 cases managed clinically by a common protocol. *Fertil Steril* 2010;94:1858-63.
 19. He H, Guo H, Han J, Wu Y, Zhu F. An atresia cervix removal, lower uterine segment substitute for cervix and uterovaginal anastomosis: a case report and literature review. *Arch Gynecol Obstet* 2015;291:93-7.
 20. Ga H, Taguchi A, Honjoh H, Nishijima A, Eguchi S, Miyamoto Y, Sone K, Mori M, Osuga Y. Prognosis of patients with endometrial cancer or atypical endometrial hyperplasia after complete remission with fertility-sparing therapy. *Arch Gynecol Obstet* 2023;308:1629-34.
 21. Committee on Adolescent Health C. ACOG Committee Opinion No. 728: Mullerian Agenesis: Diagnosis, Management, And Treatment. *Obstet Gynecol* 2018;131:e35-e42.
 22. Fujimoto VY, Miller JH, Klein NA, Soules MR. Congenital cervical atresia: report of seven cases and review of the literature. *Am J Obstet Gynecol* 1997;177:1419-25.
 23. Zhang X, Qiu J, Ding Y, Sun L, Hua K. Single port laparoscopy combined with vaginal cervicovaginal reconstruction in a patient with congenital atresia of the cervix. *Fertil Steril* 2020;113:681-2.
 24. Madec FX, Sabbagh P, Schirmann A, Morel-Journel N, Neuville P. Genital gender affirming surgery in trans women: Vulvo-vaginoplasty review. *Ann Chir Plast Esthet* 2023;68:468-76.
 25. O'Dwyer C, Kumar S, Wassersug R, Khorrami A, Mukherjee S, Mankowski P, Genoway K, Kavanagh AG. Vaginal self-lubrication following peritoneal, penile inversion, and colonic gender-affirming vaginoplasty: a physiologic, anatomic, and histologic review. *Sex Med Rev* 2023;11:212-23.

Cite this article as: Liu H, Zhang H, Wang C, Dang Q. Efficacy and safety of laparoscopic vaginoplasty with peritoneal flaps and cervicoplasty in patients with congenital cervical and complete vaginal atresia: a pilot study. *Quant Imaging Med Surg* 2024;14(4):3121-3130. doi: 10.21037/qims-23-1226

Table S1 Detailed information of the nine patients with congenital cervical and complete vaginal atresia

Case	Age (years)	Clinical symptom	Uterus size (cm ³) [†]	Endometrium (mm)	Surgical type	Surgical duration (min)	Bleeding volume (mL)	Menstruation, sex life, and pregnancy
1	17	Seasonal abdominal pain for 2 years; amenorrhea	108.5	Absent	Received laparoscopic vaginoplasty with peritoneal flaps + cervicoplasty + bladder injury repair + electrocautery for endometriosis	250	50	Normal menstrual cycle, reported satisfaction with sex life, multiple miscarriages
2	15	Seasonal abdominal pain for 5 months; amenorrhea	90.3	Absent	Transvaginal amniotic vaginoplasty, with the vaginal mold removed 1 year after. Experienced amenorrhea with lower abdominal discomfort 6 months after. After 2 years, received laparoscopic vaginoplasty with peritoneal flaps + cervicoplasty + rectal injury neoplasty	257	200	Normal menstrual cycle, reported satisfaction with sex life, not yet pregnant
3	18	Abdominal pain for 3 days; pelvic mass	60.5	Absent	Received laparoscopic vaginoplasty with peritoneal flaps + cervicoplasty + right hydrosalpinx excision + right ovarian sac excision + greater omentum adhesion separation	230	110	Normal menstrual cycle, reported satisfaction with sex life, not yet pregnant
4	14	Intermittent abdominal pain for 1 year; amenorrhea	79.1	Absent	Received transvaginal amniotic vaginoplasty. Presented with amenorrhea with lower abdominal discomfort 1 year after. After 1 year, received laparoscopic vaginoplasty with peritoneal flaps + cervicoplasty	250	230	Normal menstrual cycle, not yet pregnant
5	28	Intermittent abdominal pain for 8 years; amenorrhea	51.9	Absent	Received laparoscopic vaginoplasty with peritoneal flaps + cervicoplasty + right tubal forming + pelvic adhesion separation	270	300	Normal menstrual cycle, reported satisfaction with sex life, not yet pregnant
6	14	Intermittent abdominal pain for 1 year; amenorrhea	17.9	4	Received laparoscopic vaginoplasty with peritoneal flaps + cervicoplasty + electrocautery for endometriosis	182	80	Abnormal menstrual cycle with continuous menstruation, not yet pregnant
7	11	Seasonal abdominal pain for 3 months; pelvic mass	48.0	5	Received laparoscopic vaginoplasty with peritoneal flaps + cervicoplasty + excision of the left oviduct mesangial cyst + great omentum adhesion separation	161	100	Normal menstrual cycle, not yet pregnant
8	12	Intermittent abdominal pain concurrent with dysuria for 3 days	17.9	3	Received laparoscopic vaginoplasty with peritoneal flaps + cervicoplasty	105	100	Normal menstrual cycle, not yet pregnant
9	21	Seasonal abdominal pain for 5 years; amenorrhea	54.0	6	Received laparoscopic vaginoplasty with peritoneal flaps + cervicoplasty + removal of right ovarian endometriosis cyst + electrocautery for endometriosis	205	50	Normal menstrual cycle, reported satisfaction with sex life, not yet pregnant

[†], uterus size was calculated using the formula: uterus size = length × width × height × π/6.