

**Reviewer A**

Use of these alternative “non-monofilament” metallic sutures and the preference for “as short as possible” Nuss bars could play an important role to avoid such types of complications.

Since Nuss procedure was described and developed, indications for this technique expanded from paediatric to older patients. Indeed further modifications allowed minimal invasive correction to more complicated thoracic defects. Rapidly we observed that the Achilles Tendon of such techniques were the proposed Nuss bar(s) fixation methods; it was not unusual to read reviews about Nuss bars displacement and many surgeons involved with such procedures reported about different types of complications (1). One of the most frequent described complications, occurs when stainless wires we used for fixation like pointed in the article of.....et al.

The majority of actual available surgical sets include lateral stabilizers to avoid medial Nuss bar fixation to the surrounding ribs. Lately there is a trend towards the use of shorter bars for Pectus Excavatum correction since very lateral placed stabilizers might result in higher Nuss bar displacement (2). Some innovative proposals years ago incorporated at those bars themselves at one of the sides a lateral incorporated stabilizer called stabilizer wing (3). Another proposed maneuver to avoid bar displacement, when several bars are used, is the lateral interconnection of those bars (4).

If no access to such equipment/techniques is possible, there is an accepted trend to fix Nuss bars directly to the surrounding ribs using circumcostal sutures without lateral stabilizers. This is also our method at Vienna Medical University, but to avoid these described complications, we adopted a standard fixation method using a sternal cable system instead of simple stainless wires (5). Such type of cables are sold by different companies and during the last 10 years of use and with over 100 pectus operations in adults with Pectus Excavatum, we saw no one single cable rupture. Very important issue is the previous de-attachment of the lower intercostal bundle to avoid intercostal chronic pain.

**Reply:** We sincerely appreciate your important and detailed suggestion. Just as you said, pectus bar fixation is very important in Nuss procedure. If the bar displacement happens

---

before final removal, it will weaken the correction effect on the sunken chest, and even cause harm to adjacent organs. Therefore, pectus bar fixation technique has been reported a lot, and the most widely recognized one is surgical stainless wire fixation, which has been proved to be effective in several studies. However, the wire may break, even if there are no serious complications in most cases, its potential risk should be highly valued by thoracic surgeons. And the stabilizer wing you mentioned was also applied in our study, while, we are still worried about the displacement of that Nuss system. Therefore, the holes at the upper and lower side of the stabilizer wing were penetrated by the stainless wire to be fixed to the nearby ribs. Later, we found that the total incidence of wire fracture was high, but the fracture of wires in different positions were of great difference. Most of the wire fractures occurred between 6-12 months after operation. In addition, we found that the bar was surrounded by hard fibrous tissues in operation, which was reported to be formed 4-6 months after the operation. Therefore, we tried to replace part of the wires with PDS sutures (with the absorption time of 120-180 days) and cancel the unnecessary wires. These improvements were proved to be effective in our latter practice, and the trouble of wire fracture was avoided without any bar displacement. You mentioned the “lateral interconnection of several bars”, which is indeed a safe and effective method to fix Nuss system. We will further research and make full use of its advantages in clinical practice. In addition, since this study focused on children with “Park I” pectus excavation, fixation techniques were only stabilizer and wire / PDS fixation. We are very interested in the "sternal cable system" that you introduced. Further researchers may help us reconstruct asymmetric and more severe pectus excavatum. Sincere thanks for your kind and useful suggestions, and we have modified our text as advised.

**Changes in the text:** Page 3, Line 75-77, Page 10, Line 266-271,

#### **Reviewer B**

This paper describes the detail of the wire fracture and how to avoid both wire fracture and bar displacement. I suggest some points:

1. The purpose of this research should be placed in the abstract.

**Reply:** We sincerely appreciate your important and detailed suggestion, which is very useful and necessary. Considering the limitation of the word count in “Abstract”, we simplified the existing “Background” part and added some expositions about the

---

purpose of the article.

**Changes in the text:** Page 2, Line 59-64.

2. It seems that the parts of the results placed in the introduction part. These results were written in the results part twice.

**Reply:** Thank you for your valuable comments. We have indeed ignored the repetition of the content here. We have modified our text as advised.

**Changes in the text:** Page 3, Line 85-101.

3. If the morphological classification of pectus excavatum is not known widely, show the reference (1.3. Diagnostic criteria).

**Reply:** Thank you very much for your kind suggestions and we are sorry for our flaws. It's true that we should add some references about the morphological classification of pectus excavatum to make the article more traceable.

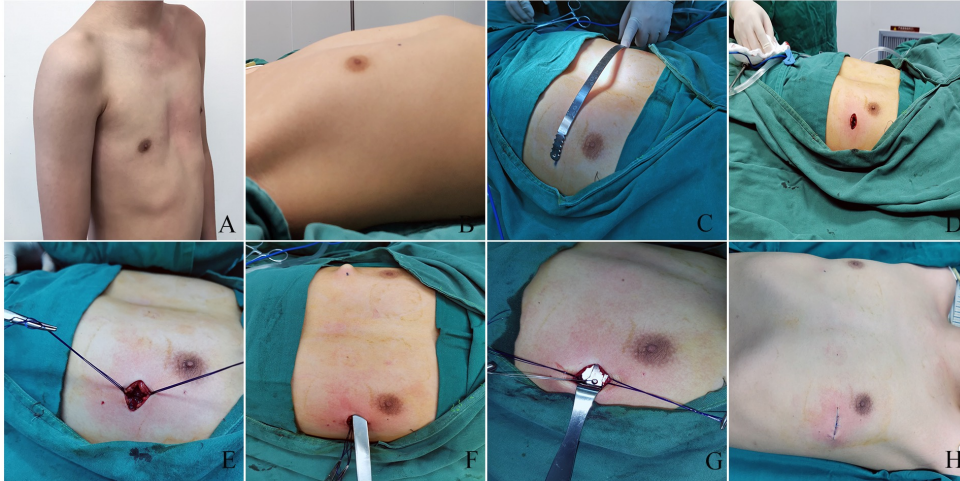
**Changes in the text:** Page 5, Line 132. The numbers of citations and references were also revised accordingly.

4. You mentioned that the introducer was pulled back without crossing the chest wall on the right side. Is that true? In figure 1b, the right edge of the bar was placed on the right rib. If this surgical technique means the single-incision procedure, is this your original modified Nuss procedure?

**Reply:** Thank you for giving us the opportunity to introduce our modified Nuss procedure in detail. As far as we know, the modified Nuss procedure mentioned in this article is our original method, and we'd like to introduce another figure of our surgical technique, see the figure below. Figure A-B showed the pectus excavatum in supine and standing position. Figure C showed the pre-bending of the pectus bar before implantation. Figure D showed the unilateral incision (left). In Figure E, we implanted the stabilizer in advance and passed PDS sutures on the upper and lower ribs. Figure F presented the tunnel construction through a stabilizer (without crossing the chest wall on the right side). Figure G demonstrated that the introducer was withdrawn from the original path and the pectus bar was then inserted; after turning over the bar, the stabilizer was secured to the bar by a surgical stainless wire, and the upper and lower side of the stabilizer were secured to adjacent rib respectively. The Figure H showed

---

the immediate effect after the operation. Therefore, this single-incision procedure prevented patients from unnecessary damage and potential wire fracture, achieving satisfactory results. Informed consent for publication of surgery photographs was obtained from the patient and his parents.



**Changes in the text:** Page 5-6, Line 148-153.

5. It is important when these wire fracture occurred during follow-up because authors insisted that the absorbable PDS fixation is effective and the fibrous tissues surrounding the bar prevent to flip the bar after the decrease of the PDS resistance. When is the timing of these wire fractures in 22 patients?

**Reply:** We sincerely appreciate your important and detailed comments, which are very useful. In this study, most patients complied with our follow-up rules and participated in outpatient visits, and the relevant information was recorded in the electronic medical record. However, some patients with poor compliance did not come to outpatient follow-up as required. In these cases, wire fracture was not found until the final admission for plate removal procedure, so the relevant data may not be accurate. We extracted and summarized the records of wire fracture in medical records, and supplemented the description in the paper.

**Changes in the text:** Page 7, Line 185-191; Page 13, Line 399-402.