



Merkel cell carcinoma after liver transplantation: a case report and review of the literature

Hongyan Xin^{1,2#}, Rong Wei^{1#}, Qinghai Ma^{1,3#}, Ni Wang¹, Ang Li⁴, Wenfei Li¹

¹Department of Dermatology, the First Affiliated Hospital of Shandong First Medical University & Shandong Provincial Qianfoshan Hospital, Jinan Clinical Research Center for Tissue Engineering Skin Regeneration and Wound Repair, Jinan, China; ²Department of Cardiac Surgery, Shandong Provincial Public Health Clinical Center & Shandong Chest Hospital, Jinan, China; ³Department of Clinical Laboratory Medicine, the First Affiliated Hospital of Shandong First Medical University & Shandong Provincial Qianfoshan Hospital, Shandong Medicine and Health Key Laboratory of Laboratory Medicine, Jinan, China; ⁴Department of Orthopaedic Surgery, Shanghai Jiao Tong University Affiliated Sixth People's Hospital, Shanghai, China

[#]These authors contributed equally to this work.

Correspondence to: Wenfei Li. Department of Dermatology, the First Affiliated Hospital of Shandong First Medical University, Shandong Provincial Qianfoshan Hospital, 16766 Jing-Shi Road, Jinan 250014, China. Email: lwf888026@163.com.

Abstract: Merkel cell carcinoma is a rare type of highly aggressive cutaneous malignant neuroendocrine tumor. The incidence of Merkel cell carcinomas is higher in organ transplant recipients than healthy controls. There are some reports of Merkel cell carcinomas after kidney transplantation, but few reports of Merkel cell carcinomas after liver transplantation are available. We present a 64-year-old Chinese woman with an asymptomatic nodule on her right tibia 6 years after liver transplantation. The nodule appeared as a purulent scab on the surface and measured 2.4×2.5 cm in diameter. Histopathologic and immunohistochemistry examinations confirmed the nodule to be a Merkel cell carcinoma. No residual Merkel cell carcinoma was detected at the surgical margins after surgical resection. No metastases were detected in a sentinel lymph node biopsy specimen. The wound was suctioned with negative pressure. The patient had an uneventful recovery and was discharged 16 days after surgery. Then, she underwent postsurgical adjuvant radiotherapy. No relapse was observed for approximately 24 months of follow-up. Merkel cell carcinoma may severely impact health, especially among transplant recipients. Immunosuppressants that must be administered after transplantation can increase the risk of Merkel cell carcinoma and physicians should be aware of Merkel cell carcinomas occurring in liver transplant recipients.

Keywords: Merkel cell carcinoma; liver transplantation; histopathology; immunohistochemistry; surgery

Submitted Dec 13, 2020. Accepted for publication Mar 15, 2021.

doi: 10.21037/apm-20-2483

View this article at: <http://dx.doi.org/10.21037/apm-20-2483>

Introduction

Merkel cell carcinoma (MCC) is a rare and aggressive skin tumor that usually occurs in areas exposed to the sun. The most significant characteristics of MCC are summarized in the acronym, AEIOU (asymptomatic/lack of tenderness, expanding rapidly, immune suppression, older than 50 years, and ultraviolet-exposed site on a person with fair skin) (1). There are three subtypes of MCC: palisade, solid, and diffuse. The solid type is the most common, while the

diffuse type has the worst prognosis. Local and regional lymph node metastases can occur in the early stage, and distant metastases appear as the disease progresses.

MCC is also known as a neuroendocrine carcinoma that originates in the skin because of the presence of neuroendocrine particles in the tumor cytoplasm. MCCs have unique immunohistochemical staining characteristics. Among skin-derived tumors, MCC has the highest case fatality rate. The administration of immunosuppressive agents after liver transplantation increases the incidence

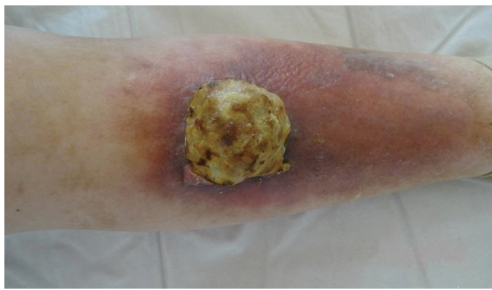

Figure 1 Lesions on the right tibia. A nodule, 2.4×2.5 cm in diameter, with scattered ulcers, a purulent scab, and a light-yellow discharge was surrounded by slightly swollen and red-brown patches on the right tibia.

of skin cancer. An MCC in a liver transplant recipient was first reported by Esen *et al.* in 2005, and to the best of our knowledge, there are only four patients with MCC after liver transplantation described in the English literature (2-5). Indeed, this is the first case of MCC after liver transplantation reported in the English literature involving a Chinese patient.

We report herein a case of MCC in a 64-year-old female who underwent liver transplantation. The diagnosis of an MCC was establishing based on clinical, histopathologic evaluation and immunohistochemistry. She was treated with surgery and adjuvant radiotherapy. We present the following case in accordance with the CARE reporting checklist. Available at: <http://dx.doi.org/10.21037/apm-20-2483>.

Case presentation

A 64-year-old Chinese female with a history of liver transplantation presented to our clinic for evaluation of an asymptomatic nodule on her right tibia. She complained of a pink, painless, non-pruritic nodule on her right tibia 4 months ago that did not improve following the application of ointment. The nodule gradually increased in size, rupture occasionally, and scabs appeared on the surface. Two weeks later, the nodule enlarged rapidly, and the surrounding skin was slightly swollen. She was a worker and lived in a city. She had potential exposure to dust. She was diagnosed with cirrhosis 20 years ago and underwent the liver transplantation 6 years ago. The patient continued treatment with single-agent tacrolimus (4.0 mg daily) after surgery, and there was no apparent discomfort. Her family members were in good health. There were no apparent nutritional deficiencies. She did not have a family history of

viral hepatitis.

The physical examination showed the right tibia to be slightly swollen with red-brown patches. The nodule was 2.4×2.5 cm in diameter, with scattered ulcers, a purulent scab, and a light-yellow discharge on the surface (Figure 1). There was a surgical scar on the abdomen consistent with the liver transplantation. An electrocardiogram and chest X-ray indicated no cardiac or pulmonary, respectively. There was no evidence of local or distant metastases on computed tomography scans.

After admission, the nodule was biopsied. The histopathologic findings were as follows: the surface of the tumor tissue was eroded; and small round, blue-stained cells infiltrated the subcutaneous nodules, which were diffusely distributed (H&E ×50, Figure 2A). The cell morphology was consistent with decreased cytoplasm, a round nucleus, and numerous mitotic images (H&E ×200, Figure 2B). Immunohistochemistry showed CK20-, CD56-, and Syn-positive staining (×200, Figure 3A,B,C, respectively), and the Ki-67-positive index was 40% (×200, Figure 3D). The diagnosis of a MCC was made.

Preoperative preparation, local infiltration anesthesia, surgical resection, and lymphatic mapping with a sentinel lymph node biopsy were performed. A skin graft was placed. No residual MCC was detected at the surgical margins. No metastases were detected in the sentinel lymph node. The MCC was stage IIa (T₂ N₀ M₀) based on AJCC consensus guidelines (6). The wound was suctioned with negative pressure. She had an uneventful recovery and was discharged 16 days after surgery. Then, she underwent postsurgical adjuvant radiotherapy (five times per week for 4 weeks). No relapse was observed during approximately 24 months of follow-up. The patient continues to have follow-up evaluations.

All procedures performed in studies involving human participants were in accordance with the ethical standards of the institutional and/or national research committee(s) and with the Helsinki Declaration (as revised in 2013). The patient and his legal guardian provided informed written consent for publication of this study and any accompanying images during the treatment.

Discussion

With the improvement and maturity of liver transplantation technology, more and more patients undergo liver transplantation; however, immunosuppressants must be administered after transplantation, which can increase

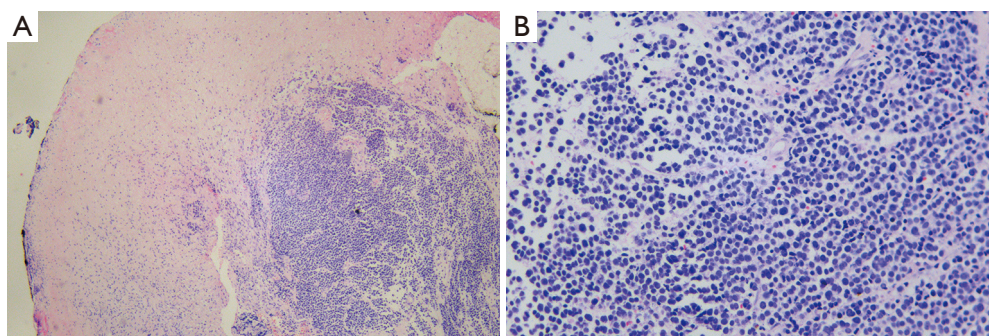


Figure 2 Histopathologic manifestations of MCC. The surface of the tumor tissue was eroded, and small, round, blue-stained cells infiltrated the subcutaneous nodules, which were diffusely distributed (A). The cell morphology was consistent, the cytoplasm was decreased, the nucleus was round, and there were numerous mitotic images (B). Hematoxylin and eosin staining: (A) $\times 50$; (B) $\times 200$. MCC, Merkel cell carcinoma.

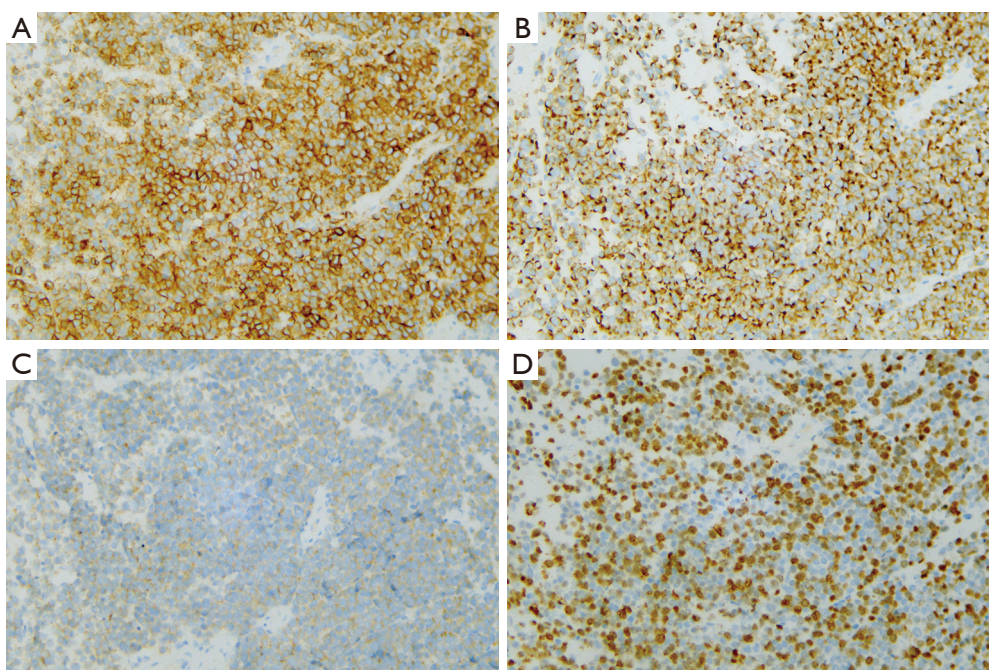


Figure 3 Immunohistochemical examination. The immunohistochemical examination showed CK20-, CD56-, and Syn-positive staining ($\times 200$), and the Ki-67 positive index was 40% ($\times 200$). (A: CK20, B: CD56, C: Syn, D: Ki67).

the risk of various skin cancers, such as squamous cell carcinoma, basal cell carcinoma, Kaposi sarcoma, malignant melanoma, and MCC (7). Only four patients with MCC after liver transplantation have been described in the English literature, as listed on PubMed. Esen *et al.* (2) reported a 25-year-old female with a small, non-tender nodule on the second finger of her right hand 4 years after liver transplantation. The results of histopathologic

examination were consistent with an MCC. In 2007, Bensaleh *et al.* (3) reported a 69-year-old man who developed an MCC on his forehead 6.5 years after liver transplantation; the MCC recurred 6 months after surgical resection. Another patient was a 55-year-old Caucasian man who noticed a subcutaneous cyst-like nodule on the right femur 3 years after liver transplantation. The nodule was confirmed to be an MCC by histopathologic analysis (4).

Table 1 Comparison of published cases of Merkel cell carcinoma after liver transplantation in PubMed's English literature

Case	Author	Age (year)/ gender	Time (year) (after LP)	Size (cm)	Location	Treatment	Prognosis
1	Esen <i>et al.</i> 2005	25/F	4	A small erythematous, firm, nontender nodule	The second finger of her right hand	Surgery, radicalization	In good health
2	Bensaleh <i>et al.</i> 2007	69/M	6	2×1 cm firm erythematous nodule	forehead	Surgery, radicalization	Die of severe sepsis
3	Bajetta <i>et al.</i> 2007	55/M	3	2 cm painless, firm, subcutaneous cyst-like nodule	The upper part of his right leg	Surgery, radicalization	No evidence of relapse
4	Obioha <i>et al.</i> 2017	67/F	6	4 cm red-violaceous, painless, dome-shaped tumor; 8 cm pink papulonodule, painless plaque	Left buttock; left hip	Chemotherapy	Died within 8 months of diagnosis

LP, liver transplantation.

In 2017, Obioha *et al.* (5) reported a 67-year-old woman who developed multiple metastatic MCC 6 years after liver transplantation. The clinical features of these patients are listed in *Table 1*. A MCC after transplantation is rare, but we will be vigilant in the future to collect additional cases.

The pathogenesis of MCC is unclear, although studies suggest that Merkel cell polyomavirus (MCPyV) is the putative etiologic agent in the carcinogenesis of MCC. The occurrence of MCC is related to risk factors, such as ultraviolet light exposure, immunosuppression, and advanced age (8). The incidence of MCC in elderly people who have chronic exposure to ultraviolet radiation is increased because ultraviolet radiation can induce mutations in numerous genes (9) and may promote the virus integration necessary for virus-induced transformation. Other risk factors include organ transplantation, previous malignant tumors, HIV infection, and the use of immunosuppressants. Although an HLA antigen mismatch can reduce the risk of skin cancer after solid organ transplantation (10), some studies have shown that MCCs occur more frequently in patients receiving immunosuppressive therapy, especially among organ transplant recipients (11,12).

Our patients had liver failure due to autoimmune hepatitis and subsequently underwent a liver transplantation. Before the liver transplantation, the dermatologist performed a skin examination using standard procedures and deemed the skin to be normal. A mass appeared on her right tibia 6 years after liver transplantation, which

was confirmed to be MCC by clinical, histopathologic examination, and immunohistochemical staining. Due to limited resources, we did not test this patient for MCPyV. The risk factors for MCC in our patient may be related to the use immunosuppressive agents after liver transplantation.

With respect to the treatment of MCC, different methods can be selected according to the MCC stage. These methods include surgery, radiotherapy, and chemotherapy. In addition, biological agents, such as avelumab, an anti-programmed cell death ligand 1 antibody, have been approved for the treatment of MCC (13). A balanced diet rich in antioxidants may be beneficial for patients with MCC. Among the different methods, surgery is the first-line therapy (14). The marginal area should not only be clean when surgically removed but should also be 2–3 cm away from the tumor. In addition, whole-body CT scanning is an important method for detecting the presence or absence of distant metastases. Because occult nodal metastasis is common in patients with MCCs (26%) (15), lymphoscintigraphy and a sentinel lymph node biopsy are of great value to assess lymph node metastases. In addition, pathologic lymph node evaluation is important for staging (16). Even if there are no lymph node metastases, radiotherapy can reduce local recurrence at the surgical incision and improve the prognosis (17). Chemotherapy is generally favored for patients with lymph node metastases but has not been shown to improve survival (18). We performed surgery and radiotherapy, and the patient was

very satisfied with the treatment effect.

Conclusions

MCC may severely impact health, especially among transplant recipients. Immunosuppressants, which must be administered after transplantation, can increase the risk of MCC. Thus, physicians should be aware of MCC occurring in liver transplant recipients.

Acknowledgments

We would like to thank Dr. Guangcun Liu in the First Affiliated Hospital of Shandong First Medical University, Shandong Provincial Qianfoshan Hospital for his help. We also thank International Science Editing (<http://www.internationalscienceediting.com>) for editing this manuscript.

Funding: None.

Footnote

Reporting Checklist: The authors have completed the CARE reporting checklist. Available at: <http://dx.doi.org/10.21037/apm-20-2483>

Conflicts of Interest: All authors have completed the ICMJE uniform disclosure form (available at: <http://dx.doi.org/10.21037/apm-20-2483>). The authors have no conflicts of interest to declare.

Ethical Statement: The authors are accountable for all aspects of the work in ensuring that questions related to the accuracy or integrity of any part of the work are appropriately investigated and resolved. All procedures performed in studies involving human participants were in accordance with the ethical standards of the institutional and/or national research committee(s) and with the Helsinki Declaration (as revised in 2013). The patient and his legal guardian provided informed written consent for publication of this study and any accompanying images during the treatment.

Open Access Statement: This is an Open Access article distributed in accordance with the Creative Commons Attribution-NonCommercial-NoDerivs 4.0 International License (CC BY-NC-ND 4.0), which permits the non-commercial replication and distribution of the article with

the strict proviso that no changes or edits are made and the original work is properly cited (including links to both the formal publication through the relevant DOI and the license). See: <https://creativecommons.org/licenses/by-nc-nd/4.0/>.

References

1. Heath M, Jaimes N, Lemos B, et al. Clinical characteristics of Merkel cell carcinoma at diagnosis in 195 patients: the AEIOU features. *J Am Acad Dermatol* 2008;58:375-81.
2. Esen BA, Pinarbasi B, Buyukbabani N, et al. Merkel-cell carcinoma arising after liver transplantation: a case report. *Transplant Proc* 2005;37:4413-5.
3. Bensaleh H, Perney P, Dereure O, et al. Merkel cell carcinoma in a liver transplant patient. *Am J Clin Dermatol* 2007;8:239-41.
4. Bajetta E, Platania M, Catena L, et al. Merkel cell carcinoma after liver transplantation: a case report. *Tumori* 2007;93:323-6.
5. Obioha J, Miller S. Aggressive Merkel cell carcinoma in a liver transplant recipient. *Cutis* 2017;100:103;104;124.
6. Kelly L Harms, Mark A Healy, Paul Nghiem, et al. Analysis of Prognostic Factors From 9387 Merkel Cell Carcinoma Cases Forms the Basis for the New 8th Edition AJCC Staging System. *Ann Surg Oncol* 2016; 23:3564-71.
7. Mittal A, Colegio OR. Skin Cancers in Organ Transplant Recipients. *Am J Transplant* 2017;17:2509-30.
8. Schadendorf D, Lebbé C, Zur Hausen A, et al. Merkel cell carcinoma: Epidemiology, prognosis, therapy and unmet medical needs. *Eur J Cancer* 2017;71:53-69.
9. Moll I. Merkel-cell carcinoma. *Pathologe* 2019;40:350-4.
10. Gao Y, Twigg AR, Hirose R, et al. Association of HLA Antigen Mismatch With Risk of Developing Skin Cancer After Solid-Organ Transplant. *JAMA Dermatol* 2019;155:307-14.
11. Koljonen V, Sahi H, Böhling T, et al. Post-transplant Merkel Cell Carcinoma. *Acta Derm Venereol* 2016;96:442-7.
12. Clarke CA, Robbins HA, Tatalovich Z, et al. Risk of merkel cell carcinoma after solid organ transplantation. *J Natl Cancer Inst* 2015;107:dju382.
13. Cardis MA, Jiang H, Strauss J, et al. Diffuse lichen planus-like keratoses and clinical pseudo-progression associated with avelumab treatment for Merkel cell carcinoma, a case report. *BMC Cancer* 2019;19:539.
14. Becker JC, Stang A, DeCaprio JA, et al. Merkel cell carcinoma. *Nat Rev Dis Primers* 2017;3:17077.
15. Sims JR, Grotz TE, Pockaj BA, et al. Sentinel lymph

- node biopsy in Merkel cell carcinoma: The Mayo Clinic experience of 150 patients. *Surg Oncol* 2018;27:11-7.
16. Woo KJ, Choi YL, Jung HS, et al. Merkel Cell Carcinoma: Our Experience with Seven Patients in Korea and a Literature Review. *J Plast Reconstr Aesthet Surg* 2010;63:2064-70.
17. Cassler NM, Merrill D, Bichakjian CK, et al. Merkel Cell Carcinoma Therapeutic Update. *Curr Treat Options Oncol* 2016;17:36.
18. Tello TL, Coggs K, Yom SS, et al. Merkel cell carcinoma: An update and review: Current and future therapy. *J Am Acad Dermatol* 2018;78:445-54.

Cite this article as: Xin H, Wei R, Ma Q, Wang N, Li A, Li W. Merkel cell carcinoma after liver transplantation: a case report and review of the literature. *Ann Palliat Med* 2021;10(7):8425-8430. doi: 10.21037/apm-20-2483