



A case report of acute simultaneous cardiocerebral infarction: possible pathophysiology

Xiaoli Wang¹, Quanye Li¹, Yao Wang², Yang Zhao¹, Shucheng Zhou¹, Zhouyu Luo¹, Mingzhong Gu¹

¹Department of Emergency, Affiliated Yancheng Hospital, School of Medicine, Nanjing Medical University, Yancheng, China; ²Department of Hematology, Affiliated Nantong Hospital, Nantong University, Nantong, China

Correspondence to: Mingzhong Gu. Department of Emergency, Affiliated Yancheng Hospital, School of Medicine, Nanjing Medical University, Yancheng 224300, China. Email: 491180993@qq.com.

Abstract: The occurrence of acute myocardial infarction (AMI) accompanied by ischemic cerebrovascular accidents has rarely been reported in previous articles. In this report, we present a 72-year-old female patient with massive cerebral infarction secondary to acute anterior and high lateral wall myocardial infarction, finally resulting in a deep coma. The patient ultimately failed to respond to aggressive resuscitation and succumbed to cardiogenic shock and fatal ventricular arrhythmias. We consider that the co-occurrence of these diseases is more than just a coincidence, and that there may be a connection between them. In this article, we performed an in-depth exploration and discussion of the explanation of this phenomenon. It is essential to recognize these situations in the early stages, which determines the follow-up treatment and prognosis. We suggest that decisions regarding patient management should be based on hemodynamic stability, close cardiac monitoring, and the site of cerebral infarction, and also emphasize that the evaluation of hemodynamic status in these patients is a prerequisite for deciding whether to treat the cerebral or coronary infarction first. The present report is written for the purpose of reminding readers of this rare and severe situation, and to emphasize the necessity for further research on how to deal with it best.

Keywords: Case Report; cardiocerebral infarction; acute ischemic cerebral stroke; acute myocardial infarction (AMI); management; prognosis

Submitted Mar 09, 2021. Accepted for publication May 17, 2021.

doi: 10.21037/apm-21-808

View this article at: <http://dx.doi.org/10.21037/apm-21-808>

Introduction

Acute ischemic stroke (AIS) and acute myocardial infarction (AMI) are both medical emergency conditions with a narrow therapeutic time window, and require early diagnosis and intervention. Previous studies have shown that AIS is associated with an increased risk of AMI, and vice versa (1,2). However, the co-occurrence of AIS and AMI combined with bilateral internal carotid artery occlusion has been rarely reported. We aimed to analyze the pathogenesis of this phenomenon in detail through the following case report. We present the following article in accordance with the CARE reporting checklist (available at <http://dx.doi.org/10.21037/apm-21-808>).

Case presentation

The patient was a 72-year-old female who was taken to the emergency department with sudden unconsciousness and numbness in his limbs for more than 1 hour. She had lived alone and her daughter discovered her lying in the room unconscious. Therefore, the accurate time of the event was unclear. Her medical history included hypertension and atrial fibrillation, and she had taken irregular medication and his blood pressure was unmonitored.

Clinical examination revealed a blood pressure of 161/88 mmHg without a significant difference between bilateral upper extremities, and an irregular pulse at 68 beats per minute. Cardiac examination revealed irregular

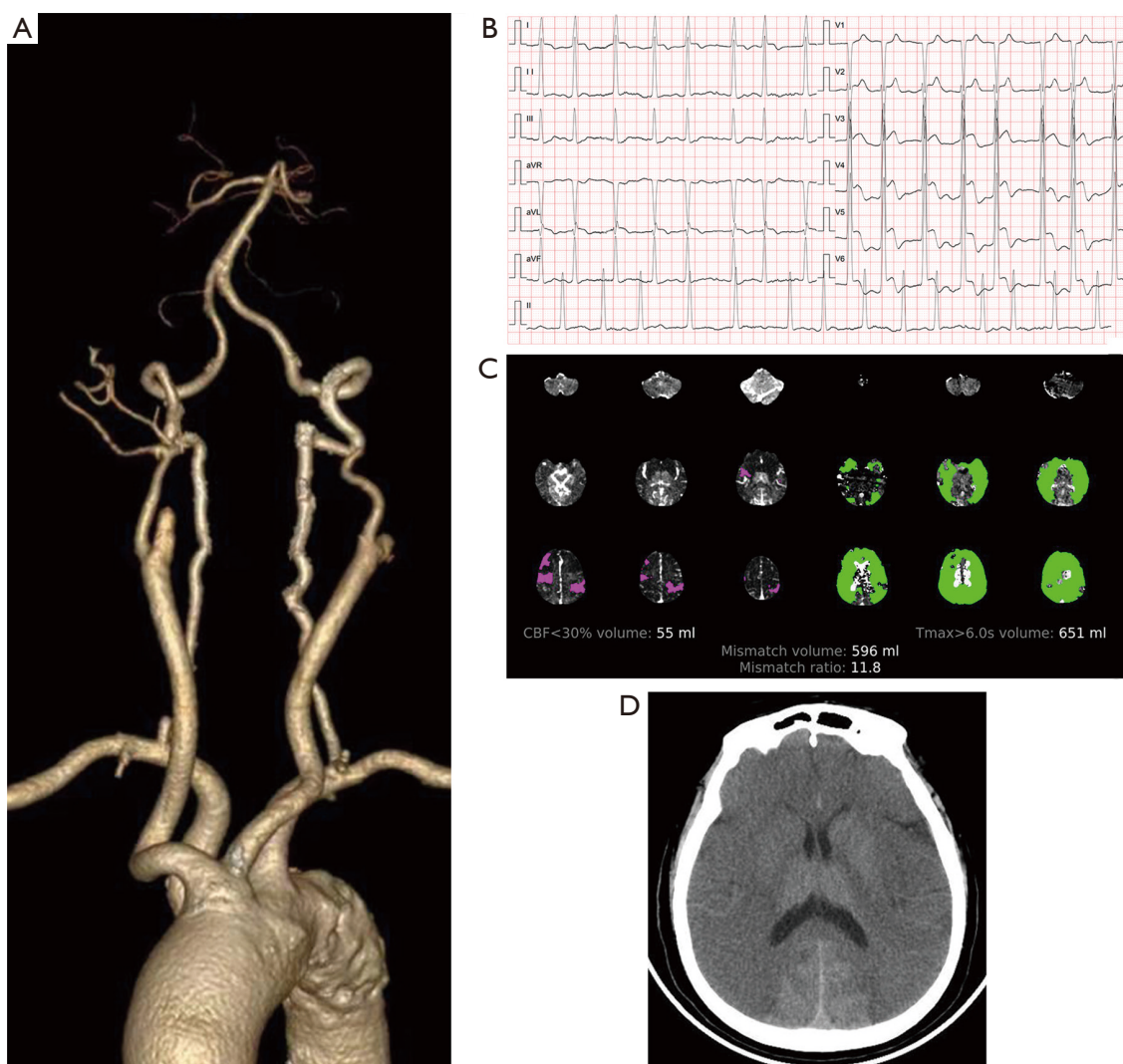


Figure 1 Computed tomography (CT) and electrocardiographic findings from illustrative case (A) The computed tomography angiogram (CTA) showed bilateral internal carotid artery occlusion and possible bilateral cerebral hemisphere infarction; (B) the CT perfusion (CTP) imaging of the skull displayed CT perfusion (CTP) less than 30%, volume of 55 mL, Tmax faster than 6.0 s, and mismatch volume of 596 mL; (C) twelve-lead electrocardiography showed atrial fibrillation with a heart rate of 83 beats/min and ST-segment elevation at I, aVL, and V2–V6; (D) the cranial CT image showed no intracranial hemorrhages.

heart sounds but no murmurs or pericardial rub, and the lungs were clear. On neurologic examination, the patient fell into a deep coma with a GCS of 5/15 and extremely small pupils which were slowly reactive to light. She showed global aphasia and bilateral paralysis. Her forehead wrinkles and nasolabial folds were symmetrical. Her limb muscle strength was grade 0, her muscle tone was decreased, and the Babinski sign was negative on both sides.

The results of a biochemical blood test on arrival were as follows: white blood cell count, $29.08 \times 10^9/L$; hemoglobin,

15.2 g/dL; platelet count, $147 \times 10^9/L$; total protein, 61 g/dL; alanine aminotransferase, 105.5 U/L; blood urea nitrogen, 11.18 mmol/L; creatinine, 117.2 $\mu\text{mol/L}$; sodium, 136.5 mg/L; potassium, 3.60 mg/L; troponin T, 7.39 $\mu\text{g/L}$; prothrombin time, 12.7 s; activated partial thromboplastin time, 25.9 s; fibrinogen, 73.8 mg/L; and D-dimer, 17.21 mg/L.

The results of a computed tomography (CT) angiogram showed bilateral internal carotid artery occlusion and possible bilateral cerebral hemisphere infarction (Figure 1A). The CT perfusion imaging of the skull displayed CTP

less than 30%, volume of 55 mL, Tmax faster than 6.0 s, and mismatch volume of 596 mL (Figure 1B). Twelve-lead electrocardiography showed atrial fibrillation with a heart rate of 83 beats/min and ST elevation at I, avL, and V2–V6 (Figure 1C). The cranial CT image showed no intracranial hemorrhages (Figure 1D). Diagnosis showed acute cerebral stroke, acute anterior and high lateral wall myocardial infarction, bilateral internal carotid artery occlusion, and atrial fibrillation. We used atorvastatin to stabilize the plaque, edaravone to clear free radicals, oxiracetam to support nerves, and dextran to dilate the vasculature and improve microcirculation. The patient went into cardiac arrest before being given rtPA. The electrocardiograph showed that pulse-free electrical activity alternated with ventricular fibrillation in the process of cardiopulmonary resuscitation (CPR). The patient ultimately failed to respond to aggressive resuscitation and succumbed to cardiogenic shock and fatal ventricular arrhythmias.

The study protocol was approved by the Ethics Committee of the Affiliated Yancheng Hospital, School of Medicine, Southeast University. All procedures performed in studies involving human participants were in accordance with the ethical standards of the institutional and national research committees and with the Helsinki Declaration (as revised in 2013). Written informed consent was obtained from the patient.

Discussion

In 2010, cardiocerebral infarction (CCI) was described by Omar *et al.* (3), who used it to define the co-occurrence of AIS and AMI. They suggested that there might be a possible but rare link between the 2 diseases, rather than just a coincidence leading to the occurrence of CCI.

When investigating such cases, the following questions should be considered: Which problem is more serious, cerebral infarction or heart disease? Is the heart disease caused by a brain lesion or by a primary cardiac lesion? It is essential to recognize these situations in the early stages, which determines the follow-up treatment and prognosis.

There are 3 possible pathophysiological mechanisms of simultaneous CCI:

- (I) Atrial fibrillation is a common source of cerebral embolism and coronary embolism, and has been reported as the cause of simultaneous cardiac and cerebral infarction (4,5). In this case, the patient had prior atrial fibrillation, it is possible to such condition, but this patient had bilateral internal carotid artery occlusion.
- (II) Cardiac conditions could lead to cerebral infarction. AMI, especially in the anterior wall and apex of the heart, weakens the systolic function of the left ventricle and provides a pathophysiological basis for the formation of left ventricular mural thrombus (6). Severely underpowered myocardium in the left ventricle increases the risk of thrombosis (7,8), which can embolize both the coronary and cerebral arteries. The subsequent severe hypotension due to AMI can also contribute to hemodynamic stroke (3,9). In patients with AMI and a long history of hypertension, sudden hemodynamic compromise may lead to a decrease in cerebral blood flow to perfuse the brain, which results in infarction, especially when automatic regulation of blood pressure fails (3). Therefore, we concluded that the patient in this case had this condition.
- (III) Brain-heart axis disorder or cerebral infarction can lead to myocardial infarction. Injuries to the left insular lobe of the brain can impair the balance of the sympathetic vagus nerve and eventually lead to arrhythmias and abnormal wall movement, as well as disorders in diurnal blood pressure variation (10). Similarly, the adrenergic surge associated with AIS may lead to catecholamine-induced cardiac shock, a common cause of stress cardiomyopathy, which is called Takotsubo syndrome.

On the other hand, CCI is also an unusual disease associated with an increased risk of mortality, which creates a management challenge for our clinical physicians. For both AMI, particularly STEMI, and AIS, the time window for treatment is limited, and delayed intervention from one infarct area to another may result in permanent and irreversible morbidity or disability, or even death. Antiplatelet therapy (11), GPIIa/IIIb inhibitors (12), and anticoagulants (13) for interventional treatment of coronary heart disease such as AMI (14) increase the risk of thrombolytic-associated hemorrhagic conversion of AIS, and the use of thrombolysis in AIS raises the risks of cardiac wall rupture at the base of the AMI. The ideal therapeutic strategy for CCI benefits both vascular territories.

In summary, we suggest that decisions regarding patient management should be based on hemodynamic stability, close cardiac monitoring, and the site of cerebral infarction. We also emphasize that the evaluation of hemodynamic status in these patients is a prerequisite for deciding whether to treat the cerebral or coronary infarction first.

Acknowledgments

Funding: None.

Footnote

Reporting Checklist: The authors have completed the CARE reporting checklist. Available at <http://dx.doi.org/10.21037/apm-21-808>

Conflicts of Interest: All authors have completed the ICMJE uniform disclosure form (available at <http://dx.doi.org/10.21037/apm-21-808>). The authors have no conflicts of interest to declare.

Ethical Statement: The authors are accountable for all aspects of the work in ensuring that questions related to the accuracy or integrity of any part of the work are appropriately investigated and resolved. The study protocol was approved by the Ethics Committee of the Affiliated Yancheng Hospital, School of Medicine, Southeast University. All procedures performed in studies involving human participants were in accordance with the ethical standards of the institutional and national research committees and with the Helsinki Declaration (as revised in 2013). Written informed consent was obtained from the patient.

Open Access Statement: This is an Open Access article distributed in accordance with the Creative Commons Attribution-NonCommercial-NoDerivs 4.0 International License (CC BY-NC-ND 4.0), which permits the non-commercial replication and distribution of the article with the strict proviso that no changes or edits are made and the original work is properly cited (including links to both the formal publication through the relevant DOI and the license). See: <https://creativecommons.org/licenses/by-nc-nd/4.0/>.

References

1. Gunnoo T, Hasan N, Khan MS, et al. Quantifying the risk of heart disease following acute ischaemic stroke: a meta-analysis of over 50,000 participants. *BMJ Open* 2016;6:e009535.
2. Witt BJ, Ballman KV, Brown RD Jr, et al. The incidence of stroke after myocardial infarction: a meta-analysis. *Am J Med* 2006;119:354.e1-3549.
3. Omar HR, Fathy A, Rashad R, et al. Concomitant acute right ventricular infarction and ischemic cerebrovascular stroke; possible explanations. *Int Arch Med* 2010;3:25.
4. Tokuda K, Shindo S, Yamada K, et al. Acute Embolic Cerebral Infarction and Coronary Artery Embolism in a Patient with Atrial Fibrillation Caused by Similar Thrombi. *J Stroke Cerebrovasc Dis* 2016;25:1797-9.
5. Kim HL, Seo JB, Chung WY, et al. Simultaneously Presented Acute Ischemic Stroke and Non-ST Elevation Myocardial Infarction in a Patient with Paroxysmal Atrial Fibrillation. *Korean Circ J* 2013;43:766-9.
6. Gianstefani S, Douiri A, Delithanasis I, et al. Incidence and predictors of early left ventricular thrombus after ST-elevation myocardial infarction in the contemporary era of primary percutaneous coronary intervention. *Am J Cardiol* 2014;113:1111-6.
7. Loh E, Sutton MS, Wun CC, et al. Ventricular dysfunction and the risk of stroke after myocardial infarction. *N Engl J Med* 1997;336:251-7.
8. Warsz-Wianecka A, Mizia-Stec K, Lasek-Bal A, et al. Segmental left ventricular hypokinesis is associated with embolic signals in transcranial Doppler. *Pol Arch Med Wewn* 2012;122:531-6.
9. Yeo LLL, Andersson T, Yee KW, et al. Synchronous cardiocerebral infarction in the era of endovascular therapy: which to treat first? *J Thromb Thrombolysis* 2017;44:104-11.
10. Nagai M, Hoshida S, Kario K. The insular cortex and cardiovascular system: a new insight into the brain-heart axis. *J Am Soc Hypertens* 2010;4:174-82.
11. Lee M, Saver JL, Hong KS, et al. Risk-benefit profile of long-term dual- versus single-antiplatelet therapy among patients with ischemic stroke: a systematic review and meta-analysis. *Ann Intern Med* 2013;159:463-70.
12. Ciccone A, Abraha I, Santilli I. Glycoprotein IIb-IIIa inhibitors for acute ischaemic stroke. *Cochrane Database Syst Rev* 2006;(4):CD005208.
13. Sandercock PA, Counsell C, Kane EJ. Anticoagulants for acute ischaemic stroke. *Cochrane Database Syst Rev* 2015;2015:CD000024.
14. Patel MR, Meine TJ, Lindblad L, et al. Cardiac tamponade in the fibrinolytic era: analysis of >100,000 patients with ST-segment elevation myocardial infarction. *Am Heart J* 2006;151:316-22.

Cite this article as: Wang X, Li Q, Wang Y, Zhao Y, Zhou S, Luo Z, Gu M. A case report of acute simultaneous cardiocerebral infarction: possible pathophysiology. *Ann Palliat Med* 2021;10(5):5887-5890. doi: 10.21037/apm-21-808