



A systematic review and meta-analysis on transcranial Doppler in diagnosing ischemic cerebrovascular disease

Jieqing Zhou¹, Yu Shan², Pan Hu³

¹Pediatrics Department, The First Hospital of China Medical University, Shenyang, China; ²The First Department of Internal Medicine, School of Medicine, University of Occupational and Environmental Health, Fukuoka, Japan; ³Neurology Department, The First Hospital of China Medical University, Shenyang, China

Contributions: (I) Conception and design: J Zhou, P Hu; (II) Administrative support: J Zhou; (III) Provision of study materials or patients: J Zhou, P Hu; (IV) Collection and assembly of data: All authors; (V) Data analysis and interpretation: All authors; (VI) Manuscript writing: All authors; (VII) Final approval of manuscript: All authors.

Correspondence to: Pan Hu. Neurology Department, The First Hospital of China Medical University, 155 North Nanjing Street, Heping District, Shenyang 110001, China. Email: hupan718@126.com.

Background: The incidence of ischemic cerebrovascular disease (ICVD) has been increasing, leading to disability and deaths among middle-aged and elderly people. Digital subtraction angiography (DSA) is the gold standard for diagnosing ICVD, but it is invasive, expensive, and complex to operate. Transcranial Doppler (TCD) ultrasound is characterized by high accuracy, simplicity, and low cost, and thus became the focus of this study.

Methods: The databases of PubMed, Web of Science, Embase, and The Cochrane Library were searched from January 2000 to September 2020, for literature involving the use of TCD to diagnose ICVD. The software RevMan 5.3 was used for quality assessment, and forest plots and summary receiver operating characteristic (SROC) curves were drawn. The software STATA12.0 was adopted for publication bias analysis.

Results: A total of 11 references were included, and the combined sensitivity, specificity, and 95% confidence interval (CI) of TCD were 0.93 (0.75 to 1.00) and 0.95 (0.78 to 1.00), respectively. The area under the curve (AUC) of SROC was 0.887.

Discussion: Superb capabilities in diagnosing ICVD have been demonstrated by TCD, and it should therefore be applied in the clinic. The results are important to realize early diagnosis of ICVD and improve the prognosis of patients.

Keywords: Ischemic cerebrovascular disease (ICVD); transcranial doppler (TCD); diagnostic value; meta-analysis

Submitted Jun 09, 2021. Accepted for publication Jul 26, 2021.

doi: 10.21037/apm-21-1759

View this article at: <https://dx.doi.org/10.21037/apm-21-1759>

Introduction

Statistics have shown that the mortality rate of ischemic cerebrovascular disease (ICVD) is approximately 20%, and about 55% experience varying degrees of disability (1,2). The incidence of vascular cerebrovascular disease (ICVD) is basically around one in 100,000. In some areas it is even higher, as high as 7 per 100,000. Early diagnosis of ICVD is required to improve prognosis and reduce

the mortality rate. Intracranial artery stenosis arises from atherosclerotic plaque, vasospasm, vasculitis, and so on (3,4). Atherosclerosis is also an important causative factor of ischemic stroke and emergency vascular occlusion (5). Correct diagnosis is a prerequisite for stratifying disease risks, formulating treatment plans, and reducing treatment risks.

Digital subtraction angiography (DSA) is a new X-ray imaging system, which combines conventional angiography

with computer image processing. Digital subtraction angiography (DSA) is the gold standard for the diagnosis of ICVD (6); however, it is invasive, costly, and there are certain risks in its clinical application, so it has not been clinically popularized. In addition, computed tomography angiography (CTA), magnetic resonance angiography (MRA), and transcranial Doppler (TCD) are also widely used in the clinical diagnosis of cerebrovascular diseases (7,8). Among them, TCD is relatively cheap, non-invasive, and easy to operate. It can determine the timing of reperfusion by continuously monitoring micro-embolic signals, so it is widely used in the diagnosis of cardiovascular and cerebrovascular diseases (9). Studies have shown that the diagnostic rate of TCD for cerebrovascular diseases is as high as 80% (10). However, few studies have systematically evaluated its performance in diagnosing ICVD.

Based on this, we collected studies conducted in China and internationally on the use of TCD to diagnose ICVD, and conducted a meta-analysis, aiming to determine the value of TCD in the diagnosis of ICVD, expecting to provide a reference for lifting its clinical diagnosis rate.

We present the following article in accordance with the PRISMA reporting checklist (available at <https://dx.doi.org/10.21037/apm-21-1759>).

Methods

Literature retrieval

The databases of PubMed, Web of Science, Embase, and The Cochrane Library were searched from January 2000 to September 2020, with “transcranial”, “carotid stenosis”, “stroke”, “ischemic”, “cerebrovascular”, “diagnosis”, “sensitivity”, and “specificity” as search terms.

Inclusion and exclusion criteria

The studies were selected according to the following inclusion criteria: (I) published international and Chinese literature on applying TCD in the diagnosis of ICVD; (II) diagnostic efficiency data could be obtained directly or indirectly; (III) literature containing at least 10 samples; and (IV) with DSA, CTA, or MRA as the diagnostic gold standard.

The exclusion criteria were as follows: (I) literature with duplicate data; (II) review, conference report, experience lecture, individual case report, and commentary research; (III) literature irrelevant to the subject of this research; (IV)

literature with unclear diagnostic criteria; and (V) unclear reporting of outcome indicators.

Literature quality assessment

The software RevMan 5.3 (Copenhagen: The Nordic Cochrane Center, The Cochrane Collaboration, 2014) and the Quality Assessment of Diagnostic Accuracy Studies (QUADAS) were used by 2 researchers to evaluate the quality of included literature. Any inconsistencies were resolved through discussion or arbitration by a third expert.

The QUADAS contains a total of 16 items judged using “Yes”, “No” and “Unclear”, where “Yes” means conforming to the standard, “No” means non-compliance with the standard, and “Unclear” is selected when the information is not comprehensive or partially meets the standard. Using RevMan 5.3 to evaluate the quality of literature involves quality assessment via the following aspects: (I) whether it is a randomized controlled trial (RCT); (II) whether an allocation concealment is used; (III) whether a blind method is used; (IV) whether the data is complete; (V) the presence of selective reporting; and (VI) whether there are other biases.

Data extraction

The following data was collated: (I) first author; (II) year of publication; (III) research type; (IV) gold standard; and (V) diagnosis results. The diagnosis results had to include the number of true positives (TP), number of false positives (FP), number of false negatives (FN), and number of true negatives (TN).

Statistics

The software RevMan 5.3 was used to analyze the risk bias of the included literature. The summary receiver operating characteristic (SROC) curve was used for diagnostic analysis. When the model was consistent, the SROC curve showed a shoulder-shape distribution, or the sensitivity and specificity were negatively correlated, and $P < 0.05$. Analysis of variance was conducted to check the consistency of the results, and $\alpha = 0.1$. When $I^2 < 50\%$ and $P > 0.05$, it was considered that there was no heterogeneity in the study, so the fixed effects model was used for statistical analysis; when $I^2 > 50\%$ and $P < 0.05$, it was considered that the study was heterogeneous, and the random effects model was used for statistical analysis. After the corresponding SROC curve was drawn, the area under the curve (AUC) was calculated

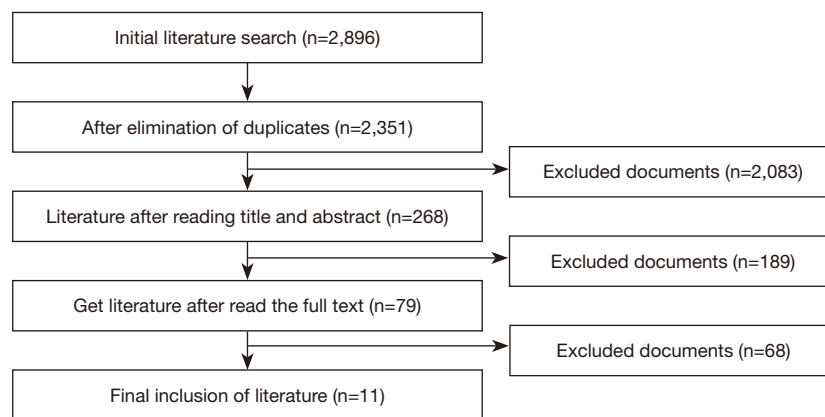


Figure 1 The literature retrieval process.

Table 1 Basic information of included literature

First author	Year	TP	FP	FN	TN	Gold standard
Bar (11)	2010	22	2	0	7	CTA
Brunser (12)	2009	30	4	3	63	CTA
Brunser (13)	2020	30	4	7	60	CTA
Guan (14)	2013	35	1	0	92	CTA
Hou (15)	2009	27	7	10	34	DSA
Kamel (16)	2010	19	2	2	7	MRA
Martinez-Sanchez (17)	2015	59	0	0	6	CTA
Panbianco (18)	2016	7	0	0	18	CTA
Roubec (19)	2011	23	23	3	416	DSA
Sharma (20)	2007	27	9	7	109	CTA/DSA
Tsivgoulis (21)	2007	34	5	9	84	CTA

CTA, computed tomography angiography; MRA, magnetic resonance angiography; DSA, digital subtraction angiography; TP, true positive; FP, false positive; TN, true negative; FN, false negative.

to determine the diagnostic value. An AUC of 0.5–0.7 was considered a low diagnosis rate; an AUC of 0.7–0.9 was considered a medium diagnosis rate; and an AUC of 0.9–1.0 was considered a high diagnostic rate. The Deek funnel chart in Stata 12.0 (StataCorp., College Station, TX, USA) was used to analyze the publication bias of the included literature, and $P < 0.05$ was the threshold for significance.

Results

The basic information of the included literature

Initially, a total of 2,896 references were identified. After

exclusion of duplicates, 2,351 remained. After reading the abstract and title, 268 references were retained. After further reading of the full text, 11 references were finally included (11–21). The literature retrieval process is depicted in *Figure 1*, and the basic information of the included literature is shown in *Table 1*.

Bias risk assessment

First, the RevMan software (version 5.3) provided by the Cochrane System was used to evaluate the quality of the included literature. As shown in *Figures 2* and *3*, “Patient

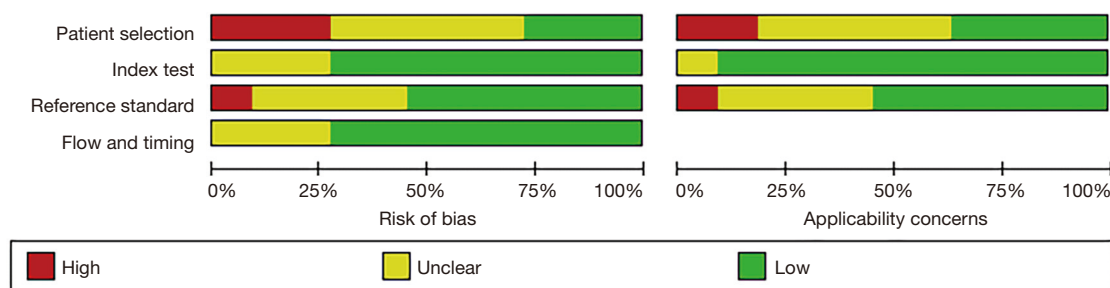


Figure 2 Bar chart showing the bias risk of the included literature.

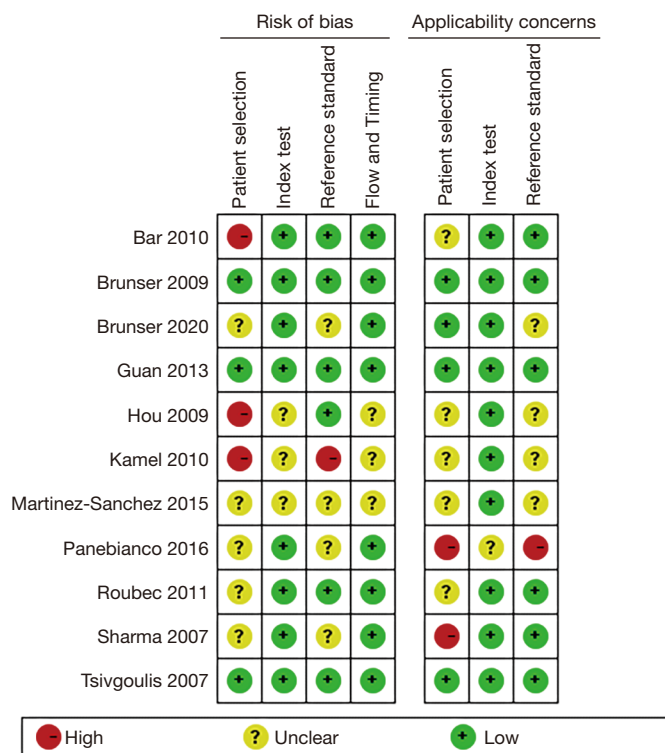

Figure 3 Summary chart of risk bias of included literature.

selection” in the study by Bar *et al.* showed high risk bias and “unclear” applicability concerns (11). The “Patient selection” showed high risk bias in the studies of Hou *et al.* and Karmel *et al.* (15,16). The “Patient selection” and “Reference standard” in the study by Panebianco *et al.* (18) both showed high applicability concerns. The “Patient selection” of the study by Sharma *et al.* showed high applicability concerns (20). Overall, the 11 included studies showed low risk bias and low applicability concerns, indicating that they met the analysis requirements.

The QUADAS tool was used to evaluate the quality of included literature, and the results are shown in *Table 2*. It was noted that the 11 references included in the study all showed low risk bias, meeting the subsequent analysis requirements.

Meta-analysis results

As shown in *Figure 4*, the estimated sensitivity of TCD in diagnosing ICVD was 0.73 to 1.00, and the specificity was

Table 2 The bias risk assessment of the included literature

First author	Year	1	2	3	4	5	6	7	8	9	10	11	12	13	14
Bar	2010	Y	Y	Y	U	Y	Y	Y	Y	Y	Y	U	Y	Y	Y
Brunser	2009	Y	Y	Y	U	Y	Y	Y	Y	Y	Y	U	Y	Y	Y
Brunser	2020	Y	Y	Y	U	Y	Y	Y	Y	Y	Y	U	Y	Y	Y
Guan	2013	Y	Y	Y	U	Y	Y	Y	Y	Y	U	U	Y	Y	Y
Hou	2009	Y	Y	Y	U	Y	Y	Y	Y	Y	Y	U	Y	Y	Y
Kamel	2010	Y	Y	Y	U	Y	Y	Y	Y	Y	Y	U	Y	Y	Y
Martinez-Sanchez	2015	Y	Y	Y	U	Y	Y	Y	Y	Y	U	U	Y	Y	Y
Panebianco	2016	Y	Y	Y	U	Y	Y	Y	Y	Y	Y	U	Y	Y	Y
Roubec	2011	Y	Y	Y	U	Y	Y	Y	Y	Y	Y	U	Y	Y	Y
Sharma	2007	Y	Y	Y	U	Y	Y	Y	Y	Y	Y	U	Y	Y	Y
Tsigvoulis	2007	Y	Y	Y	U	Y	Y	Y	Y	Y	Y	U	Y	Y	Y

1–14 are items of QUADAS. Y, yes; U, unclear; QUADAS, Quality Assessment of Diagnostic Accuracy Studies.

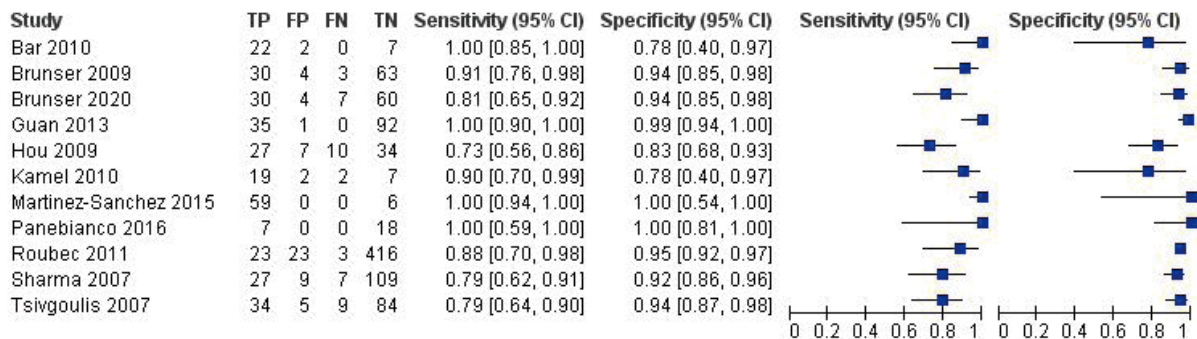


Figure 4 Forest plot showing the efficiency of TCD in diagnosing ICVD. TCD, transcranial Doppler; ICVD, ischemic cerebrovascular disease; CI, confidence interval.

0.78 to 1.00.

The bivariate model results are shown in *Figure 5*. It was noted that the combined estimated sensitivity of different studies was 0.93 [95% confidence interval (CI): 0.75 to 1.00], and the combined estimated specificity was 0.95 (95% CI: 0.78 to 1.00). The AUC under the SROC was 0.887.

The Deek funnel chart was drawn using the software Stata12.0 to analyze publication bias of the included literature, and the results are shown in *Figure 6*. It was noted that the included studies were evenly distributed on both sides of the regression line, indicating that there was no obvious publication bias in the included literature (P=0.366).

Discussion

Cerebrovascular disease is the third highest cause of human deaths, among which the ICVD is the most threatening (22). Patients with ICVD have an increased risk of paralysis, and are prone to cerebral perfusion, and vasculature or cerebrovascular accidents (23). Statistics show that about 85% of CVD patients present ischemic features, that is, interruption of blood flow to different areas of the brain (24). As per the Trial of ORG 10172 in Acute Stroke Treatment (TOAST) classification standard, ICVD can be divided into 4 categories, namely, macrovascular atherosclerosis, lacunar infarction, cardiac embolic stroke, and cryptogenic stroke (25). Studies have

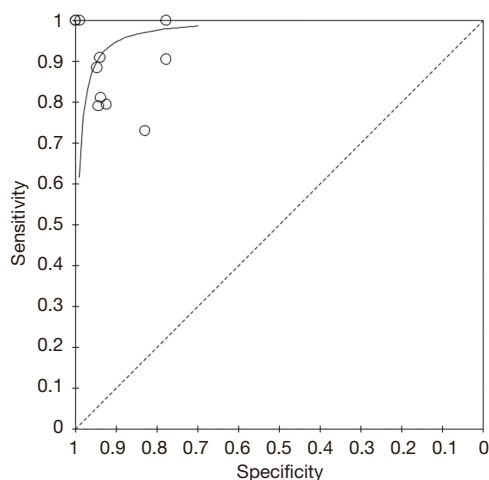


Figure 5 The SROC curve of TCD in diagnosing ICVD. SROC, summary receiver operating characteristic; TCD, transcranial Doppler; ICVD, ischemic cerebrovascular disease.

shown that when a patient develops ICVD, about 2 million neurons die every minute (26). Early diagnosis and timely treatment are necessary to improve the treatment effects and raise the quality of life of patients.

Imaging by CT has gradually been promoted in the diagnosis of cerebrovascular diseases, such as cranial CT imaging, CTA, and DSA (27,28). Among them, DSA is the gold standard for the diagnosis of ICVD, but it is invasive and difficult to operate, so its clinical application is limited (29). Studies have confirmed that CTA imaging can reveal the shape of blood vessels using contrast agents, and thus, is used in the diagnosis of occlusion or stenosis (30,31).

Transcranial Doppler ultrasound imaging technology is a non-invasive inspection method, which can reduce the risk of patients being irradiated. At the same time, transcranial Doppler ultrasound imaging has the advantages of low price, simple operation and superior detection effect (32). Today, transcranial Doppler ultrasound imaging can be used to diagnose cerebral vascular stenosis, occlusion, and spasm (33). And studies have confirmed that the disease has high sensitivity for the diagnosis of cerebrovascular stenosis and occlusion, and the diagnostic specificity can be as high as 80% or more (34). In the diagnosis of acute ischemic stroke, transcranial Doppler ultrasound is an accurate and low-cost diagnostic method, which is widely popular in clinical practice. Studies have shown that compared with CTA detection, the sensitivity and specificity of transcranial Doppler ultrasound for diagnosing arterial occlusion in

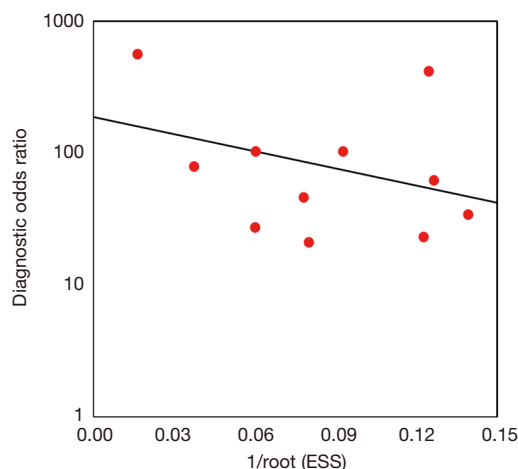


Figure 6 The Deek funnel chart.

patients with ischemic stroke are more than 90% (35,36).

In this study, meta-analysis was conducted to systematically evaluate the value of TCD in diagnosing ICVD. The results showed that the sensitivity and specificity of TCD were 0.93 and 0.95, respectively, and the AUC was 0.887. The AUC of the SROC curve was the index used to evaluate the diagnostic accuracy of a method. The ordinate and abscissa were sensitivity and specificity, respectively, and the diagnostic accuracy increased with the increase of AUC (37), that is, an AUC closer to 1 suggested a higher diagnostic accuracy. When the AUC was greater than 0.9, it was considered high accuracy (38). However, the AUC of the SROC of TCD in diagnosing ICVD was only 0.887, indicating a moderate accuracy rate. This may have arisen from subjective factors, such as the doctor's manipulation, image interpretation experience, and other factors such as hemodynamic changes. Therefore, it is necessary to combine a variety of techniques in the diagnosis of ICVD to lift the diagnosis rate. Limitation of TCD in the diagnosis of ICVD: (I) the inspection skill level of the operator is very high. (II) Due to the anatomical structure and thickness of the skull, 10% of the patients can't be detected through the glume and occipital window, which is more common for the elderly and women, so the blood flow signal of some vessels may not be obtained. (III) Cerebrovascular activity is affected by a variety of factors (PaCo₂, PaO₂, pH, blood pressure, and self-regulation of the cerebrovascular), and some people have physiological variation of the cerebrovascular, which can affect the detection results. (IV) There is still a lot of work to be done to control some diseases, or to study TCD signals with

other means of detection. In addition, accurate noninvasive monitoring with TCD is not possible, and TCD examination, unlike CT and MRI, does not provide direct imaging findings. Despite these limitations, TCD remains the only available non-invasive method for detecting changes in cerebral hemodynamics.

Conclusions

To systematically evaluate the role of TCD in the diagnosis of ICVD, a total of 11 references were included in this meta-analysis. It was found that the sensitivity and specificity of TCD 0.93 (95% CI: 0.75 to 1.00) and 0.95 (95% CI: 0.78 to 1.00), but the AUC of the SROC curve was 0.887, indicating moderate efficiency. However, some limitations should be noted. The number of included references was small, and the effects of TCD combined with other imaging techniques were not discussed. In the follow-up, an expanded size of references is needed, and their quality should be controlled in accordance with the Standards for Reporting of Diagnostic Accuracy Studies (STARD). In conclusion, the results of this study provide a theoretical basis for the application of TCD ultrasound in the diagnosis of ICVD.

Acknowledgments

Funding: None.

Footnote

Reporting Checklist: The authors have completed the PRISMA reporting checklist. Available at <https://dx.doi.org/10.21037/apm-21-1759>

Conflicts of Interest: All authors have completed the ICMJE uniform disclosure form (available at <https://dx.doi.org/10.21037/apm-21-1759>). The authors have no conflicts of interest to declare.

Ethical Statement: The authors are accountable for all aspects of the work in ensuring that questions related to the accuracy or integrity of any part of the work are appropriately investigated and resolved.

Open Access Statement: This is an Open Access article distributed in accordance with the Creative Commons Attribution-NonCommercial-NoDerivs 4.0 International

License (CC BY-NC-ND 4.0), which permits the non-commercial replication and distribution of the article with the strict proviso that no changes or edits are made and the original work is properly cited (including links to both the formal publication through the relevant DOI and the license). See: <https://creativecommons.org/licenses/by-nc-nd/4.0/>.

References

1. Battaglini D, Robba C, Lopes da Silva A, et al. Brain-heart interaction after acute ischemic stroke. *Crit Care* 2020;24:163.
2. Kloner RA, King KS, Harrington MG. No-reflow phenomenon in the heart and brain. *Am J Physiol Heart Circ Physiol* 2018;315:H550-62.
3. Tian B, Liu Q, Wang X, et al. Chronic intracranial artery stenosis: Comparison of whole-brain arterial spin labeling with CT perfusion. *Clin Imaging* 2018;52:252-9.
4. Ozcaglayan O, K TI, Gur DO, et al. Carotid arteries and vertebrobasilary system intracranial stenosis correlates with multi vessel coronary artery disease. *Bratisl Lek Listy* 2019;120:362-7.
5. Zhu Y, Xian X, Wang Z, et al. Research Progress on the Relationship between Atherosclerosis and Inflammation. *Biomolecules* 2018;8:80.
6. Xue J, Peng Y, Zhang Y, et al. Preliminary application of CT perfusion source images for evaluating regional collateral circulation in unilateral Moyamoya disease. *Quant Imaging Med Surg* 2019;9:615-24.
7. Baradaran H, Al-Dasuqi K, Knight-Greenfield A, et al. Association between Carotid Plaque Features on CTA and Cerebrovascular Ischemia: A Systematic Review and Meta-Analysis. *AJNR Am J Neuroradiol* 2017;38:2321-6.
8. Cao R, Qi P, Liu Y, et al. Improving Prognostic Evaluation by 4D CTA for Endovascular Treatment in Acute Ischemic Stroke Patients: A Preliminary Study. *J Stroke Cerebrovasc Dis* 2019;28:1971-8.
9. LaRovere KL. Transcranial Doppler ultrasound in children with stroke and cerebrovascular disorders. *Curr Opin Pediatr* 2015;27:712-8.
10. Finnsdóttir H, Szegedi I, Oláh L, et al. The applications of transcranial Doppler in ischemic stroke. *Ideggyogy Sz* 2020;73:367-78.
11. Bar M, Skoloudík D, Roubec M, et al. Transcranial duplex sonography and CT angiography in acute stroke patients. *J Neuroimaging* 2010;20:240-5.
12. Brunser AM, Lavados PM, Hoppe A, et al. Accuracy of transcranial Doppler compared with CT angiography in

- diagnosing arterial obstructions in acute ischemic strokes. *Stroke* 2009;40:2037-41.
13. Brunser AM, Mazzon E, Muñoz P, et al. Determinants of door to needle time for intravenous thrombolysis in acute ischemic stroke. *Rev Med Chil* 2020;148:1090-5.
 14. Guan J, Zhou Q, Ouyang H, et al. The diagnostic accuracy of TCD for intracranial arterial stenosis/occlusion in patients with acute ischemic stroke: the importance of time interval between detection of TCD and CTA. *Neurol Res* 2013;35:930-6.
 15. Hou WH, Liu X, Duan YY, et al. Evaluation of transcranial color-coded duplex sonography for cerebral artery stenosis or occlusion. *Cerebrovasc Dis* 2009;27:479-84.
 16. Kamel A, Aziz SA, El-Ebyary MM, et al. Ischemic stroke of anterior circulation: sensitivity and prognostic value of early ultrasound and imaging studies. *Egypt J Neurol Psychiatr Neurosurg* 2010;47:303-10.
 17. Martinez-Sanchez P, Garcia-Pastor A, Arenillas-Lara JF, et al. Accuracy of transcranial duplex sonography, compared with CT angiography, for detection of intracranial arterial occlusions in acute stroke. *Int J Stroke* 2015;10:438-77.
 18. Panebianco M, Zavanone C, Perrone P, et al. Transcranial color doppler ultrasonography: the "stethoscope" of vascular neurologist for assessment of medium cerebral artery in acute ischemic stroke patients. Conference proceeding-Congresso Nazionale SNO. 2016.
 19. Roubec M, Kuliha M, Jonszta T, et al. Detection of intracranial arterial stenosis using transcranial color-coded duplex sonography, computed tomographic angiography, and digital subtraction angiography. *J Ultrasound Med* 2011;30:1069-75.
 20. Sharma VK, Tsivgoulis G, Lao AY, et al. Noninvasive detection of diffuse intracranial disease. *Stroke* 2007;38:3175-81.
 21. Tsivgoulis G, Sharma VK, Lao AY, et al. Validation of transcranial Doppler with computed tomography angiography in acute cerebral ischemia. *Stroke* 2007;38:1245-9.
 22. Lee JY, Kim YA, Kim HS, et al. Radiotherapy can increase the risk of ischemic cerebrovascular disease in head and neck cancer patients: A Korean population-based cohort study. *Radiother Oncol* 2020;142:85-91.
 23. Zheng YR, Wu C, Zhang H, et al. Concomitant unruptured intracranial aneurysms and ischemic cerebrovascular diseases: a surgical experience of 31 cases. *Zhonghua Yi Xue Za Zhi* 2017;97:2779-82.
 24. Winship IR. Cerebral collaterals and collateral therapeutics for acute ischemic stroke. *Microcirculation* 2015;22:228-36.
 25. Huang Y, Liao X, Song Z, et al. Evaluation of the Influence of Etiological Factors on the Economic Burden of Ischemic Stroke in Younger Patients in China Using the Trial of Org 10172 in Acute Stroke Treatment (TOAST) Classification. *Med Sci Monit* 2019;25:637-42.
 26. Radak D, Katsiki N, Resanovic I, et al. Apoptosis and Acute Brain Ischemia in Ischemic Stroke. *Curr Vasc Pharmacol* 2017;15:115-22.
 27. Kong Q, Ma X, Wang C, et al. Patients with Acute Ischemic Cerebrovascular Disease with Coronary Artery Stenosis Have More Diffused Cervicocephalic Atherosclerosis. *J Atheroscler Thromb* 2019;26:792-804.
 28. Kronenburg A, Bulder MMM, Bokkers RPH, et al. Cerebrovascular Reactivity Measured with ASL Perfusion MRI, Ivy Sign, and Regional Tissue Vascularization in Moyamoya. *World Neurosurg* 2019;125:e639-50.
 29. Buehler M, Slagowski JM, Mistretta CA, Strother CM, Speidel MA. 4D DSA reconstruction using tomosynthesis projections. *Proc SPIE Int Soc Opt Eng* 2017;10132:101322C.
 30. Kruk M, Wardziak Ł, Demkow M, et al. Workstation-Based Calculation of CTA-Based FFR for Intermediate Stenosis. *JACC Cardiovasc Imaging* 2016;9:690-9.
 31. Saake M, Goelitz P, Struffert T, et al. Comparison of conventional CTA and volume perfusion CTA in evaluation of cerebral arterial vasculature in acute stroke. *AJNR Am J Neuroradiol* 2012;33:2068-73.
 32. Kamal AK, Rehman H, Mustafa N, et al. Diagnostic TCD for intracranial stenosis in acute stroke patients: experience from a tertiary care stroke center in Karachi, Pakistan. *BMC Res Notes* 2015;8:341.
 33. Blanco P, Abdo-Cuza A. Transcranial Doppler ultrasound in neurocritical care. *J Ultrasound* 2018;21:1-16.
 34. Mattioni A, Cenciarelli S, Eusebi P, et al. Transcranial Doppler sonography for detecting stenosis or occlusion of intracranial arteries in people with acute ischaemic stroke. *Cochrane Database Syst Rev* 2020;2:CD010722.
 35. Wardlaw JM, Dennis MS, Merrick MV, et al. Relationship between absolute mean cerebral transit time and absolute mean flow velocity on transcranial Doppler ultrasound after ischemic stroke. *J Neuroimaging* 2002;12:104-11.
 36. Brisson RT, Santos RDSA, Stefano LHSS, et al. Association between Tomographic Characteristics of the Temporal Bone and Transtemporal Window Quality on Transcranial Color Doppler Ultrasound in Patients with Stroke or Transient Ischemic Attack. *Ultrasound Med Biol*

- 2021;47:511-6.
37. Salineiro FCS, Kobayashi-Velasco S, Braga MM, et al. Radiographic diagnosis of root fractures: a systematic review, meta-analyses and sources of heterogeneity. *Dentomaxillofac Radiol* 2017;46:20170400.
38. Zhou J, Gou Z, Wu R, et al. Comparison of PSMA-PET/

CT, choline-PET/CT, NaF-PET/CT, MRI, and bone scintigraphy in the diagnosis of bone metastases in patients with prostate cancer: a systematic review and meta-analysis. *Skeletal Radiol* 2019;48:1915-24.

(English Language Editor: J. Jones)

Cite this article as: Zhou J, Shan Y, Hu P. A systematic review and meta-analysis on transcranial Doppler in diagnosing ischemic cerebrovascular disease. *Ann Palliat Med* 2021;10(8):8963-8971. doi: 10.21037/apm-21-1759