



Reconstruction following periprosthetic joint infection: cemented or uncemented

Nicholas J. Drayer^{1^}, Haines K. Paik¹, Antonia F. Chen^{2^}

¹Department of Orthopaedic Surgery, Madigan Army Medical Center, Tacoma, WA, USA; ²Department of Orthopaedics, Brigham and Women's Hospital, Harvard Medical School, Boston, MA, USA

Contributions: (I) Conception and design: NJ Drayer, AF Chen; (II) Administrative support: HK Paik; (III) Provision of study materials or patients: All authors; (IV) Collection and assembly of data: All authors; (V) Data analysis and interpretation: All authors; (VI) Manuscript writing: All authors; (VII) Final approval of manuscript: All authors.

Correspondence to: Antonia F. Chen, MD/MBA. 75 Francis Street, Boston, MA 02115, USA. Email: afchen@bwh.harvard.edu.

Abstract: Cemented and cementless reconstruction techniques have been widely adopted in primary and aseptic revision total joint arthroplasty (TJA). Many variables influence a surgeon's decision to adopt a particular fixation strategy, and there is no clear consensus on the optimal approach. The literature on periprosthetic joint infection (PJI) has clearly shown the importance of utilizing cement in the first stage of a two-stage exchange arthroplasty in the form of an antibiotic delivery device or temporary spacer. However, very little has been established regarding the importance of fixation method (cemented versus cementless) at the time of definitive replantation and whether this plays a role in the successful eradication of PJI. For the hip, cementless fixation at reimplantation is still the standard of care given modern modular, fluted tapered stems that have high success in the setting of severe bone defects. Hybrid fixation, or cemented femoral components used with uncemented acetabular components, can also be performed when treating PJI especially when performing one-stage exchange arthroplasty, since the antibiotic cement can be used as a delivery device. For knee reimplantation, components are either inserted fully cemented or in a hybrid fashion, where cement is applied to the articular and metaphyseal portions of the bone that is supported by long diaphyseal engaging stems. Cemented stems enable the stress imparted by bone loss to be distributed along the entire length of the construct and can also support reconstructions that may require higher levels of constraint. The objectives of this review are to discuss fixation strategies available to surgeons at the time of the second stage procedure, and to discuss their implications in the success or failure of infection management.

Keywords: Cemented; cementless; total hip arthroplasty; total knee arthroplasty; periprosthetic joint infection (PJI)

Received: 18 April 2020; Accepted: 24 July 2020; Published: 15 October 2021.

doi: 10.21037/aoj-20-74

View this article at: <http://dx.doi.org/10.21037/aoj-20-74>

Introduction

Periprosthetic joint infection (PJI) represents a devastating complication following total joint arthroplasty (TJA) for patients and surgeons alike. The incidence of PJI has been reported in 0.3–2.9% of patients following primary TJA procedures (1,2). The overall burden is expected to continue

increase with an growing number of primary procedures being performed in our aging population (3). Two-stage revision remains the gold-standard for the treatment of PJI, with the primary goal of providing an infection-free and function joint for the patient.

While most surgeons have adopted the two-stage

[^] ORCID: Nicholas J. Drayer, 0000-0003-2629-2876; Antonia F. Chen, 0000-0003-2040-8188.

Table 1 Patients characteristics favoring cemented stems for reimplantation after two-stage exchange arthroplasty

Revision total knee	Revision total hip
Poor diaphyseal bone	Poor diaphyseal bone
Large canal diameter	Large canal diameter
Abnormal distal femoral or proximal tibial bow	Abnormal proximal femoral bow
Sclerotic bone	Irradiated bone

exchange arthroplasty treatment of PJI to include surgical debridement, explantation, and antibiotics, there remains some debate over the reconstruction method utilized at the time of definitive replantation. Components exist that take advantage of both cemented and cementless fixation techniques; however, there is no consensus on which fixation method is superior. This has resulted in a wide variety of reconstruction techniques employed at the second stage and can make interpretation of treatment success very difficult with the degree of heterogeneity present. The actual reconstruction method used is often overlooked, and it is difficult to know the significance it plays in the overall management of PJI. Therefore, the primary objective of this review is to discuss the reconstruction methods used at the time of replantation and whether this has any clinical significance in the successful management of infection.

Cemented prosthesis

Historically, cement is the most prevalent method of primary fixation in arthroplasty procedures. Until the more recent introduction of highly porous metals and press fit technology, cement was the predominant means of implant fixation. Cemented fixation has numerous proven and accepted benefits that have also been adopted in revision surgery and infection management.

First and foremost, cement is beneficial in the management of PJI as a local antibiotic delivery device. Once surgical debridement and implant resection is performed, high doses of antibiotics (often >4 g per 40 g bag of cement) are placed into temporary cement spacers to provide local delivery until replantation. However, medical and mechanical complications related to antibiotics cement have been reported at these higher levels (4). Many surgeons favor cemented fixation at the time of replantation to similarly allow for a local delivery of antibiotics at lower concentrations. Antibiotic supplementation of cement at

concentrations less than 2 g per 40 g bag of cement allow for antibiotic delivery without significant detriment to the mechanical properties of the cement (5). This form of antibiotic delivery has been shown to be medically safe with no increased rate of systemic complications (6,7).

Cement is also frequently employed in the revision setting to help manage bone loss that is often not present at the time of the index procedure. (8). After extensive debridement with resection of diseased and infected bone, and prior instrumentation of the canals, there are greater areas of bone loss specifically in the articular and metaphyseal regions that require extended fixation into the diaphysis based on the zonal concept of fixation depicted in *Figure 1* (9).

Several patient physiologic characteristics favor cemented fixation (9-11). These include poor diaphyseal bone stock and large canal diameter, and in patients with canal geometry that does not allow for adequate press fit. The use of cement in patients with poor bone stock helps to mitigate risk of iatrogenic fracture, perforation or stem pain. While most modern implants have slotted or fluted stem designs, larger diameter stems are known to be a risk factor fracture or stem pain, and patients who have weaker, osteoporotic bone may still have a modulus mismatch at the transition between the tip of the stem and their native bone. Patients with profound bowing in either the coronal or sagittal plane may not be candidates for diaphyseal press-fit stems that may perforate the cortex, even when using modern implants with a variety of stem offset options. This should be identified when templating on preoperative long leg alignment radiographs. Characteristics favoring cemented stem fixation are summarized in *Table 1*.

Cementless fixation

Cementless techniques have been increasingly adopted in primary hip and knee reconstruction; and as such, there has been increasing utilization in revision surgery and second stage reconstruction for PJI. In general, cementless fixation works by obtaining primary stability of the implants. Hoop stresses stabilize the implants enough to allow for early mobilization and weight bearing, while surface architecture allows for bony in-growth and on-growth for long term stability. Metaphyseal sleeves and cones can be added to increase fixation and fill bony voids.

Cementless fixation has been widely adopted in revision hip surgery to include infection management. The significantly enhanced survivorship with acetabular

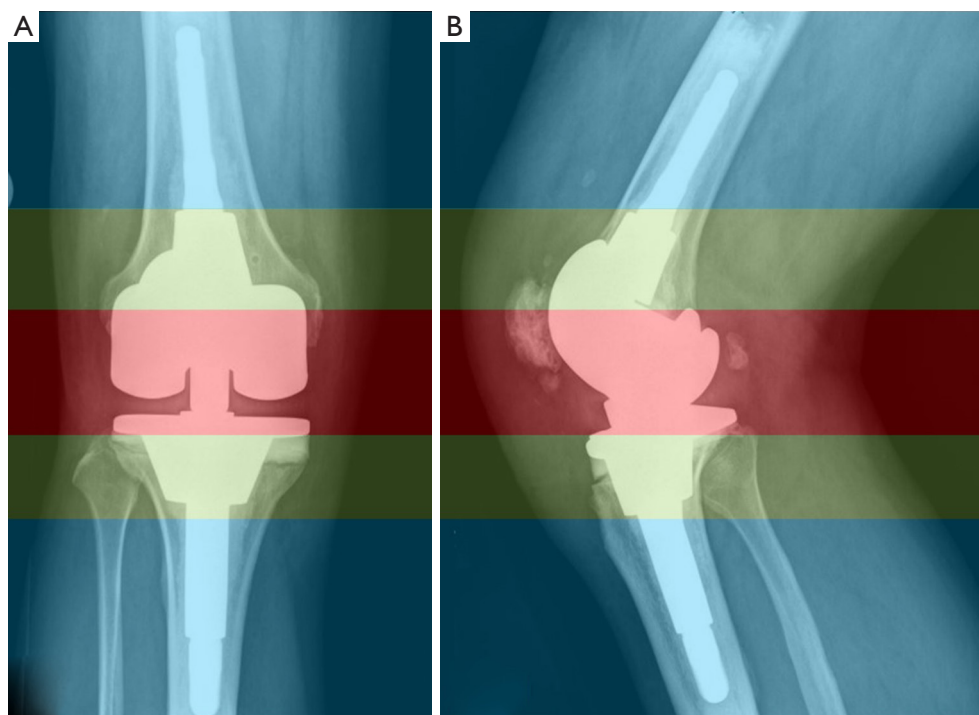


Figure 1 Concept of zonal fixation adapted from Morgan-Jones et al original description. Fixation zones are divided into articular (red), metaphyseal (green), and diaphyseal (blue) (9).

Table 2 Patients characteristics favoring cementless stems for reimplantation after two-stage exchange arthroplasty

Revision total knee	Revision total hip
Normal quality diaphyseal bone	Normal quality diaphyseal bone
Normal canal geometry that allows press fit	Normal canal geometry
Periprosthetic fracture	Periprosthetic proximal femoral fracture
	Trochanteric osteotomy

reconstruction has led to the use of cementless reconstruction even in patients with severe bone defects (12). Modular fluted tapered stems have also shown significantly improved survivorship when used in severe femoral bone defects with an intact diaphysis of less than 4 cm with the added benefit of increased flexibility to adjust length, offset and anteversion (13,14). Cementless fixation techniques in the knee are typically employed in a hybrid fashion, where cementless diaphyseal stems are utilized in conjunction with cemented articular fixation with or without the use of metaphyseal cones and sleeves.

Cementless fixation is preferred in patients with good diaphyseal bone stock and favorable osseous geometry (9-11). Patients with associated periprosthetic fracture also benefit from cementless fixation, as it allows the component to bypass the fracture site to achieve stability. Cementless fixation is also ideal in patients with sclerotic bone from pre-existing bone loss and instrumentation that would otherwise prohibit cement interdigitation. Patient factors favoring cementless stem fixation are summarized in *Table 2*.

Hip specific outcomes after reimplantation

In revision hip surgery, there has been more widespread adoption of cementless fixation with a concomitant increase in utilization for primary hip surgery. It is well established that uncemented acetabular devices have a long track record of achieving reliable ingrowth and providing long-term component fixation in both the primary and revision setting (15,16). In femoral component fixation, initial design techniques evolved as an extension from primary cemented THA. However, early mechanical failure of cemented femoral components in aseptic revision reported in 1980s led the development of extensively porous-coated, mono-

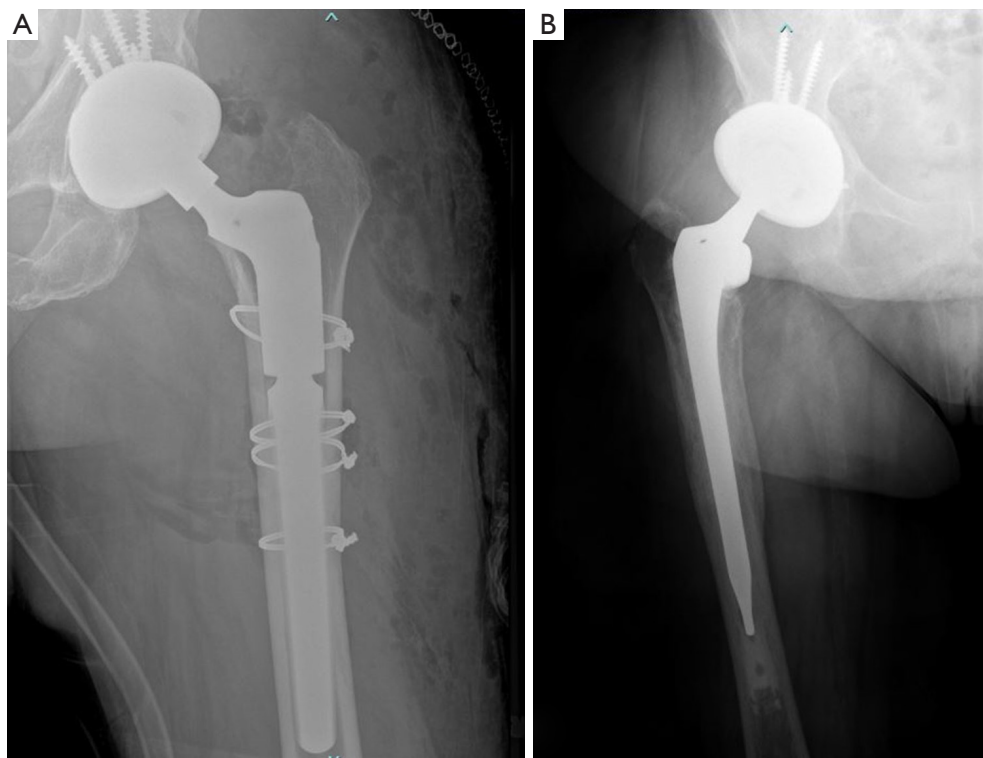


Figure 2 Depiction of cementless fixation in revision total hip arthroplasty (A) and hybrid fixation with a cementless acetabular component and cemented femoral component (B).

block, cementless revision femoral stems that allowed for stable fixation into intact bone (17-19). These designs evolved into cylindrical stems and modern modular, fluted tapered stems that have shown high success even in the setting of severe bone defects as is shown in *Figure 2A*. The flexibility and modularity afforded by these types of implant systems help to address weaknesses inherent in cemented stem design (13,20). It can be very challenging to restore length and offset with a deficient or absent metaphyseal region, even with modular build-up or restoration of the calcar region. This has led to a diminished role for cement in revision total hip arthroplasty, including during reimplantation.

Utilizing this strategy, several authors have reported low 2-year re-infection rates following two-stage exchange arthroplasty with cementless fixation at reimplantation (21-23). A study by Romano *et al.* prospectively followed a cohort of 19 patients with 20 infected total hip arthroplasties treated with two-stage revision and cementless reimplantation implants with only a single recurrent infection (23). Masri *et al.* retrospectively analyzed 29 PJI patients treated with two-stage exchange arthroplasty

with final cementless components and reported a 10.3% re-infection rate. Of the 3 patients who got re-infected, one was able to be managed with intravenous antibiotic therapy alone, another was treated with irrigation and debridement followed by a course of antibiotics, and the third required resection arthroplasty (22). Kraay *et al.* evaluated 33 patients treated for infected THA with two-stage revision utilizing cementless fixation at reimplantation and found no re-infections in the 28 patients who reached 2 year follow-up (21).

Hybrid fixation, or cemented femoral components used with uncemented acetabular components similar to the construct shown in *Figure 2B*, may still play a role in select patients (24-27). Hybrid fixation in the aseptic revision setting has been shown to have 88–91% 10-year survival rate when used in patients who are older than 60 years of age, and those with lower baseline activity levels (24,26). Hybrid fixation may also have a role in select patients when one-stage revision is attempted for PJI treatment, in order to allow for more local delivery of antibiotics. This strategy should be reserved for patients with good local tissue, who are healthy hosts, and are known to be infected by low

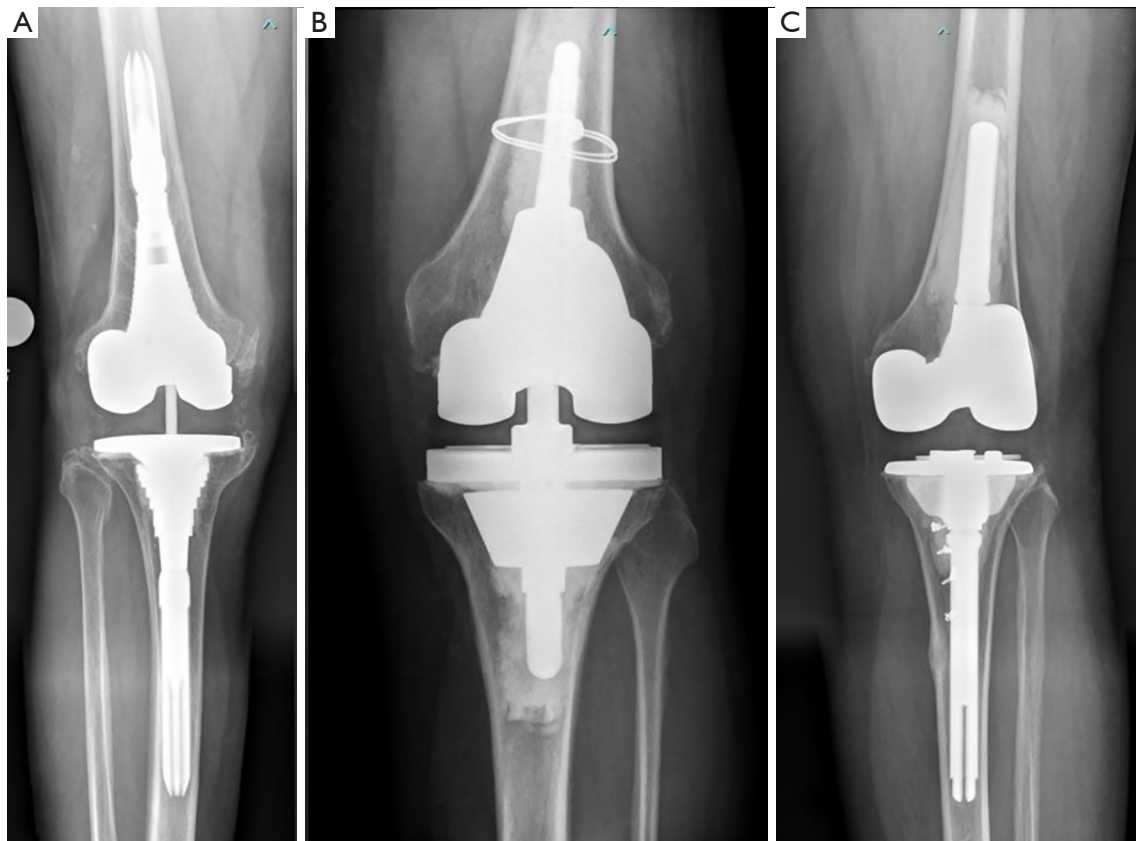


Figure 3 Different types of fixation in revision total knee arthroplasty. Depiction of revision total knee arthroplasty fixation utilizing hybrid fixation (A), with cementless stem and cemented articular component, and cemented fixation (B). The final image demonstrates a reconstruction using a combination of a cemented femoral component and a hybrid tibial component (C).

virulence organisms (28,29). Zahar *et al.* reported on 10-year outcomes in 85 hip PJI patients treated with one-stage exchange arthroplasty with hybrid component fixation. They reported a 10-year infection-free survival of 94% with 75.9% surgery free survival (29). Ilchmann *et al.* also reported their outcomes of 39 PJI hips in 38 patients who underwent one-stage exchange arthroplasty utilizing hybrid fixation (30). They reported no persistent, recurrent or new infection at minimum of 2 years.

Fully cemented fixation of the hip requires cementation of both the femoral and acetabular components. These reconstruction techniques have fallen out of favor with the widespread adoption of uncemented acetabular component fixation in revision total hip arthroplasty (15,16,31). Cementation does not provide biologic fixation, which increases the risk of long term mechanical failure. No series in literature exist that report on the outcomes of fully cemented component fixation at the time of reimplantation

of infected THA.

Knee specific outcomes

There exists much greater heterogeneity and confusion regarding the management of knee reconstruction with regards to the use of cemented or cementless stems. The emergence of stem fixation in revision total knee arthroplasty has allowed for improved stability by off-loading the metaphyseal region where augmentation may otherwise be necessary. It also allows for dispersed stresses by increasing the bone-implant surface (32,33).

Unlike with hip replacement, the term “cementless” typically refers only to the choice of fixation strategy as it applies to the stems utilized in revision knee surgery. The method of fixation is not entirely cementless—surgeons who employ a “press-fit” or “cementless” technique are cementing the knee in a hybrid fashion where cement is

applied to the articular and metaphyseal portions of the bone, which is then supported by long diaphyseal engaging stems. This type of construct is depicted in *Figure 3A*. These stems do not have a porous coating or any in-growth/on-growth potential. It is critical to engage at least 4 cm of the diaphysis to prevent early failure with this reconstruction technique (34).

On the other hand, cemented stems enable the stress imparted by bone loss to be distributed along the entire length of the construct and can also support reconstructions that may require higher levels of constraint, as depicted in *Figure 3B,C* (35,36). Concerns regarding the durability of cemented fixation in revision knee surgery remain the same as in primary surgery. These concerns are magnified in patients who have large and even catastrophic bone loss that would typically fail without some form of reconstruction technique in the metaphyseal zone with highly porous metaphyseal cones or sleeves.

Benefits of hybrid fixation include reduced surgical time and ease in removal if subsequent revision is required. The literature demonstrates that this reconstruction technique is equivalent to cemented reconstructions for mild to moderate bone loss (34,37,38). Furthermore, because long stems engage the diaphysis, the overall mechanical alignment is improved when compared to cemented reconstructions in patients who do not have an anatomic bow (9).

Cementless stems may have lower rates of loosening than cemented stems in the setting of PJI. Edwards *et al.* retrospectively compared 102 cemented to 126 cementless following two-stage exchange total knee arthroplasty (37), and found cementless stems had a lower rate of radiographic loosening (17% in the cementless group *vs.* 32% in the cemented group $P=0.006$) with no difference in re-infection between the two groups. In contrast, Wang *et al.* performed a meta-analysis of 17 studies comparing cemented versus cementless stems in aseptic revision total knee arthroplasty and found no difference in failure from aseptic loosening or infection (11).

Conclusions

Fixation methods for definitive reconstruction following PJI remains a complex topic. In the hip, cementless fixation of the femoral component appears to provide increased stability and longevity; however, cement or hybrid fixation with a cemented femoral stem and cementless acetabular cup may still provide comparable results in select patient

populations. For the reimplantation of infected total knee arthroplasty after two-stage exchange, cemented articular components remains the main mode of fixation, while cemented stems use depends on patient bone morphology and implant constraint. Higher quality comparative studies will remain challenging given the inherent complexity and heterogeneity of reimplantation after PJI. The plan for definitive fixation of implants should be individualized to address each patient's unique demographic characteristics and osseous structures at the time of reimplantation.

Acknowledgments

Funding: None.

Footnote

Provenance and Peer Review: This article was commissioned by the Guest Editors (Nemandra A Sandiford, Massimo Francescini and Daniel Kendoff) for the series “Prosthetic Joint Infection” published in *Annals of Joint*. The article has undergone external peer review.

Conflicts of Interest: All authors have completed the ICMJE uniform disclosure form (available at <http://dx.doi.org/10.21037/aoj-20-74>). The series “Prosthetic Joint Infection” was commissioned by the editorial office without any funding or sponsorship. AFC serves as an unpaid associate editor of *Annals of Joint* from June 2018 to May 2020. AFC reports personal fees from SLACK publishing, other from Joint Purification Systems, personal fees from Stryker, personal fees from bOne, other from Sonoran Biosciences, other from Graftworx, grants from OREF, personal fees from Pfizer, personal fees from Avanos, personal fees from Irrisept, personal fees from Convatec, personal fees from 3M, personal fees from Recro, personal fees from Heraeus, other from Hyalex, personal fees from DePuy - Ethicon, other from *The Journal of Bone and Joint Surgery*, personal fees from GLG, personal fees from UpToDate, outside the submitted work; and Editorial board: *Journal of Arthroplasty*; *Annals of Joint*; *Bone and Joint 360 Journal*; *Clinical Orthopaedics and Related Research*; *Healthcare Transformation*; *Journal of Bone and Joint Infection*; *Knee Surgery, Sports Traumatology, Arthroscopy*. Board/committee member: AAOS, AJRR, AAHKS, European Knee Association, International Congress for Joint Reconstruction, Musculoskeletal Infection Society. The authors have no other conflicts of interest to declare.

Ethical Statement: The authors are accountable for all aspects of the work in ensuring that questions related to the accuracy or integrity of any part of the work are appropriately investigated and resolved.

Open Access Statement: This is an Open Access article distributed in accordance with the Creative Commons Attribution-NonCommercial-NoDerivs 4.0 International License (CC BY-NC-ND 4.0), which permits the non-commercial replication and distribution of the article with the strict proviso that no changes or edits are made and the original work is properly cited (including links to both the formal publication through the relevant DOI and the license). See: <https://creativecommons.org/licenses/by-nc-nd/4.0/>.

References

1. Toulson C, Walcott-Sapp S, Hur J, et al. Treatment of infected total hip arthroplasty with a 2-stage reimplantation protocol: update on "our institution's" experience from 1989 to 2003. *J Arthroplasty* 2009;24:1051-60.
2. Westrich GH, Walcott-Sapp S, Bornstein LJ, et al. Modern treatment of infected total knee arthroplasty with a 2-stage reimplantation protocol. *J Arthroplasty* 2010;25:1015-21, 1021.e1-2.
3. Kurtz S, Ong K, Lau E, et al. Projections of primary and revision hip and knee arthroplasty in the United States from 2005 to 2030. *J Bone Joint Surg Am* 2007;89:780-5.
4. Edelstein AI, Okroj KT, Rogers T, et al. Nephrotoxicity After the Treatment of Periprosthetic Joint Infection With Antibiotic-Loaded Cement Spacers. *J Arthroplasty* 2018;33:2225-9.
5. Duey RE, Chong AC, McQueen DA, et al. Mechanical properties and elution characteristics of polymethylmethacrylate bone cement impregnated with antibiotics for various surface area and volume constructs. *Iowa Orthop J* 2012;32:104-15.
6. Berliner ZP, Mo AZ, Porter DA, et al. In-Hospital Acute Kidney Injury After TKA Revision With Placement of an Antibiotic Cement Spacer. *J Arthroplasty* 2018;33:S209-12.
7. Iarikov D, Demian H, Rubin D, et al. Choice and doses of antibacterial agents for cement spacers in treatment of prosthetic joint infections: review of published studies. *Clin Infect Dis* 2012;55:1474-80.
8. Mancuso F, Beltrame A, Colombo E, et al. Management of metaphyseal bone loss in revision knee arthroplasty. *Acta Biomed* 2017;88:98-111.
9. Morgan-Jones R, Oussedik SI, Graichen H, et al. Zonal fixation in revision total knee arthroplasty. *Bone Joint J* 2015;97-B:147-9.
10. Maggs J, Wilson M. The Relative Merits of Cemented and Uncemented Prostheses in Total Hip Arthroplasty. *Indian J Orthop* 2017;51:377-85.
11. Wang C, Pfitzner T, von Roth P, et al. Fixation of stem in revision of total knee arthroplasty: cemented versus cementless-a meta-analysis. *Knee Surg Sports Traumatol Arthrosc* 2016;24:3200-11.
12. Makita H, Kerboull M, Inaba Y, et al. Revision Total Hip Arthroplasty Using the Kerboull Acetabular Reinforcement Device and Structural Allograft for Severe Defects of the Acetabulum. *J Arthroplasty* 2017;32:3502-9.
13. Abdel MP, Cottino U, Larson DR, et al. Modular Fluted Tapered Stems in Aseptic Revision Total Hip Arthroplasty. *J Bone Joint Surg Am* 2017;99:873-81.
14. Kim YH, Park JW, Kim JS, et al. High Survivorship With Cementless Stems and Cortical Strut Allografts for Large Femoral Bone Defects in Revision THA. *Clin Orthop Relat Res* 2015;473:2990-3000.
15. Morshed S, Bozic KJ, Ries MD, et al. Comparison of cemented and uncemented fixation in total hip replacement: a meta-analysis. *Acta Orthop* 2007;78:315-26.
16. Yahiro MA, Gantenberg JB, Nelson R, et al. Comparison of the results of cemented, porous-ingrowth, and threaded acetabular cup fixation. A meta-analysis of the orthopaedic literature. *J Arthroplasty* 1995;10:339-50.
17. Amstutz HC, Ma SM, Jinnah RH, et al. Revision of aseptic loose total hip arthroplasties. *Clin Orthop Relat Res* 1982;21:33.
18. Kavanagh BF, Ilstrup DM, Fitzgerald RH, Jr. Revision total hip arthroplasty. *J Bone Joint Surg Am* 1985;67:517-26.
19. Pellicci PM, Wilson PD Jr, Sledge CB, et al. Long-term results of revision total hip replacement. A follow-up report. *J Bone Joint Surg Am* 1985;67:513-6.
20. Huang Y, Zhou Y, Shao H, et al. What Is the Difference Between Modular and Nonmodular Tapered Fluted Titanium Stems in Revision Total Hip Arthroplasty. *J Arthroplasty* 2017;32:3108-13.
21. Kraay MJ, Goldberg VM, Fitzgerald SJ, et al. Cementless two-staged total hip arthroplasty for deep periprosthetic infection. *Clin Orthop Relat Res* 2005;441:243-9.
22. Masri BA, Panagiotopoulos KP, Greidanus NV, et al. Cementless two-stage exchange arthroplasty for infection after total hip arthroplasty. *J Arthroplasty* 2007;22:72-8.
23. Romanò CL, Romano D, Meani E, et al. Two-stage

- revision surgery with preformed spacers and cementless implants for septic hip arthritis: a prospective, non-randomized cohort study. *BMC Infect Dis* 2011;11:129.
24. Haydon CM, Mehin R, Burnett S, et al. Revision total hip arthroplasty with use of a cemented femoral component. Results at a mean of ten years. *J Bone Joint Surg Am* 2004;86:1179-85.
 25. Holt G, Hook S, Hubble M. Revision total hip arthroplasty: the femoral side using cemented implants. *Int Orthop* 2011;35:267-73.
 26. Ito H, Tanino H, Yamanaka Y, et al. Cemented calcar replacement femoral component in revision hybrid total hip arthroplasty. *J Arthroplasty* 2011;26:236-43.
 27. Nelson CL. Cemented femoral revision: technique and outcome. *Am J Orthop (Belle Mead NJ)* 2002;31:187-9.
 28. Haddad FS, Sukeik M, Alazzawi S. Is single-stage revision according to a strict protocol effective in treatment of chronic knee arthroplasty infections? *Clin Orthop Relat Res* 2015;473:8-14.
 29. Zahar A, Klaber I, Gerken AM, et al. Ten-Year Results Following One-Stage Septic Hip Exchange in the Management of Periprosthetic Joint Infection. *J Arthroplasty* 2019;34:1221-6.
 30. Ilchmann T, Zimmerli W, Ochsner PE, et al. One-stage revision of infected hip arthroplasty: outcome of 39 consecutive hips. *Int Orthop* 2016;40:913-8.
 31. Kim YH, Kim JS, Park JW, et al. Cementless revision for infected total hip replacements. *J Bone Joint Surg Br* 2011;93:19-26.
 32. Albrektsson BE, Ryd L, Carlsson LV, et al. The effect of a stem on the tibial component of knee arthroplasty. A roentgen stereophotogrammetric study of uncemented tibial components in the Freeman-Samuelson knee arthroplasty. *J Bone Joint Surg Br* 1990;72:252-8.
 33. van Loon CJ, Kyriazopoulos A, Verdonschot N, et al. The role of femoral stem extension in total knee arthroplasty. *Clin Orthop Relat Res* 2000:282-9.
 34. Gililland JM, Gaffney CJ, Odum SM, et al. Clinical & radiographic outcomes of cemented vs. diaphyseal engaging cementless stems in aseptic revision TKA. *J Arthroplasty* 2014;29:224-8.
 35. Moussa ME, Lee YY, Patel AR, et al. Clinical Outcomes Following the Use of Constrained Condylar Knees in Primary Total Knee Arthroplasty. *J Arthroplasty* 2017;32:1869-73.
 36. Yoshii I, Whiteside LA, Milliano MT, et al. The effect of central stem and stem length on micromovement of the tibial tray. *J Arthroplasty* 1992;7 Suppl:433-8.
 37. Edwards PK, Fehring TK, Hamilton WG, et al. Are cementless stems more durable than cemented stems in two-stage revisions of infected total knee arthroplasties? *Clin Orthop Relat Res* 2014;472:206-11.
 38. Sinicrope BJ, Feher AW, Bhimani SJ, et al. Increased Survivorship of Cementless versus Cemented TKA in the Morbidly Obese. A Minimum 5-Year Follow-Up. *J Arthroplasty* 2019;34:309-14.

doi: 10.21037/aoj-20-74

Cite this article as: Drayer NJ, Paik HK, Chen AF. Reconstruction following periprosthetic joint infection: cemented or uncemented. *Ann Joint* 2021;6:44.