



# A narrative review of non-infected painful total shoulder arthroplasty: evaluation and treatment

Speros Gabriel<sup>^</sup>, Tyler Tucker, Michael A. Boin

Kansas City University/HCA Midwest Orthopedic Surgery, Orthopedic Surgeons, Inc., Kansas City, MO, USA

*Contributions:* (I) Conception and design: MA Boin; (II) Administrative support: MA Boin; (III) Provision of study materials or patients: All authors; (IV) Collection and assembly of data: All authors; (V) Data analysis and interpretation: All authors; (VI) Manuscript writing: All authors; (VII) Final approval of manuscript: All authors.

*Correspondence to:* Speros Gabriel, DO. Kansas City University/HCA Midwest Orthopedic Surgery, Orthopedic Surgeons, Inc., 2316 E Meyer Blvd, Kansas City, MO 64132, USA. Email: speros.gabriel@gmail.com.

**Background and Objective:** The prevalence of shoulder arthroplasty has increased significantly over the past two decades outpacing both total hip and total knee arthroplasty. Total shoulder arthroplasty (TSA) has been shown to significantly improve function and pain in most patients, however, complications after shoulder arthroplasty have been reported to be greater than 10% in anatomic shoulder arthroplasty and 10–47% in reverse shoulder arthroplasty leading to a painful shoulder. As the number of performed primary shoulder arthroplasty increases, the incidence of painful total shoulders and the need for revision shoulder arthroplasty will see a similar trend. Management of post-operative shoulder arthroplasty pain and complications will be even more essential for the orthopedic surgeon in this growing population. Potential sources of pain after shoulder arthroplasty are variable and include infection, implant related complications, hematoma, nerve injury, rotator cuff failure, instability, fracture, among other less prevalent complications. Treatment options for the painful shoulder arthroplasty differ depending on the source of pain, thus early identification of the cause will lead to expedited and appropriate definitive management. The objectives of this narrative review are to highlight the common causes of pain after TSA, provide surgeons an algorithmic approach for working up the painful total shoulder, and discuss treatment options for each source of pain.

**Methods:** A database search of PubMed and Google Scholar was conducted including studies relating to painful shoulder arthroplasty evaluation, management, and treatment.

**Key Content and Findings:** This review presents an in-depth evaluation to the non-infected, painful shoulder arthroplasty, providing treatment options for each source with the goal of assisting practicing physicians in the management of painful post-operative shoulder arthroplasty.

**Conclusions:** With increasing numbers of TSA being performed, a thorough understanding of the potential complications and their treatments is essential. A systematic approach to working up the painful TSA can help identify the source of symptoms more readily. Knowledge of the common complications and their specific causes can help surgeons avoid the painful TSA. This knowledge will also help to successfully treat the painful TSA when it is inevitably encountered.

**Keywords:** Shoulder; arthroplasty; complications; evaluation; treatment

Received: 23 November 2022; Accepted: 07 April 2023; Published online: 30 April 2023.

doi: 10.21037/aoj-22-43

**View this article at:** <https://dx.doi.org/10.21037/aoj-22-43>

<sup>^</sup> ORCID: 0000-0002-7548-018X.

## Introduction

Total shoulder arthroplasty (TSA) is a commonly performed procedure used to treat a variety of diseases of the shoulder that cause pain, limit range of motion, and impair function. Common indications for shoulder arthroplasty include: osteoarthritis, inflammatory arthritis, rotator cuff dysfunction or deficiency, proximal humerus fracture, and avascular necrosis (1). Excellent outcomes have been reported with both anatomic total shoulder arthroplasty (aTSA) and reverse total shoulder arthroplasty (rTSA) (2).

Despite the excellent outcomes of shoulder arthroplasty procedures, residual shoulder pain can occur with complication rates after shoulder arthroplasty reaching approximately 10% in anatomic shoulder arthroplasty and 10–47% in reverse shoulder arthroplasty (2,3). There are a multitude of potential causes of postoperative pain including infection, aseptic component loosening, rotator cuff tendinopathy, instability, fracture, nerve injury, among others. It can be difficult to determine the specific cause of pain if there are not obvious signs of failure on exam or initial radiographs.

Piper *et al.* reported a 10% increase in annual anatomic TSA volume and there is an expected nine-fold increase in TSA by 2030 (4). With shoulder arthroplasty becoming an increasingly performed procedure, an in-depth understanding of the complications and their management is of importance, as increasing complication numbers are inevitable. As the number of shoulder arthroplasty procedures continue to climb, so will the requirement of revision procedures (4). Now and in the future, it will be imperative to accurately identify and treat sources of painful shoulder arthroplasty.

This narrative review highlights the common sources of postoperative pain, provides an algorithmic evaluation of the painful shoulder arthroplasty, and discusses treatment options for each source of pain. The evaluation and treatment from postoperative clinical visit to operative intervention of clinical and radiographic findings, based on reviewed literature, will be discussed. Treatment options are vast and specific to each complication described throughout the article. An authors' preferred workup is included to provide a known method for evaluation of painful shoulder arthroplasty. This algorithm is based upon our clinical practice approach to evaluating and diagnosing painful shoulder arthroplasty (*Figure 1*). We present the following article in accordance with the Narrative Review reporting checklist (available at <https://aoj.amegroups.com/article/view/10.21037/aoj-22-43/rc>).

## Methods

A database search of PubMed and Google Scholar was conducted including studies relating to painful shoulder arthroplasty evaluation, management, and treatment. Articles were selected on the basis of author determined credibility, relevancy towards the topic, and current trends in best practice of evaluating and managing painful shoulder arthroplasty. Specific search terms were utilized (*Table 1*) and detailed search strategy is summarized (*Table 2*). Additional articles were selected for inclusion in the review through identification found on reference lists on previously attained articles. One article was included that was original content by the senior author. Articles greater than 20 years old were included if the content was thought to add relevant background information relating to complications of shoulder arthroplasty.

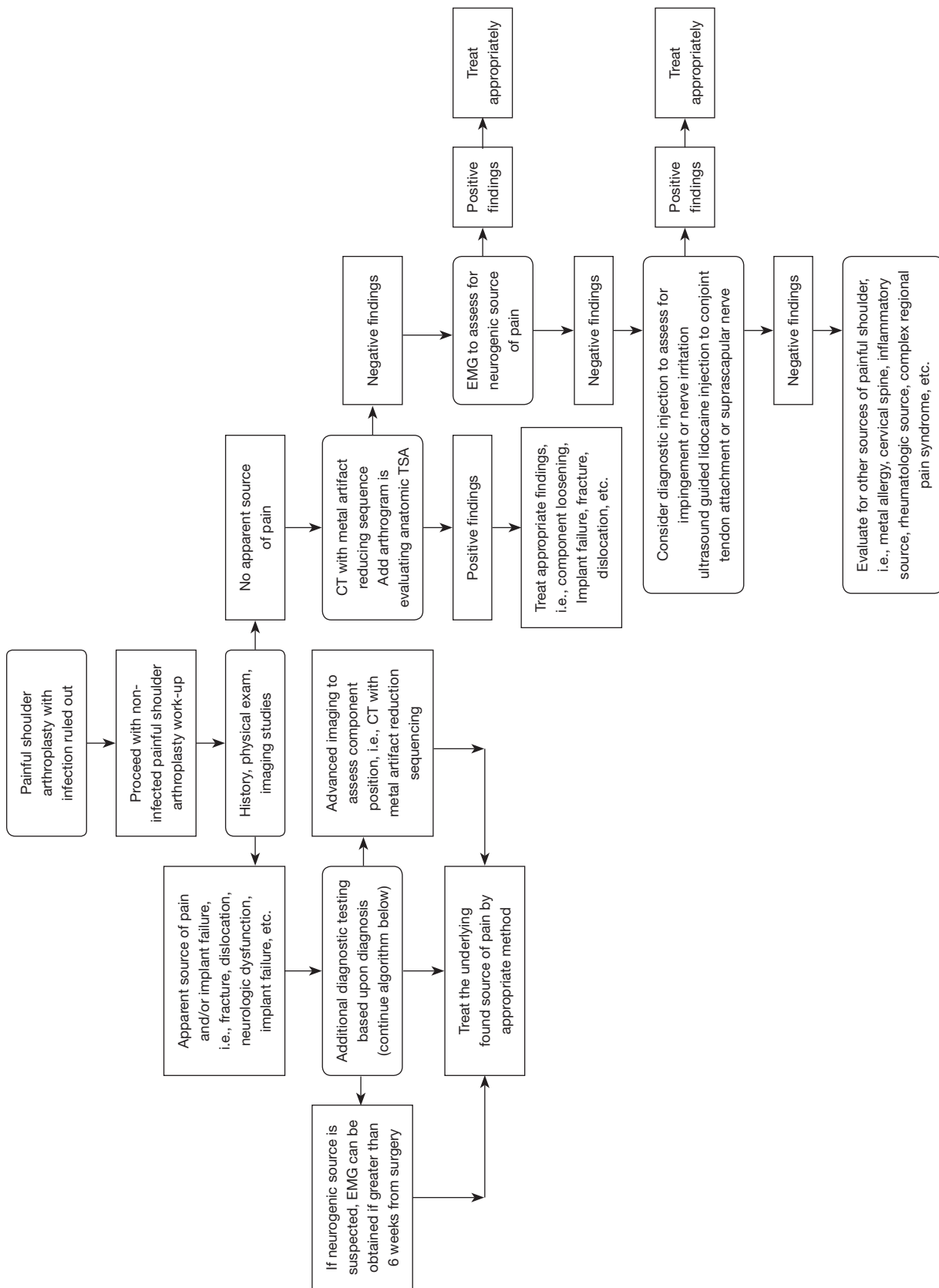
## Evaluation algorithm (*Figure 1*)

### *History and physical exam*

A systematic workup of the painful TSA is critical in correctly identifying the source of pain. Initial work-up should include a detailed history and physical exam. These aspects of the algorithmic approach provide initial insight for the complete work-up of painful shoulder arthroplasty. Important history components include duration and location of pain, rest or activity related pain, presence of a traumatic or inciting event, any initial postoperative issues, systemic symptoms, etc. The differential diagnosis is often different in patients who have a traumatic cause of pain versus those with persistent pain since the time of surgery (5).

Timing of pain can help narrow the differential. Pain at rest may be associated with infection or neuropathic pain, while pain with range of motion and/or activity suggests structural sources of pain, such as component impingement, component loosening, tendinopathy, and fracture (2,6). Time since surgery is a helpful tool in assessing the integrity of components. Aseptic component loosening and other component related complications are more likely to occur years after surgery, while complications such as postoperative infection, instability, nerve irritation, and soft tissue irritation/injury are more likely to be sources of pain acutely after surgery (1,7).

Location of pain is vital in developing a differential for



**Figure 1** Evaluation algorithm. EMG, electromyography; CT, computed tomography; TSA, total shoulder arthroplasty.

sources of pain. Pain localized to the scapula following rTSA should increase the suspicion for acromial stress reaction or fracture. Lateral arm pain after aTSA may point to rotator cuff pathology. Anterior shoulder pain after rTSA

can be due to conjoint tendonitis or coracoid fracture (8). Pain distal to the shoulder should increase suspicion for brachial neuropraxia or other nerve related pain (9). A checklist is available outlining major diagnostic steps during examination (*Table 3*).

**Table 1** Search terms used

Shoulder arthroplasty
Painful shoulder arthroplasty
Management of painful shoulder arthroplasty
Complications of shoulder arthroplasty
Shoulder arthroplasty acromial fracture
Shoulder ultrasound
Shoulder arthroplasty evaluation and treatment
Shoulder arthroplasty infection
Shoulder arthroplasty periprosthetic fracture

### *Imaging studies and other diagnostic tests*

Imaging studies provide insight into the structural integrity of the arthroplasty components as well as the status of bone and soft tissue. There are multiple imaging modalities that provide their own benefits towards diagnosing shoulder pain. It is helpful to obtain previous imaging studies for comparison when possible as these can be valuable in identifying changes at the interface between the bone and implants as well as overall alignment.

The initial imaging test in the evaluation of a shoulder arthroplasty should be plain X-rays. Preferred initial views include the true anterior-posterior (AP) (Grashey),

**Table 2** Search strategy summary

Items	Specification
Date of search	6/20/2022–3/15/2023
Databases and other sources searched	PubMed, Google Scholar
Search terms used	Please see <i>Table 1</i>
Timeframe	1988–2023
Inclusion and exclusion criteria	Inclusion criteria: journal articles and review articles translatable into English that review evaluation and management of painful shoulder arthroplasty. Exclusion criteria: articles were selected based off of relevance to the topic, and articles that were not relevant or were deemed low reliability to this study were excluded
Selection process	All authors contributed to the selection of articles

**Table 3** Checklist for painful shoulder arthroplasty clinical evaluation

History
Physical exam
Infectious analysis considered in all patients: proceed with laboratory analysis and consider aspiration and advanced laboratory testing if infection is not ruled out
Standard radiographic imaging
Consider advanced imaging for evaluation of arthroplasty components
Consider EMG for suspected neuropathic pain
Consider ultrasound guided injections for conjoint tendon impingement or suprascapular nerve irritation
Evaluate for other sources of shoulder pain if all testing related to affected shoulder is negative
EMG, electromyography.

axillary lateral, and scapular Y-view. Additional views can be obtained as necessary. Radiographic imaging can provide evidence of component loosening, component position, bone loss and fracture. Radiolucent lines adjacent to implants along with osteolysis can be key indicators of component loosening or infection. Stress shielding is also potentially identifiable on plain radiographs. If obvious signs of loosening, component failure, or fracture are identified on X-ray, advanced imaging, such as computed tomography (CT) scan, should be obtained for further assessment of bony anatomy and component positioning.

CT is a key imaging study for evaluation of postoperative pain following shoulder arthroplasty. This can give greater understanding of the bone-implant or bone-cement relationship, as well as identify fractures not visualized on radiographs. CT can best identify the position of the components. Scapular stress fractures are also best visualized with CT scan (10). CT scan is not only important for identifying the source of pain but is a valuable tool to plan for revision surgery if necessary. CT arthrogram is another helpful tool in evaluating painful shoulder arthroplasty. Extravasation of intra articular contrast can show rotator cuff tearing and help identify loosening of components (11,12).

Ultrasound is a helpful tool for assessing the painful shoulder arthroplasty, however this modality is often dependent on the technologist's skill set. Ultrasound has the ability to identify effusion, rotator cuff injury, scapular stress fracture, among others. It also has the benefit of being able to examine the shoulder dynamically which can be helpful for soft tissue pathology (13).

When neuropraxia or other nerve related pain is suspected, electromyography (EMG) is the study of choice. Timing of EMG is important as the test is not likely to show positive for 6 weeks after the onset of symptoms in acute neuropraxia (9). EMG can localize the nerve/nerves involved and grade the severity of the injury and probability of recovery (14).

If source of pain is still in question with indeterminate EMG results, ultrasound guided lidocaine injection can be trialed to evaluate for conjoint tendon impingement or suprascapular neuropathy. Ultrasound guidance is useful for accurate placement of therapeutic injection and can aid in proper diagnostic and therapeutic trial (13).

### **Laboratory evaluation**

Diagnostic evaluation of the painful shoulder arthroplasty

should include a standard laboratory workup, although inflammatory markers may not always be elevated. Tests to obtain include white blood cell (WBC) with differential, erythrocyte sedimentation rate, and C-reactive protein (3). These tests are part of a standard work-up of suspected periprosthetic infection and can be ordered in all situations where infected prosthesis is under consideration. Aspiration can also be considered, especially if inflammatory markers are elevated or infection is suspected, as inflammatory markers may not be elevated. *Cutibacterium acnes* is the most common pathogen in infected shoulder arthroplasty and may be present despite normal lab results. Aspiration can be performed and can provide valuable information, although sensitivity has been shown to be low, around 20%, when evaluating for an infection (3,15). Aspirate should be sent for cell count, gram stain, and culture. Newer tests such as alpha defensin and next generation sequencing are also available to further aid in the diagnosis of periprosthetic infection, with alpha defensin demonstrating a sensitivity of 75% and specificity of 97% (3). According to Burrus *et al.*, synovial interleukin 6 (IL-6) can be obtained with a sensitivity of 87% and specificity of 90% (3).

### **Sources of pain in TSA**

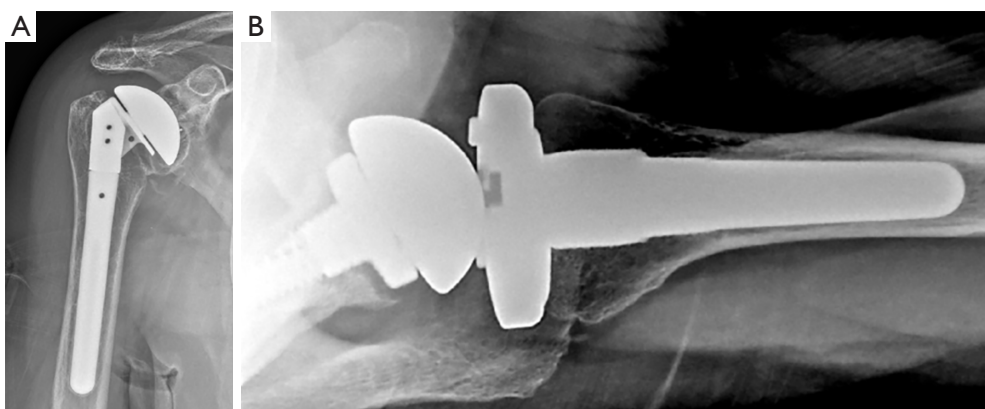
#### *Sources of pain in both rTSA and aTSA*

#### **Normal post-operative pain**

Early post-operative pain is a normal clinical exam finding in both rTSA and TSA. Implant type can have an impact on duration of postoperative pain as well as speed of recovery (16). Levy *et al.* demonstrated that compared to reverse arthroplasty, anatomic shoulder arthroplasty showed faster rates of return of shoulder functionality and lowered pain scores (16). Even with variation in patient pain levels and speed of recovery, pain and function are expected to improve gradually and a sudden change from steadily improving pain to increasing pain should be a cause for concern (16).

#### **Infection**

Periprosthetic infection is a common complication after shoulder arthroplasty, with an approximate rate of 1.2–1.5% for aTSA and 1–10% for rTSA (1,17,18). According to Bohsali *et al.*, it is the second most common reason for revision surgery in shoulder arthroplasty (1). Infection can present as insidious pain that occurs at rest and with activity. Presence of infection can include obvious signs



**Figure 2** Radiographic imaging demonstrating glenoid loosening in anatomic (A) and reverse (B) shoulder arthroplasty.

and symptoms, however, in shoulder arthroplasty its presentation is often occult. *C. acnes* is the most common pathogen in periprosthetic shoulder infections. Treatment includes antibiotics, irrigation and debridement with modular component exchanges, and one- or two-stage revision procedures (1,17). This article's focus is non-infectious sources of painful shoulder arthroplasty, however infection should always be ruled out.

### Neurogenic pain/neuropraxia

Reported rates of nerve injury after TSA are between 1–4% (14). rTSA has increased rates of this nerve injury as compared to aTSA due to alteration of native anatomy and lengthening of the arm (14). Exposure during shoulder arthroplasty surgery can lead to excessive external rotation of the arm as well as extension and adduction, placing the brachial plexus at risk for traction induced injury. Errant retractor placement can also result in nerve irritation. Direct injury to the axillary nerve is possible due to its course and proximity to the inferior glenoid. Specific implant design with rTSA can theoretically increase risk of injury due to distalization of the center of rotation and lengthening the arm. Specific implant factors such as onlay versus inlay humeral components and medialized versus lateralized glenoid components may play a role (14). Nerve injuries are a rarely occurring complication of shoulder arthroplasty surgery and their treatment is largely conservative with the vast majority resolving without treatment (19). The average time to improvement in brachial plexus neuropraxia is 3 months postoperatively (19).

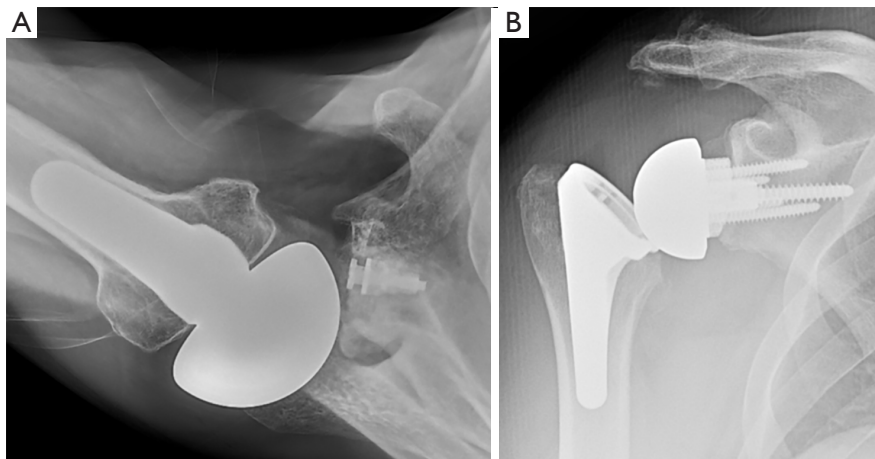
### Glenoid loosening

Loosening of the glenoid component is a well-documented complication in shoulder arthroplasty. Gonzalez *et al.* reported a glenoid loosening rate of 14.3% in anatomic TSA (20). Trivedi *et al.* reports a higher rate of long term glenoid loosening at 44% with an average follow-up of 12 years (21). Papadonikolakis *et al.* reported asymptomatic glenoid loosening in 7.3% annually and symptomatic loosening in 1.3% of aTSA per year (22).

Glenoid loosening in rTSA is less common than aTSA, but still occurs. A recent meta-analysis by Rojas *et al.* reports aseptic loosening of the glenosphere in both revision and primary rTSA within the first 12 months at 1.16% (23). The reduced rate of glenoid loosening in rTSA versus aTSA can be attributed to glenoid design. The ability for glenoid screw fixation and porous metal implants allows for bone ingrowth and more stable initial fixation.

Preoperative posterior glenoid bone loss/retroversion and posterior subluxation of humeral head have been shown to be risk factors for glenoid component loosening in aTSA. Insufficient glenoid bone stock and poorly positioned components, including superior inclination and excessive retroversion, have been shown to be risk factors for glenoid loosening in rTSA (24).

Glenoid loosening can be identified radiographically with radiolucent lines around implants (22) (Figure 2). This can be identified readily on plain X-rays in many cases, but some cases may require CT scan to identify loosening. Metal artifact reduction sequences are useful in identifying lucency around implants. CT arthrogram can be



**Figure 3** Radiographic imaging demonstrating posterior subluxation of anatomic shoulder arthroplasty (A) and instability of reverse shoulder arthroplasty (B).

useful to detect loosening as seen by contrast extravasation underneath the glenoid component (7).

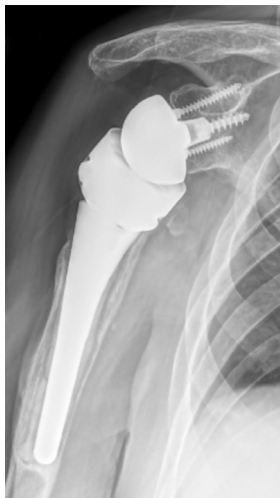Deformity correction with eccentric reaming, augmented glenoid components, and/or bone grafting are intra-operative strategies to help prevent glenoid loosening (20). Franklin *et al.* described the rocking horse phenomenon in which eccentric joint reaction forces will cause compression on one side and tension on the other side of the bone/implant or bone/cement interface leading to loosening (25). Treatment of symptomatic glenoid loosening requires revision shoulder arthroplasty. Most commonly, revision of a loose anatomic glenoid or a reverse baseplate is best performed by revising to a reverse glenoid component, often necessitating glenoid bone grafting and/or metal augmentation (26). Reverse TSA glenoid components provide better glenoid fixation versus anatomic fixation. Reverse baseplates have capacity for bony ingrowth as well as multiple screws to enhance fixation which is optimal when dealing with bone loss in a revision scenario. Reverse baseplates also provide a more stable environment and enhanced fixation for bone grafting (27).

### Instability

Instability and subluxation are known complications following aTSA (1). Parada *et al.* reported instability at 0.6% at a mean time of 19.5 months postoperative (28). Causes of unstable aTSA can include subscapularis/rotator cuff and capsular insufficiency, incorrect humeral stem version, and

uncorrected glenoid retroversion. Overstuffing the humeral component can lead to instability through loosening of soft tissues and failure of rotator cuff (1) (Figure 3A). Soft-tissue laxity and destruction (i.e., inflammatory arthritis) also can contribute to instability. Overall, instability seen after aTSA is likely multifactorial and further surgical intervention is often required (29). Soft tissue procedures can be attempted, such as subscapularis repair or pectoralis major transfer for anterior stability and posterior capsulorrhaphy for posterior instability. These procedures have high rates of recurrent instability and ultimately revision to rTSA is the gold standard treatment (20,24,26,29).

Instability following rTSA is also a commonly encountered problem with reported rates ranging from 2–31% (12,19) (Figure 3B). Guarrella *et al.* reports instability as being a primary reason for revision of reverse shoulder arthroplasty, accounting for 38% of revision cases (30). Conditions leading to instability include lack of soft tissue tension, improper sizing of implants, implant malposition, bony impingement, and infection. Instability in rTSA can be in the form of component dislocation or with subtle feelings of instability without frank dislocation. Frank dislocation should be managed with closed reduction if possible. Closed reduction and sling immobilization can be an adequate treatment method in early dislocations with success rates of around 50% (31). Recurrent dislocations, irreducible dislocations, and those with obvious instability following closed reduction should be managed with revision rTSA (17). Revision of rTSA in the setting of instability should focus on increasing soft



**Figure 4** Humeral loosening in rTSA. rTSA, reverse total shoulder arthroplasty.

tissue tension and eliminating any bony impingement. Malpositioned components should be revised. Often, increasing the size and lateralization of the glenosphere is the most effective treatment method (32). Increasing humeral polyethylene thickness and constraint are often used as well (32).

### Humeral loosening

Humeral component loosening can occur following either rTSA or aTSA. This is an infrequent complication and has been reported to be responsible for 3.3% of the total complications associated with aTSA, and 1.6% of the total complications of rTSA (28). Loosening can be identified with radiographs through change in implant position and radiolucency around implants (1,20) (*Figure 4*). Typical modes of humeral loosening include infection and poor initial fixation due to proximal humeral bone loss. Newer short stem implants have higher rates of stress shielding and some reports of increased humeral loosening (12). Management of humeral loosening requires revision of the humeral stem. Multiple options exist for humeral stem revision, from long stem revision components, distal fixation components, and cemented standard components. If proximal humeral bone loss is present, this should be addressed with revision to an allograft-prosthetic composite or proximal humeral replacing prosthesis (26).

### Periprosthetic fracture

Periprosthetic fracture can occur intraoperatively during

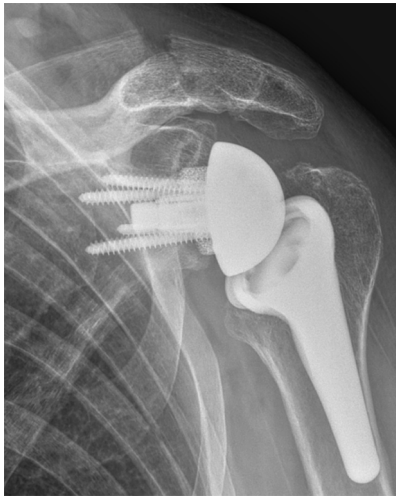implant insertion or postoperatively due to trauma. Glenoid fracture is most commonly seen intraoperatively and is less frequent postoperatively. Glenoid fracture is commonly due to the instruments used during preparation of the glenoid for implant insertion (17).

Periprosthetic humeral fractures can occur in various patterns and locations relative to the humeral stem. Management of these fractures varies by type of fracture and timing of fracture in terms of intra- *vs.* post-operative fracture. Wright *et al.* describes a periprosthetic humeral shaft fracture classification based on location of fracture relative to implant and pattern. The classification includes three fracture levels (A, B, C) with (A) being near the distal aspect of implant with fracture line extending proximally, (B) being near the distal aspect of stem with fracture line extending distally, and (C) including fracture line distal to the distal aspect of humeral stem (33). Nonoperative management can be trialed in postoperative type A, B, C fractures with stable prosthesis, although union is not always achieved. Type C fractures well distal to the stem have shown union rates similar to native humeral shaft fractures. Non-operative management is less defined with type A, B fractures, with controversial results (34). Postoperative type A, B periprosthetic fractures with stable implants can be managed with open reduction and internal fixation (ORIF) (35). Kirchhoff *et al.* outlined a comprehensive periprosthetic humeral shaft fracture classification in 2016 that includes stemless humeral implant, anatomic implant with stem, and reverse shoulder implant with a more recent study outlining the validation of this classification (36).

### Hematoma

Hematoma can form postoperatively and has been reported to occur in 1–20% of rTSA cases (17). This can be observed with patient reported pain, swelling, and drainage from the incisional site. Hematoma is seen at a greater rate in rTSA than in aTSA. There can be increased dead space between soft tissue planes in rTSA with many rTSA procedures being performed in patients with poor or torn rotator cuff tissue in combination with a larger acromiohumeral interval due to humeral distalization (2). Management of this complication is initially with observation. Hematomas can increase the risk of infection postoperatively due to this dead space (2). Severe hematoma can require re-operation with irrigation and debridement with repeat closure of wound in a layered fashion to prevent continued dead space formation





**Figure 5** Type II scapular stress fracture.

between tissue planes (2,17).

### *aTSA sources of pain*

#### **Rotator cuff failure**

Rotator cuff integrity is essential for the postoperative success of aTSA. The rotator cuff provides dynamic stability to the shoulder joint and allows for proper tensioning and motion. Failure of the rotator cuff leads to superior migration of the humeral head relative to the glenoid which can result in edge loading and early component wear, osteolysis, and loosening due to the rocking horse phenomenon (2). According to Bohsali *et al.*, rates of rotator cuff failure after aTSA range from 1.3–7.8% (1). Risk factors for failure include superior tilt of the glenoid component, infraspinatus atrophy, and increasing length of time from index aTSA procedure (2).

Physical exam is consistent with classic symptoms of rotator cuff tear including: shoulder pain, limited range of motion and strength. Standard radiographs can detect rotator cuff failure by a superiorly migrated humeral head or anterior subluxation in the case of subscapularis failure. In more subtle rotator cuff failure, a CT-arthrogram may be helpful in diagnosis.

Treatment options vary depending on the status of implants, tissue quality, and the time from the initial procedure. Acute subscapularis tendon tearing with good quality tissue can be managed with primary repair, however success with this technique is modest at best (37). Rotator cuff failure in aTSA generally requires revision to rTSA and

this remains the most effective solution despite the various other attempted salvage procedures (2).

### *rTSA sources of pain*

#### **Acromial/scapular fracture**

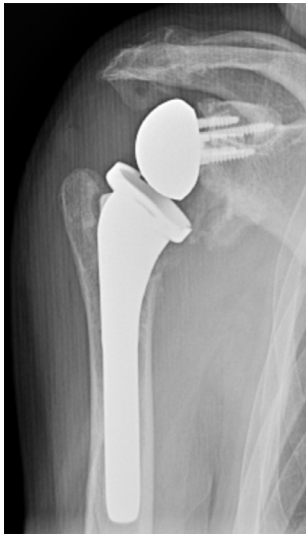Acromial stress fractures are a well-known complication with reverse shoulder arthroplasty (Figure 5). Incidence has been documented to occur in 0.6–15.8% of reverse shoulder arthroplasty (10,38,39). Fracture is thought to be related to the increased tensioning of the deltoid due to the center of rotation being redirected inferomedially. Another major component to development of the stress fracture is osteoporosis and the poor-quality bone of the acromion. Physical exam findings will generally include tenderness directly over the acromion at the site of the fracture. This complication can occasionally be observed on radiographs but often requires a CT to identify (40).

Levy classified acromial fractures according to location relative to the deltoid origin. The classification is sectioned into three types dividing the acromion into three distinct segments from lateral to medial. The lateral most segment, type 1, including the acromial corner, type 2 including the area between the acromial corner and base, and type 3 including the acromial base (38).

Patients with acute, non-displaced acromial fractures can generally trial non-operative management with non-weightbearing and immobilization followed by range of motion training and progressive physical therapy (40). Recent literature has demonstrated acceptable outcomes with non-operative management of these fractures (10).

Fractures at the acromial base and those involving scapular spine are better managed operatively as these fractures are at a higher risk of non-union and poor outcome. Fractures located towards the scapular spine involve increasing amounts of the deltoid origin, this limits the functionality of rTSA and restoration of appropriate deltoid tension should be pursued (41). The tensioning of the deltoid involved in rTSA increases the risk of displacement and poor healing potential of acromion fractures (41).

There are several treatment options available for fixation of acromion fractures. The construct of choice depends on fracture location. Treatment methods that have been described include tension banding, lag screw fixation, and dual orthogonal plating. Rouleau *et al.* describes a case report as well as a review of the literature for dual-orthogonal plating advocating for the increased purchase



**Figure 6** Scapular notching in rTSA. rTSA, reverse total shoulder arthroplasty.

and rigid stability of the construct to prevent fracture displacement and screw cut-out (41). They present a review of the sub-optimal outcomes of tension band techniques applied to fractures of the scapular spine and advocate for a more rigid construct.

Cho *et al.* completed a systematic review of acromial fracture after rTSA with results demonstrating inconclusive evidence for clear treatment algorithm (38). Fracture union rate was 43.8% with nonoperative treatment and 87.5% with operative treatment. Other studies have reported even higher non-union rates with nonoperative treatment, reaching 75% (40). There are not yet clearly defined indications for treatment of these fractures with need for further study and outcome results. Although many of conservatively treated fractures may go on to non-union, providers advocate for a painless non-union with acceptable results (40).

### Scapular notching

Scapular notching is a unique phenomenon associated with rTSA (Figure 6). Notching is the result of the humeral implant making direct contact with the scapular neck with adduction or rotation of the shoulder. According to Cheung *et al.*, scapular notching occurs in 51–96% of Grammont style rTSA implants and 0–13% in patients with lateralized components (17). This complication is thought to lead to component loosening and osteolysis as well as metallosis through particle debris seen with repetitive motion and

wear of components (7). Anatomic considerations in notching includes scapular neck length, varus versus valgus humeral neck shaft angle, inferior placement of the baseplate, lateralization, and size of glenosphere. Inferior glenoid tilt has recently been reported to lead to relative medialization of the center of rotation and thus increased risk for impingement, scapular notching, and subsequent glenoid component loosening (42).

Scapular notching itself does not require any specific treatment other than observation. If notching becomes severe enough, it can lead to glenoid component loosening and failure. It may also lead to osteolysis due to polyethylene wear which can affect humeral component stability. If severe osteolysis and implant failure occurs, revision shoulder arthroplasty is required (43).

### Conclusions

With increasing numbers of TSA being performed, a thorough understanding of the potential complications and their treatments is essential. A systematic approach to working up the painful TSA can help identify the source of symptoms more readily. Knowledge of the common complications and their specific causes can help surgeons avoid the painful TSA. This knowledge will also help to successfully treat the painful TSA when it is inevitably encountered.

### Acknowledgments

*Funding:* None.

### Footnote

*Provenance and Peer Review:* This article was commissioned by the Guest Editor (Prashant Meshram) for the series “Controversies in Shoulder Surgery and Algorithmic Approach to Decision Making” published in *Annals of Joint*. The article has undergone external peer review.

*Reporting Checklist:* The authors have completed the Narrative Review reporting checklist. Available at <https://aoj.amegroups.com/article/view/10.21037/aoj-22-43/rc>

*Peer Review File:* Available at <https://aoj.amegroups.com/article/view/10.21037/aoj-22-43/prf>

*Conflicts of Interest:* All authors have completed the ICMJE

uniform disclosure form (available at <https://aoj.amegroups.com/article/view/10.21037/aoj-22-43/coif>). The series “Controversies in Shoulder Surgery and Algorithmic Approach to Decision Making” was commissioned by the editorial office without any funding or sponsorship. The authors have no other conflicts of interest to declare.

*Ethical Statement:* The authors are accountable for all aspects of the work in ensuring that questions related to the accuracy or integrity of any part of the work are appropriately investigated and resolved.

*Open Access Statement:* This is an Open Access article distributed in accordance with the Creative Commons Attribution-NonCommercial-NoDerivs 4.0 International License (CC BY-NC-ND 4.0), which permits the non-commercial replication and distribution of the article with the strict proviso that no changes or edits are made and the original work is properly cited (including links to both the formal publication through the relevant DOI and the license). See: <https://creativecommons.org/licenses/by-nc-nd/4.0/>.

## References

- Bohsali KI, Bois AJ, Wirth MA. Complications of Shoulder Arthroplasty. *J Bone Joint Surg Am* 2017;99:256-69.
- Fossati C, Vitale M, Forin Valvecchi T, et al. Management of Painful Shoulder Arthroplasty: A Narrative Review. *Pain Ther* 2020;9:427-39.
- Burrus MT, Werner BC, Menendez ME, et al. Evaluation of the Painful Total Shoulder Arthroplasty. *J Am Acad Orthop Surg* 2023. [Epub ahead of print]. doi: 10.5435/JAAOS-D-22-01006.
- Piper C, Neviasser A. Survivorship of Anatomic Total Shoulder Arthroplasty. *J Am Acad Orthop Surg* 2022;30:457-65.
- Hagedorn JM, Pittelkow TP, Bendel MA, et al. The Painful Shoulder Arthroplasty: Appropriate Work-Up and Review of Interventional Pain Treatments. *JSES Reviews, Reports, and Techniques* 2022;2:269-76.
- Farley KX, Wilson JM, Kumar A, et al. Prevalence of Shoulder Arthroplasty in the United States and the Increasing Burden of Revision Shoulder Arthroplasty. *JB JS Open Access* 2021;6:e20.00156.
- Ekelund AL. Management of painful reverse shoulder arthroplasty. *Shoulder Elbow* 2017;9:212-22.
- Galvin JW, Kang J, Ma R, et al. Fractures of the Coracoid Process: Evaluation, Management, and Outcomes. *J Am Acad Orthop Surg* 2020;28:e706-15.
- Läderrmann A, Lübbecke A, Mélis B, et al. Prevalence of neurologic lesions after total shoulder arthroplasty. *J Bone Joint Surg Am* 2011;93:1288-93.
- Crosby LA, Hamilton A, Twiss T. Scapula fractures after reverse total shoulder arthroplasty: classification and treatment. *Clin Orthop Relat Res* 2011;469:2544-9.
- Gilot G, Alvarez-Pinzon AM, Wright TW, et al. The incidence of radiographic aseptic loosening of the humeral component in reverse total shoulder arthroplasty. *J Shoulder Elbow Surg* 2015;24:1555-9.
- Zmistowski B, Carpenter DP, Chalmers PN, et al. Symptomatic aseptic loosening of a short humeral stem following anatomic total shoulder arthroplasty. *J Shoulder Elbow Surg* 2021;30:2738-44.
- Singh JP. Shoulder ultrasound: What you need to know. *Indian J Radiol Imaging* 2012;22:284-92.
- Parisien RL, Yi PH, Hou L, et al. The risk of nerve injury during anatomical and reverse total shoulder arthroplasty: an intraoperative neuromonitoring study. *J Shoulder Elbow Surg* 2016;25:1122-7.
- Guild T, Kuhn G, Rivers M, et al. The Role of Arthroscopy in Painful Shoulder Arthroplasty: Is Revision Always Necessary? *Arthroscopy* 2020;36:1508-14.
- Levy JC, Everding NG, Gil CC Jr, et al. Speed of recovery after shoulder arthroplasty: a comparison of reverse and anatomic total shoulder arthroplasty. *J Shoulder Elbow Surg* 2014;23:1872-81.
- Cheung E, Willis M, Walker M, et al. Complications in reverse total shoulder arthroplasty. *J Am Acad Orthop Surg* 2011;19:439-49.
- Smucny M, Menendez ME, Ring D, et al. Inpatient surgical site infection after shoulder arthroplasty. *J Shoulder Elbow Surg* 2015;24:747-53.
- Zhou HS, Chung JS, Yi PH, et al. Management of complications after reverse shoulder arthroplasty. *Curr Rev Musculoskelet Med* 2015;8:92-7.
- Gonzalez JF, Alami GB, Baque F, et al. Complications of unconstrained shoulder prostheses. *J Shoulder Elbow Surg* 2011;20:666-82.
- Trivedi NN, Shimberg JL, Sivasundaram L, et al. Advances in Glenoid Design in Anatomic Total Shoulder Arthroplasty. *J Bone Joint Surg Am* 2020;102:1825-35.
- Papadonikolakis A, Neradilek MB, Matsen FA 3rd. Failure of the glenoid component in anatomic total shoulder arthroplasty: a systematic review of the English-language literature between 2006 and 2012. *J Bone Joint Surg Am*

- 2013;95:2205-12.
23. Rojas J, Choi K, Joseph J, et al. Aseptic Glenoid Baseplate Loosening After Reverse Total Shoulder Arthroplasty: A Systematic Review and Meta-Analysis. *JBJS Rev* 2019;7:e7.
  24. Walch G, Young AA, Boileau P, et al. Patterns of loosening of polyethylene keeled glenoid components after shoulder arthroplasty for primary osteoarthritis: results of a multicenter study with more than five years of follow-up. *J Bone Joint Surg Am* 2012;94:145-50.
  25. Franklin JL, Barrett WP, Jackins SE, et al. Glenoid loosening in total shoulder arthroplasty: association with rotator cuff deficiency. *J Arthroplasty* 1988;3:39-46.
  26. Favard L. Revision of total shoulder arthroplasty. *Orthop Traumatol Surg Res* 2013;99:S12-21.
  27. Boin MB, Virk MS. Addressing Glenoid Deformity in Reverse Total Shoulder Arthroplasty. *Shoulder Arthroplasty: Principles and Practice*. Chapter 25. Wolters-Kluwer; 2022.
  28. Parada SA, Flurin PH, Wright TW, et al. Comparison of complication types and rates associated with anatomic and reverse total shoulder arthroplasty. *J Shoulder Elbow Surg* 2021;30:811-8.
  29. Sanchez-Sotelo J, Sperling JW, Rowland CM, et al. Instability after shoulder arthroplasty: results of surgical treatment. *J Bone Joint Surg Am* 2003;85:622-31.
  30. Guarrella V, Chelli M, Domos P, et al. Risk factors for instability after reverse shoulder arthroplasty. *Shoulder Elbow* 2021;13:51-7.
  31. Teusink MJ, Pappou IP, Schwartz DG, et al. Results of closed management of acute dislocation after reverse shoulder arthroplasty. *J Shoulder Elbow Surg* 2015;24:621-7.
  32. Boileau P. Complications and revision of reverse total shoulder arthroplasty. *Orthop Traumatol Surg Res* 2016;102:S33-43.
  33. Wright TW, Cofield RH. Humeral fractures after shoulder arthroplasty. *J Bone Joint Surg Am* 1995;77:1340-6.
  34. Gebrelul A, Green A, Schacherer T, et al. Periprosthetic humerus fractures: classification, management, and review of the literature. *Ann Joint* 2018;3:49.
  35. Fram B, Elder A, Namdari S. Periprosthetic Humeral Fractures in Shoulder Arthroplasty. *JBJS Rev* 2019;7:e6.
  36. Kirchhoff C, Beirer M, Brunner U, et al. Validation of a new classification for periprosthetic shoulder fractures. *Int Orthop* 2018;42:1371-7.
  37. Clark JC, Ritchie J, Song FS, et al. Complication rates, dislocation, pain, and postoperative range of motion after reverse shoulder arthroplasty in patients with and without repair of the subscapularis. *J Shoulder Elbow Surg* 2012;21:36-41.
  38. Cho CH, Jung JW, Na SS, et al. Is Acromial Fracture after Reverse Total Shoulder Arthroplasty a Negligible Complication?: A Systematic Review. *Clin Orthop Surg* 2019;11:427-35.
  39. Levy JC, Anderson C, Samson A. Classification of postoperative acromial fractures following reverse shoulder arthroplasty. *J Bone Joint Surg Am* 2013;95:e104.
  40. Joyce CD, Seidl AJ. Managing acromial fractures: prevention and treatment, both nonoperative and operative. *Ann Joint* 2019;4:1.
  41. Rouleau DM, Gaudelli C. Successful treatment of fractures of the base of the acromion after reverse shoulder arthroplasty: Case report and review of the literature. *Int J Shoulder Surg* 2013;7:149-52.
  42. Patel M, Martin JR, Campbell DH, et al. Inferior tilt of the glenoid leads to medialization and increases impingement on the scapular neck in reverse shoulder arthroplasty. *J Shoulder Elbow Surg* 2021;30:1273-81.
  43. Friedman RJ, Barcel DA, Eichinger JK. Scapular Notching in Reverse Total Shoulder Arthroplasty. *J Am Acad Orthop Surg* 2019;27:200-9.

doi: 10.21037/aoj-22-43

**Cite this article as:** Gabriel S, Tucker T, Boin MA. A narrative review of non-infected painful total shoulder arthroplasty: evaluation and treatment. *Ann Joint* 2023;8:16.