



# Current scenario and future perspectives of minimally invasive approaches in rectal gastrointestinal stromal tumours

Marianna Maspero<sup>^</sup>, Jacopo Crippa<sup>^</sup>, Alessandro Giani, Carolina Rubicondo, Pietro Carnevali, Matteo Origi, Michele Mazzola, Camillo L. Bertoglio, Giovanni Ferrari, Carmelo Magistro

ASST Grande Ospedale Metropolitano Niguarda, Milan, Italy

**Contributions:** (I) Conception and design: M Maspero, J Crippa, C Magistro, G Ferrari, M Mazzola; (II) Administrative support: None; (III) Provision of study materials or patients: J Crippa, P Carnevali, M Origi, M Mazzola, G Ferrari, C Magistro; (IV) Collection and assembly of data: C Rubicondo, M Maspero, CL Bertoglio, A Giani, P Carnevali; (V) Data analysis and interpretation: J Crippa, M Maspero, C Rubicondo, M Origi, CL Bertoglio, A Giani, C Magistro; (VI) Manuscript writing: All authors; (VII) Final approval of manuscript: All authors.

**Correspondence to:** Carmelo Magistro, MD. Consultant, Division of Minimally-invasive and Oncologic General Surgery, ASST GOM Niguarda, Piazza Ospedale Maggiore 3, 20162, Milan, Italy. Email: carmelo.magistro@ospedaleniguarda.it.

**Abstract:** Gastrointestinal stromal tumours (GISTs) of the rectum are rare, corresponding to 0.1% of all rectal lesions. Their clinical course is generally more aggressive and with a higher risk of malignancy than GIST of other gastrointestinal sites. The only curative option for rectal GIST is surgery, which can be upfront or be combined with neoadjuvant chemotherapy with the tyrosine-kinase inhibitor Imatinib for tumor downstaging. Indeed, more than 85% of cases present mutations that make them susceptible to treatment with imatinib. The aim of surgery is to achieve a R0 resection, either by local excision or extended resection, while lymphadenectomy is not required. Surgical treatment of rectal GIST can be carried out via minimally invasive approaches, with an increasing number of reports of laparoscopic and robotic transabdominal extended resections, and of transanal endoluminal local excision, either with transanal endoscopic surgical platforms or robotic platforms. Surgeon expertise in minimally invasive techniques is crucial to ensure adequate oncological outcomes. The role of minimally invasive surgery for treatment of rectal GIST is likely to become more prominent in our near future, as those techniques get more widespread and technological advances provide better ergonomics, better visualization and cheaper appliances.

**Keywords:** Rectal gastrointestinal stromal tumor (rectal GIST); minimally invasive surgery; endoscopic surgery; robotic surgery

Received: 09 April 2020; Accepted: 22 September 2020; Published: 25 October 2021.

doi: 10.21037/ls-20-61

View this article at: <http://dx.doi.org/10.21037/ls-20-61>

## Background

Gastrointestinal stromal tumors (GIST) occur in the rectum in 3% to 10% of cases, making the rectum the third most frequent site after the stomach and the small intestine (1). Rectal GISTs are rare, representing 0.1% of all tumors arising from the rectum (2). This accounts for the paucity of literature on the subject, consisting mainly of small

observational series and case reports.

Similarly to other GIST, they are tumors of mesenchymal origin arising from the interstitial cells of Cajal, presenting oncogenic mutations of KIT or PDGFR $\alpha$  (platelet-derived growth factor receptor alpha) in more than 85% of cases. These mutations allow for a targeted therapy with the tyrosine-kinase inhibitor Imatinib. Imatinib can be administered before surgery or in an adjuvant setting

<sup>^</sup> ORCID: Marianna Maspero, 0000-0002-7589-4489; Jacopo Crippa, 0000-0003-4090-0989.

in high risk cases, or as palliative treatment in case of metastatic or otherwise inoperable tumors.

In the rectum, more than in any other part of the gastrointestinal tract, the treatment of GIST should be based upon a multidisciplinary approach involving surgeons, oncologists and radiologists (1). Preoperative Imatinib is reserved for those cases in which preoperative downsizing may reduce surgical morbidity and enable resection with a more conservative procedure. It is indicated in case of tumors presenting high-risk features, and it is particularly effective in case of large locally advanced tumors or for those patients candidate to abdominoperineal resection (APR). Cavnar *et al.* compared the outcomes of 17 patients treated in the pre-imatinib era (before 2001) versus 30 patients in the imatinib era, and found a drop in APR and pelvic exenteration from 59% to 3% (1). Similar results on the increased chance of sphincter-saving surgery after preoperative Imatinib have been reported by other studies (3,4). Complete pathologic response after neoadjuvant therapy is rare and isn't considered a therapeutic target (5). Despite this radical shift brought by Imatinib, surgery remains the only curative treatment for rectal GIST. Surgical resection of GIST can be performed through local excision or extended resection and it depends on the distance of the tumor from the anal verge, on the tumor size and its contiguity with other organs.

The last decades have seen an increase in the role of minimally invasive surgery for the treatment of rectal lesions. Short-term benefits of minimally invasive surgery compared to open surgery have been clearly demonstrated (6,7), however some trials have failed to establish the noninferiority of laparoscopy compared to open surgery regarding oncological outcomes (8,9).

Regarding rectal GIST, there have been scarce but promising reports of minimally invasive approaches for trans-abdominal extended resection (10-12). More substantial are the reports of local excisions through transanal minimally invasive platforms, both endoscopic and robotic, showcasing an ever-growing interest in natural orifice approaches for treatment of rectal lesions.

There is a lack of consensus about the gold-standard surgical approach to rectal GIST and whether it can be approached mini-invasively is still up for debate.

In this review, we will examine the available literature on the surgical approach to rectal GIST, with a particular focus on the application of minimally invasive techniques.

We present the following article in accordance with the Narrative Review reporting checklist (available at <http://dx.doi.org/10.21037/ls-20-61>).

[dx.doi.org/10.21037/ls-20-61](http://dx.doi.org/10.21037/ls-20-61)).

## Methods

The literature search for this narrative review was conducted using the PubMed, EMBASE and Google Scholar search engines, searching for publications in the English language using the keywords “rectal GIST”, “rectal gastrointestinal stromal tumor”, “minimally invasive surgery”, “endoscopic surgery”, “robotic surgery” and “local excision” in different combinations. No time limit was posed and all study designs were considered, including case reports and video vignettes. Reference lists of selected studies were also examined for potentially relevant publications.

### Diagnosis and staging

The mean age at diagnosis for rectal GIST is 65 years, with equal distribution between males and females (13).

Rectal GISTs are frequently diagnosed as incidental findings, e.g., during a routine colonoscopy, or may present with symptoms due to local involvement or, more rarely, due to distant metastases. Common symptoms include abdominal pain, constipation, pelvic or suprapubic pain, rectal bleeding or anemia, and weight loss. On digital rectal examination, a GIST of the lower rectum appears as a soft mass, firmly adherent to the deep visceral planes (2).

Preoperative staging of rectal GIST follows the same indications as GIST of the upper gastrointestinal tract. The most common sites of metastasis are the perineum and liver, while dissemination to lung, bone and lymph nodes is rare.

All patients should receive computed tomography (CT) of the abdomen and pelvis with administration of IV and oral contrast. For rectal GIST, contrast-enhanced magnetic resonance enables for better preoperative local staging and better visualization of the surrounding pelvic structures. Chest CT scan should be added to exclude lung metastasis, although very rare.

GIST usually originates from the muscularis propria, less often from the muscularis mucosa. At imaging, an intramural mass with no involvement of the mucosa should raise a suspicion of GIST.

Colonoscopy is frequently the first exam performed. At colonoscopy, the GIST appears as a mass enveloped in regular mucosa with a healthy epithelium. Mucosal involvement is rare, but may develop as a result of the erosion of the tumor from deeper planes. Tumor erosion may lead to bleeding.

Endoscopic ultrasound (EUS) can be used to exclude local invasion and determine high-risk features, such as heterogeneity, echogenic foci, cystic areas, ulceration, irregular borders. ESMO guidelines recommend EUS-guided biopsy for mutational analysis in all rectal GIST (14). The interruption of the GIST capsule exposes to a high risk of insemination, but the risk of peritoneal contamination following biopsy is negligible if the procedure is properly performed. Positron emission tomography with fluorodeoxyglucose (FDG-PET) may be useful for metastasis detection and to assess susceptibility to targeted therapy.

Prognostic factors for GIST are related to tumor location, histology, tumor size, depth of invasion, grade of differentiation, presence of metastasis, and mitotic rate (14).

NIH-Fletcher criteria for GIST risk assessment (15) stratify lesions according to tumor size and mitotic rate per 50 high-power fields (HPF). A GIST with a mitotic rate  $>5$  per 50 HPF and a diameter  $>5$  cm is considered a high-risk lesion and has an 85% chance of becoming metastatic (16). Rectal GISTs are classified as high risk in about 86% of cases, much higher than the 20–50% frequency in GIST of other sites (17). Miettinen *et al.* (18), in 2006, created the Armed Forces Institute of Pathology (AFIP) classification system, which adds the prognostic value of the anatomical site, and states that non-gastric GIST have a worse prognosis than gastric GIST. The modified NIH classification (19), designed by Joensuu *et al.* in 2008 as an evolution of the NIH criteria and the AFIP classification, also considers the negative prognostic value of tumor rupture.

## Surgical treatment

Surgical resection is the only curative treatment for rectal GIST. A full preoperative workup is crucial to establish resectability and to plan the most appropriate treatment strategy.

For tumors  $<2$  cm with no high-risk features, NCCN guidelines permit a wait and watch strategy with endoscopic surveillance performed every 6–12 months (16). Differently, ESMO guidelines (14) recommend biopsy or excision of any rectal nodule, regardless of the tumor size, for they have a worse prognosis compared with GIST of other sites and tend to a faster progression. Each case has to be carefully evaluated, considering patient-specific characteristics, such as life expectancy and comorbidities.

Surgery can be upfront or follow neoadjuvant treatment

with imatinib. Once the timing of surgery has been established, tumor excision can be carried out in two ways: local excision or extended resection. The decision for one or the other should be based on tumor size, location and malignancy risk stratification (15).

Surgical approaches for rectal GIST are many and varied: with the increased interest and development of minimally invasive approaches, both trans-anal and trans-abdominal, novel options have become available in recent years.

The goal of surgery is to perform a R0 resection. The decision of using one approach over another should reflect this goal, balancing the best oncological outcome with organ preservation. A clear margin of a few millimeters is enough to achieve an R0 resection in rectal GIST.

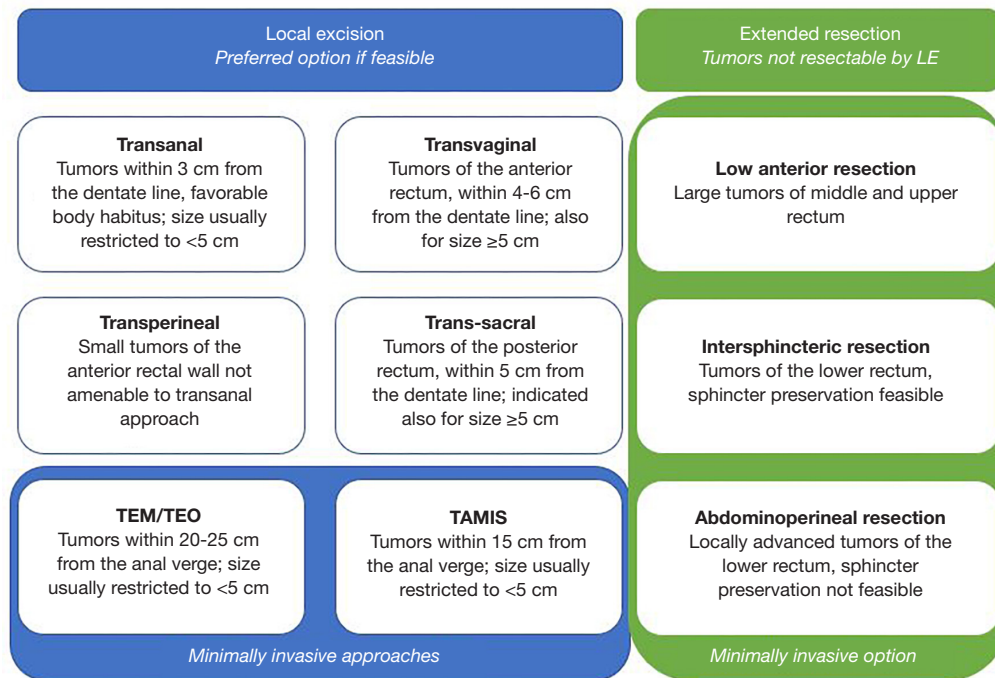
A large retrospective review from the American College of Surgeons Oncology Group (ACOSOG) Intergroup Adjuvant Gist Study Team examined the outcomes of 819 patients who underwent resection of primary GIST (20). They found no difference in recurrence-free survival (RFS) between R1 and R0 resections, and concluded that recurrence was likely correlated with tumor rupture. Other series including only rectal GIST found that R1 resection was an independent factor for decreased RFS (4,5). Most R1 resections are enucleations, which have a high risk of tumor rupture, with negative implications on the oncological outcome. For small tumors, endoscopic tattoo marking may help with intraoperative localization of the lesion.

If the goal of a R0 resection cannot be achieved (e.g., due to unfavorable location, unfavorable pelvic conformation, closeness to other anatomical structures), a R1 resection could still be beneficial. If a R0 resection would cause significant functional impairment, a discussion can be held with the patient regarding more conservative options with R1 resection.

Surgery for rectal GIST may not follow the principles of mesorectal excision that represent the gold standard for rectal adenocarcinoma. Lymphadenectomy of negative lymph nodes is not recommended (14) for GIST commonly spread through the hematogenous route rather than lymphatics. This is one reason why a local approach is preferable when indicated.

## Indications

When establishing the surgical plan for a rectal GIST, the surgeon should carefully evaluate distance of the tumor from the anal verge, the tumor size, risk features and the involvement of adjacent structures.



**Figure 1** Surgical options for treatment of rectal GIST. Transabdominal procedures for extended resection may be combined with transanal approaches for hybrid top-down and bottom-up procedures. GIST, gastrointestinal stromal tumour; LE, local excision; TEM, transanal endoscopic microsurgery; TEO, transanal endoscopic operation; TAMIS, transanal minimally invasive surgery.

Figure 1 summarizes the main surgical options for treatment of rectal GIST.

If the tumor is located in the upper and middle rectum, low anterior resection is the preferred choice in the majority of cases. The upper and middle rectum can also be reached via transanal minimally invasive surgery (TAMIS), transanal endoscopic microsurgery (TEM) and transanal endoscopic operation (TEO).

For tumors located in the lower rectum, local excision can be offered if sphincter-preserving R0 resection is achievable. Rectal GIST resection does not require wide margins or an extended lymphadenectomy, making them feasible for local excision thus reducing morbidity and preserve sphincter function. The approach can be transanal for tumors within 3 cm from the dentate line (21), transvaginal and transperineal for tumors located in the anterior rectum or trans-sacral for tumors located in the posterior rectum.

Transvaginal excision can be considered for lesions located in the anterior rectal wall and at an average distance from the dentate line of 4 cm (22), although excision of tumours located as high as 6 cm has been described (23).

This approach has been successfully applied in case of tumours  $\geq 5$  cm in diameter (22,24) and offers a valid alternative for GIST of the rectovaginal septum that are too large or unfavourably located for transanal excision. The major concern regarding this approach is the development of rectovaginal fistula, whose rate of occurrence however appears low (25).

The transperineal approach is quite uncommon, with few reports in the literature (26-28). It offers an alternative for tumours located in the anterior rectum but not close enough to the anal verge to be approached transanally. The transperineal approach should be considered in small anteriorly located rectal GIST that would otherwise be candidate to APR. During the procedure, a hard catheter should be placed in the urethra and its position frequently assessed during incision to avoid urethral injury, while the tumour should be located with digital examination.

Several series have reported similar oncological outcomes following local excision versus extended resection in tumors of the lower rectum (4,5,29,30).

In a recent case series (4), Shu *et al.* analyzed 71 patients with rectal GIST, 42 treated with local excision and 29 with

extended surgery. In the local excision group, there were significantly smaller tumors as well as a greater number of low-risk GIST. R0 resection was reached in a minority of cases compared to the extended surgery group (69% *vs.* 93%). In the extended surgery group, 23 patients had a tumor located in the lower rectum. Eleven patients received preoperative Imatinib, 8 of whom subsequently underwent anterior resection. Of the 12 patients that didn't receive neoadjuvant therapy, 10 received an APR; this once again suggests that preoperative Imatinib increases the chances of sphincter-saving surgery. After a median follow up of 84 months, they found 25 recurrences and a 5-year RFS and OS of 64.8% and 91.5%. At a multivariate Cox regression analysis, higher malignant risk grade and R1 resection were independent predictors for poor RFS, while surgical modality had no impact.

Local excision should be performed with caution in case of ulcerated GIST, as its oncological safety has yet to be proved. Indeed, local excision of ulcerated GIST poses a higher risk of rupture of the rectal wall, with potential peritoneal dissemination.

Whenever local excision cannot be performed, patients should undergo biopsy for risk stratification of the tumor and mutational analysis to assess the possibility of a neoadjuvant treatment. Neoadjuvant treatment may down-size the tumor, increase the chances for a R0 resection and allow for sphincter-saving surgery. If this still isn't the case, APR should be taken into consideration, although whether conservative surgery followed by adjuvant chemotherapy may be an oncologically safe alternative to APR (31) is still debated.

### ***Minimally-invasive approaches to rectal GIST***

#### **Trans-abdominal minimally invasive surgery**

The role of trans-abdominal minimally invasive surgery, both laparoscopic and robotic, is well established in the treatment of GIST of the stomach and small intestine, and has been validated by multiple studies (32-36).

The well-known advantages of a minimally-invasive approach such as a reduced postoperative pain, faster recovery and shortened length of hospital stay, have all been translated to the treatment of GIST. Laparoscopic excision should follow the principles of oncological surgery (14), and tumors should be removed via plastic bag to prevent the risk of port-site tumor recurrence.

Despite its increasingly widespread use, laparoscopy for the treatment of rectal adenocarcinoma has still not been

accepted as a standard of care. Laparoscopy in the rectum is technically challenging due to the constraints of the pelvis, the need to preserve adjacent structures and the importance of dissection in the correct plane to guarantee the adequacy of total mesorectal excision. However, while quality of rectal cancer surgery is based on the integrity of mesorectal excision, negative circumferential resection margins and the number of harvested lymph nodes, these concerns do not apply to the treatment of GIST.

Current guidelines limit the use of laparoscopy for GIST to small-sized tumors due to the increased risk of tumor rupture: NCCN guidelines set the cut-off at 2 cm (16), while ESMO guidelines discourage a laparoscopic approach for large tumors (14).

Nevertheless, several studies and meta-analyses have compared laparoscopic and open surgery for the treatment of GIST  $\geq 5$  cm with consistent findings of similar morbidity rate and oncological outcomes compared to open surgery, with a shorter length of hospital stay for patients treated laparoscopically (31,37-41).

While the body of literature on laparoscopic treatment of gastric and small intestinal GIST is wide and solid, reports on laparoscopic treatment of rectal GIST are few. Their main findings are summarized in *Table 1*.

In 2007, Nakamura *et al.* (12) published a case report of a laparoscopic APR for rectal GIST following preoperative Imatinib. The case was a 6.5 cm GIST located on the anterior wall of the lower rectum with a local invasion of the anal sphincter. They reported no postoperative complications and no recurrence after 15 months of follow up. No adjuvant therapy was required, as it was a low-risk lesion. The authors concluded that laparoscopic surgery improved visualization of the tumor on the anterior wall of the rectum, especially during the dissection near to the seminal vesicles and prostate.

In 2014, Fujimoto *et al.* (11) published a case series of 5 patients with rectal GIST who underwent laparoscopic sphincter-preserving surgery after 4-12 months of preoperative Imatinib therapy. Three patients underwent laparoscopic intersphincteric resection (ISR), while two patients underwent laparoscopic modified ISR with preservation of the superior rectal artery. All patients received a diverting ileostomy. The authors reported one occurrence of postoperative ileus, managed conservatively. Three patients received postoperative Imatinib. They reported no recurrence after a median follow up period of 36 months.

Somu *et al.* (42) in 2016 reported a case of a 6.7 cm rectal

**Table 1** Minimally invasive surgery in rectal GIST

Authors	Year	Operation	N. of patients	Preoperative IM	R0 resections	Size (cm)	Distance from the anal verge (cm)	Complications	Follow up (months)	Recurrences
Transabdominal minimally invasive surgery										
Nakamura (12)	2007	Laparoscopic APR	1	1/1	1/1	6.5	N/A	0/1	15	0/1
Fujimoto (11)	2014	Laparoscopic ISR	5	5/5	5/5	3.1 (2.4–8.8)	3 (2–5.0)	1/5	36	0/5
Somu (42)	2016	Laparoscopic subserosal excision	1	0/1	1/1	6.7	3	0/1	N/A	N/A
Du (10)	2016	Robotic ISR	3	3/3	3/3	4 (1.6–6.1)	2.5 (2–3.0)	0/3	12	0/3
Transanal minimally invasive surgery										
Han (43)	2017	TEM	25	8/25	25/25	N/A	N/A	0/35	36	0/25
Wu (44)	2018	TEM	35	12/35	35/35	1.8±1.1	4±1.8	8/35	50	0/30
Liu (45)	2017	TEM	1	1/1	1/1	1.9	4	0/1	18	0/1
Eidamshety (46)	2017	TEO	2	1/2	2/2	1.5–5.9	2–4	1/2	12	0/2
Quaresima (47)	2016	TAMIS	2/31	N/A	2/2	2.4 (1–5.0)	9.5 (6–15.0)	3/31	30	0/2
Pintor-Tortolero (48)	2016	TAMIS	3	0/3	3/3	2 (1–3.5)	10 (8–12.0)	0/3	18	0/3
Nepal (49)	2018	TAMIS	1	0/1	1/1	4.5	7	0/1	12	0/1
Spinelli (50)	2019	TAMIS	1	1/1	1/1	2.5	2	0/1	8	0/1
Hybrid transabdominal and transanal minimally invasive surgery										
Wachter (51)	2016	Laparoscopic ISR + TAMIS	1	1/2	2/2	7	3	0/1	12	0/1
Transanal robotic surgery										
Paull (52)	2018	Flex® Colorectal Drive Robotic System	1	0/1	N/A	1.4	13	0/1	N/A	N/A
Tomassi (53)	2019	Robotic TAMIS	1/58	N/A	1/1	4.2	5	9/58	22	0/1

Values are n or mean (range). GIST, gastrointestinal stromal tumour; N/A, non applicable; IM, imatinib mesylate; APR, abdominoperineal resection; ISR, intersphincteric resection; TEM, transanal endoscopic microsurgery; TEO, transanal endoscopic operation; TAMIS, transanal minimally invasive surgery.

GIST located 3 cm from the anal verge, which was resected through a laparoscopic subserosal excision, without the need for extended resection. The capsule was delivered intact and the serosal gap was left open. The patient received covering loop ileostomy. Postoperative course was uneventful. Oncological follow up was not reported.

It can be concluded that, in centers with an extensive experience in laparoscopic surgery, laparoscopy may be considered if R0 resection is feasible and the integrity of the capsule can be maintained.

Robotic surgery, with its three-dimensional vision, increased control of the surgical field, heightened precision of movement, and improved ergonomics, may be helpful in excising large, unfavourably located GISTs, and diminish the risk of tumor rupture. The use of this approach in the treatment of rectal GIST is limited to a case series by Du *et al.* (10) in which 3 patients underwent robot-assisted ISR. They reported no postoperative complications and no recurrence at 12 months follow up.

More studies are needed to validate those preliminary results, but the transabdominal minimally invasive approach appears to be safe and effective if performed by adequately skilled surgeons.

### Transanal endoscopic surgery (TES)

TES consists of different relatively new platforms (namely TEM, TAMIS and TEO) that allow for local excision of lesions located in the middle and lower rectum. It may also be considered for favorably small tumors located in the upper rectum, especially TEM and TEO: while TAMIS can only access lesions located 12–15 cm from the anal verge, TEM and TEO may reach lesions located up to 20–25 cm from the verge (54).

While considerably more technically demanding than other local approaches, TES may achieve superior operative results thanks to a better exposition and visualization, and permits the extraction of the specimen intact.

In TEM, endoluminal surgery is performed with constant CO<sub>2</sub> insufflation through a dedicated closed proctoscopic system. The quality of resection is improved compared to transanal local excision, but its high costs and long learning curve have hindered its diffusion.

Its application in the treatment of rectal GIST has been shown in two recent series (43,44), that reported results on respectively 25 and 35 patients who underwent rectal GIST excision with TEM. In the series by Han *et al.* (43), they had no postoperative complications and no recurrence after a median follow up of 3 years. Eight patients received

preoperative Imatinib, with an average downsizing ratio of 14.5%: this allowed resection by TEM for several large tumors at diagnosis. Wu *et al.* (44) reported excision of 35 rectal GIST, with a mean tumor diameter of 1.8±1.1 cm and a mean distance from the anal verge of 4±1.8 cm. They reported 7 minor complications, while 1 patient require reoperation. After more than 50 months of follow up, the authors reported no local recurrence or metastasis.

TEO can be considered an evolution of TEM, with improved ergonomics (55) and significantly lower cost thanks to a reusable platform. The only experience with TEO for the treatment of rectal GIST comes from the 2 cases described by Eldamshety *et al.* (46). One case was a 1.5 cm mass located 2 cm from the anal verge and the other a 5.9 cm mass at the recto-vaginal pouch. They reported a low complication rate with only a wound dehiscence in one patient. After respectively 14 and 10 months of follow up, the patients remained disease free.

In TAMIS, transanal access is achieved through a standard single-port laparoscopic equipment. It is cheaper than TEM and may have less impact on anal function, however it has lower reach and may be unsuitable for larger tumors.

Several case reports on the use of TAMIS for the treatment of rectal GIST have been published (47–51), describing a low morbidity rate and good oncological outcomes. While the majority of the lesions were around 2 cm in diameters, Nepal *et al.* (49) reported the excision of a 4.5 cm submucosal GIST. As for tumor location, Pintor-Tortolero *et al.* (48) described excision of a tumor located 12 cm from the anal verge, the highest currently reported.

Wachter *et al.* (51) described the case of a 10 cm locally advanced GIST located 3 cm from the anal verge that, after preoperative Imatinib with downsizing to 7 cm, was excised through an electrophysiology-controlled nerve-sparing hybrid of laparoscopic partial intersphincteric resection and TAMIS. The patient retained good anal and urinary function and 12 months after the procedure remains disease-free.

Many authors advocating for TES stress the importance of preservation of urinary and anorectal function. While the experience for rectal GIST is limited, initial results are promising and, together with good postoperative, functional and oncological outcomes obtained for other rectal lesions, may encourage the use of TES in carefully selected patients in specialized centers.

### Robotic transanal surgery

The application of robotic technology for a transanal

approach is still in its early stages, but it's been successfully implemented both in robotic-TAMIS (56) and in the transanal portion of transanal total mesorectal excision (TaTME) (57).

Paull *et al.* published in 2018 a case report (52) on the use of the Flex Colorectal Drive Robotic System for the excision of a 1.4 cm rectal GIST located 13 cm from the anal verge. They had no postoperative complications.

In the context of a case series on 58 patients with rectal lesions treated with robotic transanal excision (53), Tomassi *et al.* in 2019 reported one case of a 4.2 cm rectal GIST located 5 cm from the anal verge. The patient had no recurrence after 22 months of follow up. They concluded that this approach is safe and oncologically effective in selected cases and it may be superior to other transanal minimally invasive approaches with regards to quality of resection and morbidity, and may offer superior ergonomics and better visualization.

While results are preliminary and the experience too scarce to draw conclusions, the robotic transanal approach, hand in hand with its transabdominal counterpart, may gain popularity in the next decades and may prove a valid strategy in the local treatment of rectal GIST.

We envision that the role of minimally invasive surgery will continue to rise and that any new technological advance in minimally invasive rectal surgery will find its application in the treatment of rectal GIST. This will continue to go hand in hand with multimodal treatment, which allows the downstaging of larger lesions and lesions located near the anal sphincter, thus increasing the possibility of sphincter-saving procedures.

## Conclusions

The infrequency of rectal GISTs accounts for a lack of consensus on the gold standard of surgical treatment. Recent publications show promising results for the use of minimally invasive surgery, both transanal and transabdominal, with increasing reports of the safety and efficacy of TES, laparoscopy, and robotics, when performed by experienced surgeons.

## Acknowledgments

*Funding:* None.

## Footnote

*Provenance and Peer Review:* This article was commissioned

by the Guest Editor (Ferdinando Carlo Maria Cananzi) for the series “Minimally invasive approach in Gastrointestinal Stromal Tumors (GISTs)” published in *Laparoscopic Surgery*. The article has undergone external peer review.

*Reporting Checklist:* The authors have completed the Narrative Review reporting checklist. Available at <http://dx.doi.org/10.21037/ls-20-61>

*Conflicts of Interest:* All authors have completed the ICMJE uniform disclosure form (available at <http://dx.doi.org/10.21037/ls-20-61>). The series “Minimally invasive approach in Gastrointestinal Stromal Tumors (GISTs)” was commissioned by the editorial office without any funding or sponsorship. The authors have no other conflicts of interest to declare.

*Ethical Statement:* The authors are accountable for all aspects of the work in ensuring that questions related to the accuracy or integrity of any part of the work are appropriately investigated and resolved.

*Open Access Statement:* This is an Open Access article distributed in accordance with the Creative Commons Attribution-NonCommercial-NoDerivs 4.0 International License (CC BY-NC-ND 4.0), which permits the non-commercial replication and distribution of the article with the strict proviso that no changes or edits are made and the original work is properly cited (including links to both the formal publication through the relevant DOI and the license). See: <https://creativecommons.org/licenses/by-nc-nd/4.0/>.

## References

1. Cavnar MJ, Wang L, Balachandran VP, et al. Rectal Gastrointestinal Stromal Tumor (GIST) in the Era of Imatinib: Organ Preservation and Improved Oncologic Outcome. *Ann Surg Oncol* 2017;24:3972-80.
2. Kane WJ, Friel CM. Diagnosis and treatment of rectal gastrointestinal stromal tumors. Vol. 62, *Diseases of the Colon and Rectum*. Lippincott Williams and Wilkins, 2019:537-40.
3. Wilkinson MJ, Fitzgerald JEF, Strauss DC, et al. Surgical treatment of gastrointestinal stromal tumour of the rectum in the era of imatinib. *Br J Surg* 2015;102:965-71.
4. Shu P, Sun XF, Fang Y, et al. Clinical outcomes of different therapeutic modalities for rectal gastrointestinal stromal tumor: summary of 14-year clinical experience in a single



- center. *Int J Surg* 2020;77:1-7.
5. Jakob J, Mussi C, Ronellenfisch U, et al. Gastrointestinal stromal tumor of the rectum: Results of surgical and multimodality therapy in the era of imatinib. *Ann Surg Oncol* 2013;20:586-92.
  6. Vennix S, Pelzers L, Bouvy N, et al. Laparoscopic versus open total mesorectal excision for rectal cancer. Vol 2014, *Cochrane Database of Systematic Reviews*. John Wiley and Sons Ltd, 2014.
  7. Zheng J, Feng X, Yang Z, et al. The comprehensive therapeutic effects of rectal surgery are better in laparoscopy: A systematic review and meta-analysis. *Oncotarget* 2017;8:12717-29.
  8. Stevenson ARL, Solomon MJ, Brown CSB, et al. Disease-free Survival and Local Recurrence After Laparoscopic-assisted Resection or Open Resection for Rectal Cancer: The Australasian Laparoscopic Cancer of the Rectum Randomized Clinical Trial. *Ann Surg* 2019;269:596-602.
  9. Fleshman J, Branda M, Sargent DJ, et al. Effect of laparoscopic-assisted resection vs open resection of stage II or III rectal cancer on pathologic outcomes the ACOSOG Z6051 randomized clinical trial. *JAMA* 2015;314:1346-55.
  10. Du JL, Chen CC, Chao HM, et al. Robot-assisted intersphincteric resection for rectal submucosal tumour. *Int J Med Robot* 2016;12:478-82.
  11. Fujimoto Y, Akiyoshi T, Konishi T, et al. Laparoscopic sphincter-preserving surgery (intersphincteric resection) after neoadjuvant imatinib treatment for gastrointestinal stromal tumor (GIST) of the rectum. *Int J Colorectal Dis* 2014;29:111-6.
  12. Nakamura T, Ihara A, Mitomi H, et al. Gastrointestinal stromal tumor of the rectum resected by laparoscopic surgery: Report of a case. *Surg Today* 2007;37:1004-8.
  13. Søreide K, Sandvik OM, Søreide JA, et al. Global epidemiology of gastrointestinal stromal tumours (GIST): A systematic review of population-based cohort studies. *Cancer Epidemiol* 2016;40:39-46.
  14. Casali PG, Abecassis N, Bauer S, et al. Gastrointestinal stromal tumours: ESMO-EURACAN Clinical Practice Guidelines for diagnosis, treatment and follow-up. *Ann Oncol* 2018;29:iv68-78.
  15. Fletcher CDM, Berman JJ, Corless C, et al. Diagnosis of gastrointestinal stromal tumors: A consensus approach. *Hum Pathol* 2002;33:459-65.
  16. Kim E, Mayerson J, McCarter M, et al. National Comprehensive Cancer Network. *Soft Tissue Sarcoma (Version 1.2018)*. [published 31 October 2017, accessed 30 March 2020]. Available online: <https://nccn.org/wp-content/uploads/2018/03/NCCN-sarcoma-guidelines-for-physicians.pdf>
  17. Agaimy A, Vassos N, Märkl B, et al. Anorectal gastrointestinal stromal tumors: A retrospective multicenter analysis of 15 cases emphasizing their high local recurrence rate and the need for standardized therapeutic approach. *Int J Colorectal Dis* 2013;28:1057-64.
  18. Miettinen M, Lasota J. Gastrointestinal stromal tumors: review on morphology, molecular pathology, prognosis, and differential diagnosis. *Arch Pathol Lab Med* 2006;130:1466-78.
  19. Joensuu H. Risk stratification of patients diagnosed with gastrointestinal stromal tumor. *Hum Pathol* 2008;39:1411-9.
  20. McCarter MD, Antonescu CR, Ballman KV, et al. Microscopically positive margins for primary gastrointestinal stromal tumors: Analysis of risk factors and tumor recurrence. *J Am Coll Surg* 2012;215:53-9.
  21. Kosciński T, Mallinger S, Drews M. Local excision of rectal carcinoma not-exceeding the muscularis layer. *Colorectal Dis* 2003;5:159-63.
  22. Hellan M, Maker VK. Transvaginal excision of a large rectal stromal tumor: An alternative. *Am J Surg* 2006;191:121-3.
  23. Hara M, Takayama S, Arakawa A, et al. Transvaginal resection of a rectal gastrointestinal stromal tumor. *Surg Today* 2012;42:909-12.
  24. Shizhuo W, Liuyuan, Sha N, et al. Transvaginal excision of rectal stromal tumors: Case reports and a literature review. *World J Surg Oncol* 2019;17:164.
  25. Fu T, Liu B, Zhang L, et al. Outcome of transvaginal excision of large rectal adenomas. *Int J Colorectal Dis* 2005 Jul;20:334-7.
  26. Kinoshita H, Sakata Y, Umamo Y, et al. Perineal approach for a gastrointestinal stromal tumor on the anterior wall of the lower rectum. *World J Surg Oncol* 2014;12:62.
  27. Hamada M, Ozaki K, Horimi T, et al. Recurrent rectal GIST resected successfully after preoperative chemotherapy with imatinib mesylate. *Int J Clin Oncol* 2008;13:355-60.
  28. Tulina I, Kitsenko Y, Lukyano A, et al. Transperineal Excision of Rectal Gastrointestinal Stromal Tumor. *Surg Technol Int* 2019;34:195-8.
  29. Yasui M, Tsujinaka T, Mori M, et al. Characteristics and prognosis of rectal gastrointestinal stromal tumors: an analysis of registry data. *Surg Today* 2017;47:1188-94.

30. Liu H, Yan Z, Liao G, et al. Treatment strategy of rectal gastrointestinal stromal tumor (GIST). *J Surg Oncol* 2014;109:708-13.
31. Chen QF, Huang CM, Lin M, et al. Short-and Long-Term Outcomes of Laparoscopic Versus Open Resection for Gastric Gastrointestinal Stromal Tumors. *Medicine (Baltimore)* 2016;95:e3135.
32. Karakousis GC, Singer S, Zheng J, et al. Laparoscopic versus open gastric resections for primary gastrointestinal stromal tumors (GISTs): A size-matched comparison. *Ann Surg Oncol* 2011;18:1599-605.
33. Liang JW, Zheng ZC, Zhang JJ, et al. Laparoscopic versus open gastric resections for gastric gastrointestinal stromal tumors: A meta-analysis. *Surg Laparosc Endosc Percutan Tech* 2013;23:378-87.
34. El-Menyar A, Mekkodathil A, Al-Thani H. Diagnosis and management of gastrointestinal stromal tumors: An up-to-date literature review. *J Cancer Res Ther* 2017;13:889-900.
35. Buchs NC, Bucher P, Pugin F, et al. Robot-assisted oncologic resection for large gastric gastrointestinal stromal tumor: A preliminary case series. *J Laparoendosc Adv Surg Tech A* 2010;20:411-5.
36. Desiderio J, Trastulli S, Ciocchi R, et al. Robotic gastric resection of large gastrointestinal stromal tumors. *Int J Surg* 2013;11:191-6.
37. Badic B, Gancel CH, Thereaux J, et al. Surgical and oncological long term outcomes of gastrointestinal stromal tumors (GIST) resection- retrospective cohort study. *Int J Surg* 2018;53:257-61.
38. Cui JX, Gao YH, Xi HQ, et al. Comparison between laparoscopic and open surgery for large gastrointestinal stromal tumors: A meta-analysis. *World J Gastrointest Oncol* 2018;10:48-55.
39. Lian X, Feng F, Guo M, et al. Meta-analysis comparing laparoscopic versus open resection for gastric gastrointestinal stromal tumors larger than 5 cm. *BMC Cancer* 2017;17:760.
40. Xiong H, Wang J, Jia Y, et al. Laparoscopic surgery versus open resection in patients with gastrointestinal stromal tumors: An updated systematic review and meta-analysis. *Am J Surg* 2017;214:538-46.
41. Inaba CS, Dosch A, Koh CY, et al. Laparoscopic versus open resection of gastrointestinal stromal tumors: survival outcomes from the NCDB. *Surg Endosc* 2019;33:923-32.
42. Somu K, Dashore A, Shah A, et al. Laparoscopic excision of large lower rectal gastrointestinal stromal tumour (GIST): A case report. *J Minim Access Surg* 2016;12:283-5.
43. Han X, Xu J, Qiu H, et al. A Novel Curative Treatment Strategy for Patients with Lower Grade Rectal Gastrointestinal Stromal Tumor: Chemoreduction Combined with Transanal Endoscopic Microsurgery. *J Laparoendosc Adv Surg Tech A* 2017;27:579-85.
44. Wu X, Lin G, Qiu H, et al. Transanal endoscopic microsurgery for local excision of rectal gastrointestinal stromal tumors. *Zhonghua Wei Chang Wai Ke Za Zhi* 2018;21:1296-300.
45. Liu Q, Zhong G, Zhou W, et al. Initial application of transanal endoscopic microsurgery for high-risk lower rectal gastrointestinal stromal tumor after imatinib mesylate neoadjuvant chemotherapy. *Medicine (Baltimore)* 2017;96:e7538.
46. Eldamshety O, Metwally IH, Ghoneem E, et al. Resection of rectal GIST using a novel technique: a report of two cases. *Ecancermedalscience* 2017;11:760.
47. Quaresima S, Balla A, Franceschilli L, et al. Transanal minimally invasive surgery for rectal lesions. *JLS* 2016;20:1-6.
48. Pintor-Tortolero J, García JC, Cantero R. Transanal minimally invasive surgery approach for rectal GIST. *Tech Coloproctol* 2016;20:321-2.
49. Nepal P, Mori S, Kita Y, et al. Management of a case of high-risk gastrointestinal stromal tumor in rectum by transanal minimal invasive surgery. *World J Surg Oncol* 2018;16:165.
50. Spinelli A, Carvello M, Sacchi M, et al. Transanal minimally invasive surgery (TAMIS) for anterior rectal GIST. *Tech Coloproctol* 2019;23:501-2.
51. Wachter N, Wörns MA, dos Santos D, et al. Transanal minimally invasive surgery (TAMIS) approach for large juxta-anal gastrointestinal stromal tumour. *J Minim Access Surg* 2016;12:289.
52. Paull JO, Pudalov N, Obias V. Medrobotics Flex transanal excision of a rectal gastrointestinal stromal tumour: first video of the transanal Flex robot used in a human—a video vignette. *Colorectal Dis* 2018;20:1048-9.
53. Tomassi MJ, Taller J, Yuhan R, et al. Robotic transanal minimally invasive surgery for the excision of rectal neoplasia: Clinical experience with 58 consecutive patients. *Dis Colon Rectum* 2019;62:279-85.
54. Atallah S, Albert M, De Beche-Adams T, et al. Transanal minimally invasive surgery (TAMIS): Applications beyond local excision. *Tech Coloproctol* 2013;17:239-43.
55. Nieuwenhuis DH, Draaisma WA, Verberne GHM, et al.

- Transanal endoscopic operation for rectal lesions using two-dimensional visualization and standard endoscopic instruments: A prospective cohort study and comparison with the literature. *Surg Endosc* 2009;23:80-6.
56. Liu S, Suzuki T, Murray BW, et al. Robotic transanal minimally invasive surgery (TAMIS) with the newest robotic surgical platform: a multi-institutional North American experience. *Surg Endosc* 2019;33:543-8.
57. Medina MG, Tsoraides SS, Dwyer AM. Review and update: robotic transanal surgery (RTAS). Vol. 70, *Updates in Surgery*. Springer-Verlag Italia s.r.l., 2018:369-74.

doi: 10.21037/ls-20-61

**Cite this article as:** Maspero M, Crippa J, Giani A, Rubicondo C, Carnevali P, Origi M, Mazzola M, Bertoglio CL, Ferrari G, Magistro C. Current scenario and future perspectives of minimally invasive approaches in rectal gastrointestinal stromal tumours. *Laparosc Surg* 2021;5:45.