



# A systematic review of clinically available and experimental dyes for intraoperative near-infrared fluorescence imaging of the ureters during laparoscopic surgery

Robin A. Faber<sup>1</sup>, Floris P. R. Verbeek<sup>1</sup>, Kim S. de Valk<sup>1</sup>, Jacobus Burggraaf<sup>1,2</sup>, Alexander L. Vahrmeijer<sup>1</sup>, J. Sven D. Mieog<sup>1</sup>

<sup>1</sup>Department of Surgery, Leiden University Medical Center, Leiden, The Netherlands; <sup>2</sup>Centre for Human Drug Research, Leiden, The Netherlands

*Contributions:* (I) Conception and design: RA Faber, JSD Mieog; (II) Administrative support: RA Faber; (III) Provision of study materials or patients: RA Faber; (IV) Collection and assembly of data: RA Faber, FPR Verbeek, KS de Valk; (V) Data analysis and interpretation: RA Faber, JSD Mieog; (VI) Manuscript writing: All authors; (VII) Final approval of manuscript: All authors.

*Correspondence to:* Dr. J. Sven D. Mieog. Albinusdreef 2, 2333 ZA Leiden, The Netherlands. Email: j.s.d.mieog@lumc.nl.

**Background:** Iatrogenic ureteral injury is a rare but serious complication during laparoscopic abdominopelvic surgery. Preoperative ureteral stent placement can facilitate intraoperative identification of the ureters. However, even with ureteral stents, visualization of ureters during laparoscopic abdominopelvic surgery can be challenging due to their retroperitoneal location and, particularly during robot-assisted surgery, the lack of tactile feedback. Recently, the use of near-infrared (NIR) fluorescence imaging showed to be a good non-invasive alternative for intraoperative ureter identification. The aim of this review is to provide an overview of current clinically available contrast agents for NIR fluorescence imaging of the ureters during laparoscopic surgery and also focuses on novel experimental dyes.

**Methods:** A systematic literature search was performed in the PubMed database. Data were extracted from eligible papers and reported based on the Preferred Reporting Items for Systematic reviews and Meta-Analyses (PRISMA). Clinically relevant information focusing on the clinical use of NIR fluorescence imaging for ureter identification during laparoscopic surgery was reviewed.

**Results:** The search identified a total of 149 articles. Of these, 9 articles met our eligibility criteria and formed the basis of this review. The feasibility of two current clinically available contrast agents, methylene blue (MB) and indocyanine green (ICG), and two experimental dyes, ZW800-1 and IS-001, were evaluated for NIR fluorescence imaging of the ureters during laparoscopic abdominopelvic surgery in human.

**Conclusions:** The current clinically available dyes, MB and ICG, are less applicable for NIR fluorescence imaging of the ureters during laparoscopic surgery. Based on their properties, MB is preferred over ICG but has its limitations. ZW800-1, on the other hand, is a promising fluorescent contrast agent for ureter visualization. In the future, larger clinical trials are needed to assess the benefit of intraoperative NIR fluorescence imaging on iatrogenic ureteral injury.

**Keywords:** Near-infrared (NIR); fluorescence; ureter visualization; methylene blue (MB); indocyanine green (ICG); zwitterionic

Received: 14 July 2020; Accepted: 06 November 2020; Published: 25 January 2021.

doi: 10.21037/ls-20-111

View this article at: <http://dx.doi.org/10.21037/ls-20-111>

## Introduction

Iatrogenic ureteral injury during laparoscopic abdominopelvic surgery is rare, but consequences of such injury are serious and can lead to increased postoperative mortality, morbidity, hospital stay and health costs (1). During laparoscopic colorectal cancer surgery, the incidence of iatrogenic ureteral injury varies from 0.5% to 1% and increases up to 10% in advanced gynecologic oncologic procedures. When ureteral damage occurs, it should be explored intraoperatively to allow immediate repair to reduce long-term morbidity and to preserve renal function. Unfortunately, ureteral damage is often missed during surgery, which can result in several severe complications, such as urinomas, abscesses, fistulae and permanent renal compromise (2-4).

To reduce the risk of iatrogenic ureteral injury, double-J stents or even lighted ureteral stents can be placed into the ureter preoperatively. This way, the stents can be palpated or visualized during surgery (5). However, preoperative placement of ureteral stents is an invasive procedure that is associated with increased time of anesthesia and an increased risk of complications, such as ureteral perforation, urinary tract infection, postoperative hematuria or acute renal failure (6). In addition, during minimal invasive surgery there is a lack of tactile feedback which makes identifying the ureters a bit more challenging. Alternatives for intraoperative ureter visualization, such as near-infrared (NIR) fluorescence imaging, could therefore be beneficial.

Recently, NIR fluorescence imaging has evolved rapidly and offers real-time visualization of specific structures or tissues, such as tumors, lymph nodes, blood vessels, nerves, biliary duct and ureters during surgery. One of the main advantages of NIR light (700–900 nm) is its capability to penetrate up to 10 millimeters deeper into tissue, when compared to visible light (7,8). Additionally, the NIR spectrum exhibits almost no autofluorescence and therefore, using NIR fluorescent contrast agents, high signal-to-background ratios (SBR) can be achieved, creating contrast between different tissue types (9). Various types of contrast agents have been evaluated (pre)clinically using NIR fluorescence imaging. Only two of these contrast agents, namely methylene blue (MB) and indocyanine green (ICG), are approved for clinical use by the Food and Drug Administration (FDA) and the European Medicines Agency (EMA).

This review provides an overview of current clinically available contrast agents for NIR fluorescence imaging of the ureters during laparoscopic surgery and also focuses on

experimental dyes that have been investigated in first-in-human trials. We present the following article in accordance with the PRISMA reporting checklist (available at <http://dx.doi.org/10.21037/ls-20-111>).

## Methods

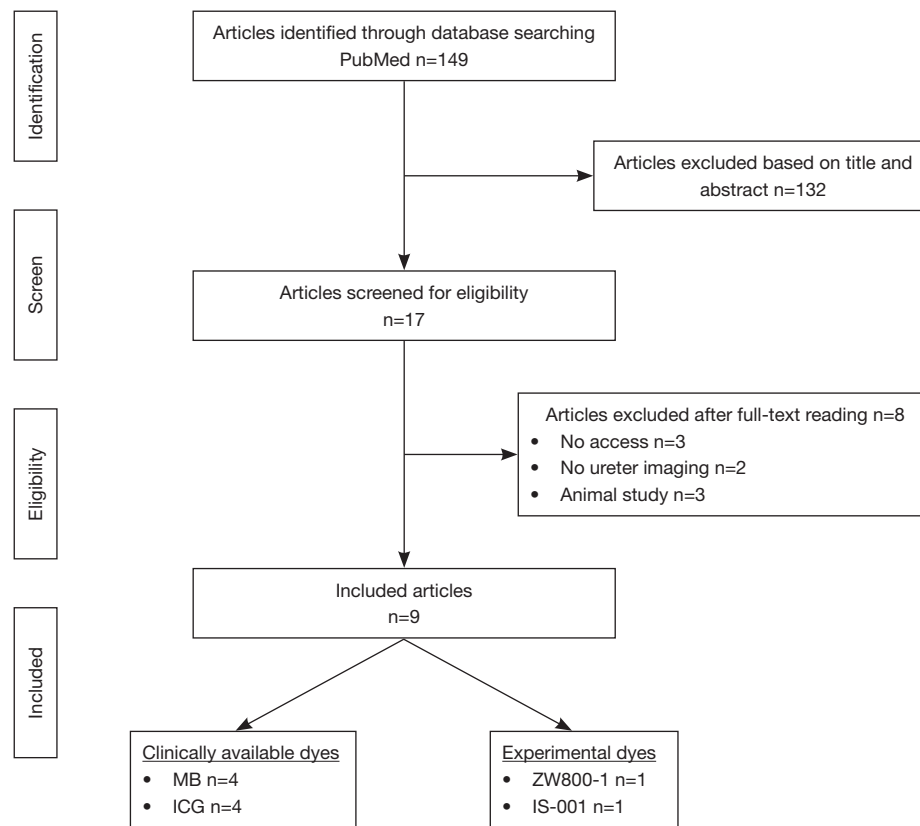
A PubMed search was performed to collect clinical trials using a fluorescent contrast agent for NIR fluorescence imaging of the ureters during laparoscopic surgery published before June 2020. The search was based on the following search items: (“ureter” or “ureteral”) and (“fluorescence” or “fluorescent” or “near-infrared” or “NIR” or “NIR fluorescence imaging” or “near-infrared fluorescence imaging”). To be included in the analysis, articles had to be written in English, available in full-text and presenting original data of NIR ureter visualization in humans. Case reports and (systematic) reviews were excluded from the analysis. After selection of relevant articles, based on the eligibility criteria as described above, clinically relevant information focusing on the clinical use of NIR fluorescence imaging for ureter identification during laparoscopic surgery was extracted from the articles for a review. This systematic review was reported in accordance with the guidelines from the Preferred Reporting Items for Systematic reviews and Meta-Analysis (PRISMA) group (10).

## Results

The search identified 149 articles of which 132 articles were excluded based on title and abstract and another 8 articles were excluded after full-text reading. A total of 9 articles met our eligibility criteria and formed the basis of this review (*Figure 1*). An overview of the included articles is shown in *Table 1*.

### MB

Four studies evaluated the use of MB as a contrast agent for NIR ureter visualization in humans (12-15). MB is considered a suitable compound as it is mainly cleared by the kidneys and therefore administered intravenously in doses ranging from 0.25–1.0 mg/kg (MB concentration 10 mg/mL in most studies). The administration time varied from 40 minutes before introduction of the first trocar to 15 minutes prior to the surgeon entering the lower pelvis



**Figure 1** A PRISMA flow-chart of the literature search strategy. PRISMA, Preferred Reporting Items for Systematic reviews and Meta-Analyses; MB, methylene blue; ICG, indocyanine green.

(12,13). Ureter fluorescence was commonly detected 10 to 20 minutes after MB administration with the longest fluorescence signal lasting 2 hours and 5 minutes post injection (13-15). Verbeek *et al.* (14) showed that in all 12 patients undergoing open surgery both ureters could be detected clearly 10 minutes after MB injection when imaged with the Mini-FLARE<sup>®</sup> imaging system (*Figure 2*). The highest signal-to-background ratio (SBR) was observed in patients who received 1.0 mg/kg MB. However, in patients who received 0.25 mg/kg MB, the SBR (mean SBR of 2.27) was amply sufficient for early identification of the ureters and would therefore be recommended as the optimal dose during open surgery. During laparoscopic abdominal surgery, in 50% to 95% of the patients, the ureters were detected when imaged with the Karl Storz, PINPOINT or an internally developed imaging system capable of fluorescence imaging at  $\pm 700$  nm (12,13,15). The highest SBR (mean SBR ranging from 2.74 to 5.29) was obtained using a dose ranging from 0.75–1.0 mg/kg and therefore

seems to be the optimal dose during minimal invasive surgery. No adverse events related to the use of MB were reported.

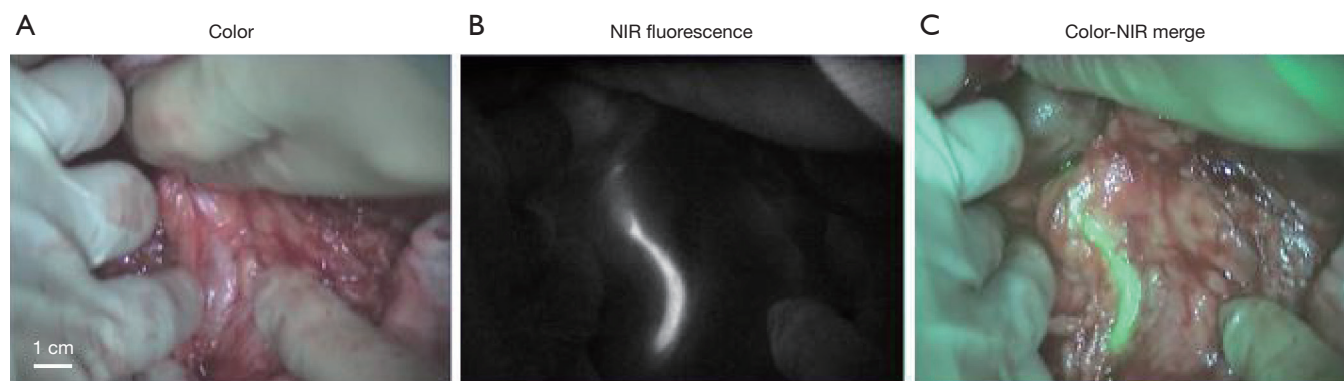
### ICG

ICG has a hepatic-exclusive clearance pattern and can therefore not be used as an intravenous contrast agent for NIR ureter visualization. However, it is possible to highlight the ureters by injecting ICG directly into the ureters. Three studies investigated the feasibility of this approach (16-18). Siddighi *et al.* (16) evaluated the method for ureter visualization during laparoscopic sacrocolpopexy, Lee *et al.* (17) evaluated the use during robot-assisted ureteroureterostomy, and Morozov *et al.* (18) evaluated the technique during open urethroplasty. In these studies, ICG was administered by injecting 10 mL of ICG (concentration 2.5 mg/mL) through a 6-french catheter into the ureter during cystoscopy. In patients with a nephrostomy tube,

**Table 1** Results of studies using clinically available- and experimental dyes for NIR fluorescence imaging of the ureter in human (11)

Dye	Article	Surgical specialism	Surgical approach <sup>a</sup>	Number of patients	Administration	Dose	Ureter identification
Methylene blue	Al-TaHER <i>et al.</i> (12)	Colorectal	Laparoscopic	9 <sup>b</sup>	Intravenous	0.125–1.0 mg/kg	6/9
	Barnes <i>et al.</i> (13)	Colorectal	Both	40	Intravenous	0.25–1.0 mg/kg <sup>c</sup>	64/69 <sup>d</sup>
	Verbeek <i>et al.</i> (14)	Abdominal	Open	12	Intravenous	0.25–1.0 mg/kg	24/24
	Yeung <i>et al.</i> (15)	Colorectal	Both	8	Intravenous	0.25–1.0 mg/kg	10/11
Indocyanine green	Siddighi <i>et al.</i> (16)	Gynaecology	Laparoscopic	>10	UC <sup>e</sup>	10 mL of 2.5 mg/mL	All
	Lee <i>et al.</i> (17)	Urology	Laparoscopic	7	UC /PNT <sup>f</sup>	10 mL of 2.5 mg/mL	All
	Morozov <i>et al.</i> (18)	Urology	Open	1	Renal pelvis <sup>g</sup>	4 mL of 2.5 mg/mL	All
ZW800-1	de Valk <i>et al.</i> (19)	Abdominal	Laparoscopic	12	Intravenous	1.0–5.0 mg	All
IS-001	Farnam <i>et al.</i> (20)	Gynaecology	Laparoscopic	24	Intravenous	10–40 mg	16/24 <sup>f</sup>

<sup>a</sup>, surgical approach: open, laparoscopic or both. <sup>b</sup>, a total of ten patients were included in this study. In one of these patients, conversion to an open procedure was performed before NIR fluorescence imaging of the ureter take place and was therefore excluded from the study. <sup>c</sup>, 5 mg/mL methylene blue. All other studies used a concentration of 10 mg/mL methylene blue. <sup>d</sup>, of all ureters, 59/63 ureters were identified during laparoscopic surgery and 5/6 ureter were identified during an open procedure. <sup>e</sup>, UC: retrograde injection of ICG through a ureteral catheter, PNT: antegrade injection of ICG though a percutaneous nephrostomy tube, renal pelvis: direct injection of ICG into the renal pelvis. <sup>f</sup>, all ureters were visible 10 minutes after intravenous administration, but a difference in signal intensity was observed (ranging from weak up to strong). A strong signal intensity was only observed in 16 of the 24 patients. ICG, indocyanine green; NIR, near-infrared.



**Figure 2** NIR ureter visualization during lower abdominal surgery. Ureter imaging 15 minutes after intravenous injection of 0.5 mg/kg MB using the Mini-FLARE<sup>®</sup> imaging system. (A) White light view, (B) NIR fluorescence imaging mode, (C) color-NIR overlay (white light view and NIR fluorescence mode were merged with the fluorescence signal in the color green). NIR, near-infrared; MB, methylene blue.

half of the ICG solution was injected antegrade through the nephrostomy tube. After administration, the urinary catheter was clamped to minimize drainage of ICG (16,17). All studies observed clear visualization of the ureters with NIR light. However, none of the studies specified the fluorescence intensity expressed in SBR nor the duration of fluorescence imaging. Adverse events, related to the use of

ICG or catheter placement were not reported.

### Experimental dyes

Recently, research focused on dyes with renal-exclusive clearance that can be injected intravenously for NIR ureter imaging. These experimental dyes include ZW800-1

and IS-001 which were investigated in first-in-human trials (19,20).

### ZW800-1

ZW800-1 is a self-shielding zwitterionic NIR fluorophore that exhibits lower non-specific binding and tissue uptake *in vivo* after intravenous administration, when compared to conventional NIR fluorophores, such as ICG (21). ZW800-1 is characterized by its renal-exclusive clearance with elimination from the body into urine. de Valk *et al.* (19) was the first who evaluated the utility of ZW800-1 in visualizing and assessing ureter structure and function during laparoscopic abdominal surgery in human. During surgery, ZW800-1 was administered intravenously once the surgeon identified the location of the ureters under white light, either fully exposed or still covered by peritoneum and retroperitoneal fat. The administered doses were 1.0, 2.5 or 5.0 mg ZW800-1, respectively. In all 12 patients, both ureters became fluorescent within 10 minutes after administration and could be imaged with various commercial imaging systems, including the Olympus®, the da Vinci® robot, and the FLARE® MIS system. High SBRs (2.3 and 2.7) were measured in the first hour after administration of 1.0 and 2.5 mg ZW800-1, respectively (Figure 3). In the second hour the signal intensity of 2.5 mg ZW800-1 was considerably stronger when compared to 1.0 mg ZW800-1 (SBR of 2.1 *vs.* 1.4). In patients who received 5.0 mg ZW800-1, a significantly lower SBR was measured within the first hour after administration compared to 2.5 mg (1.6 *vs.* 2.7) and 1.0 mg ZW800-1 (1.6 *vs.* 2.3). In these patients, background fluorescence was more pronounced in the surrounding tissue, organs (i.e., colon), and major blood vessels. Furthermore, this study showed that ZW800-1 allows real-time assessment of ureter structure and function as it also visualized ureter motility and patency due to ureter pulsations. No adverse events, related to ZW800-1, were reported and pharmacokinetic analysis showed the administered doses (ranging from 0.5–5.0 mg) were safe and well tolerated.

### IS-001

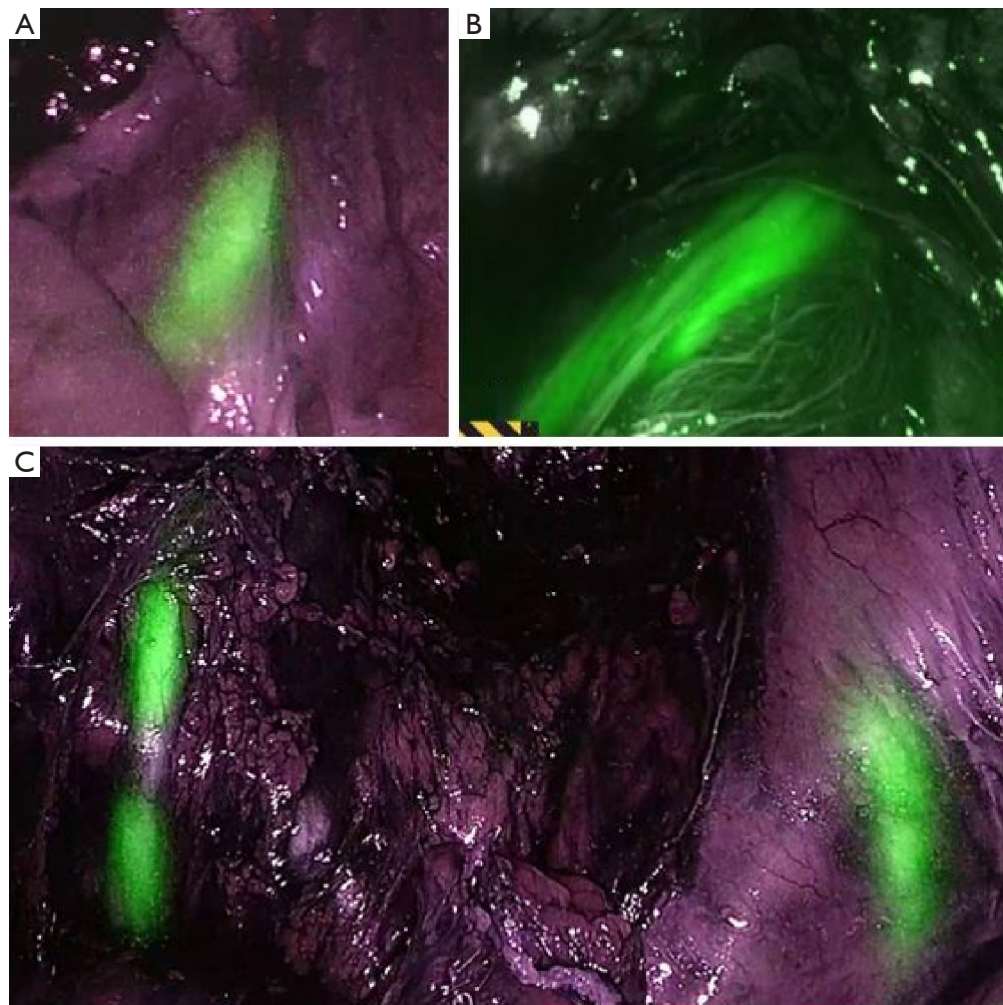
The utility of IS-001 for ureter visualization in humans has been investigated by Farnam *et al.* (20) In this study, NIR fluorescence imaging of the ureters was evaluated in 24 women during a robot-assisted minimally-invasive hysterectomy. Patients received an intravenous dose of 10, 20 or 40 mg IS-001 before the robotic endoscope was inserted into the abdomen. After administration,

fluorescence of the ureters was observed in all patients when imaged with the da Vinci® Surgical System Firefly® imaging system (Figure 4). The strongest signal was observed 10 minutes after patients received 40 mg IS-001 and was therefore considered the optimal dose for ureter visualization. However, the signal intensity decreased rapidly over time. After 60 minutes post injection (or last possible time-point if the operating time was less than 60 minutes), a high fluorescent intensity was observed in only one of the eight patients who received 40 mg IS-001 and in none of the patients who received 10 or 20 mg IS-001. No adverse events, related to IS-001, were reported during the study. Moreover, pharmacokinetic analysis also showed that intravenous administration of IS-001 up to 40 mg was safe and well tolerated.

### Discussion

Identifying the ureters during laparoscopic abdominopelvic surgery can be challenging due to their retroperitoneal location and lack of tactile feedback during minimal invasive surgery. One method to help visualize the ureters during surgery, is the use of ureteral stents which can be placed into the ureter preoperatively. However, this conventional technique is relatively invasive and is associated with high risk of complications (6). Intraoperative NIR fluorescence imaging provides a non-invasive alternative for safe intraoperative ureter detection. This systematic review provides an overview of current clinically available fluorescent contrast agents that enable NIR fluorescence imaging of the ureters during laparoscopic surgery and also focuses on novel experimental NIR dyes.

MB and ICG are at present the only available fluorescent contrast agents approved for clinical use. Several studies have shown that MB is a safe and feasible contrast agent for ureter visualization, as it is mainly cleared by the kidneys. However, when MB is compared to the other investigated dyes in this review, it is not the most optimal agent for NIR ureter visualization. MB has a peak emission of 700 nm, which is known to cause higher tissue autofluorescence and reduced penetration capacity (12-14). ICG, on the other hand, has its limitations as well for the use in ureter visualization. This agent was approved in 1958 as a dye to determine cardiac output, hepatic blood flow and function, and ophthalmic angiography. ICG has a peak emission of 820 nm and is therefore a well suited fluorescent contrast agent for NIR fluorescence imaging in general (17,22). Yet, for intraoperative ureter visualization, ICG is the least

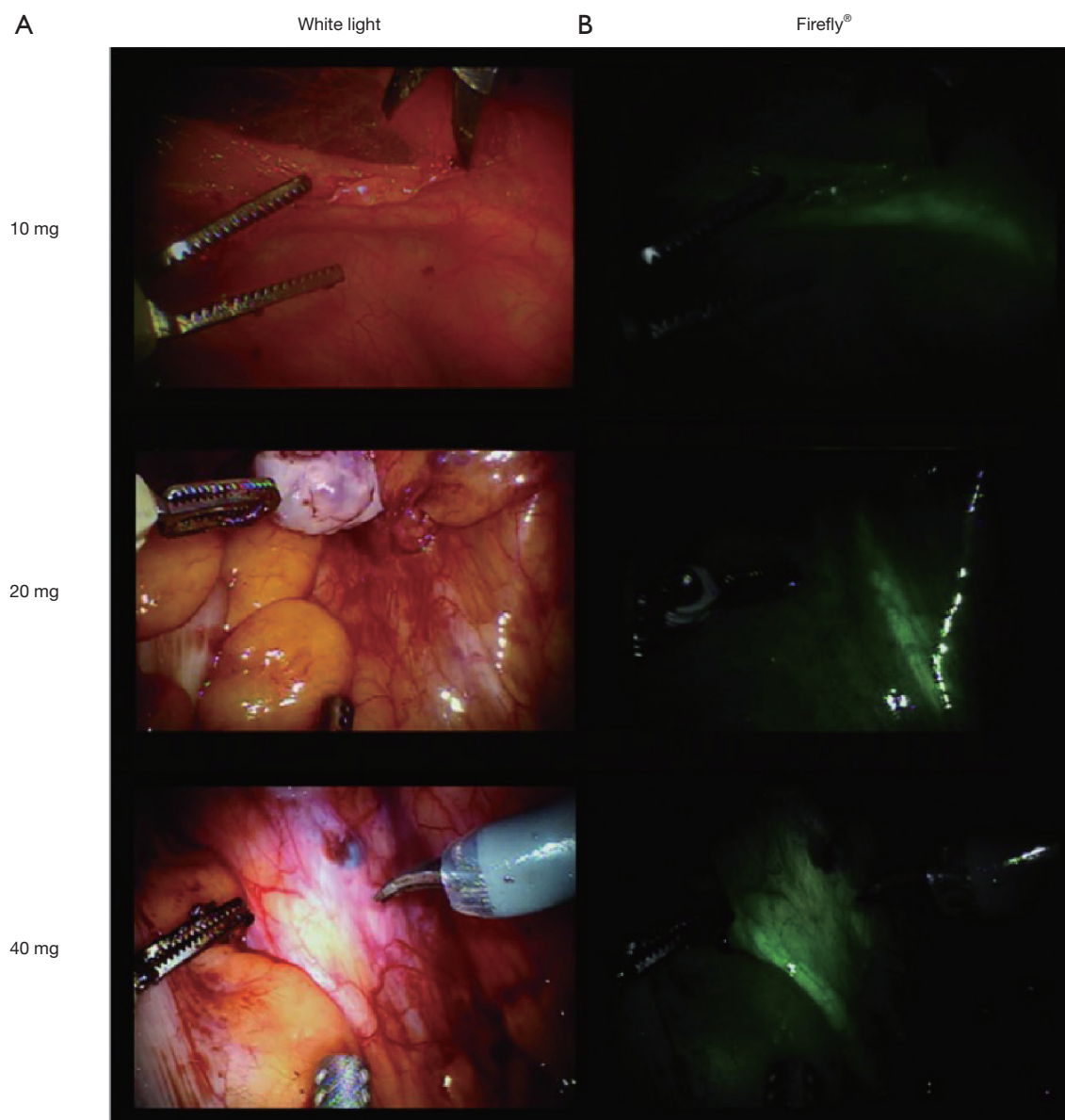


**Figure 3** High fluorescence intensity with precise structural delineation of the ureters during laparoscopic abdominopelvic surgery. Ureter imaging 45 minutes after intravenous injection of ZW800-1. (A) Ureter fluorescence after administration of 1.0 mg ZW800-1 using the Olympus® imaging system, (B,C) ureter(s) fluorescence after administration of 2.5 mg ZW800-1 using the da Vinci® robot Firefly® imaging system (B) or the Olympus® imaging system (C).

applicable due to pharmacological properties. Because of its hepatic clearance it needs to be injected directly into the ureters to enable ureter visualization. Therefore, based on fluorescent properties and clearance pattern, MB is preferred over ICG for ureter visualization, but is still not optimal due to its previously described limitations. This creates a need for developing novel improved imaging agents with features such as renal-exclusive clearance, low background fluorescence from surrounding tissue, and long duration of visualization after low dose administration.

ZW800-1 and IS-001 are the first experimental dyes with a selectively renal clearance pattern, that have been

investigated in humans. de Valk *et al.* (19) showed that ZW800-1 provides a large safety window in which a single low dose of ZW800-1 (1.0–2.5 mg) is sufficient for intraoperative ureter visualization and real-time assessment of ureter function, even with overlying tissue, permitting precise structural ureter delineation for a period of at least two hours after administration. Moreover, it works on most available commercial imaging systems (e.g., Olympus®, the da Vinci® robot, Stryker® and the FLARE® MIS system). In addition, Farnam *et al.* (20) investigated the use of IS-001 and showed that the compound is apparently safe and observed the strongest fluorescent signal after an injection



**Figure 4** NIR fluorescence imaging of the ureters during robot-assisted hysterectomy. Ureter imaging 20 minutes after intravenous injection of 10, 20, or 40 mg IS-001. (A) White light images per dose, (B) Firefly® NIR fluorescence images per dose. IS-001 excitation and emission wavelength: 780 and 815 nm (20). NIR, near-infrared.

of the highest dose of 40 mg IS-001 when imaged with the da Vinci® Surgical System's Firefly® setting. The duration of the signal strength was shorter compared to ZW800-1 with a decrease in signal intensity already noted at 30 minutes after injection of 40 mg IS-001. This suggests that ZW800-1 has more favorable properties compared to IS-001.

Besides better ureter visualization, a major advantage of ZW800-1 is its endless conjugation possibilities to

ligands or peptides to create tumor-targeted agents, enabling simultaneous ureter and tumor tissue detection, as was shown (pre)clinically (23,24). de Valk *et al.* (24) demonstrated the successful clinical application of such a novel fluorescent contrast agent, cRGD-ZW800-1, in patients. It was shown that tumor tissue was visible after an injection of the highest dose cRGD-ZW800-1 (0.05 mg/kg) and ureters could be visualized in all doses ranging from

**Table 2** Results of preclinical studies that investigated the utility of experimental dyes for ureter visualization in animals. In addition, the pharmacokinetic properties (i.e., clearance pattern, excitation and emission) of the experimental dyes have been described (11)

Dye	Article	Number of animals	Dose (IV <sup>a</sup> , mg/kg)	Duration of visualization	Clearance	Excitation (nm)	Emission (nm)	Ongoing clinical trial
IRDye-CW800	Korb <i>et al.</i> (25)	6 pigs	0.03–0.12	60 min <sup>b</sup>	Liver and kidneys	774	789	Unknown
	Tanaka <i>et al.</i> (26)	12 rats	0.0015–0.015	30 min <sup>b</sup>				
		6 pigs	0.0075–0.015	30 min <sup>b</sup>				
	Schols <i>et al.</i> (27)	2 pigs	0.007–0.086	120 min <sup>b</sup>				
UreterGlow	Mahalingam <i>et al.</i> (28)	5 pigs	0.01	>2 hours	Liver and kidneys	800	830	Unknown
IRDye-800BK	van den Bos <i>et al.</i> (29)	3 pigs	0.15	3.5 hours	Primarily kidneys	774	790	NCT03387410; NCT03106038
UL-766	Cha <i>et al.</i> (30)	8 rats	.09	>60 min	Kidneys	± 800	± 800	Unknown
	Lau <i>et al.</i> (31)	2 pigs	0.12	>4 hours				
Liposomal ICG	Portnoy <i>et al.</i> (32)	25 mice	8	>120 min	Liver and kidneys	780	800	Unknown
	Friedman-Levi <i>et al.</i> (33)	>12 mice	8	–				
			2 pigs	1	>90 min			
Sodium fluorescein	Dip <i>et al.</i> (34)	9 rats	7	<12 hours	Liver and kidneys	465	530	Unknown

<sup>a</sup>, IV: intravenous; <sup>b</sup>, last time-point for measuring the fluorescence intensity of the ureters.

0.005–0.05 mg/kg when administered 2 to 4 hours prior to surgery.

Other experimental dyes have been investigated preclinically only (Table 2). These novel dyes have been described in a systematic review recently (11). Previous studies showed that intravenously administered IRDye-CW800 and UreterGlow can be used to visualize ureters intraoperatively in rats and pigs. However, these fluorescent contrast agents are mainly cleared by the liver and will conceivably result in more background fluorescence (25–28). In addition, IRDye-800BK and IRDye-800NOS were developed as a sequel to IRDye-CW800. van den Bos *et al.* (29) showed a higher tumor-background-ratio (TBR) when using IRDye-800BK compared to IRDye-CW800 (TBR of 2.14 versus 1.44), which is logical as IRDye-800BK is mainly cleared by the kidneys. Currently, IRDye-800BK is undergoing clinical translation in multiple studies (NCT03387410) and (NCT03106038). Two studies have evaluated the dye UL-766, which is an exclusive renally cleared dye like ZW800-1 and IS-001, for the fluorescence imaging of the ureters in rats and pigs (30,31). After intravenous administration, results showed a signal intensity, expressed as contrast-background-ratio (CBR), twice as high

compared to IRDye-CW800. Based on its properties, UL-766 appears to be a promising fluorescent contrast agent for ureter visualization. Furthermore, Portnoy *et al.* (35) described a liposomal formulation in which ICG is passively absorbed to liposomes. This formulation results in an increased renal ICG clearance, allowing visualization of the ureters. Two studies described fluorescence of the ureters in mice and pigs after intravenous injection (32,33). However, liposomal ICG is still partially excreted by the liver, resulting in relatively bright background from surrounding tissue. In addition, liposomal formulations are frequently associated with adverse events in humans (36,37). Finally, Dip *et al.* (34) demonstrated ureter visualization by injecting intravenous sodium fluorescein in rats. However, fluorescence of the ureters was observed in a 530 nm wavelength mode, which is in the visible light spectrum and could therefore interfere with the surgical field.

This review describes the feasibility of current clinically available and novel contrast agents for NIR fluorescence imaging of the ureters during laparoscopic abdominopelvic surgery. The pertaining literature is still scarce as to date only nine papers are available with a limited number of included patients. Therefore no firm conclusions can



be drawn about the effect of intraoperative use of NIR fluorescence imaging of the ureters on the incidence of iatrogenic ureteral injury. Notwithstanding, it appears that from the currently approved contrast agents both have some merit with MB outperforming ICG. However, it is also clear that substantial improvement is possible and the most likely candidate appears to be ZW800-1. These improvements are highly needed as the application of robot-assisted surgery will increase because of the well documented advantages, such as greater precision, miniaturization of instruments, smaller incision, and enhanced vision, compared to laparoscopic surgery (38,39). The expansion of robot-assisted surgery in all surgical fields could be assisted by application of NIR fluorophores, which will obviously require larger patient studies.

In addition, the currently available camera systems (i.e., the Olympus<sup>®</sup>, the da Vinci<sup>®</sup> robot Firefly<sup>®</sup> and the FLARE<sup>®</sup> MIS system) are well developed for accurate NIR fluorescence imaging of the ureters during laparoscopic surgery as shown in this review. Ongoing phase 3 multicenter clinical trials, such as AVOID (Trial NL7502) and SGM-101 (NCT03659448), have been set up to improve the technique of NIR fluorescence imaging even more and evaluate the wide use during perfusion surgery and colorectal tumor detection. At this moment, one of the main hurdles is that not all hospitals have a camera system that enables NIR fluorescence imaging. Buying such camera systems is expensive, but on the other hand a one-time purchase. For instance, since Firefly<sup>®</sup> imaging system is introduced in the da Vinci<sup>®</sup> robot, no addition costs other than purchasing the NIR fluorophore must be incurred to allow intraoperative NIR fluorescence imaging. The absolute price of these NIR fluorophores is determined by the companies themselves, but does not have to be that expensive. This will make intraoperative NIR fluorescence imaging an affordable support for visualization of specific structures, such as ureters, during minimal invasive surgery in the future.

## Conclusions

The current clinically available dyes, MB and ICG, are not the most optimal contrast agents for NIR fluorescence imaging of the ureters during laparoscopic surgery, due to their sub-optimal fluorescent properties and clearance pattern. ZW800-1, on the other hand, has a renal-exclusive clearance and greater fluorescent properties making it

an encouraging fluorescent contrast agent for ureter visualization. To assess the benefit of intraoperative use of NIR fluorescence imaging on the incidence of iatrogenic ureteral injury, larger clinical trials are needed.

## Acknowledgments

*Funding:* None.

## Footnote

*Provenance and Peer Review:* This article was commissioned by the Guest Editors (Hendrik A. Marsman and Mark C. Boonstra) for the series “Clinical Applications of Fluorescence Imaging in Laparoscopic Surgery” published in *Laparoscopic Surgery*. The article has undergone external peer review.

*Reporting Checklist:* The authors have completed the PRISMA reporting checklist. Available at <http://dx.doi.org/10.21037/ls-20-111>

*Conflicts of Interest:* All authors have completed the ICMJE uniform disclosure form (available at <http://dx.doi.org/10.21037/ls-20-111>). The series “Clinical Applications of Fluorescence Imaging in Laparoscopic Surgery” was commissioned by the editorial office without any funding or sponsorship. The authors have no other conflicts of interest to declare.

*Ethical Statement:* The authors are accountable for all aspects of the work in ensuring that questions related to the accuracy or integrity of any part of the work are appropriately investigated and resolved. This article does not contain any studies with human participants or animals performed by any of the authors. Informed consent was not required.

*Open Access Statement:* This is an Open Access article distributed in accordance with the Creative Commons Attribution-NonCommercial-NoDerivs 4.0 International License (CC BY-NC-ND 4.0), which permits the non-commercial replication and distribution of the article with the strict proviso that no changes or edits are made and the original work is properly cited (including links to both the formal publication through the relevant DOI and the license). See: <https://creativecommons.org/licenses/by-nc-nd/4.0/>.

## References

- Douissard J, Ris F, Morel P, et al. Current Strategies to Prevent Iatrogenic Ureteral Injury During Colorectal Surgery. *Surg Technol Int* 2018;32:119-24.
- Delacroix SE Jr, Winters JC. Urinary tract injuries: recognition and management. *Clin Colon Rectal Surg* 2010;23:104-12.
- Andersen P, Andersen LM, Iversen LH. Iatrogenic ureteral injury in colorectal cancer surgery: a nationwide study comparing laparoscopic and open approaches. *Surg Endosc* 2015;29:1406-12.
- Lee Z, Kaplan J, Giusto L, et al. Prevention of iatrogenic ureteral injuries during robotic gynecologic surgery: a review. *Am J Obstet Gynecol* 2016;214:566-71.
- Chahin F, Dwivedi AJ, Paramesh A, et al. The implications of lighted ureteral stenting in laparoscopic colectomy. *JLS* 2002;6:49-52.
- Luks VL, Merola J, Arnold BN, et al. Prophylactic Ureteral Stenting in Laparoscopic Colectomy: Revisiting Traditional Practice. *J Surg Res* 2019;234:161-6.
- Chance B. Near-infrared images using continuous, phase-modulated, and pulsed light with quantitation of blood and blood oxygenation. *Ann N Y Acad Sci* 1998;838:29-45.
- Frangioni JV. In vivo near-infrared fluorescence imaging. *Curr Opin Chem Biol* 2003;7:626-34.
- Vahrmeijer AL, Hutteman M, van der Vorst JR, et al. Image-guided cancer surgery using near-infrared fluorescence. *Nat Rev Clin Oncol* 2013;10:507-18.
- Shamseer L, Moher D, Clarke M, et al. Preferred reporting items for systematic review and meta-analysis protocols (PRISMA-P) 2015: elaboration and explanation. *BMJ* 2015;350:g7647.
- Slooter MD, Janssen A, Bemelman WA, et al. Currently available and experimental dyes for intraoperative near-infrared fluorescence imaging of the ureters: a systematic review. *Tech Coloproctol* 2019;23:305-13.
- Al-Taher M, van den Bos J, Schols RM, et al. Fluorescence Ureteral Visualization in Human Laparoscopic Colorectal Surgery Using Methylene Blue. *J Laparoendosc Adv Surg Tech A* 2016;26:870-5.
- Barnes TG, Hompes R, Birks J, et al. Methylene blue fluorescence of the ureter during colorectal surgery. *Surg Endosc* 2018;32:4036-43.
- Verbeek FP, van der Vorst JR, Schaafsma BE, et al. Intraoperative near infrared fluorescence guided identification of the ureters using low dose methylene blue: a first in human experience. *J Urol* 2013;190:574-9.
- Yeung TM, Volpi D, Tullis ID, et al. Identifying Ureters In Situ Under Fluorescence During Laparoscopic and Open Colorectal Surgery. *Ann Surg* 2016;263:e1-2.
- Siddighi S, Yune JJ, Hardesty J. Indocyanine green for intraoperative localization of ureter. *Am J Obstet Gynecol* 2014;211:436.e1-2.
- Lee Z, Simhan J, Parker DC, et al. Novel use of indocyanine green for intraoperative, real-time localization of ureteral stenosis during robot-assisted ureteroureterostomy. *Urology* 2013;82:729-33.
- Morozov AO, Alyaev YG, Rapoport LM, et al. Near-infrared fluorescence with indocyanine green for diagnostics in urology: initial experience. *Urologia* 2017;84:197-202.
- de Valk KS, Handgraaf HJ, Deken MM, et al. A zwitterionic near-infrared fluorophore for real-time ureter identification during laparoscopic abdominopelvic surgery. *Nat Commun* 2019;10:3118.
- Farnam RW, Arms RG, Klaassen AH, et al. Intraoperative ureter visualization using a near-infrared imaging agent. *J Biomed Opt* 2019;24:1-8.
- Choi HS, Nasr K, Alyabyev S, et al. Synthesis and in vivo fate of zwitterionic near-infrared fluorophores. *Angew Chem Int Ed Engl* 2011;50:6258-63.
- Schaafsma BE, Mieog JS, Hutteman M, et al. The clinical use of indocyanine green as a near-infrared fluorescent contrast agent for image-guided oncologic surgery. *J Surg Oncol* 2011;104:323-32.
- Verbeek FP, van der Vorst JR, Tummers QR, et al. Near-infrared fluorescence imaging of both colorectal cancer and ureters using a low-dose integrin targeted probe. *Ann Surg Oncol* 2014;21 Suppl 4:S528-37.
- de Valk KS, Deken MM, Handgraaf HJM, et al. First-in-Human Assessment of cRGD-ZW800-1, a Zwitterionic, Integrin-Targeted, Near-Infrared Fluorescent Peptide in Colon Carcinoma. *Clin Cancer Res* 2020;26:3990-8.
- Korb ML, Huh WK, Boone JD, et al. Laparoscopic Fluorescent Visualization of the Ureter With Intravenous IRDye800CW. *J Minim Invasive Gynecol* 2015;22:799-806.
- Tanaka E, Ohnishi S, Laurence RG, et al. Real-time intraoperative ureteral guidance using invisible near-infrared fluorescence. *J Urol* 2007;178:2197-202.
- Schols RM, Lodewick TM, Bouvy ND, et al. Application of a new dye for near-infrared fluorescence laparoscopy of the ureters: demonstration in a pig model. *Dis Colon Rectum* 2014;57:407-11.
- Mahalingam SM, Dip F, Castillo M, et al. Intraoperative

- Ureter Visualization Using a Novel Near-Infrared Fluorescent Dye. *Mol Pharm* 2018;15:3442-7.
29. van den Bos J, Al-Taher M, Bouvy ND, et al. Near-infrared fluorescence laparoscopy of the ureter with three preclinical dyes in a pig model. *Surg Endosc* 2019;33:986-91.
  30. Cha J, Nani RR, Luciano MP, et al. A chemically stable fluorescent marker of the ureter. *Bioorg Med Chem Lett* 2018;28:2741-5.
  31. Lau LW, Luciano M, Schnermann M, et al. Ureter Identification In an Inflammatory Pig Model Using a Novel Near-Infrared Fluorescent Dye. *Lasers Surg Med* 2020;52:537-42.
  32. Portnoy E, Nizri E, Golenser J, et al. Imaging the urinary pathways in mice by liposomal indocyanine green. *Nanomedicine* 2015;11:1057-64.
  33. Friedman-Levi Y, Larush L, Diana M, et al. Optimization of liposomal indocyanine green for imaging of the urinary pathways and a proof of concept in a pig model. *Surg Endosc* 2018;32:963-70.
  34. Dip FD, Nahmod M, Anzorena FS, et al. Novel technique for identification of ureters using sodium fluorescein. *Surg Endosc* 2014;28:2730-3.
  35. Portnoy E, Lecht S, Lazarovici P, et al. Cetuximab-labeled liposomes containing near-infrared probe for in vivo imaging. *Nanomedicine* 2011;7:480-8.
  36. Szebeni J. Complement activation-related pseudoallergy caused by liposomes, micellar carriers of intravenous drugs, and radiocontrast agents. *Crit Rev Ther Drug Carrier Syst* 2001;18:567-606.
  37. Szebeni J, Muggia F, Gabizon A, et al. Activation of complement by therapeutic liposomes and other lipid excipient-based therapeutic products: prediction and prevention. *Adv Drug Deliv Rev* 2011;63:1020-30.
  38. Daskalaki D, Aguilera F, Patton K, et al. Fluorescence in robotic surgery. *J Surg Oncol* 2015;112:250-6.
  39. Pathak RA, Hemal AK. Intraoperative ICG-fluorescence imaging for robotic-assisted urologic surgery: current status and review of literature. *Int Urol Nephrol* 2019;51:765-71.

doi: 10.21037/ls-20-111

**Cite this article as:** Faber RA, Verbeek FPR, de Valk KS, Burggraaf J, Vahrmeijer AL, Mieog JSD. A systematic review of clinically available and experimental dyes for intraoperative near-infrared fluorescence imaging of the ureters during laparoscopic surgery. *Laparosc Surg* 2021;5:4.