



# Effective tyrosine kinase inhibitor re-treatment in epidermal growth factor receptor-mutated non-small-cell lung cancer patient: a case report

Alessandro Galletti, Marco Russano, Fabrizio Citarella, Bruno Vincenzi, Giuseppe Tonini, Daniele Santini

Department of Medical Oncology, Campus Bio-Medico University, Rome, Italy

Correspondence to: Alessandro Galletti, MD. Department of Medical Oncology, Campus Bio-Medico University, Via Alvaro del Portillo 200, Rome, Italy. Email: a.galletti@unicampus.it.

**Abstract:** The epidermal growth factor receptor (EGFR) tyrosine kinase inhibitors (TKI) represent the standard of care as first-line treatment for patients with non-small-cell lung cancer (NSCLC) harbouring EGFR mutation. There are few treatment options after progression from TKI. In the absence of targetable mutations, patients who develop resistance are usually treated with chemotherapy. There are limited data focusing the role of TKI re-treatment. We present the case of a patient who achieved clinical benefit and objective response upon re-treatment with a first-generation anti-EGFR TKI.

**Keywords:** Non-small-cell lung cancer (NSCLC); epidermal growth factor receptor (EGFR); target therapy; tyrosine kinase inhibitors (TKI)

Received: 01 October 2020; Accepted: 10 December 2020; Published: 30 December 2020.

doi: 10.21037/pcm-20-56

View this article at: <http://dx.doi.org/10.21037/pcm-20-56>

## Introduction

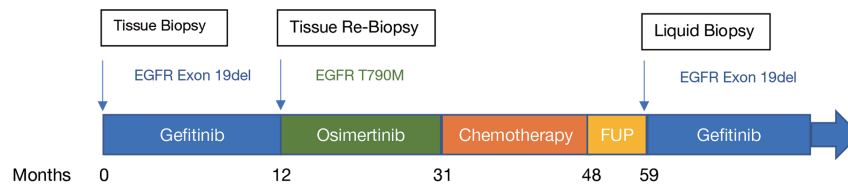
Lung cancer is the leading cause of cancer death worldwide (1). Over 80% of cases are classified as Non-small-cell lung cancer (NSCLC). Although the prognosis remains severe, innovative treatments have been developed in recent years, including immunotherapy and biological therapies. They have improved the quality of life (QoL) and the survival of patients compared to conventional chemotherapy (CT). In particular, advances in the knowledge of molecular biology have led to the identification of some driver mutations that can be targetable with tailored treatments (2,3).

Epidermal growth factor receptor (EGFR) mutations are the most common driver gene alterations in NSCLC, occurring in about 20% of adenocarcinomas in the Caucasian people. They are more common in women, Asian ethnicity, young patients, and never-smokers. In the last decade, first and second generation tyrosine kinase inhibitors (TKI) such as Gefitinib, Erlotinib, and Afatinib, showed a clear superiority in terms of safety and efficacy compared to chemotherapy, becoming the standard of care as first-line treatment in patients

harbouring EGFR sensitizing mutations (4). Osimertinib, a third generation TKI, was designed to overcome the most common mechanism of resistance to former TKIs, the substitution of threonine to methionine at amino acid position 790 (T790M) in exon 20 of the EGFR gene (5). Since Osimertinib is also active against EGFR sensitizing mutations, it was tested in the first-line setting showing a net improvement in efficacy and survival when compared to Gefitinib and Erlotinib, becoming a new standard of care for naive patients (6).

These treatments can achieve long-lasting responses, but they are effective until the tumour becomes resistant and progresses. Some mechanisms of resistance are known and clinical trials with tailored therapies are ongoing. However, in the absence of targetable mutations, patients who develop resistance are usually treated with chemotherapy (7). There is no strong evidence encouraging the reuse of EGFR-TKI in the progressive disease.

We report the case of a patient who benefited from gefitinib re-treatment for metastatic EGFR-mutated NSCLC. We present the following case in accordance with



**Figure 1** Treatment timeline and molecular monitoring.

the CARE reporting checklist (available at <http://dx.doi.org/10.21037/pcm-20-56>).

### Case presentation

A Caucasian 68-year-old man with a smoking history over the past 20 years was admitted to the hospital with shortness of breath in February 2016. Full body computed tomography (CT) scan showed pleural effusion in the left lung, mediastinal lymphadenopathies, and multiple pulmonary nodules. The patient underwent thoracentesis and lung biopsy resulting in adenocarcinoma diagnosis. Molecular assessment showed EGFR exon 19 (19del) mutation. In March 2017, he started first-line treatment with Gefitinib at standard dosage of 250 mg/die, obtaining clinical benefit and radiological partial response. In February 2018, at the moment of thoracic progression observed through CT-scan, liquid biopsy did not show EGFR mutations, so the patient underwent lung re-biopsy revealing the presence of EGFR T790M. Therefore, he started treatment with Osimertinib 80 mg/die achieving partial response on the first radiological evaluation and six-months of progression free survival. In September 2018, when the patient experienced a significant increase of lung mass size, he started a Platinum based chemotherapy. He received Cisplatin plus pemetrexed for 4 cycles followed by Pemetrexed maintenance treatment until March 2019, when the chemotherapy was definitely discontinued due to serious gastrointestinal toxicity while maintaining long-lasting disease stability. After a multidisciplinary discussion, the patient underwent radiotherapy on primary lung mass and mediastinal nodes. No systemic treatments were needed for subsequent ten months. In February 2020, the patient reported abdominal discomfort. CT scan showed multiple peritoneal metastases. Liquid biopsy revealed exon 19 deletion (19del) without concomitant T790M. We considered the few treatment options available and the previous toxicity to chemotherapy. Assuming a re-activation of cellular clones harbouring EGFR sensitizing mutations,

we decided to start gefitinib 250 mg/die re-challenge. Three weeks later patient described significant clinical benefit and regression of abdominal pain. In May 2020, after 2 months of treatment, full body CT Scan showed a partial response both in thoracic and peritoneal disease. Then, patient proceeded Gefitinib treatment, maintaining clinical benefit without any significant toxicity. Treatment timeline and molecular asset are represented in *Figure 1*.

Patient provided written informed consent for publication of this report. All procedures performed in studies involving human participants were in accordance with the ethical standards of the institutional and/or national research committee(s) and with the Helsinki Declaration (as revised in 2013).

### Discussion

There is no standard of treatment for EGFR-mutated NSCLC patients who progress to targeted therapies. Chemotherapy still remains the main clinical choice. We believe that after a drug holiday, cellular clones harbouring EGFR sensitizing mutations could reactivate. Then, the re-treatment with an anti-EGFR TKI could be effective.

Evidence of re-sensibilization and subsequent re-treatment with an anti-EGFR agent is already available in colon-rectal cancer (8). A small phase II clinical trial investigated the efficacy and safety of retreatment with gefitinib in NSCLC. These studies showed a modest benefit, suggesting that Gefitinib rechallenge should be considered only for patients who have no other treatment option (9). Additional data regarding the other TKIs derive from some clinical case reports (10-14). However, there are little evidence regarding the efficacy of a first generation TKI in pre-treated patients for both “sensitizing- and resistant-” EGFR mutations.

Cancer is heterogeneous and dynamic, and different cellular clones can coexist and differently predominate during the clinical course of the disease. In our case, we believe that the TKI treatment eradicated EGFR-

sensitizing cells, whereas resistant clones proliferated leading to progressive disease. A subsequent chemotherapy acted on these clones while being less effective on TKI-sensitive cells, whose re-growth and reactivation caused a new tumour EGFR-dependent progression (15-17).

For these reasons, assessment and molecular monitoring should be encouraged. Solid biopsy is still the standard for molecular profiling, but liquid biopsy is an excellent tool and might be more advantageous in some cases, not only for its repeatability and less invasiveness but also for its potential greater ability to detect circulating cellular clones and to capture the tumour heterogeneity (18,19).

In conclusion, we believe that in EGFR-mutated NSCLC patients who progress to TKI and subsequently receive non-targeted therapies, the re-treatment with anti-EGFR drug should be considered, especially in cases of a plausible re-activation of cell clones expressing EGFR-sensitizing mutations. Molecular monitoring and liquid or solid re-biopsy could optimize clinical choices.

### Acknowledgments

*Funding:* None.

### Footnote

*Reporting Checklist:* The authors have completed the CARE reporting checklist. Available at <http://dx.doi.org/10.21037/pcm-20-56>

*Conflicts of Interest:* All authors have completed the ICMJE uniform disclosure form (available at <http://dx.doi.org/10.21037/pcm-20-56>). MR serves as an unpaid editorial board member of *PCM* from August 2020 to July 2022. The other authors have no conflicts of interest to declare.

*Ethical Statement:* The authors are accountable for all aspects of the work in ensuring that questions related to the accuracy or integrity of any part of the work are appropriately investigated and resolved. All procedures performed in studies involving human participants were in accordance with the ethical standards of the institutional and/or national research committee(s) and with the Helsinki Declaration (as revised in 2013). Written informed consent was obtained from the patient for publication of this study. Local ethics committee approval was not required due to non-experimental content of the manuscript.

*Open Access Statement:* This is an Open Access article distributed in accordance with the Creative Commons Attribution-NonCommercial-NoDerivs 4.0 International License (CC BY-NC-ND 4.0), which permits the non-commercial replication and distribution of the article with the strict proviso that no changes or edits are made and the original work is properly cited (including links to both the formal publication through the relevant DOI and the license). See: <https://creativecommons.org/licenses/by-nc-nd/4.0/>.

### References

1. Bray F, Ferlay J, Soerjomataram I, et al. Global cancer statistics 2018: GLOBOCAN estimates of incidence and mortality worldwide for 36 cancers in 185 countries. *CA Cancer J Clin* 2018;68:394-424.
2. Yuan M, Huang LL, Chen JH, et al. The emerging treatment landscape of targeted therapy in non-small-cell lung cancer. Vol. 4, *Signal Transduction and Targeted Therapy*. Springer Nature, 2019 [cited 2020 Sep 21]. p. 1-14.
3. Gautschi O, Milia J, Cabarrou B, et al. Targeted Therapy for Patients with BRAF-Mutant Lung Cancer Results from the European EURAF Cohort. *J Thorac Oncol* 2015;10:1451-7.
4. Novello S, Barlesi F, Califano R, et al. Metastatic non-small-cell lung cancer: ESMO Clinical Practice Guidelines for diagnosis, treatment and follow-up. *Ann Oncol* 2016;27:v1-27.
5. Mok TS, Wu YL, Ahn MJ, et al. Osimertinib or Platinum-Pemetrexed in EGFR T790M-Positive Lung Cancer. *N Engl J Med* 2017;376:629-40.
6. Soria JC, Ohe Y, Vansteenkiste J, et al. Osimertinib in Untreated EGFR -Mutated Advanced Non-Small-Cell Lung Cancer. *N Engl J Med* 2018;378:113-25.
7. Schoenfeld AJ, Yu HA. The Evolving Landscape of Resistance to Osimertinib. Vol. 15, *Journal of Thoracic Oncology*. Elsevier Inc., 2020 [cited 2020 Sep 21]. p. 18-21.
8. Cremolini C, Rossini D, Dell'Aquila E, et al. Rechallenge for Patients with RAS and BRAF Wild-Type Metastatic Colorectal Cancer with Acquired Resistance to First-line Cetuximab and Irinotecan: A Phase 2 Single-Arm Clinical Trial. *JAMA Oncol* 2019;5:343-50.
9. Cappuzzo F, Morabito A, Normanno N, et al. Efficacy and safety of rechallenge treatment with gefitinib in patients with advanced non-small cell lung cancer. *Lung Cancer* 2016;99:31-7.

10. Yokouchi H, Yamazaki K, Kinoshita I, et al. Clinical benefit of readministration of gefitinib for initial gefitinib-responders with non-small cell lung cancer. *BMC Cancer* 2007;7:51.
11. Becker A, Crombag L, Heideman DAM, et al. Retreatment with erlotinib: Regain of TKI sensitivity following a drug holiday for patients with NSCLC who initially responded to EGFR-TKI treatment. *Eur J Cancer* 2011;47:2603-6.
12. Liu J, Jin B, Su H, et al. Afatinib helped overcome subsequent resistance to osimertinib in a patient with NSCLC having leptomeningeal metastasis bearing acquired EGFR L718Q mutation: A case report. *BMC Cancer* 2019;19:702.
13. Babu Koyyala VP, Batra U, Jain P, et al. Good response to erlotinib in a patient after progression on osimertinib: A rare case of spatiotemporal T790M heterogeneity in a patient with epidermal growth factor receptor-mutant nonsmall cell lung cancer. *South Asian J Cancer* 2017;6:179.
14. Liu L, Lizaso A, Mao X, et al. Rechallenge with erlotinib in osimertinib-resistant lung adenocarcinoma mediated by driver gene loss: A case report. *Transl Lung Cancer Res* 2020;9:144-7.
15. Oxnard GR, Arcila ME, Chmielecki J, et al. New strategies in overcoming acquired resistance to epidermal growth factor receptor tyrosinekinase inhibitors in lung cancer [Internet]. Vol. 17, *Clinical Cancer Research*. American Association for Cancer Research; 2011 [cited 2020 Sep 21]. p. 5530-7.
16. Sharma SV, Lee DY, Li B, et al. A Chromatin-Mediated Reversible Drug-Tolerant State in Cancer Cell Subpopulations. *Cell* 2010;141:69-80.
17. Sequist LV, Waltman BA, Dias-Santagata D, et al. Genotypic and histological evolution of lung cancers acquiring resistance to EGFR inhibitors. *Sci Transl Med* 2011;3:75ra26.
18. Russano M, Napolitano A, Ribelli G, et al. Liquid biopsy and tumor heterogeneity in metastatic solid tumors: The potentiality of blood samples [Internet]. Vol. 39, *Journal of Experimental and Clinical Cancer Research*. BioMed Central Ltd.; 2020 [cited 2020 Sep 24]. p. 95.
19. Bai Y, Zhao H. Liquid biopsy in tumors: opportunities and challenges. *Ann Transl Med* 2018;6:S89.

doi: 10.21037/pcm-20-56

**Cite this article as:** Galletti A, Russano M, Citarella F, Vincenzi B, Tonini G, Santini D. Effective tyrosine kinase inhibitor re-treatment in epidermal growth factor receptor-mutated non-small-cell lung cancer patient: a case report. *Precis Cancer Med* 2020;3:29.