



# Surgical management of parathyroid cancer during the COVID-19 pandemic: experience from a tertiary referral centre (a case series)

Katie Greene, Jason K. Ramsingh

Department of Endocrine Surgery, Royal Victoria Infirmary, Newcastle Upon Tyne Hospitals NHS Foundation Trust, Newcastle, UK

*Contributions:* (I) Conception and design: JK Ramsingh; (II) Administrative support: Both authors; (III) Provision of study materials or patients: JK Ramsingh; (IV) Collection and assembly of data: K Greene; (V) Data analysis and interpretation: K Greene; (VI) Manuscript writing: Both authors; (VII) Final approval of manuscript: Both authors.

*Correspondence to:* Jason K. Ramsingh. Royal Victoria Infirmary, Queen Victoria Road, Newcastle, NE1 4LP, UK. Email: Ramsingh.jason@gmail.com.

**Background:** Parathyroid carcinoma is a rare malignancy which accounts for 1% of cases of primary hyperparathyroidism. In patients with severe hypercalcaemia or a significantly raised parathyroid hormone (PTH) level clinicians should consider parathyroid carcinoma and expedited management is essential. During the current pandemic, a high index of suspicion should be maintained to ensure care is not compromised. A review of the management of patients with suspected parathyroid carcinoma during the COVID-19 pandemic is presented.

**Methods:** In our tertiary referral centre for endocrine surgery, 4 patients presented with primary hyperparathyroidism and a high index of suspicion for parathyroid cancer during the first wave of the COVID-19 pandemic. The pre-operative presentation, investigations, surgical management and post-operative outcomes are reported for these patients and a literature review of parathyroid cancer was conducted.

**Results:** All 4 patients presented with severe hypercalcaemia and significantly raised PTH levels. Pre-operative mean calcium and PTH was 3.36 (3.10–3.80) mmol/L and 80.0 (52.0–99.8) pmol/L respectively. Imaging modalities utilized included sestamibi-SPECT, 4D-CT and ultrasound. Two patients had evidence of distant disease at presentation (brown tumours and/or metastases). One patient was transferred as an inpatient and the other three patients were seen within 2 weeks of referral. Mean time from referral to surgery was 14 days. Histological findings confirmed parathyroid cancer in all 4 patients.

**Conclusions:** Despite limitations on face-to-face clinic consultations, reduced capacity for elective surgery during the COVID19 pandemic and given the diagnosis of parathyroid cancer, expedited care ensured that these patients were managed appropriately with possible improved long-term outcomes.

**Keywords:** Parathyroid cancer; COVID-19; hypercalcaemia

Received: 18 February 2020; Accepted: 01 April 2021; Published: 30 June 2021.

doi: 10.21037/aot-21-7

View this article at: <http://dx.doi.org/10.21037/aot-21-7>

## Introduction

The impact of the COVID-19 pandemic has been widespread and practices for managing new specialty referrals have been adjusted to maintain social distancing where possible and reduce transmission of the disease. In

the UK, there has been a shift toward conducting outpatient consultations over the telephone and reducing face-to-face contact. There have also been challenges in inter-hospital transfer of patients and capacity for elective operating has reduced (1). These factors have an impact on diagnosis and

treatment of cancer leading to additional strain on resources and on health care systems internationally (2).

Parathyroid carcinoma is a rare malignancy which accounts for 1% of cases of primary hyperparathyroidism (3-5). It is most common in patients in the fourth or fifth decade of life. Presentation is usually associated with high parathyroid hormone (PTH) and high calcium as these tumours are often hormonally active. Diagnosis is often difficult pre-operatively in the absence of metastatic disease as the presentation is similar to benign primary hyperparathyroidism. The majority of patients present with symptomatic hypercalcaemia. Predictive factors of malignancy include hypercalcaemia (>3.5 mmol/L), abnormally high PTH, a mass on clinical examination, hypercalcaemia with a vocal cord palsy and concurrent renal and skeletal abnormalities with an elevated PTH (3,5-7). Pre-operative diagnosis of parathyroid cancer is challenging but imaging can be helpful especially when invasion of adjacent structures and metastatic disease is present.

Our centre is a large volume tertiary referral centre for endocrine surgery and manages patients from across the north of England. During the COVID-19 pandemic we have continued to accept referrals for benign and suspected malignant disease and report on our experience of 4 patients referred with primary hyperparathyroidism and their subsequent management. We also highlight the co-ordination efforts required to expedite the management of these patients despite the limitations on provision of care during COVID-19 pandemic. We present the following article in accordance with the AME Case Series reporting checklist (available at <http://dx.doi.org/10.21037/aot-21-7>).

## Methods

Our single tertiary academic centre operates on over 300 patients per year with endocrine conditions affecting the thyroid, parathyroid and adrenal glands. During the current pandemic, we were operating mainly on patients with confirmed or suspected cancer. The following cases series highlights the management of consecutive patients admitted to our unit with a high index of suspicion for parathyroid cancer. Patients' data was entered into a prospectively kept database and represents patients operated on for parathyroid cancer in 2020. Normal reference ranges for calcium were 2.2–2.60 mmol/L and for PTH was 1.1–6.9 pmol/L.

Consent was obtained from all patients in this case series following a detailed explanation of the nature of the series and the specific details and images that would be included

in this paper. As this study was a case series, approval from an independent ethical committee was not sought prior to beginning this retrospective review. This study involving the use of patient information conformed to the principles of the Declaration of Helsinki (as revised in 2013).

## Results

### Case 1

A 59-year-old man referred to the endocrine surgeons an emergency admission with severe hypercalcaemia (3.5 mmol/L) requiring dialysis. There was no evidence of a neck mass, renal calculi or bone disease at the time of presentation. The patient was discharged from their local hospital on cinacalcet. The patient was contacted and an urgent arranged admission was planned for further investigation and early surgical intervention.

A Sestamibi-SPECT scan was reported showing uptake at the lower pole of the right lobe of the thyroid gland. This corresponded to an 18 mm soft tissue mass on CT thorax. An ultrasound of the neck was also performed and this was reported as normal.

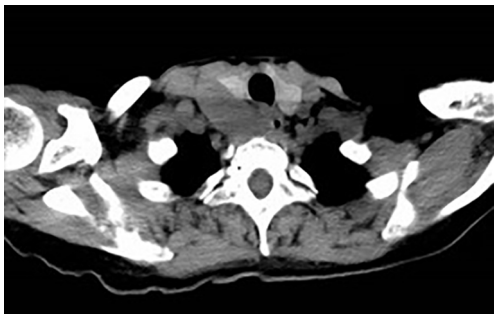
Pre-operatively, the adjusted calcium level was 2.71 mmol/L and PTH was 70.5 pmol/L. He was advised that there was a clinical concern of parathyroid cancer and consented for a parathyroidectomy and possible *en bloc* resection of right lobe of thyroid. He was also advised that if his recurrent laryngeal nerve was involved it would be sacrificed and the implications of this.

Intra-operatively, a firm, grey mass was seen adherent to the inferior pole of the right lobe of the thyroid. Given these findings, an *en bloc* resection of the parathyroid and right lobe of thyroid was performed. A right central neck dissection was also performed and the recurrent laryngeal nerve was not involved and preserved.

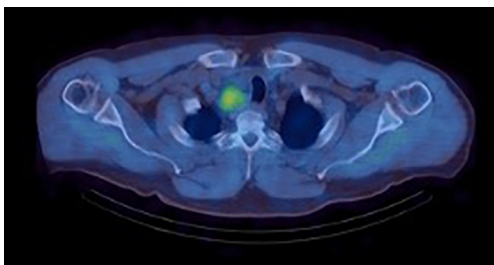
Post-operatively, PTH and calcium returned to within normal levels. Histology from the specimen confirmed low-grade parathyroid carcinoma. There was no nodal involvement; T1 N0 R1. Tumour size was 25 mm. No further imaging was performed post-operatively and the patient was followed up with annual surveillance with the endocrine surgery team measuring calcium and PTH at their clinic visits.

### Case 2

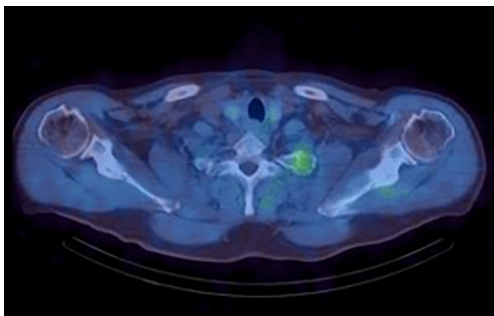
A 58-year-old woman was admitted under general surgery as an emergency with perforated diverticular disease which



**Figure 1** 4D CT scan showing large right-sided parathyroid tumour densely adherent to right lobe of thyroid.



**Figure 2** SPECT CT showing sestamibi uptake in right parathyroid mass.



**Figure 3** SPECT CT showing sestamibi uptake in left posterior first rib.

was managed with a Hartmann's procedure. During this admission, it was noted that her calcium (3.62 mmol/L) and PTH (35.8 pmol/L) were raised. The hypercalcaemia was medically managed initially with cinacalcet and an ultrasound of the neck was performed which revealed a 33 mm × 42 mm nodule on the right lower lobe of the thyroid gland. The patient was referred to the endocrine surgery team on discharge.

Following outpatient clinic review, a semi-urgent

elective parathyroidectomy was planned however she was unfortunately admitted with hypercalcaemia prior to the date for her procedure. Calcium on this admission was 4.10 mmol/L and PTH was 52.0 pmol/L. Further imaging was performed urgently due to increasing clinical concern about malignancy. A 4D CT showed a 50 mm × 25 mm × 40 mm cystic lesion in the right lower neck which sat deep to the right lobe of the thyroid and mildly displaced the oesophagus and trachea (*Figure 1*). There was no evidence of distant disease on this pre-operative scan. She was counselled pre-operatively on the concern of this being a parathyroid cancer and this was highlighted again during the consent process.

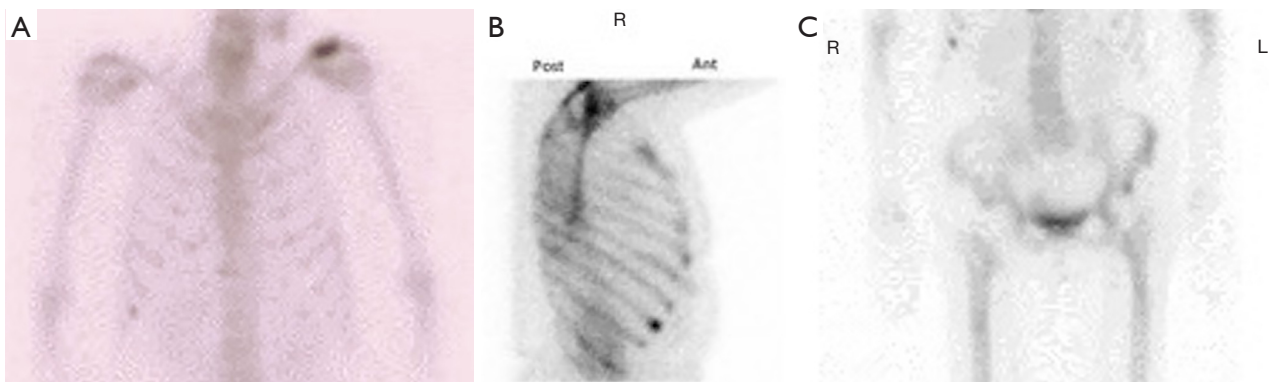
Intra-operatively, an *en bloc* resection of the right lobe of thyroid and right-sided parathyroid gland mass was performed with a right central lymph node dissection. The procedure was uncomplicated and the patient's calcium and parathyroid hormone levels returned to normal post-operatively.

Histology confirmed low-grade parathyroid carcinoma with no evidence of nodal involvement (T1, N0 R0). The tumour size in the specimen was 44 mm. This patient was also followed up with annual surveillance including yearly calcium and PTH and did not require any further imaging or intervention post-operatively.

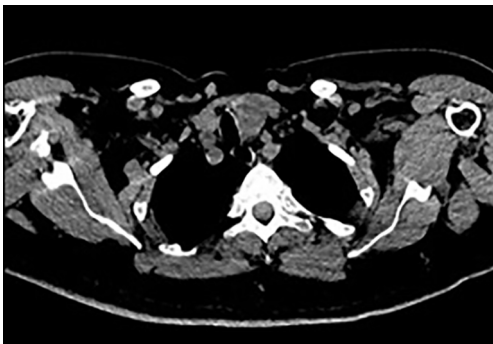
### Case 3

A 59 year old man was referred to endocrine surgeons after presenting to his GP with severe leg cramps. His GP checked his calcium level which was raised at 3.24 mmol/L and PTH was 94 pmol/L. Hypercalcaemia was initially managed with cinacalcet. Prior to referral, a renal tract ultrasound was performed which showed evidence of a renal calculus. A sestamibi SPECT scan was performed and this reported a 43 mm lesion at the right lower pole of the thyroid gland, extending to the thoracic inlet (*Figure 2*). There was also evidence of increased uptake on the scan in the left first rib which was suspicious for a Brown tumour or possible parathyroid cancer metastases (*Figure 3*).

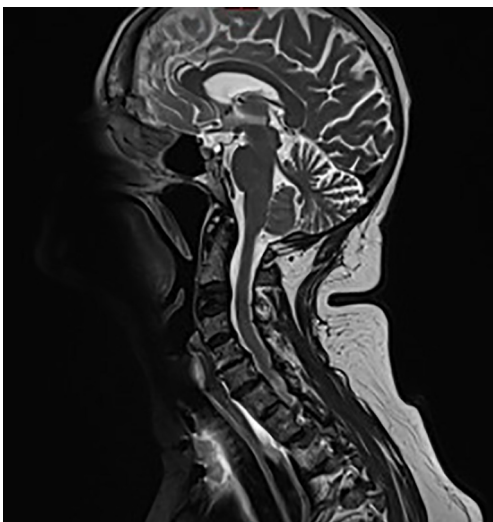
An urgent parathyroidectomy and *en bloc* resection of the right thyroid lobe was performed. Intra-operatively, the large parathyroid mass was densely adherent to the lower right pole of the thyroid gland and the recurrent laryngeal was sacrificed intra-operatively as it was unable to be separated from the tumour. There was evidence of lymphadenopathy intraoperatively and as such, a right central lymph node dissection was performed. Post-operatively, the patient clinically had a recurrent laryngeal nerve palsy as had been



**Figure 4** Isotope bone scan showing uptake in (A) left humeral head, (B) right ribs and (C) left iliac wing.



**Figure 5** 4D CT showing large left parathyroid mass with tracheal deviation.



**Figure 6** Sagittal MRI showing loss of height in C3 vertebral body.

expected and an urgent referral to speech and language therapy was made. There was a significant biochemical improvement post-operatively: PTH pre-op 133.9 pmol/L and 1-day post-op PTH 11.6 pmol/L.

Histology of the resected tissue showed a 39 mm low-grade parathyroid carcinoma with no evidence of nodal involvement T1 N0 R0. Given that the increased sestamibi uptake in the left 1st rib was inconclusive for the presence of bone involvement, a plan was made to further investigate this with a PET scan and 6-month interval MRI.

#### Case 4

A 67-year-old woman was admitted to hospital with diarrhoea and was noted to have high calcium (3.39 mmol/L) on admission with an elevated PTH (99.8 pmol/L). A renal ultrasound showed no evidence of renal calculi or nephrocalcinosis. CT chest, abdomen and pelvis was performed which showed sclerotic bony lesions in the neck and pelvis which were confirmed on an isotope bone scan and suspicious for widespread bony metastases (Figure 4). The patient was commenced on cinacalcet and an outpatient referral to endocrine surgery was made prior to discharge.

The endocrine surgery team arranged for urgent inpatient transfer of this patient to expedite surgical management. CT of the parathyroid gland showed 35mm lobular lesion on the lower pole of the left lobe of the thyroid gland and this corresponded with a similar lesion noted on USS of the neck (Figure 5). Further bony lesions were noted on this scan with a significant lesion in the C3 vertebra which required further evaluation with an MRI spine and was found to be stable with no evidence of spinal cord compression (Figure 6).

A left hemithyroidectomy with *en bloc* parathyroidectomy

was performed with left central lymph node dissection. The procedure was not associated with any complications and post-operatively, PTH was  $<0.6$  pmol/L when checked and calcium was normal. Given the undetectable level of PTH, the patient was discharged on a short course of alfacalcidol.

The bone changes were reviewed by the consultant radiologists at both a sarcoma and endocrine surgery MDT and in the context of significant primary hyperparathyroidism, were considered to be Brown tumours. Histology from the resection specimen showed a low-grade parathyroid carcinoma which measured 26 mm and had no evidence of lymphatic invasion (T1/2, N0, R0). Annual follow up was planned and the spinal changes noted pre-operatively were followed up with a 6-month repeat MRI of the spine.

## Discussion

Parathyroid carcinoma is a rare malignancy and challenging to diagnose. Our centre receives a high volume of referrals for patients with primary hyperparathyroidism and with the additional pressure of reduced accessibility to outpatient clinics for assessment, the pertinence of maintaining a high index of suspicion for potential malignancy is warranted. The current COVID-19 pandemic has impacted on the early diagnosis and management of several cancers which can potentially lead to adverse outcomes for patients (1,2). This case series highlights that despite these unforeseen challenges, maintaining the same high index of suspicion and delivering expedited care for patients with parathyroid cancer is possible.

The preoperative diagnosis of parathyroid cancer is challenging and is often made intra- and post-operatively based on evidence of invasion and histological criteria respectively. In our case series, patients presented with severe hypercalcaemia, raised PTH and evidence of skeletal/renal involvement in 50% of patients. These bony lesions are likely to represent Brown tumours rather than metastatic deposits as traditionally parathyroid cancer tends to metastasise to lungs rather than bone (8,9). Pre-operative imaging also reported large cervical masses (mean size: 33.5 mm) which further raised the possibility of malignancy. Based on the pre-operative factors, the possibility of a parathyroid cancer was discussed with our patients as part of our counselling and consent process but also facilitated intra-operative decision-making.

Surgical management of primary hyperparathyroidism involves excision of enlarged parathyroid glands suspected to be an adenoma or hyperplastic. Conversely,

in suspected parathyroid carcinoma an *en bloc* resection with the ipsilateral hemithyroid +/- recurrent laryngeal nerve is recommended as this provides superior outcomes. Lymph node dissection in the central compartment is also indicated where the intraoperative findings are consistent with suspected malignancy however clinicians should use their judgement to consider further lymph node dissection in the lateral compartments if appropriate. In all of the cases in this series, it was noted that the enlarged parathyroid gland was densely adherent to the ipsilateral hemithyroid and thus an *en bloc* resection was performed with central lymph node dissection. In one patient there was evidence of involvement of the recurrent laryngeal nerve and so this was resected in keeping with oncological principles.

Pathological diagnosis on histological criteria presents its own challenges. Features such as capsular and vascular invasion may indicate malignant potential with ICD recommending the presence of distant disease is required for the diagnosis of parathyroid cancer (10,11). Truran *et al.* showed that staining for parafibromin and galectin-3 can be helpful but not diagnostic (12). Given the centralisation of the parathyroid pathology reporting service in our region, the pathologist in our unit has amassed vast experience in recognising the subtleties of parathyroid malignancy. An experienced pathologist is invaluable in assessing potential parathyroid cancer just as in any rare malignancy.

We noted that in all of the patients in this series achieved normocalcaemia post-operatively in keeping with biochemical cure. One patient had an elevated PTH following their procedure (11.6 from 133.9) raising the suspicion of metastatic disease. All patients were discussed in a multidisciplinary team meeting post-operatively. For those who had no evidence of bony disease annual surveillance was recommended with serum calcium and PTH measurements. Those patients with evidence of bony disease required skeletal MRI surveillance to assess for regression or progression of these lesions. Follow up of patients with parathyroid cancer is important considering there is a high risk of recurrence (40–60%) with most recurrences presenting within 5 years of the index procedure (13).

There has been international concern that diagnosis and management of malignancy is subject to delay leading to adverse outcomes for patients due to the COVID-19 pandemic. We have demonstrated that through careful consideration of endocrine surgery referrals during this time, those patients who have suspected malignancy can

be managed as per the standards of care set prior to the pandemic. All of the patients in this series were investigated and operated on within 30 days of referral with a mean time from referral to surgery of days. In line with RCS guidance and local trust policy, patients were screened pre-operatively with a COVID-19 virology test; none of the patients in this series tested positive.

## Conclusions

The COVID-19 pandemic has disrupted surgical services in both the UK and the world leading to delayed diagnosis and worse outcomes for patients (14). Despite having no specific pre-operative diagnostic criteria, certain biochemical and radiological features may point to a diagnosis of parathyroid cancer. Clinicians receiving referrals of patients with primary hyperparathyroidism should exercise vigilance in order to identify and expedite management of those with suspected cancer, especially given the limitations COVID-19 has placed on both inpatient and outpatient surgical services. Pre-operative counselling for patients enables intra-operative decision making if clinical concerns are confirmed. This is crucial for delivering optimal treatment outcomes at the initial procedure, especially in a time when there is significant strain on healthcare resources.

## Acknowledgments

We will like to acknowledge all the dedicated nursing and medical staff at the Royal Victoria Infirmary, Newcastle Upon Tyne Hospitals, NHS Foundation Trust, who have worked admirably during the current pandemic to ensure that a high quality of care is delivered to patients.

*Funding:* None.

## Footnote

*Reporting Checklist:* The authors have completed the AME Case Series reporting checklist. Available at <http://dx.doi.org/10.21037/aot-21-7>

*Data Sharing Statement:* Available at <http://dx.doi.org/10.21037/aot-21-7>

*Conflicts of Interest:* Both authors have completed the ICMJE uniform disclosure form (available at <http://dx.doi.org/10.21037/aot-21-7>). The authors have no conflicts of interest to declare.

*Ethical Statement:* The authors are accountable for all aspects of the work in ensuring that questions related to the accuracy or integrity of any part of the work are appropriately investigated and resolved. Consent was obtained from all patients in this case series following a detailed explanation of the nature of the series and the specific details and images that would be included in this paper. As this study was a case series, approval from an independent ethical committee was not sought prior to beginning this retrospective review. This study involving the use of patient information conformed to the principles of the Declaration of Helsinki (as revised in 2013).

*Open Access Statement:* This is an Open Access article distributed in accordance with the Creative Commons Attribution-NonCommercial-NoDerivs 4.0 International License (CC BY-NC-ND 4.0), which permits the non-commercial replication and distribution of the article with the strict proviso that no changes or edits are made and the original work is properly cited (including links to both the formal publication through the relevant DOI and the license). See: <https://creativecommons.org/licenses/by-nc-nd/4.0/>.

## References

1. Richards M, Anderson, M, Carter P, et al. The impact of COVID-19 pandemic on cancer care. *Nature Cancer* 2020. doi: 10.1038/s43018-020-0074-y. [Epub ahead of print].
2. Veronesi P, Corso G. Impact of COVID-19 pandemic on clinical and surgical breast cancer management. *EClinicalMedicine* 2020;26:100523.
3. Rahbari R, Kebebew E. Parathyroid tumours. In: DeVita VT Jr, Lawrence TS, Rosenberg SA. *Cancer: Principles and practice of oncology*. 9th ed. Philadelphia, Pa: Lippincott Williams & Wilkins, 2011:1473-9.
4. Fraker DL. Update on the management of parathyroid tumors. *Curr Opin Oncol* 2000;12:41-8.
5. Shane E. Clinical Review 122: Parathyroid carcinoma. *J Clin Endocrinol Metab* 2001;86:485-93.
6. Anderson BJ, Samaan NA, Vassilopoulou-Sellin R, et al. Parathyroid carcinoma: features and difficulties in diagnosis and management. *Surgery* 1983;94:906-15.
7. Obara T, Fujimoto Y. Diagnosis and treatment of patients with parathyroid carcinoma: an update and review. *World J Surg* 1991;15:738-44.
8. Hundahl SA, Fleming ID, Fremgen AM, et al. Two hundred eighty-six cases of parathyroid carcinoma treated

- in the U.S. between 1985-1995: a National Cancer Data Base Report. The American College of Surgeons Commission on Cancer and the American Cancer Society. *Cancer* 1999;86:538-44.
9. Wynne AG, van Heerden J, Carney JA, et al. Parathyroid carcinoma: clinical and pathologic features in 43 patients. *Medicine (Baltimore)* 1992;71:197-205.
  10. Schantz A, Castleman B. Parathyroid carcinoma. A study of 70 cases. *Cancer* 1973;31:600-5.
  11. Bondeson L, Sandelin K, Grimelius L. Histopathological variables and DNA cytometry in parathyroid carcinoma. *Am J Surg Pathol* 1993;17:820-9.
  12. Truran PP, Johnson S, Bliss RD, et al. Parafibromin, galectin-3, PGP9.5, Ki67, and cyclin D1: using an immunohistochemical panel to aid the diagnosis of parathyroid cancer. *World J Surg* 2014;38:2845-54.
  13. Cohn K, Silverman M, Corrado J, et al. Parathyroid carcinoma: the Lahey Clinic experience. *Surgery* 1985;98:1095-100.
  14. Levin KE, Galante M, Clark OH. Parathyroid carcinoma versus parathyroid adenoma in patients with profound hypercalcaemia. *Surgery* 1987;101:649-60.

doi: 10.21037/aot-21-7

**Cite this article as:** Greene K, Ramsingh JK. Surgical management of parathyroid cancer during the COVID-19 pandemic: experience from a tertiary referral centre (a case series). *Ann Thyroid* 2021;6:9.