

Ivor Lewis minimally invasive esophagectomy

Gail E. Darling

Division of Thoracic Surgery, Kress Family Chair in Esophageal Cancer, University of Toronto, Toronto General Hospital, University Health Network, Toronto, Ontario, Canada

Correspondence to: Gail E. Darling, MD, FRCSC. Professor of Surgery, Division of Thoracic Surgery, Kress Family Chair in Esophageal Cancer, University of Toronto, Toronto General Hospital, University Health Network, 200 Elizabeth St. 9N-955, Toronto, Ontario, M5G 2C4, Canada. Email: Gail.darling@uhn.ca.

Abstract: Esophagectomy is a complex operation with many steps. Adaption of this procedure to a minimally invasive approach has been embraced by many surgeons including totally minimally invasive Ivor Lewis esophagectomy, and hybrid procedures wherein either the abdominal phase or thoracic phase are performed minimally invasively, the other phase is open. When performing a minimally invasive procedure, it is recommended that the procedure should include all the same steps as the open operation. However, there is a lack of consensus around certain components of esophagectomy such as an *en bloc* technique or use of a gastric emptying procedure and so it is with the minimally invasive equivalent. Even the open approach varies between surgeons with some preferring the Ivor Lewis approach, some a transhiatal and others the McKeown approach. This article will describe my approach to the totally minimally invasive Ivor Lewis esophagectomy with notations regarding variations in practice.

Keywords: Esophagectomy; minimally invasive surgery; esophageal neoplasm

Received: 29 March 2020; Accepted: 14 August 2020; Published: 25 June 2021.

doi: 10.21037/aoe-20-26

View this article at: <http://dx.doi.org/10.21037/aoe-20-26>

Ivor Lewis minimally invasive esophagectomy

Overall, the minimally invasive approach to an Ivor Lewis esophagectomy is the same as the open operation. The goal of the operation is a complete (R0) resection of the cancer, with appropriate proximal, distal and radial margins and a complete lymph node dissection. The esophagus is reconstructed with stomach and the anastomosis is placed in the right chest. Laparoscopic/thoracoscopic cameras, instruments and techniques have been applied to the Ivor Lewis esophagectomy with excellent results, comparable to the open operation in terms of oncologic outcomes, and improved in terms of reduced pulmonary complications (1).

Minimally invasive Ivor Lewis esophagectomy is a technically challenging operation with a significant learning curve with some authors suggesting that more than 100 cases are required to be proficient whereas others report only 30–40 cases are needed (2–4). Robotic approaches may facilitate many parts of the operation however this is not the topic for this chapter.

In 1946 Ivor Lewis reported in the British Journal of Surgery his approach to carcinoma of the esophagus using a separate laparotomy and right thoracotomy (5). This approach became popular and was added to the armamentarium of esophageal surgeons (6). In 1992, Cuschieri reported on a totally minimally invasive approach to the Ivor Lewis esophagectomy (7). With the growth of minimally invasive surgery, esophagectomy was added to the list of procedures that could be approached in this manner (8). However it was James Luketich who really brought this operation into the mainstream, first reporting on his initial cases (9,10) and more recently on over 1,000 cases (11).

The technique for minimally invasive Ivor Lewis esophagectomy

There are multiple components of the operation which can be conducted in different sequence depending on the patient's body habitus, the size and location of the tumour

and the difficulty of the dissection.

The components are: the laparoscopic resection of the proximal stomach and preparation of the gastric conduit; the laparoscopic upper abdominal lymphadenectomy (D1 minimum), right thoracoscopic resection of the thoracic

esophagus, mediastinal lymphadenectomy, delivery of the gastric conduit and esophagogastric anastomosis. Additional procedures including gastric emptying procedures and feeding jejunostomy may also be included although are less frequently used in the current era. See *Table 1*.

Table 1 Steps of minimally invasive Ivor Lewis esophagectomy

Abdominal phase

Establishment of pneumoperitoneum

Inspection of abdomen

5 ports

Division of gastrohepatic ligament

Exposure and dissection of right crus

Exposure of confluence of crura posteriorly

Division of phrenoesophageal ligament

Exposure and dissection of anterior aspect of left crus

Division of gastrocolic ligament

Mobilization of the stomach off the pancreas and retroperitoneum over to the pylorus posteriorly

Division of short gastrics

Mobilization of the fundus away from the tail of the pancreas and left crus posteriorly

Identification of left gastric pedicle

Skeletonization and division of the left gastric vein

Skeletonization of origin of left gastric artery, splenic artery and common hepatic artery

Division of left gastric artery

Creation of the gastric conduit

Lymphadenectomy: common hepatic, celiac (aortocaval), splenic

Transhiatal dissection of distal esophagus:

En bloc resection of lymph node bearing tissue anterior to aorta,

Division of right mediastinal pleura and inferior portion of right inferior pulmonary ligament

Skeletonization of posterior pericardium

Resection of left pleura and division of inferior portion of left inferior pulmonary ligament

Completion of circumferential *en bloc* dissection aorta to pericardium, right and left pleura

Suture distal aspect of resected proximal stomach to proximal tip of conduit

Closure of abdomen

Left chest tube

Thoracic phase

Left lateral decubitus position (prone or semi-prone)

4 ports

Table 1 (*continued*)

Table 1 (continued)

Insufflation of CO ₂ 8 mmHg
Mobilization and division of azygous vein
Division of mediastinal pleura from the level of the divided azygous vein, across the RMB, divide right vagus nerve at the lower border of the RMB
Subcarinal nodes dissected off RMB at this point or later
Open pleura right IPV and complete division of right inferior pulmonary ligament
Mobilize infracarinal esophagus off the posterior pericardium from carina down to hiatus (From right over to left exposing left IPV)
Divide mediastinal pleura up to apex
Mobilize esophagus off carina and trachea
Divide mediastinal pleura from the divided azygous vein posterior to the esophagus, medial to the ascending azygous vein down to the hiatus
Mobilize esophagus off the descending aorta
Mobilize esophagus away from aortic arch
Mobilize esophagus off LMB, stay close to esophagus to avoid injury to left RLN
Complete dissection of esophagus off the left IPV
Divide the left vagus nerve between the distal LMB and left IPV
Complete division of left pleura
Mobilize esophagus superiorly
Divide esophagus
Deliver distal esophagus, proximal resected stomach and attached conduit into chest
Enlarge ant superior port, remove resected specimen
Complete subcarinal lymph node dissection (Complete paratracheal node dissection right and left)
Anastomosis
Place purse-string suture
Place EEA anvil in esophagus
Secure with purse-string
Reinforce with second purse-string
Create gastrotomy along lesser curve staple line opposite to planned location of anastomosis
Introduce EEA stapler and deploy point of stapler through greater curve
Dock stapler on anvil, turn down and fire
Close gastrotomy
Leak test, reinforce anastomosis if required
Intercostal blocks
Drains
Close

RMB, right main bronchus; LMB, left main bronchus; RLN, recurrent laryngeal nerve; IPV, inferior pulmonary vein.

My approach follows, variations are noted

With the patient awake in the operating room, we review our first surgical checklist. The patient is then anaesthetized and intubated. A double lumen endotracheal tube is used from the start of the procedure rather than reintubating for the thoracic component. An arterial line, foley catheter and sequential compression devices are standard. Often a triple lumen central venous catheter is inserted in the right internal jugular vein which is used for postoperative TPN. Subcutaneous fractionated heparin is given and intravenous antibiotics are administered. A bronchoscopy and bronchoscopic washing for culture is performed. We have identified colonization of gram negative bacteria in some patients, and have been able to minimize the severity of postoperative pneumonia using this practice.

I prefer not to perform an endoscopy at the time of the planned resection. This introduces air into the stomach and bowel which can make the subsequent laparoscopic portion of the operation more challenging. In my practice, I will have usually performed endoscopy at the time of diagnosis or staging with EUS or prior to the start of neoadjuvant therapy. At the time of my initial endoscopy I note the upper extent of Barrett's esophagus if present, the upper and distal extent of the tumor and the degree of involvement of the gastric cardia, or fundus. If I have not done an initial endoscopy, I will perform this prior to surgery but not on the day of surgery.

The patient is positioned supine on the operating table with all pressure points well padded. I prefer to keep both arms tucked at the side if possible. This prevents postoperative shoulder pain. The abdomen is prepped with chlorhexidine from above the nipple line to the symphysis pubis and from table side on the right to the left.

Port placement

The second surgical checklist is reviewed and then the laparoscopic ports are placed. We infiltrate all port sites with 0.5% Marcaine with epinephrine prior to making the skin incisions. I use an open Hassan technique for the camera port which is generally placed several centimetres above the umbilicus. In patients with larger BMI, the port may be placed even higher. For very small patients, particularly if they have a narrow costal arch, the camera port is placed in the umbilicus. The abdomen is insufflated with CO₂ to a sustained pressure of 15 mmHg. The camera is then inserted and the abdomen is inspected looking for

evidence of carcinomatosis. Biopsy and quick section of any suspicious lesions is performed after placing an additional 5 mm port. If there is no evidence of metastatic disease, 4 more ports are inserted. Typically we use two 5 mm ports in the right and left subcostal positions laterally and two 12 mm ports in the epigastrium to the right and left of the midline with sufficient distance between these and the camera port. I choose to use two 12 mm ports so that I have flexibility when operating with a resident and can move the camera laterally to allow a more ergonomic approach when operating from either the right or left side of the patient. I use the 5 mm right subcostal port for the liver retractor. Alternatively, this could be placed in the subxiphoid position.

Dissection of the stomach

The gastrocolic, gastrosplenic and gastrohepatic ligaments are divided in this portion of the procedure. I use the ultrasonic shears energy device (Harmonic ACE with advanced hemostasis Ethicon/J&J US) for all dissection. I previously began by dividing the gastrocolic ligament, however, more recently, I have started by dividing the gastrohepatic ligament beginning at the pars flaccida and proceeding in a cephalad direction exposing the right crus (*Figure 1A,B*). I then divide the phrenoesophageal ligament beginning at the right crus and extending over to the left crus, exposing the left crus anteriorly (*Figure 2*).

The division of the gastrohepatic ligament is completed, and then the lesser curvature tissues are divided to the gastric wall. Previously these tissues were divided at the level of the incisura, I now divide these tissues to the gastric wall just below the crow's foot. This will be the site for initiation of the gastric staple line. This completes this portion of the operation.

The gastrocolic ligament is then divided. This is facilitated by the operating surgeon gently grasping the anterior wall of the stomach with the left hand and elevating the stomach toward the hiatus while the assistant applies downward traction on the gastrocolic ligament near the edge of the transverse colon. This puts the gastrocolic ligament on some tension and helps to expose the right gastroepiploic arcade (*Figure 3*). Once the right gastroepiploic vessels have been identified, the division of the gastrocolic ligament is initiated usually at a point near the mid antrum. Dissection initially proceeds in a cephalad direction up the greater curvature to the level of the left gastroepiploic which is divided with the energy

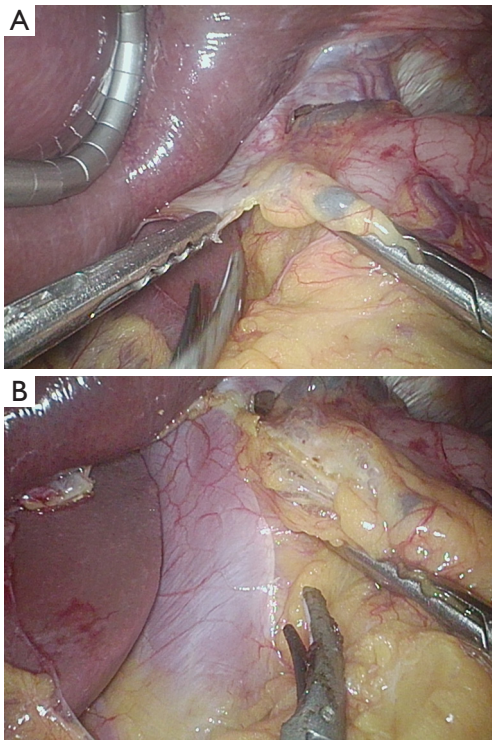


Figure 1 Beginning of dissection along the lesser curve of the stomach. (A) Division of the gastrohepatic ligament beginning at the pars flaccida; (B) exposure of the R crus after dividing the gastrohepatic ligament.

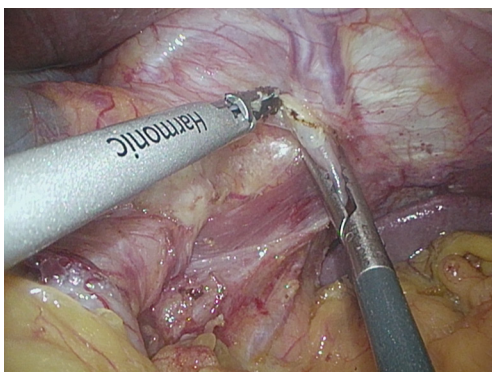


Figure 2 Opening the phrenoesophageal ligament from the left side.

device (*Figure 4*). In overweight individuals, this part of the dissection can be challenging because of the amount of fat and one must proceed cautiously so as not to injure the splenic flexure.

Once the lesser sac has been entered, the stomach can be elevated away from the pancreas and retroperitoneum and

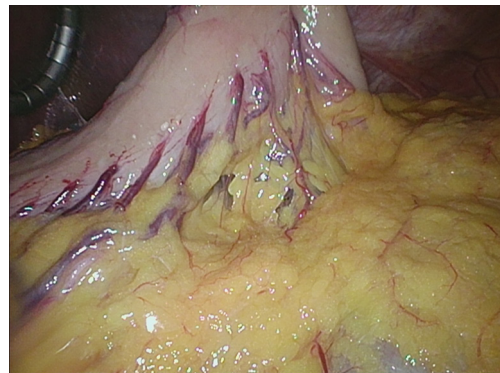

Figure 3 Exposure of the right gastroepiploic arcade by applying cephalad traction on the stomach.

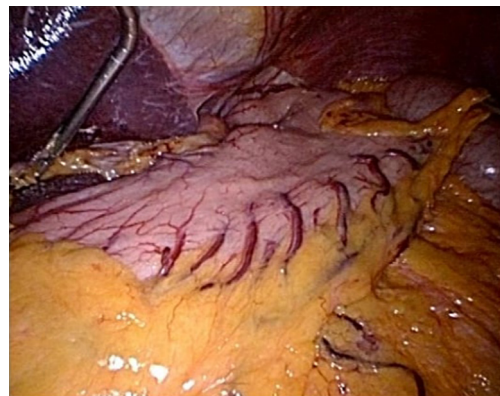


Figure 4 Stomach after partial division of gastrocolic ligament.

adhesions divided sharply. Sometimes it is easier to visualize the right gastroepiploic arcade from the posterior aspect of the stomach as there may be less fat and the division of the gastrocolic ligament can be performed keeping the vascular arcade in view. To do this, the posterior wall of the stomach is grasped and elevated away from the pancreas and towards the hiatus and liver. Once the watershed between the gastroepiploic and the short gastric vessels has been reached, the division of the gastrosplenic ligament and the short gastric vessels is accomplished close to the gastric wall. This is facilitated by retracting the stomach to the patient's right side putting the ligament on some tension (*Figure 5A,B,C*). Care must be taken to be sure that the jaws of the energy device are completely across each of the vessels, which are taken in sequence, partial division will result in hemorrhage. Elevating the stomach off the retroperitoneum and retracting the fundus to the patient's right helps to expose the uppermost short gastric as well as the occasional

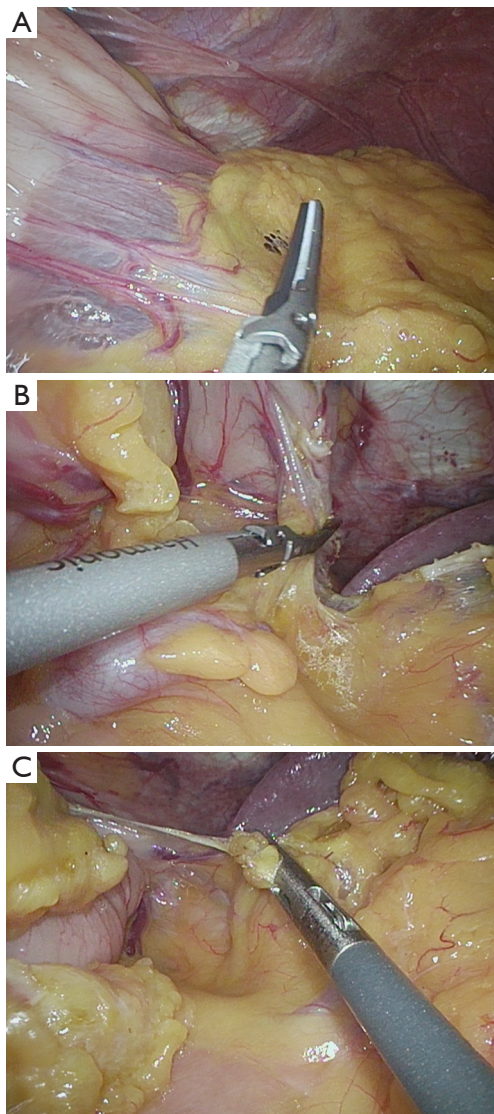


Figure 5 Completion of greater curve dissection. (A) Approaching the end of the right gastroepiploic; (B) division of short gastrics; (C) uppermost short gastric and additional branch arising from the splenic artery.

posterior branch coming off the splenic artery. Once these vessels are divided, the fundus is completely mobilized off the retroperitoneum and the left crus (*Figure 6A,B*). The hiatus is then entered medial to the left crus (*Figure 7*).

Attention is then turned to the distal antrum. Again elevating the stomach superiorly and anteriorly, adhesions between the posterior wall of the stomach and the pancreas are divided (*Figure 8A,B*). The gastrocolic ligament is divided as far as the level of the pylorus being careful to avoid injury to the right gastroepiploic as it arches

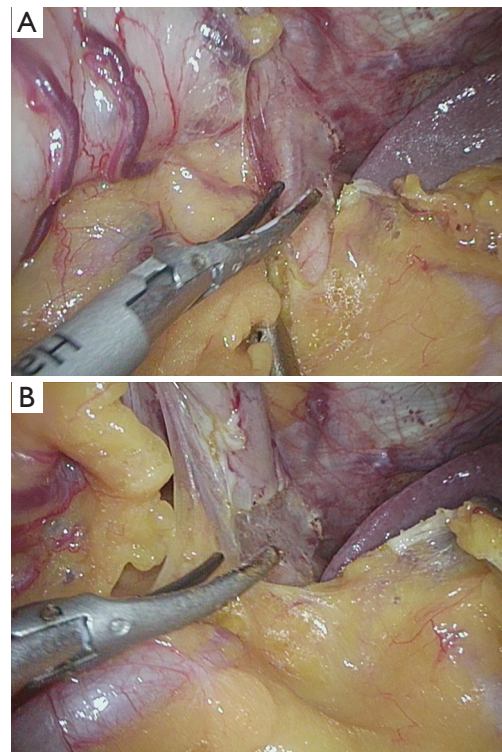


Figure 6 (A,B) Division of the attachments of the fundus to the left crus.

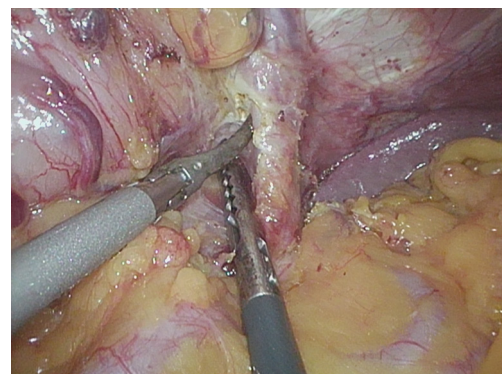


Figure 7 Opening the hiatus medial to the left crus.

posteriorly to its origin off the gastroduodenal artery. It is important to carefully mobilize the filmy posterior tissues at this level to improve visualization of the arcade as well as mobility of the distal stomach (*Figure 9*). This allows visualization of the pedicle proceeding posteriorly and separates the pedicle from the remaining gastrocolic ligament (*Figure 10*). Once this dissection is completed the pylorus is visible both anteriorly and posteriorly. I do not

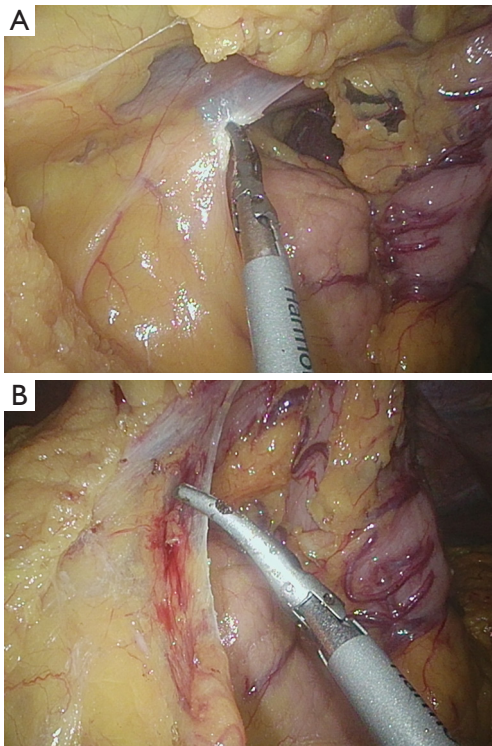


Figure 8 (A,B) Division of adhesions between the posterior wall of the stomach and the pancreas.

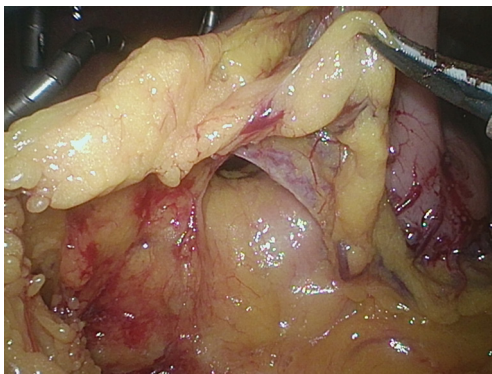


Figure 9 Division of filmy tissues posterior to the right gastroepiploic arcade.

perform a Kocher maneuver.

Left gastric artery (LGA) dissection

With the stomach otherwise fully mobilized, the left gastric pedicle is grasped near the lesser curvature and gentle cephalad traction applied. This puts the left gastric pedicle

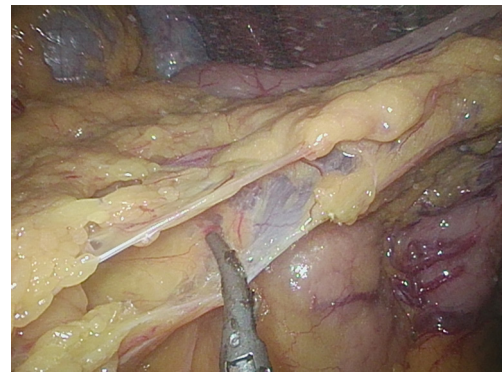


Figure 10 Completion of the retrogastric mobilization at the pylorus and division of gastrocolic ligament.

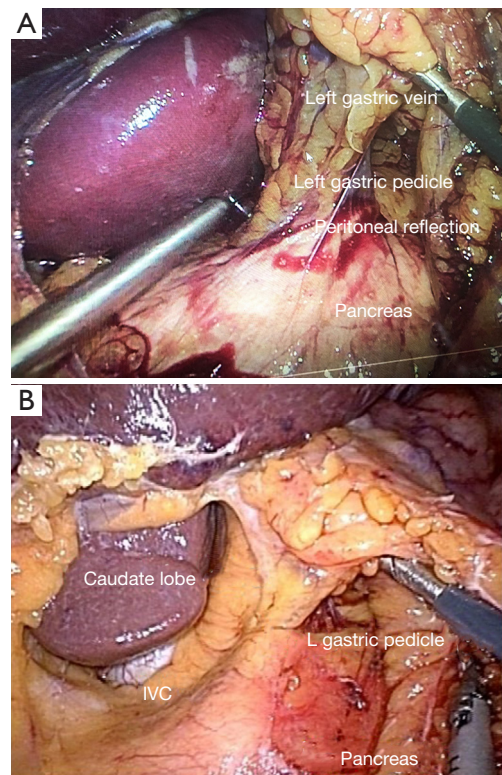


Figure 11 Left gastric pedicle dissection. (A) Upward traction on the left gastric pedicle facilitates identification of the peritoneal reflection where the dissection of the left gastric pedicle begins. (B) Upward traction on left. gastric pedicle exposes its origin.)

on some tension and helps to identify its origin (*Figure 11*). The peritoneum overlying the upper border of the pancreas is incised and then the plane of dissection deepened. The left gastric vein is divided at the base of the pedicle as it

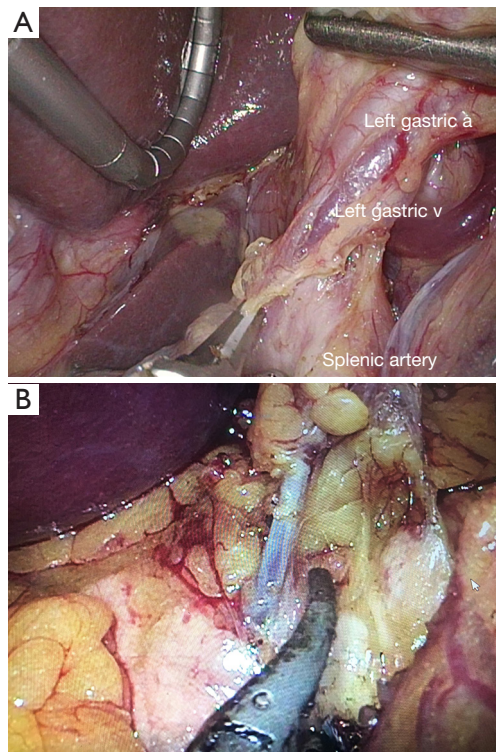


Figure 12 Exposure of left gastric artery and vein. (A) Dissection along the anterior aspect of the splenic artery, proceeding from left to right, allows identification of the left gastric vein. (B) Division of the left gastric vein facilitates dissection of the origin of the left gastric artery.

passes posteriorly and inferiorly to join the portal vein (*Figure 12*). The origin of the LGA and the trifurcation of the celiac artery into the LGA, common hepatic and splenic arteries is exposed (*Figure 13A*). It is important to see the origin of the 3 arteries as the LGA pedicle should be divided as close to its origin as possible. The LGA is skeletonized, sweeping the lymph node bearing fatty tissues up with the specimen. This dissection is facilitated by dividing the soft tissues between the origin of the LGA and the confluence of the right and left crura. The artery is taken either with an endovascular load of the endoGIA (Covidien) or if small, with clips. I previously completed the full lymph node dissection with the LGA intact (*Figure 13B*) and prior to creating the gastric conduit. I have found that division of the LGA and creation of the conduit allows better visualization for completion of the lymph node dissection.

Creation of the gastric conduit

Once the left gastric pedicle is divided, I create the gastric

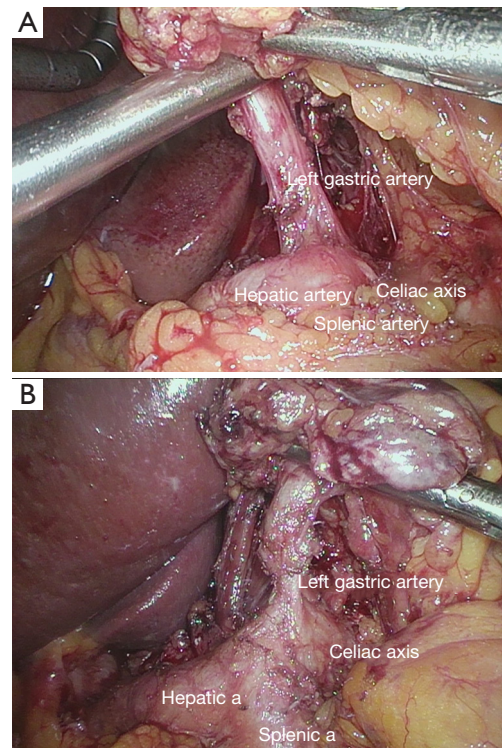


Figure 13 Dissection of the trifurcation of the celiac axis. (A) skeletonization of the left gastric artery; (B) skeletonization of the left gastric artery, common hepatic artery, splenic artery and celiac artery.

conduit. Applying traction on the fundus and opposing traction on the antrum, the creation of the conduit is initiated using an endoGIA 45 mm purple load tri stapler (Covidien) applied just below the Crow's foot (*Figure 14*). Multiple applications of the endoGIA stapler using either 45 or 60 mm purple Tri-Stapler cartridges are required to create a long narrow conduit. This is facilitated by articulating the stapler rather than applying it in its straightened configuration. We have also found that this reduces the problem of "spiraling" the conduit. The width of the conduit is approximately 4 cm as measured from the staple line to the greater curvature. Usually at total of 6 cartridges are required (*Figure 15A,B*). I completely divide the stomach in the abdomen having abandoned the practice of leaving the upper most portion of the fundus attached early on in my experience. This allows free mobility of the proximal resected stomach and facilitates dissection at the hiatus and in the lower mediastinum. It also reduces handling of the conduit and risk of injury. Once the creation of the conduit is completed, it is positioned inferiorly to improve visualization for the lymphadenectomy.

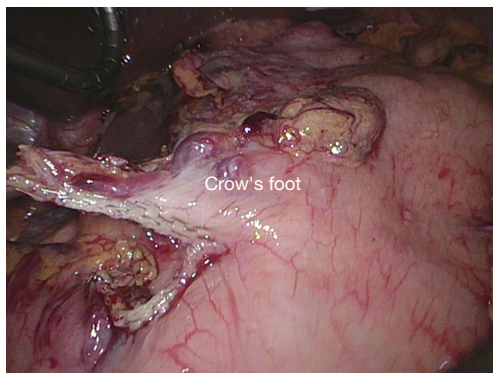


Figure 14 Initiation of gastric staple line just below Crow's foot.

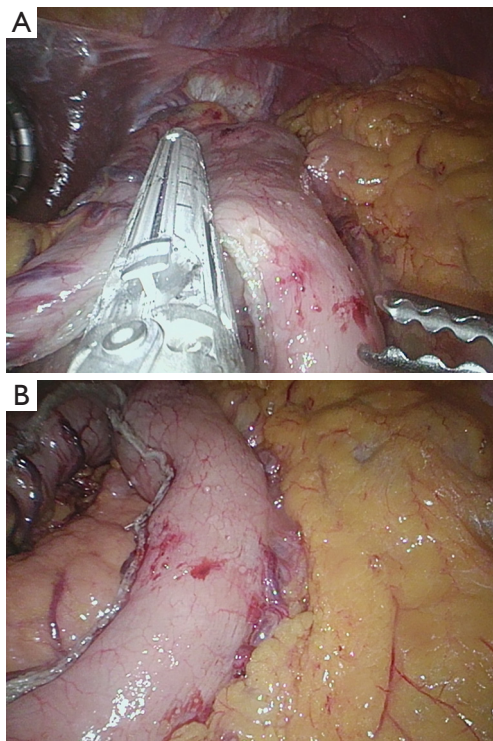


Figure 15 (A,B) Creation of gastric conduit.

Lymphadenectomy

At this point in the procedure, the left gastric nodes have been resected and are left attached to the resected proximal stomach. Beginning at the level of the left gastric stump, the peritoneum overlying the common hepatic artery is divided and then the hepatic artery is skeletonized from its origin to its division into right and left branches. The lymph node bearing tissue is then dissected off the cephalad border of the hepatic artery by gently retracting the origin

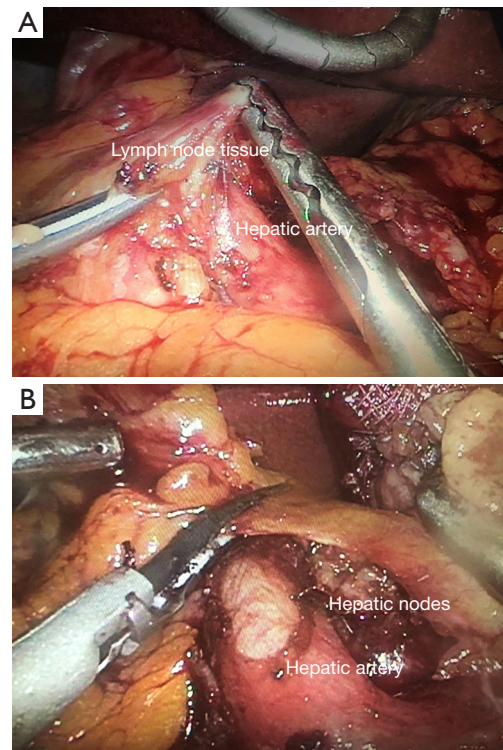


Figure 16 (A,B) Dissection of common hepatic lymph nodes.

of the common hepatic artery inferiorly (*Figure 16A,B*). When doing this, one must be aware that the portal vein lies posterior to the artery and can be exposed by retraction of the artery. Once these nodes are fully dissected, they are removed from the abdomen, usually in a sterile specimen bag and submitted as a separate specimen for pathology.

We next dissect the aortocaval nodes lying between the aorta/celiac axis and the inferior vena cava. This is accomplished using sharp dissection with the ultrasonic shears as well as blunt dissection with the suction device and/or peanut sponge. Many times there is very little tissue in this space and we do not do a formal dissection. The celiac nodes are dissected next, beginning at the level of the LGA stump and proceeding up to the confluence of the right and left crura (*Figure 17*). Lastly we skeletonize the splenic artery beginning at its origin and following it distally. We generally stop short of the splenic hilum but include the soft tissues overlying the retroperitoneum between the splenic artery and the left crus. Again, this is facilitated by gently retracting the pancreas inferiorly, being aware that the splenic vein lies just posterior to the artery (*Figure 18*). It is safest to follow the artery closely, staying right on the artery from proximal to distal, as the

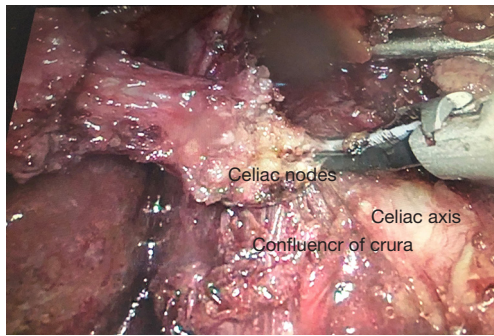


Figure 17 Dissection of celiac lymph nodes.

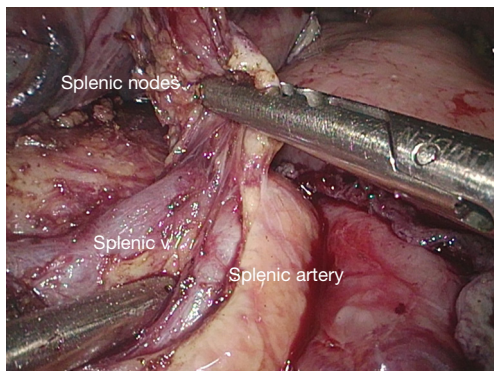


Figure 18 Dissection of splenic lymph nodes skeletonizing both splenic artery and vein.

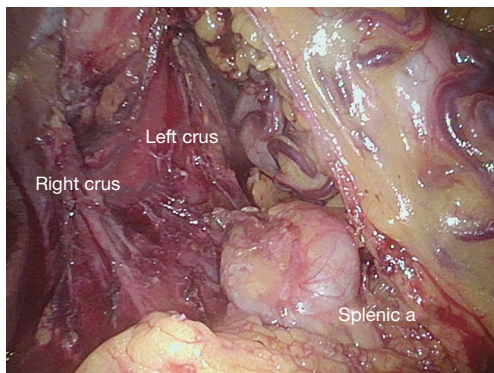


Figure 19 Dissection of splenic nodes must follow the artery to avoid injury to a tortuous artery.

artery may be quite tortuous and injury can result if the surgeon deviates away from the artery (*Figure 19*). Once the lymphadenectomy is completed the hepatic, splenic, left gastric and celiac arteries are completely skeletonized.

All lymph nodes are submitted as separate specimens,

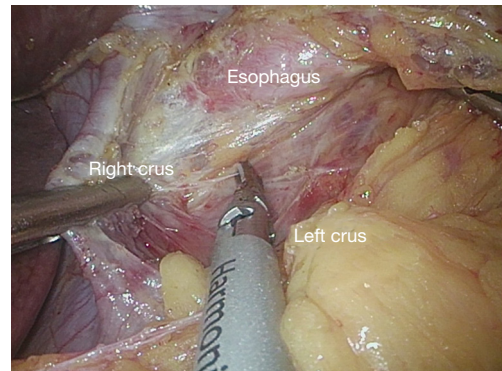


Figure 20 Beginning of the hiatal dissection skeletonizing both right and left crura posterior to esophagus.

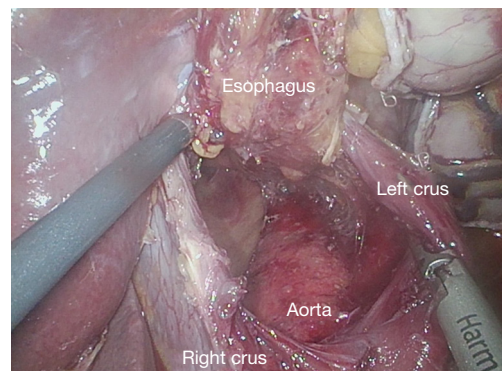


Figure 21 Continuing hiatal dissection by elevating the esophagus anteriorly, skeletonizing the descending thoracic aorta.

labelled appropriately as to their origin. This facilitates accurate nodal counts as well as localization of positive nodes.

Hiatal dissection

Following completion of the lymphadenectomy, we turn to the hiatal dissection. The hiatus is opened medial to the right crus. The confluence of the crura and left crus are exposed posteriorly (*Figure 20*). This is facilitated by retracting the resected proximal stomach to the patient's left. I expose the descending thoracic aorta above the hiatus and skeletonize it, sweeping all the fatty tissue up with the esophagus (*Figure 21*). I then come around to the right and open into the right pleural space, again taking the fatty tissue superior and adjacent to the hiatus with the esophagus. I continue around anteriorly and skeletonize the posterior pericardium (*Figure 22*). I divide the right inferior

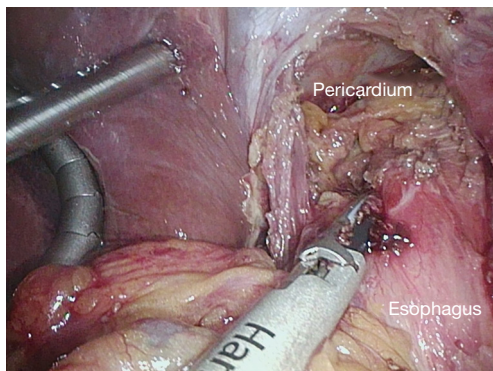


Figure 22 Continuing the hiatal dissection by retracting the esophagus posteriorly, skeletonizing the posterior pericardium.

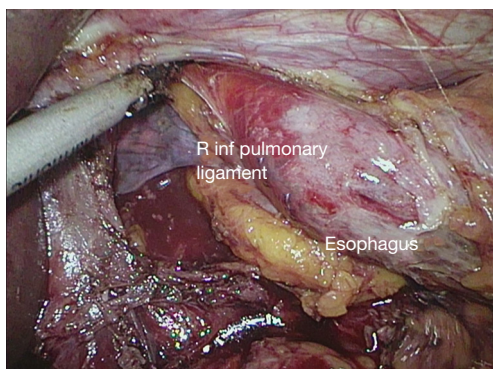


Figure 23 Continuing the hiatal dissection, entering the right pleural space, identifying the right inferior pulmonary ligament which will be partially divided from the abdomen.

pulmonary ligament close to the pulmonary parenchyma so that the lymph node bearing tissue in the ligament is included with our resected specimen (*Figure 23*). I retract the resected proximal stomach to the patient's right and similarly resect the perihial fatty tissue, the left pleura and left pulmonary ligament proceeding from posterior to anterior until I join the plane of dissection on the posterior pericardium. The hiatal dissection is facilitated by retracting each crus laterally to aid visualization of the lower mediastinum. We continue the dissection as high as is comfortable. We do not attempt to completely divide the inferior pulmonary ligaments and are careful as we proceed superiorly to avoid injury to the inferior pulmonary veins.

Once the hiatal dissection is complete, we suture the tip of the conduit to the lower portion of the resected proximal stomach using two sutures to maintain orientation. The liver retractor is then removed, followed by all ports, the

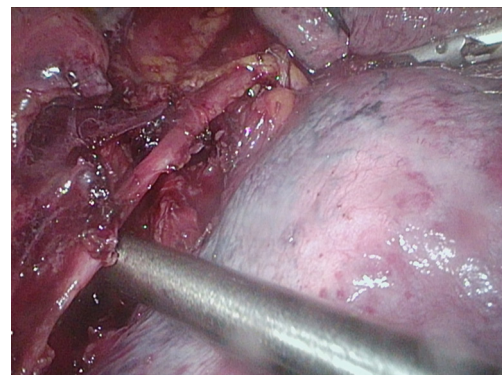


Figure 24 In the thoracic phase, after dividing the azygous vein and opening the pleural overlying the RMB, the right vagus nerve is identified prior to its division.

CO₂ is evacuated from the abdomen and the port sites are closed in standard fashion. We then insert a chest tube into the left pleural space through a small incision in the left inframammary fold in the anterior axillary line. We have recently moved from 28 to 20 Fr chest tubes.

Thoracic phase

Once the abdomen is closed the patient is repositioned into the left lateral decubitus position, leaning slightly anteriorly. Many surgeons are now doing the thoracic phase in the prone position and we believe this likely offers many advantages but we have not yet made this transition. The semiprone approach is a compromise with the operating surgeon standing at the front of the patient.

Generally, we use four ports: three in the anterior axillary line 3rd, 5th and 7th interspace and one posteriorly in the 8th or 9th interspace. All port sites are infiltrated with 0.05% Marcaine with epinephrine prior to making the skin incisions. We use a closed system with CO₂ insufflation to a pressure of 8 mmHg for the initial dissection. The lung is retracted anteriorly (the more prone the patient, the less retraction is required).

The pleura above and below the azygous vein arch is divided, the azygous vein skeletonized and then taken with the endo-GIA vascular load. The esophagus is gently retracted posteriorly and the pleura overlying the right main bronchus (RMB) is carefully opened beginning at the level of the divided azygous vein and proceeding inferiorly. The right vagus is divided as it crosses the RMB (*Figure 24*). Keeping posterior traction on the esophagus, the esophagus is mobilized off the posterior pericardium from the level of

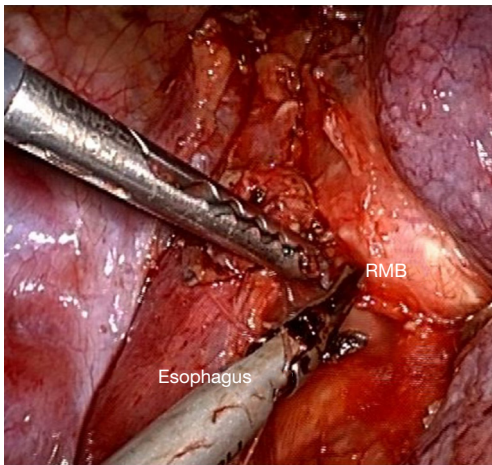


Figure 25 The esophagus is dissection off the right main bronchus (RMB) together with the subcarinal nodes.

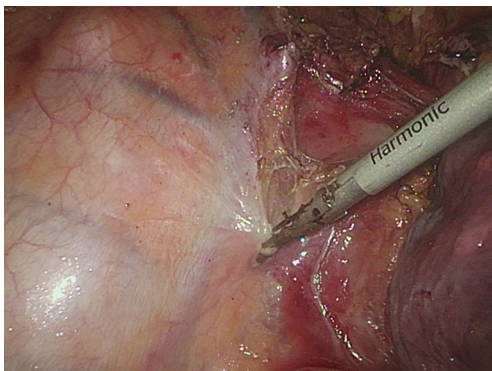


Figure 26 The pleura anteromedial to the ascending azygous vein is divided from the level of the divided azygous vein down to the hiatus.

the RMB down to the level achieved by the hiatal dissection during the abdominal phase. During this dissection, we may leave the subcarinal node packet in situ or remove it with the esophagus depending on the ease of removal. As we proceed from the right RMB inferiorly, we skeletonize the right inferior pulmonary vein. The mobilization of the esophagus away from the pericardium is continued proceeding from the right toward the left until the left inferior pulmonary vein is identified and skeletonized. The esophagus is then mobilized off the distal trachea, tracheal carina and left main bronchus (Figure 25). Extreme care must be used to avoid thermal injury to the membranous airways. The LMB is particularly at risk because of distension by the bronchial balloon of the double lumen tube. Once the distal trachea and LMB are

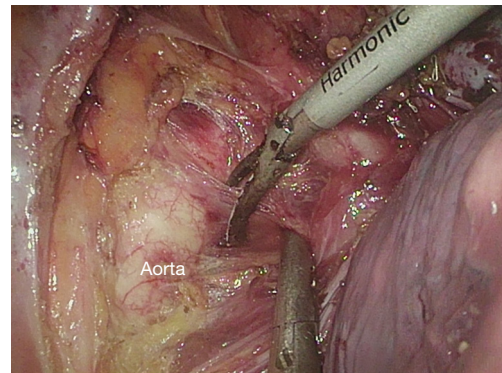


Figure 27 The esophagus is mobilized off the descending aorta, skeletonizing the aorta.

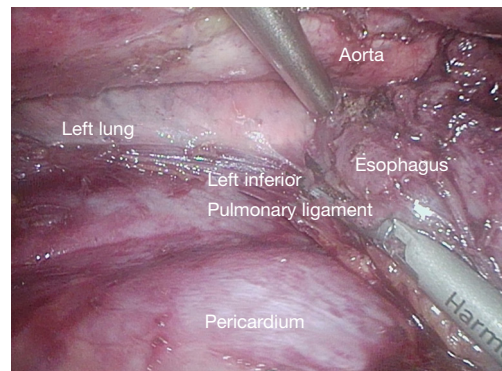


Figure 28 The left inferior pulmonary ligament is divided.

fully exposed, attention is directed to the dissection of the esophagus posteriorly.

The esophagus is retracted anteriorly, and the pleura anteromedial to the ascending azygous vein is incised beginning at the level of the divided azygous arch and proceeding inferiorly down to the hiatus (Figure 26). The esophagus is the dissected off the descending aorta (Figure 27). The aorta is skeletonized from the aortic arch down to the hiatus exposing the left lung and left inferior pulmonary ligament (Figure 28). Most of the branches off the aorta can be managed with the ultrasonic shears, but it is prudent to leave a short stump of these branches on the aortic side to allow for placement of a clip or suture, if hemostasis with the ultrasonic shears is insufficient. Particularly troublesome are two small branches arising from the undersurface of the arch itself.

If the thoracic duct is to be removed, this is accomplished as part of the skeletonization of the aorta taking care to clip the duct inferiorly just above the hiatus as well as

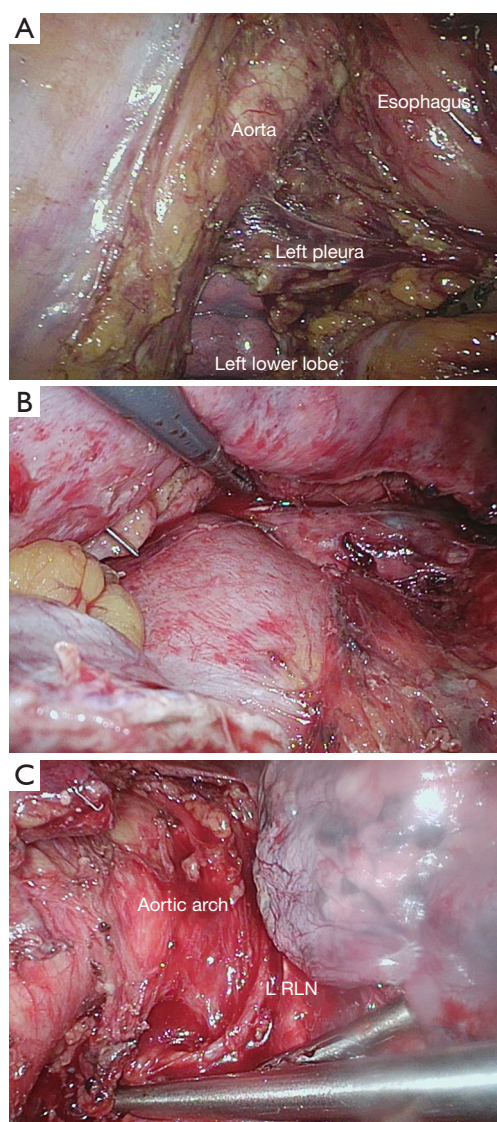


Figure 29 Paraaortic dissection. (A) The division of the left pleura is completed, beginning inferiorly and ascending beside the aorta. (B) The dissection is continued along the aorta, skeletonizing the left inferior pulmonary vein, exposing the left main bronchus and dividing the left vagus nerve between the distal left main bronchus and the left inferior pulmonary vein. (C) The dissection is continued along the aorta up to the arch where the left recurrent nerve is identified as it comes around the arch and is carefully preserved.

superiorly where it crossed from right to left just at the level of the aortic arch and the arch of the azygous vein. I do not routinely take the thoracic duct.

Once the descending aorta has been skeletonized, the division of the left pleura and the left inferior pulmonary

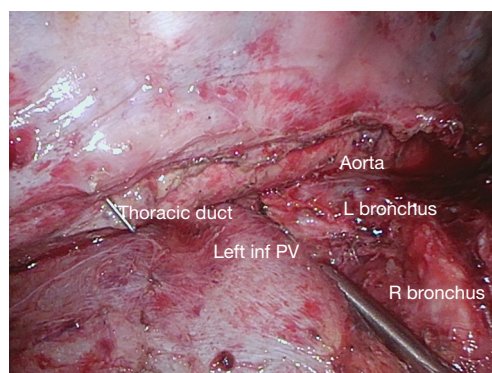


Figure 30 The completed infracarinal dissection.

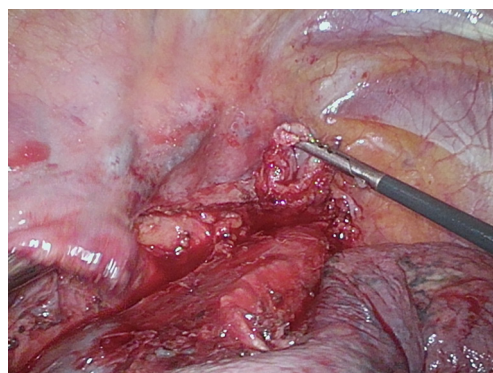


Figure 31 The esophagus is divided sharply, several centimetres about the divided azygous vein.

ligament is completed proceeding from the lower chest superiorly (*Figure 29A,B*), skeletonizing the left inferior pulmonary vein and then dividing the left vagus nerve just above the left inferior pulmonary vein. The esophagus is then fully mobilized away from the aortic arch, LMB and distal trachea (*Figure 29C*). At this level, dissection is kept close to the esophagus to avoid injury to the left recurrent nerve. Once the infracarinal dissection is completed, the RMB, left main bronchus, carina, right and left inferior pulmonary veins, descending aorta and posterior pericardium have been skeletonized (*Figure 30*).

I generally dissect the esophagus for 4–6 cm above the azygous vein and then divide the esophagus 3 cm above the divided azygous vein (*Figure 31*). The esophagus is divided with the ultrasonic shears as I use an EEA stapler (Covidien) for my anastomosis. If the Orvil stapler or linear stapler is to be used, the esophagus may be divided using the endoGIA stapler.

We then turn off the CO₂ insufflation, and enlarge the anterior superior port. The resected proximal stomach and

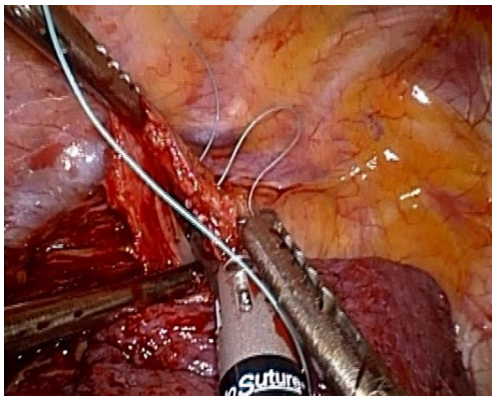


Figure 32 The first purse-string suture is placed in the divided end of the esophagus using the EndoStitch device.

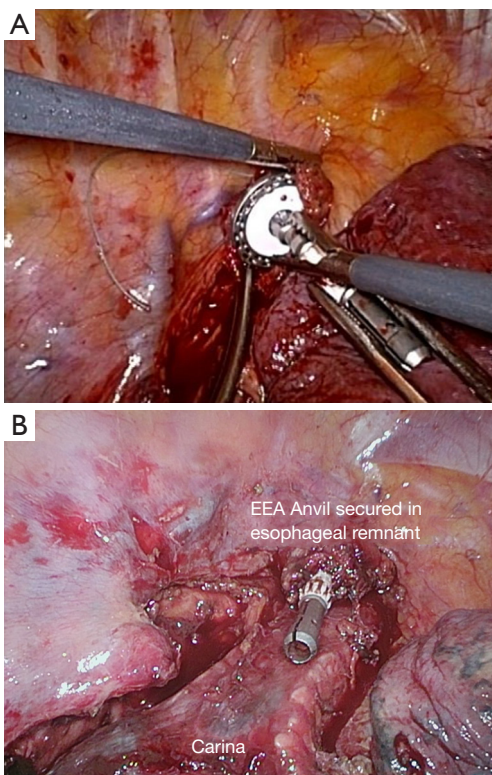


Figure 33 (A) The 25 mm EEA anvil is rotated into the divided end of the esophagus and then secured with the first purse-string. (B) A second purse-string suture is placed and the esophageal remnant with the anvil lies at the apex of the chest.

attached conduit are delivered into the chest and the sutures holding them together are divided. A large heavy specimen bag is then introduced into the chest, the resected specimen is placed in the bag and together they are extracted from the

chest. On a back table, lymph nodes are separately harvested off and sent as separate specimens (left gastric nodes, pericardial nodes, periesophageal nodes, subcarinal nodes if attached). Margins are inspected. Generally, a margin from the divided end of the esophagus is sent for frozen section but if the gastric margin looks close, this will be sent as well.

Once the specimen is removed, we dissect out the subcarinal lymph node packet if these have been left in situ, skeletonizing the main bronchi, carina and posterior pericardium if this has not been done previously. If the upper mediastinal node dissection is performed, it is at this point in the procedure that this is undertaken. We use bipolar energy and blunt dissection for this lymphadenectomy, taking the paratracheal tissue off the lateral walls of the trachea up to the right innominate artery and the common carotid on the left. This has not been a routine part of our procedure as most of our patients have cancers of the distal esophagus and gastroesophageal junction. However, we have had late isolated recurrences in this region and are starting to incorporate the paratracheal dissection as a routine part of the operation.

Anastomosis

I continue to use a standard EEA stapling device (Covidien) for the anastomosis. A purse string suture of 2-0 Tevdek using the EndoStitch device (Covidien) is placed (*Figure 32*). The EEA anvil is then introduced through the anterior access incision. Grasping the end of the esophagus at two points, the anvil is rotated into the lumen and secured in place by tying the ends of the purse-string suture (*Figure 33A*). We do not use the EndoStitch device for tying the first purse-string, instead we cut the suture at the level of the needle and do an intracorporeal knot using two needle holders. We then reinforce the closure with a second purse-string of 2-0 Tevdek using the EndoStitch device, this time using the device to complete the knot (*Figure 33B*).

The conduit is then delivered fully into the chest. Generally the distal end of the lesser curve staple line lies just above the hiatus. This leaves the portion of the antrum close to the pylorus below the diaphragm. This is important to eliminate stasis in the antrum if it is pulled into the chest and sits on the diaphragm. The conduit is delivered by applying gently upward and anterior traction to avoid trauma to the vascular pedicle. Care must be taken to ensure that the conduit is not twisted as it is delivered into the chest. The lesser curve staple line should face upward away from the mediastinum, and the vascular pedicle should face down into the mediastinum.

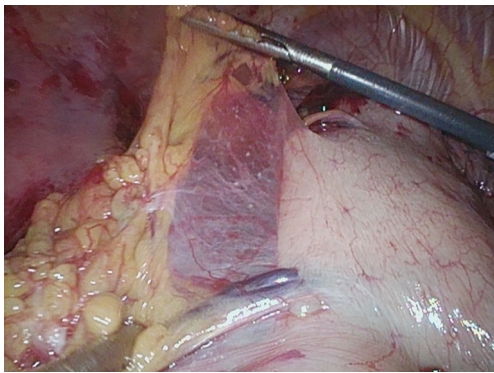


Figure 34 The greater curve of the gastric conduit is inspected to identify the end of the right gastroepiploic arcade.

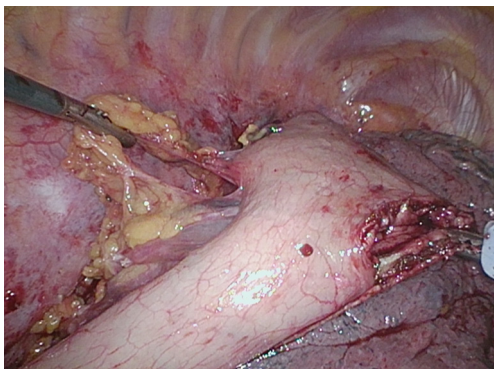


Figure 35 A gastrotomy is made adjacent to the lesser curve staple line opposite the site identified as the end of the right gastroepiploic arcade.

We then inspect the greater curve and identify the end of the right gastroepiploic arcade (*Figure 34*). A gastrotomy is then made adjacent to the lesser curve staple line using the L-hook opposite to the end of the right gastroepiploic arcade (*Figure 35*). The contents of the gastric conduit are evacuated. The EEA stapler is then introduced through the access incision, through the gastrotomy and positioned such that the point of the stapler extrudes through the greater curvature just above the end of the gastroepiploic arcade (*Figure 36A*). The stapler is angled upward and docked on the previously placed anvil (*Figure 36B*), turned down and fired. The stapler is turned back 5 half turns and removed. The donuts are inspected and also the anastomosis is inspected through the gastrotomy (*Figure 37*). Finally the gastrotomy is closed and redundant stomach is resected with 1 or more firings of the endo-GIA stapler (*Figure 38*). We generally find we have excess conduit and by placing the

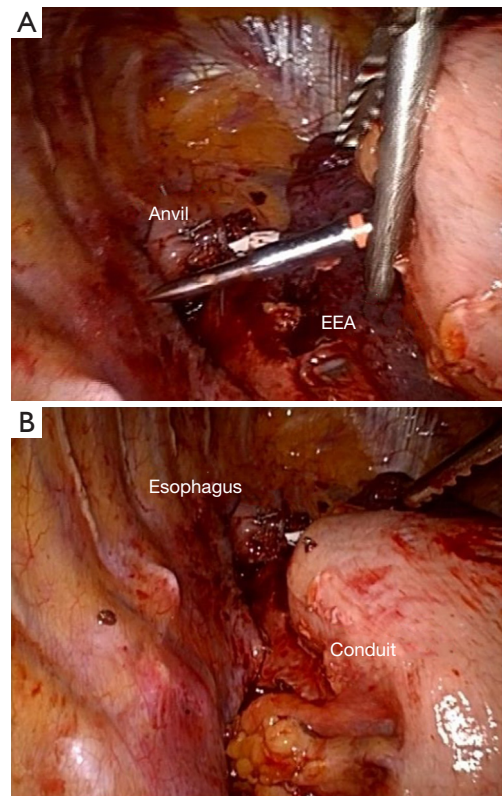


Figure 36 (A) The EEA stapler is brought in through the anterior access incision, introduced into the conduit through the gastrotomy, the point is deployed at the site chosen for the anastomosis. (B) The stapler is rotated upward, stretching the conduit, and docked on the previously placed anvil.

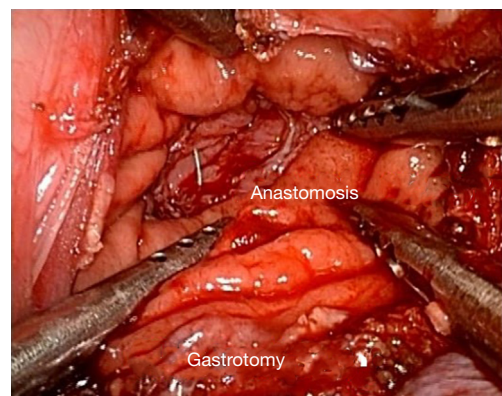


Figure 37 After docking the stapler on the anvil, the stapler is fired, turned back and removed. The anastomosis is inspected through the gastrotomy.

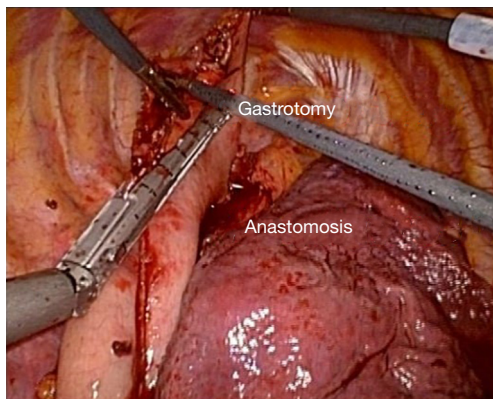


Figure 38 The gastrotomy is closed and the redundant upper stomach is resected with 1 or more fires of the endoGIA stapler.

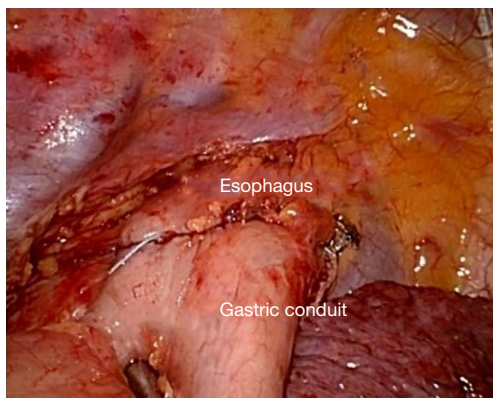


Figure 39 The exterior aspect of the anastomosis is inspected circumferentially.

anastomosis lower on the greater curve adjacent to the right gastroepiploic arcade, we are able to place the anastomosis in a well vascularized part of the stomach and resect the more ischemic upper portion of the conduit. The external aspect of the anastomosis is inspected circumferentially (*Figure 39*). The anastomosis may be reinforced with sutures if there are any areas of concern. The final reconstruction should lie straight without redundancy with the anastomosis high in the chest (*Figure 40*).

It can be difficult to advance the stapler between the ribs. Generally we use a 25 mm stapler and have found this to provide a satisfactory lumen without stricture or dysphagia. If the esophagus is very large, a 28 mm anvil may be required but it is even more difficult to pass the stapler between the ribs. Some surgeons introduce the stapler through an inferior port site where the interspaces

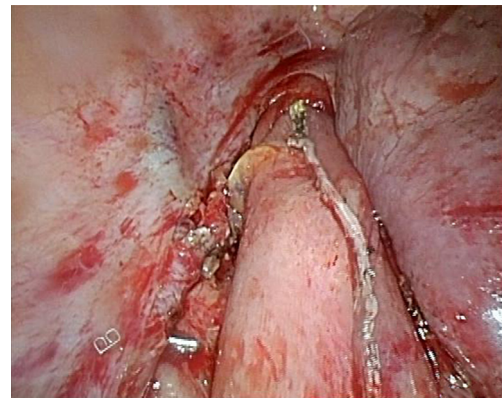


Figure 40 The completed reconstruction. The conduit is straight without redundancy and the lesser curve staple line faces up away from the mediastinum.

are wider. The stapler can then be introduced into the stomach through a lesser curve gastrotomy as described or through the uppermost end of the conduit, pulling the conduit onto the stapler like a sock. My own experience with these methods is limited. When using these methods I have experienced some difficulty in placing the anastomosis exactly in the desired location on the great curve tending to always be higher than intended, but perhaps this would be overcome with more experience.

An alternative anastomotic technique uses the ORVIL device (Covidien). The Orvil device passed *per os* into the esophageal remnant. It can be challenging to get it to pass the upper sphincter and we have often scrubbed out to assist our anaesthesiologist with this step using a laryngoscope. A small esophagotomy is made adjacent to the stapled end of the esophageal remnant and the delivery device is advanced through the esophagotomy into the chest until the circular portion of the anvil is seated at the esophageal staple line with the post fully positioned beyond the esophagotomy. The EEA stapler is then docked on the anvil, turned down and fired. Problems have arisen with leaks, largely related to the crossing staple lines. This has led some surgeons to move the esophagotomy from the middle of the esophageal staple line to one corner or to a site positioned 1 cm away from the esophageal staple line. We have moved away from the Orvil because of our high leak rate when using the device. Surgeons who continue to use it, anecdotally report reinforcing the anastomosis with sutures, particularly where staple lines cross.

Another alternative is to use the linear endoGIA to create a side to side, functional end to end anastomosis

either using the Orringer technique or a modified Collard technique. Both of these techniques require a longer length of esophageal remnant. These create a larger diameter anastomosis and are useful in a very dilated esophagus. After creating the anastomosis with the linear stapler using either a 30 or 45 mm cartridge, the front wall is sewn with a running or interrupted suture such as 3-0 PDS or Vicryl. A v-lock suture can also be used. Some surgeons report using another endo GIA to close the front wall but there is a risk of narrowing the anastomosis so we prefer to sew the front wall.

Following completion of the anastomosis, the anastomosis is submerged under warm saline and an endoscopy is performed insufflating air into the esophageal reconstruction. The absence of bubbles in the saline is reassuring that there is no technical leak. We have found this quite useful not only for the anastomosis but also for the occasional injury to the conduit, or leak at the gastric staple line. The gastroscope is advanced through the pylorus and then withdrawn verifying the correct orientation of the conduit. We find that passing the scope through the pylorus serves to dilate it somewhat.

We then place a #10 flat Jackson-Pratt drain in the posterior mediastinum adjacent to the anastomosis and a separate 20 Fr intercostal drain brought out through the inferior port site. Intercostal nerve blocks (8) are placed and the chest is closed. A nasogastric sump drain is positioned within the intrathoracic conduit.

The patient is awakened and extubated in the operating room. Postoperative pain is managed with patient controlled IV analgesia using hydromorphone. Chest tubes are removed after 48–72 hours and the JP drain is left in situ for measurement of drain amylase. The ng is usually removed after 48–72 hours although we have removed it after 24 hours.

Summary

The minimally invasive Ivor Lewis esophagectomy includes all the essential components of the open operation. There will always be some variation between surgeons. It is important that each surgeon assess their outcomes, and perfect their technique to provide the best outcome for the patient. From the oncologic perspective an R0 resection and adequate lymphadenectomy are key. From the patient perspective the ability to eat and swallow comfortably are key which relates to a reliable anastomosis that doesn't leak or stricture and a straight nonredundant conduit that

empties well. Additionally reducing reflux by placing the anastomosis as high in the chest as possible will improve patient comfort. As we improve survival from esophageal cancer with combined modality therapy and improved operations, we should strive to provide patients with the best possible quality of life.

Acknowledgments

Funding: None.

Footnote

Provenance and Peer Review: This article was commissioned by the Guest Editors (Christopher R. Morse and Uma M. Sachdeva) for the series “Minimally Invasive Esophagectomy” published in *Annals of Esophagus*. The article has undergone external peer review.

Conflicts of Interest: The author has completed the ICMJE uniform disclosure form (available at <http://dx.doi.org/10.21037/aoe-20-26>). The series “Minimally Invasive Esophagectomy” was commissioned by the editorial office without any funding or sponsorship. The author has no other conflicts of interest to declare.

Ethical Statement: The author is accountable for all aspects of the work in ensuring that questions related to the accuracy or integrity of any part of the work are appropriately investigated and resolved.

Open Access Statement: This is an Open Access article distributed in accordance with the Creative Commons Attribution-NonCommercial-NoDerivs 4.0 International License (CC BY-NC-ND 4.0), which permits the non-commercial replication and distribution of the article with the strict proviso that no changes or edits are made and the original work is properly cited (including links to both the formal publication through the relevant DOI and the license). See: <https://creativecommons.org/licenses/by-nc-nd/4.0/>.

References

1. Giugliano DN, Berger AC, Rosato EL, et al. Total minimally invasive esophagectomy for esophageal cancer: approaches and outcomes. *Langenbecks Arch Surg* 2016;401:747-56.
2. Claassen L, van Workum F, Rosman C. Learning curve

- and postoperative outcomes of minimally invasive esophagectomy. *J Thorac Dis* 2019;11:S777-S785.
3. van Workum F, Stenstra MHBC, Berkelmans GHK, et al. Learning Curve and Associated Morbidity of Minimally Invasive Esophagectomy: A Retrospective Multicenter Study. *Ann Surg* 2019;269:88-94.
 4. Tapias LF, Morse CR. Minimally invasive Ivor Lewis esophagectomy: description of a learning curve. *J Am Coll Surg* 2014;218:1130-40.
 5. Lewis I. The surgical treatment of carcinoma of the oesophagus; with special reference to a new operation for growths of the middle third. *Br J Surg* 1946;34:18-31.
 6. Mathisen DJ, Grillo HC, Wilkins EW Jr, et al. Transthoracic esophagectomy: a safe approach to carcinoma of the esophagus. *Ann Thorac Surg* 1988;45:137-43.
 7. Cuschieri A, Shimi S, Banting S. Endoscopic oesophagectomy through a right thoracoscopic approach. *J R Coll Surg Edinb* 1992;37:7-11.
 8. Watson DI, Davies N, Jamieson GG. Totally endoscopic Ivor Lewis esophagectomy. *Surg Endosc* 1999;13:293-7.
 9. Luketich JD, Schauer PR, Christie NA, et al. Minimally invasive esophagectomy. *Ann Thorac Surg* 2000;70:906-11; discussion 911-2.
 10. Luketich JD, Alvelo-Rivera M, Buenaventura PO, et al. Minimally invasive esophagectomy: outcomes in 222 patients. *Ann Surg* 2003;238:486-94; discussion 494-5.
 11. Luketich JD, Pennathur A, Awais O, et al. Outcomes after minimally invasive esophagectomy: review of over 1000 patients. *Ann Surg* 2012;256:95-103.

doi: 10.21037/aoe-20-26

Cite this article as: Darling GE. Ivor Lewis minimally invasive esophagectomy. *Ann Esophagus* 2021;4:18.