doi: 10.3978/j.issn.2095-6959.2021.10.038
View this article at: https://dx.doi.org/10.3978/j.issn.2095-6959.2021.10.038

·临床病例讨论·

婴儿骨外尤文肉瘤 1 例并文献复习

马秀才[1]，买自林[2]，罗国栋[1]，绽春蕊[1]，刘鹏[1]，俞永智[1]，宋建民[1]

(1. 甘肃省人民医院骨与软组织肿瘤科，兰州 730000; 2. 吴忠市人民医院骨科，宁夏 吴忠 750003)

[摘　要] 婴儿骨外尤文肉瘤发病罕见、恶性程度高，其治疗是采用手术、放射治疗和化学药物治疗于一体的综合治疗，手术广泛切除是治疗的关键。因此，规范化诊治对患儿预后尤为重要。尽管婴儿放射治疗和化学药物治疗风险极高，但仍需实施，剂量和周期的把握有待大量临床样本进一步证实。本文报告1例骨外尤文肉瘤婴儿诊疗经过并复习文献，探讨婴儿骨外尤文氏肉瘤规范化诊治的重要性及特点。

[关键词] 婴儿；骨外尤文肉瘤；规范化诊疗；广泛切除

Extraskeletal Ewing's sarcoma in infant: A case report and literature review

MA Xiucai[1], MAI Zilin[2], LUO Guodong[1], ZHAN Chunrui[1], LIU Peng[1], YU Yongzhi[1], SONG Jianmin[1]

(1. Department of Bone and Soft Tissue Tumors, Gansu Province Hospital, Lanzhou 730000; 2. Department of Orthopedics, Wuzhong City People's Hospital, Wuzhong Ningxia 750003, China)

Abstract Extraskeletal Ewing's sarcoma (EES) in infant is rare, and has a high degree of malignancy. The treatment of EES is a combination of surgery, chemotherapy, and radiotherapy, extensive excision is the key to the treatment. Therefore, the standardized diagnosis and treatment are particularly important for prognosis of patients. Although the risk of radiotherapy and chemotherapy for infants is very high, it still needs to be carried out, and the dosage and cycle of treatment still need to be confirmed by a large number of clinical samples. The report combined the clinical data of one infant EES case with literature review to explore the feature and importance of standardized diagnosis and treatment in infant EES.

Keywords infant; extra-skeletal Ewing's sarcoma; standardized diagnosis and treatment; extensive excision

尤文肉瘤是好发于青少年下肢长管骨的恶性肿瘤，是起源于骨髓内小圆细胞的原发恶性骨肿瘤，也有来自神经的小圆细胞恶性肿瘤，与原发性神经外胚层肿瘤(primitive neuroectodermal tumors，PNET)的病理特性非常相似[1-3]。骨外尤文肉瘤(extraskeletal Ewing's sarcoma，EES)是

收稿日期 (Date of reception)：2020–10–23
通信作者 (Corresponding author)：宋建民，Email: songjm_lz@163.com
基金项目 (Foundation item)：甘肃省人民医院国自然孵育计划项目 (19SYPYB-22)。This work was supported by the Natural Incubation Program of Gansu Provincial People's Hospital, China (19SYPYB-22).

来源于神经外胚层的恶性肿瘤，其恶性度高、侵袭性强[4-5]。发生于婴儿EES罕见。甘肃省人民医院骨与软组织肿瘤科2019年5月收治1名婴儿EES患者，现总结分析该病例特点，为提高临床工作者对该病的认识以及规范化的诊治提供良好的思路。

1 临床资料

患儿，男，5个月，因“右肘部尤文肉瘤术后2周”入院。患儿2周前因右肘部软组织包块就诊于某大型医院，行右肘部X线片(图1)及CT(图2)检查，见肘部软组织肿胀，未侵及骨组织，考虑为恶性肿瘤。行肘部软组织肿瘤切除术，术后病检提示EES。由于病理检查结果为恶性肿瘤，术后半月患者家属为求进一步治疗入住我院。入院体格检查：右肘部外侧可见约7 cm纵行手术疤痕，切口愈合良好，局部轻度肿胀，无明显压痛。辅助检查：血常规及生化检查未见明显异常。右上臂局部B超示：右肘部软组织肿物，不均质回声，无明显血流信号。右上臂MRI(图3)示：T1、T2右上臂远端骨髓水肿信号，周围软组织轻度肿胀，局部呈术后改变。胸部CT未见转移等异常表现。对于该患儿的诊治非常慎重，组织全院相关科室会诊。结合该患儿第1次外院术后病理报告，会诊结果建议行化学药物治疗(以下简称化疗)或放射(以下简称放疗)，考虑到该患儿年龄偏小，化疗剂量很难把握，并且化疗风险很高，充分和家属沟通后，家属拒绝化疗。鉴于患儿处于生长旺盛期，局部放疗会影响右上肢正常发育，再次向患儿家属交代后，家属拒绝行放疗。我科团队再次详阅核磁共振影像后，考虑到当时外院在未明确诊断前提下行软组织肿瘤切除，切除范围有限，局部仍有瘤组织残留，一致建议行瘤床广泛切除术。于入院后10日在全身麻醉下行右上臂瘤床广泛切除术，术中见右侧肱三头肌及肱桡肌之间软组织肿物，与周围软组织边界欠清，距病变边界外2 cm切下肿物，大小约8 cm × 3 cm × 2 cm条索状。术后切开瘤床组织，局部仍可见鱼肉状瘤组织残留(图4)。术后病检提示标本中仍有瘤组织残留，切缘未见肿瘤细胞，并对切片进行HE染色及免疫组织化学分析，再次明确诊断的准确性(图5)。

该患者第2次手术后，切口愈合后出院，当时建议行放疗或化疗辅助治疗，但其家属因婴儿年龄小，放化疗风险高而拒绝进一步辅助治疗。术后3个月随访，局部未见异常肿物，肺部CT仍无明显异常。术后半年患者家属未返院复查，术后14个月患儿出现呼吸困难，至当地医院行肺部CT示大量转移病灶并胸腔积液，给予对症治疗后症状仍未见好转，入院后3周出现呼吸衰竭，后家属放弃治疗。

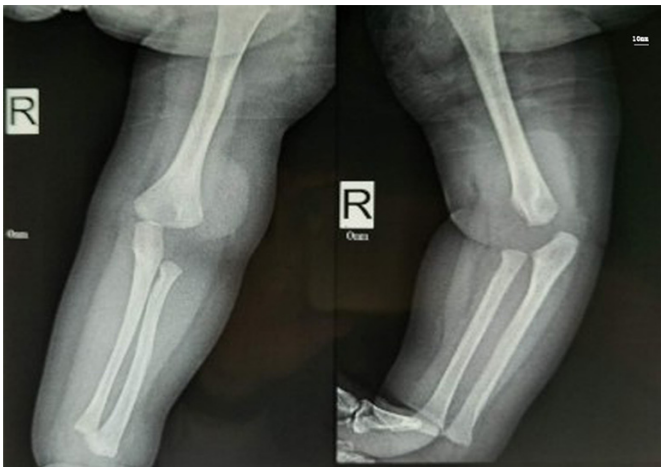

第一次术前X线片

图1 第1次术前上肢X线检查，示右肱骨远端外侧可见约6 cm × 5 cm大小异常肿物，骨质未见明显侵犯

Figure 1 The first preoperative X-ray examination of the upper limb showed an abnormal mass of about 6 cm × 5 cm in size on the lateral side of the distal right humerus, without significant bone invasion

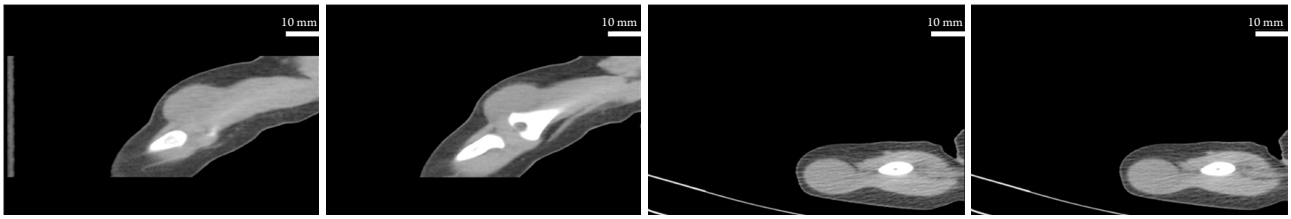

图2 第1次术前上肢CT检查：矢状位及横断面均提示肱骨远端异常软组织肿胀影，骨质未见明显侵袭，恶性肿瘤可能

Figure 2 The first preoperative CT examination of the upper limb and its sagittal and cross-sectional views showed abnormal soft tissue swelling in the distal humerus; no obvious invasion of bone was observed, and malignant tumor was possible

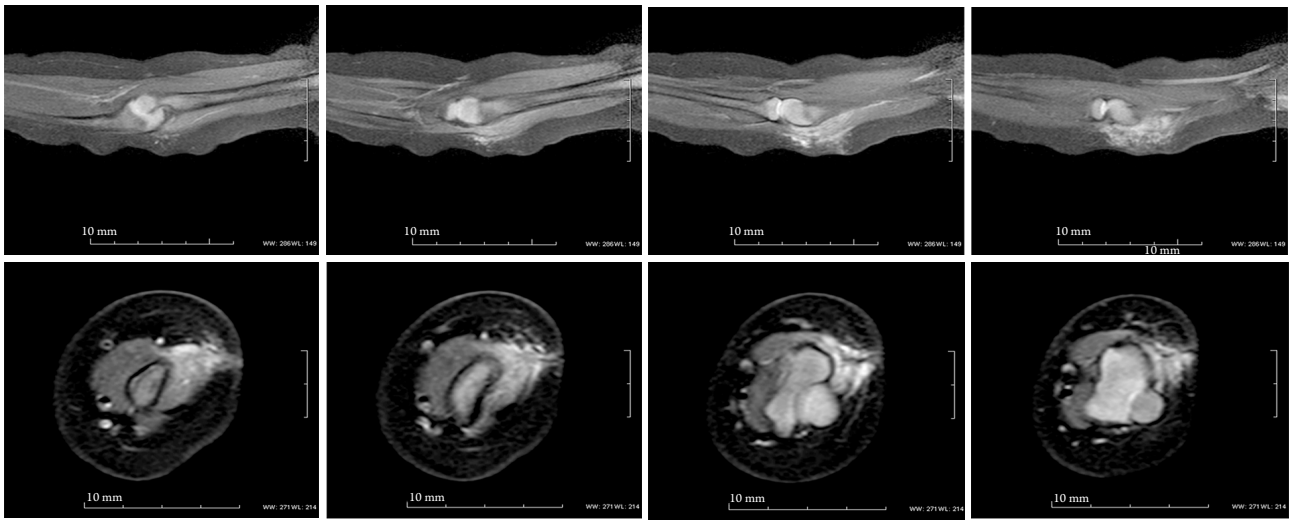

图3 第1次术后复查MRI：右侧肱骨外上髁肱桡肌肿胀，其内可见片絮状长T1、PDWI高信号影，边界迷糊，肱骨下端及桡骨小头骨髓水肿

Figure 3 MRI examination after the first surgery revealed swelling of brachioradialis muscle of the right lateral epicondylar humerus, with flocculent long T1 and PDWI hyperintensity shadow inside, blurred boundary, and edema of bone marrow of the lower humerus and radial head

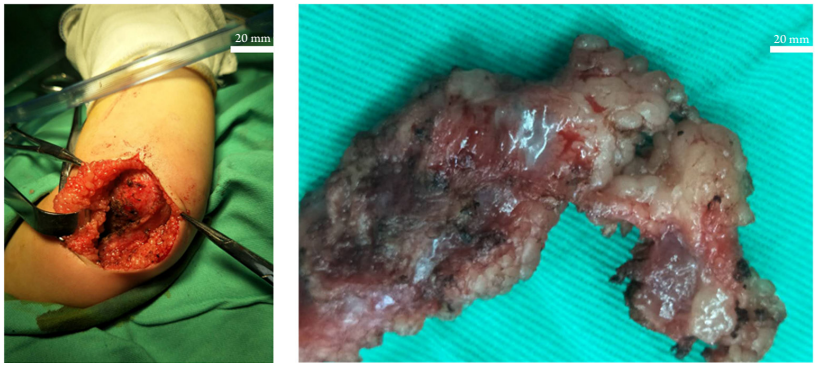

扩大切除术后创面　　扩大切除术后标本外观照

图4 肿瘤被扩大切除后创面外观照示肱桡肌周围病灶组织被彻底切除；切除后标本外观照示切开标本后可见鱼肉状肿瘤残留

Figure 4 External observation of the wound after the enlarged resection of the tumor revealed that the foci surrounding the brachioradialis muscle had been completely excised; external observation of the specimen after excision showed that fish-like tumor remained after the specimen was cut open

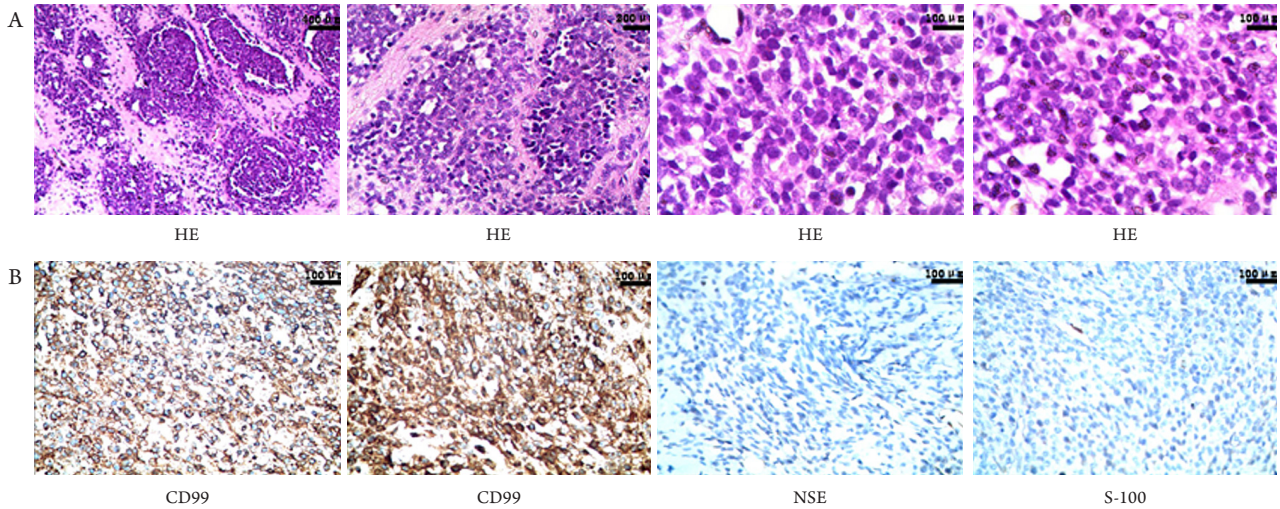

图5 病理HE染色不同放大倍数下镜下表现及免疫组织化学关键分子表达情况

Figure 5 Pathological HE staining under different magnification and expression of key immunohistochemical molecules

(A)病理HE染色示可见疏松纤维组织间见分化幼稚的小圆细胞弥漫浸润，略称不规则片状或巢状，核型不规则，染色质细，分裂象多见，细胞质稀少，间质小血管丰富，瘤组织间见多灶性不规则片状凝固型坏死；(B)免疫组织化学对诊断关键分子进行验证，CD99强阳性表达，NSE及S-100呈弱阳性表达。

(A) Pathological HE staining showed diffuse infiltration of immature differentiated small round cells in loose fibrous tissues, briefly called irregular sheets or nests, irregular karyotype, fine chromatin, frequent mitotic images, rare cytoplasm, abundant small vessels in the stroma, and multi-focal irregular sheets of coagulation necrosis in tumor tissues; (B) key molecules of diagnosis were verified by immunohistochemistry, CD99 was strongly positive, while NSE and S-100 were weakly positive.

2 讨论

EES最早由Tefft于1969年描述，并于1975年由Angervall命名[6]。EES是骨尤文氏肉瘤的特殊表现形式，其发病率约为0.6/10万，多发于青少年，常见部位为肢体末端和躯干等，有较高的侵袭性，但在婴儿发病极为罕见[7-10]。该病有较强的侵袭性，预后差，而且术前明确诊断率很低[11]。EES多起源于软组织深部，影像学表现缺乏特异性，诊断困难，容易被误诊，X线检查意义不大，CT平扫呈中等密度，增强扫描明显强化，其内可见片状低密度坏死。MRI成像T1呈中等信号，可见小片状坏死，T2呈中等偏高信号，增强扫描可见明显强化，边界清楚，临近骨质边缘可有破坏，无钙化[12-14]。MRI对于软组织病变诊断具有很大优势，能辨别肿物与周围血管、神经关系，为手术切除具有一定的指导意义[15]。但对于该病的确诊有赖于手术切开或穿刺活检行病理学检查，这是诊断的金标准。EES为小圆细胞肿瘤，瘤细胞形态一致，细胞质少，染色浅，胞膜不清楚。细胞核呈圆形或椭圆形，颗粒细，分布均匀，核分裂相多见，瘤组织内细胞丰富，细胞排列成巢状[16]。90%以上EES表面抗原MIC2(CD99)阳性，是32-kD膜糖蛋白，参与细胞黏附、迁移和凋亡机制，也可见于部分滑膜肉瘤、黑色素瘤等[17]。EES多数表达FLI-1，该抗原见于造血细胞和内皮细胞，并参与细胞增殖和肿瘤形成过程[17]。该患者病理HE染色示可见疏松纤维组织间见分化幼稚的小圆细胞弥漫浸润，略称不规则片状或巢状，核型不规则，染色质细，分裂象多见，细胞质稀少，间质小血管丰富，瘤组织间见多灶性不规则片状凝固型坏死。免疫组织化学示CD99强阳性表达，NSE及S-100弱表达。

EES治疗仍以手术切除为主，对于早期诊断明确的患者行放化疗也很敏感[18]。放疗的实施必须考虑肿瘤周围组织和器官的耐受性，尽可能减少对周围正常组织的损伤。术后化疗对抑制病情的发展和提高5年生存率都有积极的作用[19]。目前较公认的化疗方案有VAC方案(VCR+ADM+CTX)和ICE方案(IFO+DDP+VP-16)或二者交替，具体剂量及周期数与疗效尚无明确的效应关系，一般依据患者化疗后影像学所示肿瘤大小的变化而定[20]。对于婴儿骨外尤文肉瘤治疗几乎无报道，我国曾有作者[21]报道过1例婴儿尤文肉瘤患者，文中表明术后给予化疗，但没明确具体化疗方案。国外有研究[22]报道1例肩部尤文肉瘤婴儿，术前未行

放化疗，术后肿瘤复发。复发后再次手术并术后化疗，化疗几天后因重度呼吸衰竭而死亡。最新NCCN指南提出[23]：尤文肉瘤家族肿瘤患者应给予以下治疗方案：基础治疗后进行局部控制治疗和辅助治疗。基础治疗包括术前多药联合化疗至少9个周期，转移性尤文肉瘤患者可根据肿瘤对化疗反应敏感度可持续更长时间化疗，VAC/IE是首选方案。局部控制治疗包括广泛切除，精准放疗及灌注化疗，选择性截肢。广泛切除或截肢术后的辅助化疗强调所有患者无论手术切缘阴性与否，强烈建议术后化疗时间需持续28~49周，这个取决于患者生活状态和治疗剂量。推荐对于切缘R1及R2，或肿瘤距离切缘很近的患者使用术后放疗联合化疗。EES5年和10年生存率分别为69.7%和65.2%，影响EES的预后因素尚未明确。对于骨外尤文肉瘤，患者年龄、切缘是否达到R0、有无微转移灶、及肿瘤细胞是否扩散是影响预后的主要因素[22,24]。预后不良的指标为肿瘤体积大(>200 mL)、组织学不典型、转移灶、p16表达缺失、1q和12号染色体增多[24]。

针对该婴儿，术后病理检查结果提示恶性肿瘤后至专科医院求进一步治疗。仔细分析其诊疗过程，诸多不规范之处值得大家高度重视。首先，当影像学表现提示肿瘤病变，应先行穿刺或切开取活组织检查明确诊断，待病理检查确定后再行规范化治疗，当为恶性肿瘤时，一定要明确扩大彻底切除肿瘤的重要性。其次，在未明确病理检查前行肿瘤切除，要考虑是否达到有效切缘。对该患儿复查MRI发现局部仍有瘤组织残留，故行瘤床广泛切除。最后，要重视术后辅助治疗的重要性。在对该患儿实施扩大切除前评估无远处转移，建议术后辅助放化疗，但被患者家属拒绝，尽管风险极高，且无相关放化疗指南或共识可依，但仍要实施术后辅助治疗。

对于年龄偏小，放化疗风险极高的EES婴儿，手术彻底切除显得尤其重要。鉴于目前对婴儿EES放化疗报道甚少，无相关指南或共识可依，治疗尚处于摸索阶段，仍需大量临床样本进一步研究。EES高度恶性，当放化疗不能进行时，规范化手术治疗对降低复发率和提高生存率至关重要。

参考文献

1. Agarwal P, Bhardwaj M, Choudhary A. Primary intracranial extraosseous CNS Ewing's sarcoma: a distinct entity[J]. J Pediatr Neurosci, 2017, 12(4): 396-397.
2. Mavrogenis AF, Vottis CT, Megaloikonomos PD, et al. Neovascularization in Ewing's sarcoma[J]. Neoplasma, 2018, 65(3): 317-325.
3. Yaprak N, Toru HS, Ozbudak IH, et al. Primary extraskeletal Ewing's sarcoma of the maxillary sinus[J]. Braz J Otorhinolaryngol, 2019, 85(4): 538-541.
4. Saglam M, Ozdemir Y, Yigit T, et al. Ewing's sarcoma of the peritoneum: a rare location for extraskeletal Ewing's sarcoma(Article)[J]. J Gastrointest Surg, 2016, 20 (11): 1918-1919.
5. Loya AC, Prayaga AK, Arora A, et al. Lymph node metastasis of soft tissue tumors[J]. Acta Cytol, 2007, 51(2): 153-160.
6. Lu, Victor M, Goyal, et al. Primary intradural Ewing's sarcoma of the spine: a systematic review of the literature[J]. Clin Neurol Neurosurg, 2019, 177(1): 12-19.
7. Naoki M, Toshiharu S, Ryu T, et al. Limb saving surgery for Ewing's sarcoma of the distal tibia: a case report[J]. BMC cancer, 2018, 18(1): 503.
8. Stevenson JD, Doxey R, Abudu A, et al. Vascularized fibular epiphyseal transfer for proximal humeral reconstruction in children with a primary sarcoma of bone[J]. Bone Joint J, 2018, 100B(4): 535-541.
9. Nair P, Aggarwal V, Kumar K, et al. Calvarial Ewing's sarcoma, a rare childhood tumor: report and a review of literature[J]. Neurol India, 2017, 65(4): 904-906.
10. Evelina M, Rita DV, Andrea C, et al. DNA methylation profiling for diagnosing undifferentiated sarcoma with capicua transcriptional receptor (CIC) alterations[J]. Int J Mol Sci, 2020, 21(5): 1818.
11. Yutaka Y, Masahiro N, Nobutaka S, et al. Pazopanib for recurrent extraosseous Ewing's sarco- ma of the retroperitoneum[J]. Int J Urol, 2014, 21(11): 1183-1184.
12. Valentina DR, Giada DB, Maria DDP, et al. Ectopic ACTH secretion in a child with metastatic Ewing's sarcoma: a case report[J]. Front Oncol, 2020, 10: 574.
13. Douglas JH, Marguerite TP, Hedieh K, et al. PET With 18 F-fluorodeoxyglucose/computed tomography in the management of pediatric sarcoma[J]. PET Clin, 2020, 15(3): 333-347.
14. Bhattacharjee S, Venkata SR, Uppin MS. Skull and spinal Ewing's sarcoma in children: An institutional study[J]. J Pediatr Neurosci, 2018, 13(4): 392-397.
15. Shulman DS, Klega K, Imamovic T, et al. Detection of circulating tumour DNA is associated with inferior outcomes in Ewing sarcoma and osteosarcoma: a report from the Children's Oncology Group[J]. Br J Cancer, 2018, 119(3): 615-621.
16. Scheryll A, Cormac O, Charles G, et al. Survival of childhood and adolescent/young adult (AYA) cancer patients in Ireland during 1994-2013: comparisons by age[J]. Ir J Med Sci, 2020, 189(4): 1223-1236.

17. Yasukage T, Fumitoshi A, Katsuya M, et al. A Case of Ewing sarcoma of the mandible on 18F-FDG PET/CT[J]. Asia Ocean J Nucl Med Biol, 2020, 8(1): 84-87.
18. Dutton P, Love SB, Billingham L, et al. Analysis of phase II methodologies for single-arm clinical trials with multiple endpoints in rare cancers: an example in Ewing's sarcoma[J]. Stat Methods Med Res, 2018, 27(5): 1451-1463.
19. Gisel AB, Natali B, Laura MV, et al. Primary extra-osseous Ewing sarcoma of the dorsal spine with spinal cord compression at diagnosis: Case report[J]. Arch Argent Pediatr, 2019, 117(1): e41-e46.
20. Miller HE, Gorthi A, Bassani N, et al. Reconstruction of Ewing sarcoma developmental context from Mass-Scale transcriptomics reveals characteristics of EWSR1-FLI1 permissibility[J]. Cancers (Basel), 2020, 12(4): 948.
21. 刘双利, 李宝山, 章雪松, 等. 婴儿尤文肉瘤1例[J]. 实用手外科杂志, 2004, 18(3): 137-138.
LIU Shuangli, LI Baoshan, ZHANG Xuesong, et al. A case of infantile Ewing's sarcoma[J]. Journal of Practical Hand Surgery, 2004, 18(3): 137-138.
22. Akçalı M, Yapıcıoğlu H, Akay E, et al. A congenital soft tissue Ewing sarcoma in a newborn patient[J]. Turk J Pediatr, 2017, 59(1): 76-79.
23. Joseph SA, Bhandari R, Albert A, et al. Saving the hand: Role of multimodality therapy for Ewing's sarcoma family tumor of the palm[J]. Adv Radiat Oncol, 2018, 3(2): 205- 208.
24. Nie CL, Ren WH, Ma Y, et al. Circulating miR-125b as a biomarker of Ewing's sarcoma in Chinese children[J]. Genet Mol Res, 2015, 14(4): 19049-19056.

本文引用：马秀才, 买自林, 罗国栋, 绽春蕊, 刘鹏, 俞永智, 宋建民. 婴儿骨外尤文肉瘤1例并文献复习[J]. 临床与病理杂志, 2021, 41(10): 2487-2492. doi: 10.3978/j.issn.2095-6959.2021.10.038
Cite this article as: MA Xiucai, MAI Zilin, LUO Guodong, ZHAN Chunrui, LIU Peng, YU Yongzhi, SONG Jianmin[J]. Extraskeletal Ewing's sarcoma in infant: A case report and literature review. Journal of Clinical and Pathological Research, 2021, 41(10): 2487-2492. doi: 10.3978/j.issn.2095-6959.2021.10.038