

A case of esophageal squamous cell intraepithelial neoplasia with positivity for type 16 human papillomavirus successfully treated with radiofrequency ablation

Alessandro Repici¹, Chiara Genco^{1,2}, Andrea Anderloni¹, Paola Spaggiari³, Rosanna Minieri¹, Alessandra Carlino¹, Manol Jovani¹, Vincenzo Villanacci⁴, Prateek Sharma⁵, Alberto Malesci¹

¹Department of Gastroenterology, IRCCS Istituto Clinico Humanitas, Milan, Italy; ²Department of Gastroenterology, DIBIMIS, University of Palermo, Palermo, Italy; ³Department of Pathology, IRCCS Istituto Clinico Humanitas, Milan, Italy; ⁴Department of Laboratory Diagnostics, Pathology Section, Brescia, Italy; ⁵Department of Gastroenterology and Hepatology, Veterans Affairs Medical Center and University of Kansas School of Medicine, Kansas City, Missouri, USA

Correspondence to: Alessandro Repici. Istituto Clinico Humanitas, Milan, Italy. Email: alessandro.repici@humanitas.it.

Abstract: Esophageal cancer is the eight most common cancer worldwide and the sixth cause of cancer related death with squamous cell carcinoma (SCC) accounting for almost half of all esophageal cancers. Persistent human papilloma virus (HPV) infection has been suspected to play an active role in esophageal carcinogenesis but a clear association has not still been proven and no specific indications or guidelines for possible endoscopic and surgical therapeutic approaches to this clinical scenario are available. We report a case of a 62-year-old woman with histological diagnosis of high-grade intraepithelial squamous neoplasia of distal esophagus associated with cytological modifications resembling cervical HPV infection and with a positive INNO-LiPA assay for genotype 16 HPV. A single session of radiofrequency ablation (RFA) was performed on the dysplastic esophageal area with complete endoscopic eradication as confirmed by the following endoscopic, histologic and microbiologic examinations. Our report might give further strength to the hypothesis of an etiological role of HPV in selected cases of esophageal carcinogenesis and opens a discussion on the possible use of Radio Frequency Ablation as an effective and safe endoscopic treatment for both early squamous cell neoplasia and HPV esophageal colonization.

Keywords: Esophagus; squamous cell neoplasia; human papilloma virus (HPV); radiofrequency ablation (RFA)

Submitted Feb 06, 2014. Accepted for publication Mar 04, 2014.

doi: 10.3978/j.issn.2078-6891.2014.005

View this article at: <http://www.thejgo.org/article/view/2327/2910>

Introduction

Esophageal cancer is the eighth most common cancer worldwide and the sixth cause of cancer related death (1-3). Squamous cell carcinoma (SCC) is the leading pathological type with mean rates of incidence of 2.5-5/100.000 cases among men and 1.5-2.5 cases among women but higher incidence rates are reported in high risk countries such as China, Iran, South Africa and France (4,5).

Principal risk factors for its development are alcohol consumption, smoking, nutritional deficiencies and physical injuries but several studies have evaluated the possible association with infections (6). The role of human papilloma

virus (HPV) has been investigated with controversial results. Persistent HPV infection has been detected in benign esophageal squamous cells tumors (4) but there are no studies proving a clear causal association between HPV infection and cancer. Since 1982 at least 70 studies have reported detection rates of HPV in esophageal SCC ranging from 0% to 67% (7) with viral type 16 being the most common (8,9).

Given the lack of evidence regarding the significance of HPV in esophageal SCC, no specific indications or guidelines for possible endoscopic and surgical therapeutic approaches to this clinical scenario are available.

European Organization for Research and Treatment of

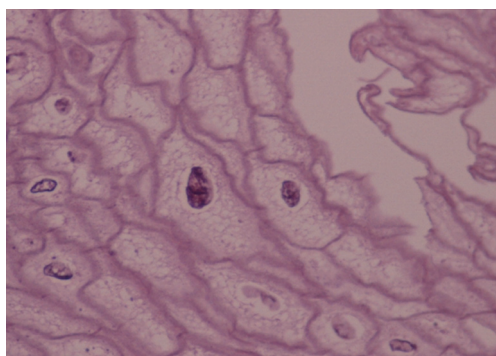


Figure 1 Focal koilocytosis of squamous esophageal epithelium with nuclear abnormalities and perinuclear halos (E & E 400×).

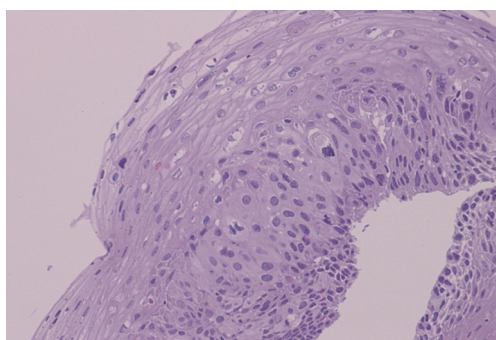


Figure 2 High grade intraepithelial neoplasia of squamous esophageal epithelium with nuclear polymorphism and mitotic figures (E & E 200×).

Cancer (EORTC) treatments strategies for esophageal SCC suggest the use of endoscopic mucosal resection (EMR) and endoscopic submucosal dissection (ESD) in early cancers with exclusive mucosal involvement with more aggressive surgical approaches indicated in those cases in which submucosal invasion is present (10).

Radiofrequency ablation (RFA) is an endoscopic technique that is currently used for the treatment of flat high-grade dysplasia in Barrett's esophagus (11). Recently it has also been evaluated in the setting of esophageal SCC in small prospective studies (12-14).

We report a case of esophageal SCC *in situ* with histologic and microbiologic findings of genotype 16 HPV infection successfully treated with a single session of RFA.

Case report

In November 2011, a 62-year-old white woman was referred to our unit because of dyspeptic syndrome. Past history

included hypothyroidism treated with L-thyroxine, Irritable Bowel Syndrome and Gastroesophageal Reflux Disease managed with PPIs. Upper gastrointestinal endoscopy (UGIE) revealed the presence of a dyschromic area of about 2 cm in diameter which was located 30 cm from the incisors. Lugol staining confirmed the presence of an unstained area of about 30 mm involving half of the esophageal circumference. Histologic examination showed the presence of cytoarchitectural atypias of squamous epithelium with atypical mitosis, enlarged nuclei with nuclear alterations and parakeratotic hyperkeratosis (Figure 1). Specifically the presence of koilocytosis, giant and multinucleated cells, associated with hyperkeratosis, acanthosis, and koilocytic-like modifications suggested the possible association with an HPV infection. In March 2012 a second UGIE with multiple biopsies of the targeted area and the entire length of esophagus was performed. Histologic diagnosis of high grade intraepithelial neoplasia (HGIEN sec. WHO) was confirmed in biopsy samples obtained from the unstained area (Figure 2). Immunohistochemical staining for CMV and HSV were negative as well as histochemical PAS staining for fungal colonization. Assessment with INNO-LiPA assay for HPV revealed positivity for genotype 16 HPV only in the biopsies obtained from the HGIEN area (Figure 3A). The same test for HPV was negative in the remaining biopsies from the rest of esophagus. In April 2012 a session of RFA (RFA; HALO⁹⁰ System, GI Solutions, Covidien, Sunnyvale, Calif) on the dysplastic esophageal area was performed. There were no complications during or after the procedure. An UGIE with Lugol staining was repeated after two months: a whitish semi-circumferential area suggestive of scarring was detected in the middle esophagus at the site of prior ablation, but no signs of dysplasia were evident. Microbiologic evaluation with INNO-LiPA assay excluded the persistence of HPV infection (Figure 3B). The same result was confirmed in the following UGIEs with biopsies performed in October 2012 and April 2013.

Discussion

HPV is a DNA virus whose association with anogenital and head and neck cancer has been clearly identified (15,16). HPV may be often detected in the squamous epithelium of the esophagus and is considered to be related to the appearance of benign lesions with no risk of progression. Several studies have tried to identify a potential role of HPV in esophageal SCC carcinogenesis but results have been non-conclusive yet (4). The first peculiar finding of




Figure 3 INNO-LiPA HPV genotyping extra. (A) HPV 16 detected in esophageal biopsy from High Grade Intraepithelial Neoplasia area; (B) HPV 16 not detected in esophageal biopsy after three months from radiofrequency ablation. HPV, human papilloma virus.

our case report is that the presence of HPV was suspected on the basis of the histologic similarities between tissue from the neoplastic esophageal lesion and tissues from typical HPV related cervical neoplasms. Interestingly, HPV infection was then confirmed by microbiologic assays exclusively in the areas with neoplastic changes but not in the surrounding healthy esophageal epithelium. Moreover the most virulent HPV genotype was identified, which may have been associated with neoplastic progression of this HPV-related esophageal lesion. The second point of interest in this case is the efficacy of a single course of RFA on neoplastic change and HPV infection as well. Biopsy specimens from three subsequent endoscopic exams have demonstrated a complete histological response with absence of residual dysplasia and eradication of HPV colonization.

Some small prospective studies have already suggested the potential role of RFA in patients with early squamous cell neoplasia of the esophagus but this therapeutic approach has never been evaluated in the setting of controlled trials (12-14). Our experience supports this possible new use of the HALO⁹⁰ RFA procedure in patients with superficial early squamous cell neoplasia, suggesting the treatment can be effective with potential lower complications rates than more invasive techniques such as EMR, ESD and esophagectomy. Moreover, since the etiologic role of HPV in esophageal carcinogenesis is uncertain, our case may facilitate discussion regarding the appropriateness of regular endoscopic follow-up in patients with HPV esophageal colonization and of eventual prophylactic treatment of benign HPV-related lesions. Further investigations are warranted.

Acknowledgements

Disclosure: The authors declare no conflict of interest.

References

1. Kamangar F, Dores GM, Anderson WF. Patterns of cancer incidence, mortality, and prevalence across five continents: defining priorities to reduce cancer disparities in different geographic regions of the world. *J Clin Oncol* 2006;24:2137-50.
2. Jemal A, Bray F, Center MM, et al. Global cancer statistics. *CA Cancer J Clin* 2011;61:69-90.
3. Ferlay J, Shin HR, Bray F, et al. Estimates of worldwide burden of cancer in 2008: GLOBOCAN 2008. *Int J Cancer* 2010;127:2893-917.
4. Syrjänen KJ. HPV infections and oesophageal cancer. *J Clin Pathol* 2002;55:721-8.
5. Pennathur A, Gibson MK, Jobe BA, et al. Oesophageal carcinoma. *Lancet* 2013;381:400-12.
6. Lambert R, Hainaut P. Esophageal cancer: cases and causes (part I). *Endoscopy* 2007;39:550-5.
7. Dąbrowski A, Kwaśniewski W, Skoczylas T, et al. Incidence of human papilloma virus in esophageal squamous cell carcinoma in patients from the Lublin region. *World J Gastroenterol* 2012;18:5739-44.
8. Dillner J, Knekt P, Schiller JT, et al. Prospective seroepidemiological evidence that human papillomavirus type 16 infection is a risk factor for oesophageal squamous cell carcinoma. *BMJ* 1995;311:1346.
9. Han C, Qiao G, Hubbert NL, et al. Serologic association

- between human papillomavirus type 16 infection and esophageal cancer in Shaanxi Province, China. *J Natl Cancer Inst* 1996;88:1467-71.
10. Lutz MP, Zalcberg JR, Ducreux M, et al. Highlights of the EORTC St. Gallen International Expert Consensus on the primary therapy of gastric, gastroesophageal and oesophageal cancer - differential treatment strategies for subtypes of early gastroesophageal cancer. *Eur J Cancer* 2012;48:2941-53.
 11. Bennett C, Vakil N, Bergman J, et al. Consensus statements for management of Barrett's dysplasia and early-stage esophageal adenocarcinoma, based on a Delphi process. *Gastroenterology* 2012;143:336-46.
 12. Bergman JJ, Zhang YM, He S, et al. Outcomes from a prospective trial of endoscopic radiofrequency ablation of early squamous cell neoplasia of the esophagus. *Gastrointest Endosc* 2011;74:1181-90.
 13. van Vilsteren FG, Alvarez Herrero L, Pouw RE, et al. Radiofrequency ablation for the endoscopic eradication of esophageal squamous high grade intraepithelial neoplasia and mucosal squamous cell carcinoma. *Endoscopy* 2011;43:282-90.
 14. Becker V, Bajbouj M, Schmid RM, et al. Multimodal endoscopic therapy for multifocal intraepithelial neoplasia and superficial esophageal squamous cell carcinoma - a case series. *Endoscopy* 2011;43:360-4.
 15. Syrjänen S. The role of human papillomavirus infection in head and neck cancers. *Ann Oncol* 2010;21 Suppl 7:vii243-5.
 16. Zandberg DP, Bhargava R, Badin S, et al. The role of human papillomavirus in nongenital cancers. *CA Cancer J Clin* 2013;63:57-81.

Cite this article as: Repici A, Genco C, Anderloni A, Spaggiari P, Minieri R, Carlino A, Jovani M, Villanacci V, Sharma P, Malesci A. A case of esophageal squamous cell intraepithelial neoplasia with positivity for type 16 human papillomavirus successfully treated with radiofrequency ablation. *J Gastrointest Oncol* 2014;5(2):E36-E39. doi: 10.3978/j.issn.2078-6891.2014.005