



# Clinical efficacy and safety of 3D vascular reconstruction combined with 3D navigation in laparoscopic hepatectomy: systematic review and meta-analysis

Jihua Jiang<sup>1#</sup>, Lei Pei<sup>2#</sup>, Renya Jiang<sup>1</sup>

<sup>1</sup>Department of Hepatobiliary Surgery, The Quzhou Affiliated Hospital of Wenzhou Medical University, Quzhou People's Hospital, Quzhou, China;

<sup>2</sup>Department of Radiology, The Quzhou Affiliated Hospital of Wenzhou Medical University, Quzhou People's Hospital, Quzhou, China

**Contributions:** (I) Conception and design: J Jiang; (II) Administrative support: R Jiang; (III) Provision of study materials or patients: L Pei; (IV) Collection and assembly of data: R Jiang; (V) Data analysis and interpretation: All authors; (VI) Manuscript writing: All authors; (VII) Final approval of manuscript: All authors.

<sup>#</sup>These authors contributed equally as co-first authors.

**Correspondence to:** Renya Jiang. Department of Hepatobiliary Surgery, The Quzhou Affiliated Hospital of Wenzhou Medical University, Quzhou People's Hospital, 100 Minjiang Dadao, Smart New Town, Quzhou 324000, China. Email: jiangrenya2021@163.com.

**Background:** Meta-analysis was used to compare the difference between 3D reconstruction technology and 2D computed tomography (CT) before surgery for primary hepatic carcinoma (PHC) and to systematically evaluate the application value of 3D vascular reconstruction and 3D navigation technology in guiding precise liver resection for PHC. However, there are still many controversies in this aspect, and there are no clear conclusions on the effectiveness and safety of three-dimensional vascular reconstruction combined with three-dimensional navigation in laparoscopic hepatectomy. Therefore, it is necessary to systematically review the results of previous studies with meta method in this study to determine their clinical efficacy and complications and guide clinical treatment.

**Methods:** We used the Cochrane Library, PubMed, Embase, Chinese Biomedical Literature Database (CBM), China National Knowledge Infrastructure (CNKI), Chinese Science and Technology Periodicals Full-Text Database (VIP), and Wanfang database to conduct an online search for data from randomized controlled trials of preoperative 3D reconstruction versus conventional CT in hepatectomy published up to October 2021. Relevant literature was selected based on the inclusion criteria, data was extracted, and quality evaluation of the included literature was carried out.  $I^2$  test was used to evaluate heterogeneity among the studies, and Cochrane risk of bias 2.0 was used to evaluate the studies.

**Results:** A total of 16 studies were included in this study. Meta-analysis showed that there were statistically significant differences between the 3D vascular reconstruction group and conventional surgery group in operation time [mean differences (MD) = -40.10, 95% confidence interval (CI): -74.94, -5.26,  $P=0.02$ ,  $I^2=78\%$ ,  $Z=2.26$ ] and intraoperative blood loss (MD = -50.40, 95% CI: -62.93, -37.86,  $P<0.00001$ ,  $I^2=9\%$ ,  $Z=7.88$ ), but no statistically significant difference was found in total days in hospital (MD = -0.39, 95% CI: -1.81, 1.03,  $P=0.59$ ,  $I^2=76\%$ ,  $Z=0.54$ ), and postoperative complications rate (OR = 0.98, 95% CI: 0.64, 1.50,  $P=0.91$ ,  $I^2=0\%$ ,  $Z=0.11$ ).

**Discussion:** Preoperative 3D reconstruction plays an important role in preoperative evaluation and surgical planning, which improves the operation time of PHC and reduces the intraoperative blood loss, but no effect to length of stay in hospital or complication rate comparing to conventional 2D techniques.

**Keywords:** 3D navigation; laparoscopic hepatectomy; systematic review; meta-analysis

Submitted Jan 21, 2022. Accepted for publication Jun 16, 2022.

doi: 10.21037/jgo-22-198

View this article at: <https://dx.doi.org/10.21037/jgo-22-198>

## Introduction

Primary hepatic carcinoma (PHC) is a malignant tumor occurring in liver cells or intrahepatic bile duct cells (1). Ranked fifth for incidence among global malignant tumors, PHC is one of the most common malignant tumors clinically and the third leading cause of cancer-related death. The annual number of new PHC cases in China accounts for more than 50.0% of the global number of cases (2). With an increasing number of PHC cases, the optimization of PHC treatment planning has become a focus of research at home and abroad (3). At present, individualized comprehensive treatment based on PHC stage is the main principle for managing PHC, with surgery the most important method (4). However, only 10–20% tumors are resectable at diagnosis, and 5-year survival is low in patients with PHC compared to other gastrointestinal malignancies. Despite this, surgical treatment remains the main treatment method for PHC. In recent years, the concept of precise liver resection has been undergoing continuous development. Its goal is to completely remove the lesion while minimizing intraoperative bleeding and maximizing the remaining liver volume and function (5). In liver surgery, complicated liver structure and anatomic variation, anatomical location, size and number of tumors, and tumor invasion of the portal vein, hepatic vein, and other blood vessels increase the difficulty of PHC surgery. Therefore, it is particularly important to plan and evaluate the safety of liver cancer surgery before it is performed (6).

Although traditional 2D computed tomography (CT) images can provide rough image data on PHC lesions and the duct system, they cannot provide sufficient detailed information of the resection scope and surgical path for PHC surgical planning. For complicated PHC cases, the surgical plan can always be determined during surgery. In 3D reconstruction technology, the CT images are used to build 3D models. Compared with traditional 2D images, 3D reconstruction can present an individualized liver structure model which clearly shows the liver anatomical structure and spatial relationships, providing multiangle observation of the intrahepatic vascular system, the anatomy construction of the tumor, anatomical variations, the extent of the lesion, and accurate measurement of the spatial relationships with adjacent vascular anatomy. Further, 3D construction displays accurate positioning of lesions and the estimated resection area, as well as postoperative residual liver volume and volume on the edge of the surgical site. Multiangle analysis of the surgical situation and

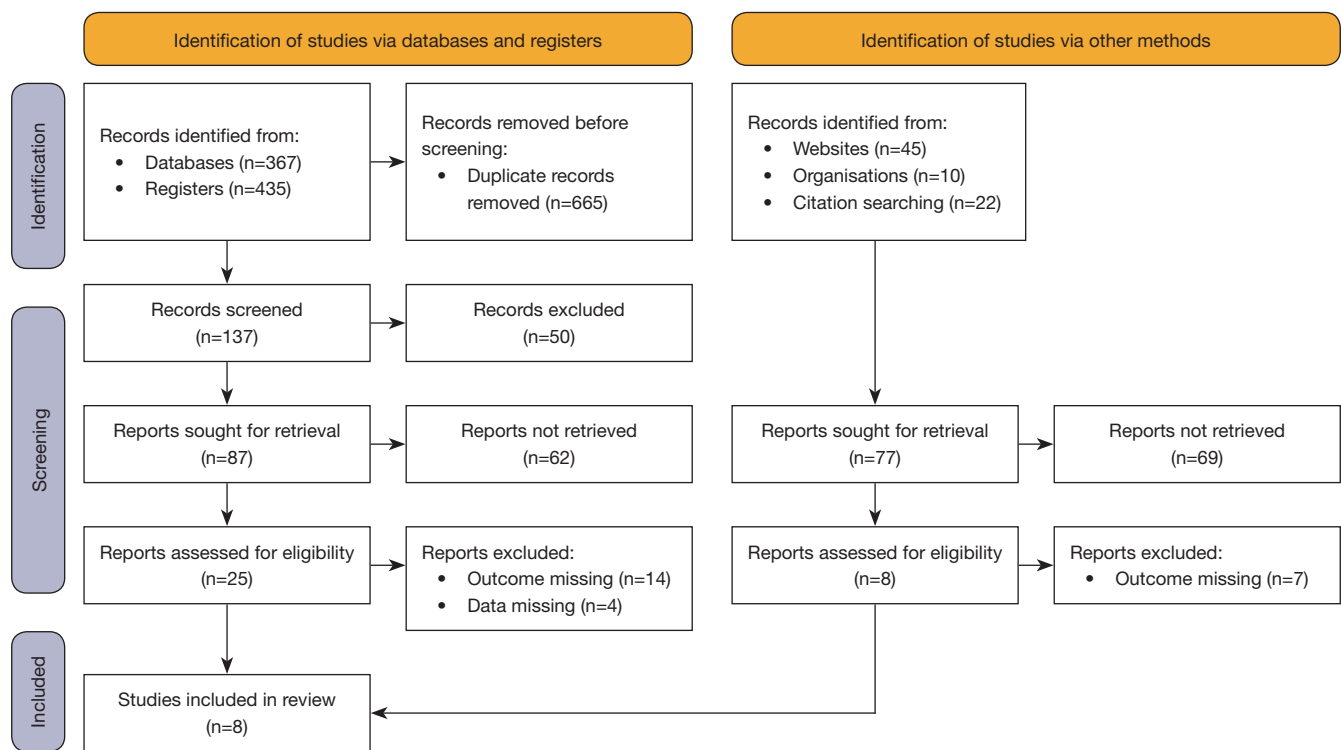
preoperative simulation of surgery plays an important role in the pre-evaluation of precision hepatectomy, providing an anatomical basis for the planning and implementation of precision PHC surgery.

Meta-analysis refers to the application of statistical methods to research data collected for analysis and summary. Meta-analysis can be used to determine the average effect of the combination of independent research results and objectively evaluate the evidence to provide more accurate curative effect evaluation as well as explain the heterogeneity among individual studies. Meta-analysis is based on the PICO (patient/population, intervention, comparison, outcomes) framework to identify research issues, develop search terms, retrieve relevant evidence, and evaluate the quality of literature for each included study in accordance with recognized standards for implementation and extract key research data for systematic analysis. 3D reconstruction can improve the efficacy and safety of PHC, but most of the studies are single-center and small-sample studies, which have certain selection bias and sample bias. Therefore, it is necessary to review and analyze previous relevant studies in this study to clarify the efficacy and safety of 3D reconstruction in improving PHC.

By comparing the 3D reconstruction group with the non-3D reconstruction group, it was found that there were statistically significant differences between the 3D reconstruction group and the non-3D reconstruction group in operation time [(141±36) *vs.* (207±66) min] and blood loss [(274±88) *vs.* (418±189) mL] (7).

Another study included 30 patients in the 3D reconstruction combined with laparoscopic precision hepatectomy group (combined group) and 30 patients in the laparoscopic precision hepatectomy group (control group). The comparison between the combined group and the control group showed that: Compared with the control group, the amount of intraoperative blood loss in the combined group was significantly decreased [(214.49±35.28) *vs.* (379.57±42.89) mL]. The overall incidence of postoperative complications (13.33% *vs.* 43.33%), recurrence and metastasis rate (3.33% *vs.* 20.00%) and mortality rate (3.33% *vs.* 26.67%) were significantly decreased (8).

At present, the application of preoperative 3D reconstruction in PHC surgery (9). However, most of the published clinical studies are single-center and small-sample studies, and there is a lack of multicenter and large-sample randomized controlled trials. Therefore, it is difficult to draw accurate and definite conclusions on the



**Figure 1** Flow chart of literature screening.

clinical efficacy of preoperative 3D reconstruction (10). In this study, meta-analysis was used to compare postoperative indicators of preoperative 3D reconstruction and preoperative 2D CT. Multiple single-center clinical studies were comprehensively analyzed, providing more reliable evidence on the basis of the expanded sample size. We systematically evaluated the application value of 3D reconstruction in PHC surgery and explored its effectiveness in improving postoperative survival rate and reducing postoperative recurrence rate. We present the following article in accordance with the PRISMA reporting checklist (available at <https://jgo.amegroups.com/article/view/10.21037/jgo-22-198/rc>).

## Methods

### Search strategy

We conducted an online search in Cochrane Library, PubMed, Embase, Chinese Biomedical Literature Database (CBM), China National Knowledge Infrastructure (CNKI), Chinese Science and Technology Periodicals Full-Text Database (VIP), Wanfang database and research institutions,

*et al.* for relevant literature. In addition, literature that met the inclusion criteria but was not included in the above databases were obtained using the literature traceability method. All randomized controlled trials on preoperative 3D reconstruction versus conventional CT before PHC surgery published up to October 2021 were retrieved from the databases. The final retrieval strategy was determined according to the PICO framework, along with the guidance and suggestions of third-party personnel. The key words were “3D reconstruction”, “liver cancer” (or primary liver cancer, hepatocellular carcinoma, HCC) and “hepatectomy”. The literature was searched by combining keyword retrieval with free word retrieval. During the retrieval process, the search terms are adjusted according to different databases (Figure 1).

### Inclusion criteria

The inclusion criteria were: (I) randomized controlled trial (RCT) or cohort study design types; (II) study subjects were patients with pathological diagnosis of PHC who underwent surgical treatment for the first time and did not have distant metastasis found through preoperative examination; (III)

the intervention of the experimental group was preoperative CT 3D reconstruction, and the control group was examined by 2D CT; and (IV) outcome indicators were: intraoperative blood loss, operation time, postoperative hospital stay, liver function-related indicators [aspartate aminotransferase (AST), alanine aminotransferase (ALT), and total bilirubin (TBiL)], postoperative complication rate, postoperative early recurrence rate, and postoperative short-term survival rate; (V) All the studies included in this study strictly comply with PICO principles. PICO is a formatted retrieval method based on evidence-based medicine (EBM) theory. Interventions, outcomes. PICO divided each question into four parts: participants who participated in the interventions, or outcomes.

### **Exclusion criteria**

The exclusion criteria were: (I) single-arm studies, case reports, and systematic evaluations; (II) repeated published versions of studies; (III) conference abstracts without full text or incomplete data and clinical trial studies with incomplete data for key studies; (IV) the research object was a special population; and (V) studies that we failed to obtain complete data for after trying various retrieval methods and contacting the authors.

### **Literature screening and data extraction**

The literature was separately screened according to the inclusion and exclusion criteria by 2 experienced researchers. The screening results of the 2 researchers were summarized to obtain the final selection of included literature, and the data were then extracted. If there was any disagreement in the literature screening and data extraction processes, it was resolved through consultation with a third-party expert. If the included literature lacked key data content, an attempt was made to contact the author to obtain the data, and if the data were still unobtainable, the study was excluded.

### **Literature quality evaluation and bias analysis**

Cochrane risk of bias 2.0 was used to evaluate the trials. The literature quality evaluation was conducted separately by 2 people, and the evaluation results were checked. If the evaluation opinions differed, the final quality evaluation grade was determined through consultation with a third-party professional researcher.

### **Statistical analysis**

We performed combined statistical analysis of the included data using RevMan 5.3 software, provided by the Cochrane Collaboration.  $I^2$  statistic was used to test the heterogeneity of each research indicator. The value of  $I^2$  ranges from 0% to 100%. When  $I^2$  equals 0, it indicates that there is no heterogeneity among the research results, and the heterogeneity between the research results is positively correlated with the value of  $I^2$ . When the value of  $I^2$  is less than 50%, slight heterogeneity between studies can be considered. When  $I^2$  is above 50%, it can be considered that there is high heterogeneity among studies. If the heterogeneity was low ( $I^2 < 50\%$ ), the fixed effect model was used for data combination and analysis. If the heterogeneity was high ( $I^2 \geq 50\%$ ), subgroup analysis, sensitivity analysis, and other methods were used to reduce the heterogeneity and analyze the source of heterogeneity, and a random effects model was used for combined analysis of the data.

## **Results**

### **Literature retrieval results and research characteristics of included studies**

The meta-analysis included 249 patients in the preoperative 3D reconstruction group and 283 patients in the traditional 2D CT group. There were 8 studies (11-18) included comparing the operation duration of the 2 groups. The selection flow was shown in *Figure 1*. The basic characteristics and quality evaluation of the 16 included studies are shown in *Table 1*. The risk of bias of the 8 studies were evaluated by Cochrane ROB 2.0, as shown in *Figure 2*.

### **Operation time (min)**

A total of 7 studies were included in this analysis, and statistically significant difference was found between the 3D vascular reconstruction group and conventional surgery group in operation time [mean differences (MD) = -40.10, 95% confidence interval (CI): -74.94, -5.26,  $P=0.02$ ,  $I^2=78\%$ ,  $Z=2.26$ ; *Figure 3*].

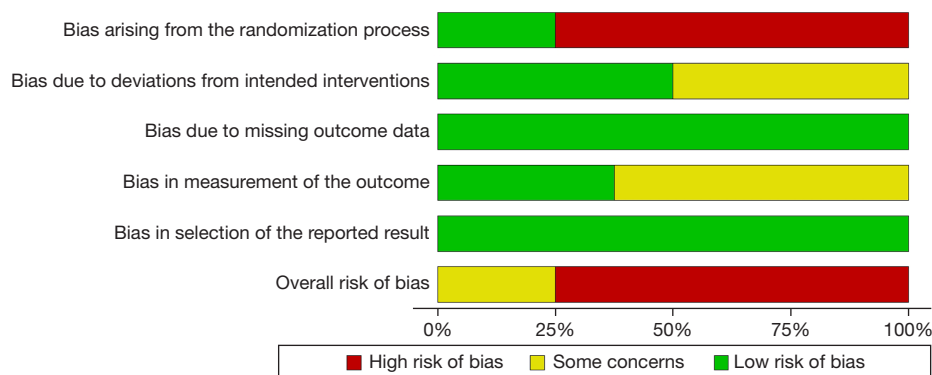
### **Intraoperative blood loss (mL)**

A total of 7 studies were included in this analysis, and statistically significant difference was found between the 3D vascular reconstruction group and conventional surgery

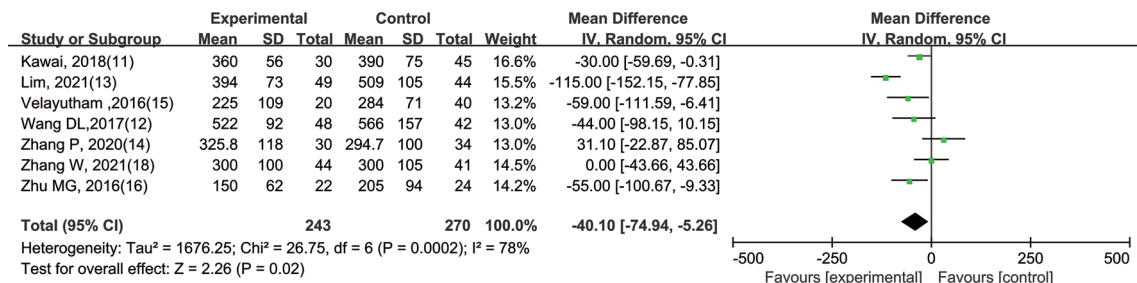
**Table 1** Basic clinical features of the 16 included studies

Study	Age, years	Gender (male)	Disease type	E	C	Research type
Kawai <i>et al.</i> , 2018 (11)	63.71±12.2	41.25%	Primary liver cancer	30	45	Cohort
Wang <i>et al.</i> , 2017 (12)	54.65±12.4	61.11%	Primary liver cancer	48	42	RCT
Lim <i>et al.</i> , 2021 (13)	63.12±14.5	45.72%	Primary liver cancer	49	44	Cohort
Zhang <i>et al.</i> , 2020 (14)	55.7±11.2	81.25%	Liver cancer	30	34	Cohort
Velayutham <i>et al.</i> , 2016 (15)	NR	55.00%	Primary liver cancer	20	40	Cohort
Zhu <i>et al.</i> , 2016 (16)	53.7±13.3	67.39%	Primary liver cancer	22	24	Cohort
Park <i>et al.</i> , 2019 (17)	57.25±16.0	66.34%	Donor	6	13	RCT
Zhang <i>et al.</i> , 2021 (18)	68.12±2.5	66.22%	Primary liver cancer	44	41	Cohort

E, experimental group; C, control group; RCT, randomized controlled trial; NR, not reported.



**Figure 2** Literature quality evaluation chart: risk of bias summary.



**Figure 3** Meta-analysis of operation time. CI, confidence interval.

group in intraoperative blood loss (MD = -50.40, 95% CI: -62.93, -37.86, P < 0.00001, I<sup>2</sup> = 9%, Z = 7.88; Figure 4).

**Total days in hospital (d)**

A total of 6 studies were included in this analysis, and no statistically significant difference was found between the

3D vascular reconstruction group and conventional surgery group in total days in hospital (MD = -0.39, 95% CI: -1.81, 1.03, P = 0.59, I<sup>2</sup> = 76%, Z = 0.54; Figure 5).

**Incidence of postoperative complications**

A total of 7 studies were included in this analysis, and



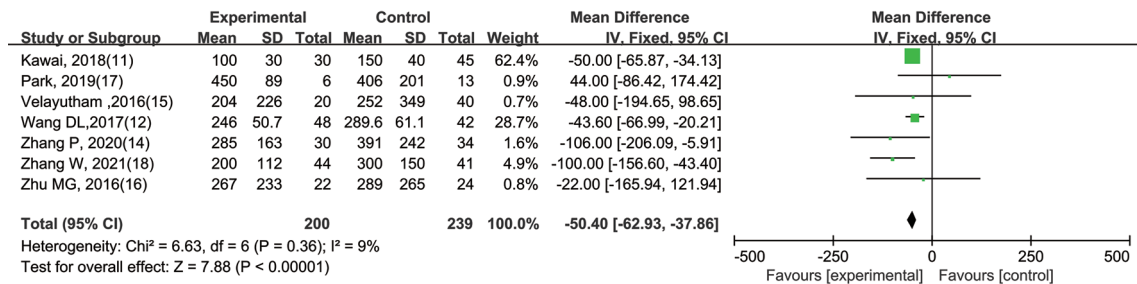


Figure 4 Meta-analysis of intraoperative blood loss. CI, confidence interval.

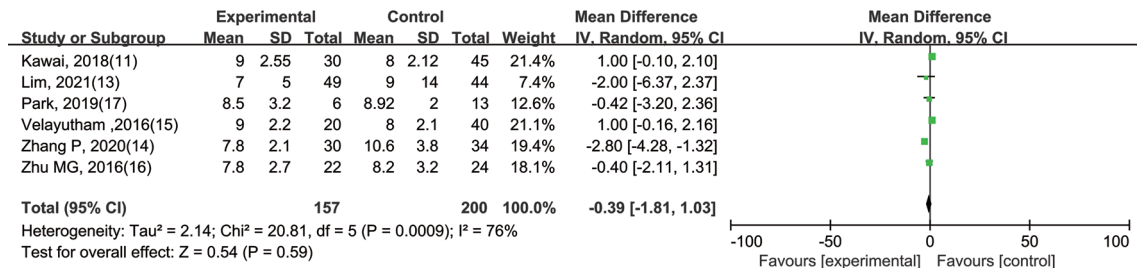


Figure 5 Meta-analysis of total days in hospital. CI, confidence interval.

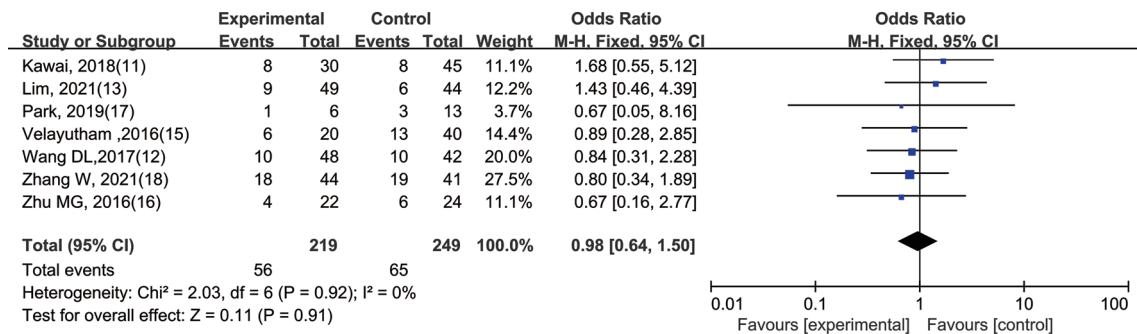


Figure 6 Meta-analysis of incidence of postoperative complications. CI, confidence interval.

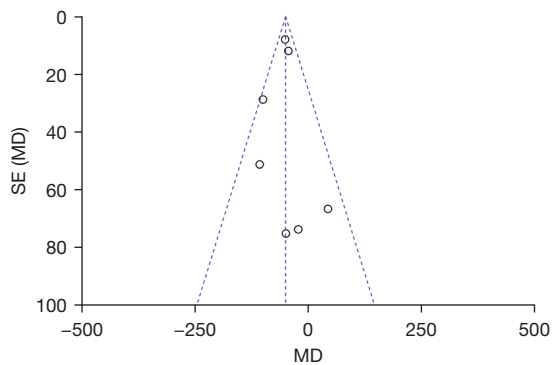
no statistically significant difference was found between the 3D vascular reconstruction group and conventional surgery group in incidence of postoperative complications (OR =0.98, 95% CI: 0.64, 1.50, P=0.91, I<sup>2</sup>=0%, Z=0.11; Figure 6).

**Publication bias**

For the funnel figure of blood loss, the studies distributed evenly under the funnel, which present there was little publication bias, as shown in Figure 7.

**Discussion**

At present, surgery is the main method to treat PHC. Guided by the concept of precision surgery, 3D reconstruction is used to accurately determine and measure the anatomic relationship between PHC lesions and adjacent vessels, providing an anatomic basis for accurate preoperative evaluation, accurate surgical decision, and precise surgical planning of PHC (19). At the same time, the means for obtaining maximum residual liver volume with minimum trauma under precise tumor resection has become a focus of current research (20). However, PHC



**Figure 7** Funnel plots of literature publication bias. Literature publication bias of intraoperative blood loss. SE, standard error.

patients generally have no obvious symptoms in the early stage, and many PHC patients are in the compensatory or decompensated stage of liver failure at the time of diagnosis, with reduced liver function reserve capacity, and the remaining liver volume cannot be accurately estimated before surgery (21,22). Therefore, obtaining fine liver anatomy preoperatively is an important condition for the safety of liver surgery. However, it is difficult to obtain the visual information and images of liver anatomy because of the complex anatomical structure and many anatomical variations of liver vasculature. In addition, complicated PHC is often accompanied by compression and deformation of intrahepatic large vessels and formation of intravascular tumor thrombectomy, which deviates the normal position of liver vessels. Hepatectomy under the guidance of traditional imaging increases the risk of postoperative complications such as liver failure, which is not conducive to rapid recovery after hepatectomy. Therefore, more refined preoperative imaging is a prerequisite to ensure safety and good prognosis in hepatectomy (23).

With the development of digital medical technology, Han *et al.* (24) reported in their study for the first time that 3D liver reconstruction technology was superior to traditional 2D liver imaging technology and could be better used for preoperative PHC location, preoperative disease assessment, and surgical planning. Okumura *et al.* (25) described the clinical use of 3D techniques in liver resection and evaluated the accuracy of 3D visualization techniques to estimate the volume of liver resection.

At present, the use of 3D reconstruction technology in liver surgery is becoming more common. 3D reconstruction technology can create a 3D liver model from CT images,

describing the anatomical relationship between liver vasculature and PHC more intuitively and vividly. More and more studies have shown that surgeons can obtain accurate anatomical location information that cannot be obtained from traditional 2D images that more clearly display the blood vessels and bile duct system of the liver, providing an anatomical basis for accurate preoperative evaluation, surgical planning, and selection of surgical approach in PHC. The reduction of blood vessel damage during the operation and rapid recovery post-operation are beneficial for PHC patients. However, clinical studies published to date are single-center and small-sample studies with low reliability, and there is a lack of multicenter, large-sample studies to guide clinical work. This meta-analysis is expected to further evaluate the clinical effect of 3D reconstruction-guided precision hepatectomy for PHC by combining current published studies to obtain more reliable evidence (26).

This paper had some limitations. The included studies were all RCTs controlled studies with a greater probability of selection bias, which may have affected the value of the meta-analysis conclusions. Most studies did not directly report the hazard ratio (HR) and its 95% CI, and data extracted from survival curves may have been biased from the real data, which may have biased the merged results. The operation level and operation mode of the operator were not completely consistent, which may also have affected the reliability of the results.

Through preoperative 3D reconstruction technology, preoperative planning is undertaken to guide precise liver resection and provide accurate understanding of liver structures and precise tumor localization, offering the advantages of minimal trauma, high safety, and quick postoperative recovery (27). Preoperative 3D reconstruction of PHC resection showing surrounding anatomical structures is beneficial for reducing damage to liver blood vessels during the operation, avoiding intraoperative bleeding during the operation, achieving accuracy of the tumor resection, promoting rapid recovery, reducing postoperative complications and postoperative recurrence rate, and improving long-term survival. It is hoped that more high-quality studies will further explore the clinical value of 3D reconstruction.

### Acknowledgments

**Funding:** This work was funded by the Quzhou City Science and Technology Plan Guiding Project (No. 2019065).

## Footnote

*Reporting Checklist:* The authors have completed the PRISMA reporting checklist. Available at <https://jgo.amegroups.com/article/view/10.21037/jgo-22-198/rc>

*Conflicts of Interest:* All authors have completed the ICMJE uniform disclosure form (available at <https://jgo.amegroups.com/article/view/10.21037/jgo-22-198/coif>). The authors have no conflicts of interest to declare.

*Ethical Statement:* The authors are accountable for all aspects of the work in ensuring that questions related to the accuracy or integrity of any part of the work are appropriately investigated and resolved.

*Open Access Statement:* This is an Open Access article distributed in accordance with the Creative Commons Attribution-NonCommercial-NoDerivs 4.0 International License (CC BY-NC-ND 4.0), which permits the non-commercial replication and distribution of the article with the strict proviso that no changes or edits are made and the original work is properly cited (including links to both the formal publication through the relevant DOI and the license). See: <https://creativecommons.org/licenses/by-nc-nd/4.0/>.

## References

1. Fang C, An J, Bruno A, et al. Consensus recommendations of three-dimensional visualization for diagnosis and management of liver diseases. *Hepatology* 2020;14:437-53.
2. Kresakova L, Danko J, Andrejckova Z, et al. 3D Reconstruction and Evaluation of Accessory Hepatic Veins in Right Hemilivers in Laboratory Animals by Metrotomography: Implications for Surgery. *Med Sci Monit* 2019;25:920-7.
3. Clipet F, Rebibo L, Dembinski J, et al. Portal vein variants associated with right hepatectomy: An analysis of abdominal CT angiography with 3D reconstruction. *Clin Anat* 2019;32:328-36.
4. Kamiyama T, Kakisaka T, Orimo T. Current role of intraoperative ultrasonography in hepatectomy. *Surg Today* 2021;51:1887-96.
5. Wang C, Komminos C, Andersen S, et al. Ultrasound 3D reconstruction of malignant masses in robotic-assisted partial nephrectomy using the PAF rail system: a comparison study. *Int J Comput Assist Radiol Surg* 2020;15:1147-55.
6. Yang T, Lin S, Xie Q, et al. Impact of 3D printing technology on the comprehension of surgical liver anatomy. *Surg Endosc* 2019;33:411-7.
7. Paschold M, Huettl F, Kneist W, et al. Local, semi-automatic, three-dimensional liver reconstruction or external provider? An analysis of performance and time expense. *Langenbecks Arch Surg* 2020;405:173-9.
8. Altomare M, Sposito C, Regalia E, et al. Resection of Retro-Hepatic Vena Cava (RHVC) En-bloc with Caudate Lobe without Vascular Exclusion for a Low Grade Leiomyosarcoma of Inferior Vena Cava. *Ann Surg Oncol* 2021;28:6848-9.
9. Wang T, Li G, Fu Z, et al. Surgical treatment of extensive hepatic alveolar echinococcosis using a three-dimensional visualization technique combined with allograft blood vessels: A case report. *Medicine (Baltimore)* 2020;99:e21336.
10. Au KP, Chan MY, Chu KW, et al. Impact of Three-Dimensional (3D) Visualization on Laparoscopic Hepatectomy for Hepatocellular Carcinoma. *Ann Surg Oncol* 2022;20:1-14.
11. Kawai T, Goumard C, Jeune F, et al. 3D vision and maintenance of stable pneumoperitoneum: a new step in the development of laparoscopic right hepatectomy. *Surg Endosc* 2018;32:3706-12.
12. Wang DL, Qu BH, Hu M, et al. Clinical value of 3D laparoscopic hepatectomy in the treatment of primary liver cancer. *Chinese Journal of General Surgery* 2017;26:13-7.
13. Lim C, Goumard C, Salloum C, et al. Outcomes after 3D laparoscopic and robotic liver resection for hepatocellular carcinoma: a multicenter comparative study. *Surg Endosc* 2021;35:3258-66.
14. Zhang P, Luo H, Zhu W, et al. Real-time navigation for laparoscopic hepatectomy using image fusion of preoperative 3D surgical plan and intraoperative indocyanine green fluorescence imaging. *Surg Endosc* 2020;34:3449-59.
15. Velayutham V, Fuks D, Nomi T, et al. 3D visualization reduces operating time when compared to high-definition 2D in laparoscopic liver resection: a case-matched study. *Surg Endosc* 2016;30:147-53.
16. Zhu MG, Fang ZS, Sun X, et al. Comparative study of 3D laparoscopic and 2D laparoscopic hepatectomy. *Chinese Journal of Clinical Anatomy* 2016;34:96-9, 103.
17. Park K, Shehta A, Lee JM, et al. Pure 3D laparoscopy versus open right hemihepatectomy in a donor with type II and III portal vein variations. *Ann Hepatobiliary Pancreat*



- Surg 2019;23:313-8.
18. Zhang W, Zhu W, Yang J, et al. Augmented Reality Navigation for Stereoscopic Laparoscopic Anatomical Hepatectomy of Primary Liver Cancer: Preliminary Experience. *Front Oncol* 2021;11:663236.
  19. Ju M, Xu F, Zhao W, et al. Efficacy and factors affecting the choice of enucleation and liver resection for giant hemangioma: a retrospective propensity score-matched study. *BMC Surg* 2020;20:271.
  20. Kim JH. Three-Dimensional Ventral Approach with the Modified Liver-Hanging Maneuver During Laparoscopic Right Hemihepatectomy. *Ann Surg Oncol* 2019;26:2253.
  21. Han HS, Cho JY, Kaneko H, et al. Expert Panel Statement on Laparoscopic Living Donor Hepatectomy. *Dig Surg* 2018;35:284-8.
  22. Chong CCN, Lok HT, Fung AKY, et al. Robotic versus laparoscopic hepatectomy: application of the difficulty scoring system. *Surg Endosc* 2020;34:2000-6.
  23. Chen K, Pan Y, Maher H, et al. Laparoscopic hepatectomy for elderly patients: Major findings based on a systematic review and meta-analysis. *Medicine (Baltimore)* 2018;97:e11703.
  24. Han JH, You YK, Choi HJ, et al. Clinical advantages of single port laparoscopic hepatectomy. *World J Gastroenterol* 2018;24:379-86.
  25. Okumura S, Goumard C, Gayet B, et al. Laparoscopic versus open two-stage hepatectomy for bilobar colorectal liver metastases: A bi-institutional, propensity score-matched study. *Surgery* 2019;166:959-66.
  26. Chen HW, Deng FW, Wang FJ, et al. Laparoscopic Right Hepatectomy Via an Anterior Approach for Hepatocellular Carcinoma. *JSLS* 2018;22:e2017.
  27. Cho JY, Han HS, Kaneko H, et al. Survey Results of the Expert Meeting on Laparoscopic Living Donor Hepatectomy and Literature Review. *Dig Surg* 2018;35:289-93.
- (English Language Editor: A. Muijlwijk)

**Cite this article as:** Jiang J, Pei L, Jiang R. Clinical efficacy and safety of 3D vascular reconstruction combined with 3D navigation in laparoscopic hepatectomy: systematic review and meta-analysis. *J Gastrointest Oncol* 2022;13(3):1215-1223. doi: 10.21037/jgo-22-198