



# Nasal alar metastasis of advanced hepatocellular carcinoma misdiagnosed as reactive cutaneous capillary endothelial proliferation in a patient treated with camrelizumab and apatinib: a case report

Jin Liu, Gang Cao, Genshan Zhang, Shuyi Liu, Daqun Shi

Department of Interventional Therapy, The First People's Hospital of Lianyungang, Lianyungang, China

*Contributions:* (I) Conception and design: J Liu, G Cao; (II) Administrative support: J Liu, G Cao, G Zhang; (III) Provision of study materials or patients: J Liu, S Liu; (IV) Collection and assembly of data: J Liu, S Liu, D Shi; (V) Data analysis and interpretation: J Liu; (VI) Manuscript writing: All authors; (VII) Final approval of manuscript: All authors.

*Correspondence to:* Gang Cao, PhD. Department of Interventional Therapy, The First People's Hospital of Lianyungang, No. 6 Zhenhua East Road, Lianyungang 222000, China. Email: caoglyg@163.com

**Background:** Reactive cutaneous capillary endothelial proliferation (RCCEP) is a common adverse event of camrelizumab in the treatment of advanced hepatocellular carcinoma. Facial skin metastasis is an exceptionally uncommon occurrence in hepatocellular carcinoma (HCC). It can be easily mistaken for a prevalent complication known as RCCEP, particularly when it manifests as a persistently enlarging tumor-like mass. This case report highlights a prototypical instance where a metastasis in the nasal alar region of HCC was mistakenly diagnosed as RCCEP during immunotherapy. The findings of this report hold significant clinical value in guiding the management of larger RCCEP lesions encountered during immunotherapy.

**Case Description:** In this case, the patient is a male with a history of hepatitis B. In October 2015, he was diagnosed with HCC. In April 2020, he commenced treatment with ramucirumab (200 mg every 3 weeks) as tumor progression. However, during the third treatment cycle, the patient experienced RCCEP, predominantly affecting the head, neck, trunk, and limbs. To address this, sequential administration of apatinib was initiated, resulting in the gradual regression of RCCEP in these areas. Unfortunately, the metastatic lesion in the nasal alar region continued to grow, exhibiting a tumor-like appearance. On January 25, 2021, surgical resection was performed to remove the nasal alar lesion, and subsequent pathological examination confirmed it as a liver metastasis. Post-surgery, radiation therapy was administered to effectively manage the remaining lesion in the nasal alar region. Importantly, the treatment of the nasal alar metastasis did not hinder the comprehensive management of HCC. The patient obtained excellent curative effect.

**Conclusions:** During the course of immunotherapy for HCC, the emergence of a larger RCCEP lesion that does not show signs of regression even with vigorous treatment raises the suspicion of skin metastasis. It is difficult to distinguish metastatic tumor on the skin from morule- and tumor-like RCCEP that does not easily resolve. To obtain a definitive diagnosis, an early pathological biopsy is crucial. If confirmed as a metastatic tumor, prompt consideration should be given to implementing curative surgical resection.

**Keywords:** Camrelizumab; advanced hepatocellular carcinoma; nasal alar metastasis; apatinib; case report

Submitted Apr 14, 2023. Accepted for publication Jun 16, 2023. Published online Jun 25, 2023.

doi: 10.21037/jgo-23-336

View this article at: <https://dx.doi.org/10.21037/jgo-23-336>

## Introduction

Camrelizumab combined with apatinib has become the main treatment for advanced hepatocellular carcinoma, and its efficacy has been fully recognized. In response, greater attention has been paid to the related adverse events, especially camrelizumab-induced reactive cutaneous capillary endothelial proliferation (RCCEP) which is most commonly found in the head, neck, trunk, and limbs, accounting for approximately 77% of cases, and RCCEP is typically classified into five distinct types: erythematous, pearly, mulberry-like, patchy, and tumor-like (1,2). The most common sites of extrahepatic metastases in advanced hepatocellular carcinoma are the lungs, followed by bone and brain, while metastases to the skin of the nasal alar are rare (3). The occurrence of nasal alar metastasis in hepatocellular carcinoma (HCC) is an extremely rare phenomenon, and there is currently a lack of relevant literature documenting such cases. The treatments for nasal alar metastases and tumor-like RCCEP are different during the application of camrelizumab, and thus differentiating between the two is critical, albeit difficult. We report a misdiagnosed patient who underwent surgical resection of metastasis followed by standardized radiotherapy and achieved complete response (CR). Misdiagnosing nasal alar metastasis as RCCEP can potentially lead to continuous tumor progression, significantly impacting the patient's long-term prognosis. Despite an extensive review of the literature, no previous reports have been found

documenting the misdiagnosis of nasal alar metastasis as RCCEP. Hence, this case report holds exceptional value due to its rarity and unique findings. We present this article in accordance with the CARE reporting checklist (available at <https://jgo.amegroups.com/article/view/10.21037/jgo-23-336/rc>).

## Case presentation

A 68-year-old male patient was admitted to The First People's Hospital of Lianyungang on October 14, 2015, due to the discovery of a liver mass during the physical examination 3 days prior. The patient had a history of hepatitis B virus infection for more than 20 years and was treated with oral entecavir. After admission, contrast-enhanced computed tomography (CT) and Primovist magnetic resonance imaging (MRI) of the abdomen showed that there was an active lesion in both the right and left hepatic lobes, showing "fast in and fast out" after enhancement. No retroperitoneal enlarged lymph nodes were found. Chest CT showed increased lung texture in both lungs. The alpha-fetoprotein (AFP) level was 5.49 ng/mL. The patient was diagnosed with primary hepatocellular carcinoma and chronic viral hepatitis B infection.

From October 17, 2015, to March 10, 2016, transcatheter arterial chemoembolization (TACE) was performed 4 times. On April 26, 2016, CT-guided microwave ablation was performed due to poor control of the right-lobe lesion of the liver. Abdominal enhanced CT performed in follow-up on April 6, 2018, showed a new lesion in the right lobe of the liver. From April 9, 2018, to August 06, 2019, TACE was again performed 4 times, with 3 of these being conventional TACE (c-TACE) and 1 being drug-eluting beads TACE (D-TACE). On September 18, 2019, the re-examination with contrast-enhanced CT of the abdomen and chest showed that the intrahepatic lesions were well controlled, and there was no distant metastasis. On December 25, 2019, the contrast-enhanced MRI of the abdomen showed multiple active intrahepatic lesions and multiple retroperitoneal lymph node metastases. It was recommended that the patient be admitted to the hospital for treatment, but the patient refused. On April 8, 2020, the patient was admitted to the hospital due to back pain and discomfort. The contrast-enhanced MRI of the abdomen showed that intrahepatic metastatic lesions and retroperitoneal lymph node metastases were significantly larger than the previous ones (*Figure 1A-1C*), and chest

### Highlight box

#### Key findings

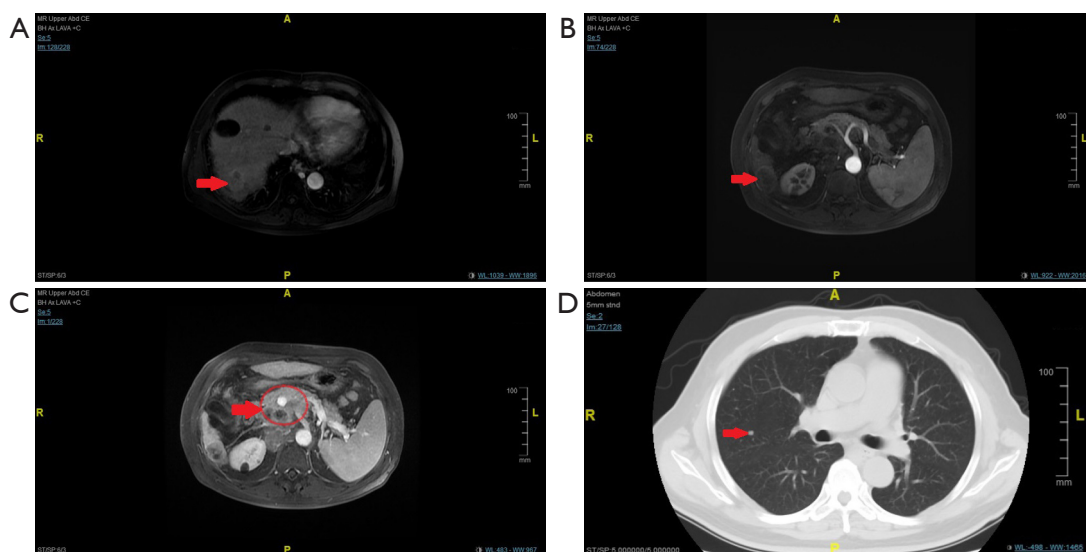
- This case report emphasizes the need to be attentive to the occurrence of RCCEP that perseveres despite treatment with camrelizumab, as this may be metastasis of hepatocellular carcinoma.

#### What is known and what is new?

- RCCEP has been confirmed to be the most common adverse event during camrelizumab monotherapy, but nasal alar metastasis from liver cancer is rare.
- The nasal alar metastasis of hepatocellular carcinoma can be misdiagnosed as RCCEP.

#### What is the implication, and what should change now?

- The treatments for nasal alar metastases and tumor-like RCCEP are different during the application of camrelizumab, and thus differentiating between the two is critical, albeit difficult. Pathological diagnosis is the gold standard in these cases.

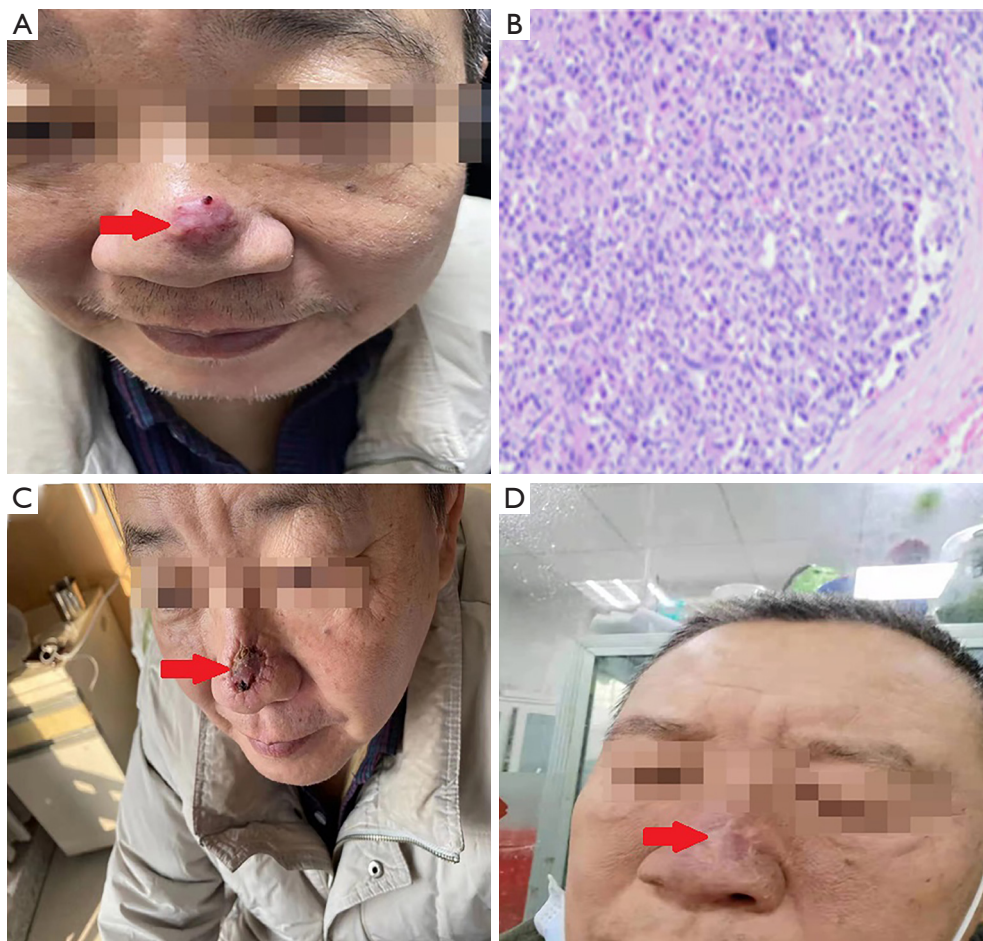


**Figure 1** Contrast-enhanced abdominal MRI and chest CT on April 8, 2020. (A,B) Multiple active intrahepatic lesions (arrows). (C) Multiple retroperitoneal lymph node metastases (red circle). (D) Intrapulmonary metastasis (arrow). A, anterior; P, posterior; R, right; L, left; MRI, magnetic resonance imaging; CT, computed tomography.

CT showed a metastatic lesion in the lung (*Figure 1D*). The clinical stage was IIIb. D-TACE was performed again for the intrahepatic progressive lesions. On April 15, 2020, the first intravenous injection of camrelizumab (200 mg once every 3 weeks) for tumor treatment was performed, and there was no special discomfort after the first administration. During the third medication cycle, the patient developed a bright red punctate rash protruding from the skin surface of the head, neck, trunk, and limbs and was diagnosed with RCCEP. In order to better inhibit the development of tumor and RCCEP, the patient was treated with oral apatinib (250 mg once daily). In the fifth cycle, the symptoms of RCCEP in the head, neck, trunk, and limbs almost disappeared, but the rash on the nasal alar was large and mulberry-like and tended to bleed. Yunnanbaiyao was used to stop the bleeding, and the effect was acceptable.

On December 30, 2020, during the treatment with camrelizumab, the size of the patient's nasal alar lesion continued to increase to about 17 mm × 15 mm, and the lesion assumed a tumor-like shape (*Figure 2A*) and was accompanied by repeated bleeding. The effect of medical hemostasis was poor. Surgical resection was performed on January 25, 2021. Combined with histological morphology, immune markers, and clinical history, postoperative pathology confirmed that the nasal alar lesion was a malignant tumor which had metastasized from the HCC. Cancerous tissue was observed at the basal resection

margin, but none was detected at the surrounding resection margin (*Figure 2B*). Due to the clear diagnosis of metastasis and the presence of cancerous tissue at the basal resection margin, radiotherapy was performed for the residual lesions of the nasal alar on March 3, 2021 (*Figure 2C*). The specific plan was as follows: gross tumor volume (GTV), the tumor bed of nasal alar metastasis; primary GTV (pGTV), GTV + 0.3 cm; 95% PGTV, 6,000 cGy/30 f; and 3F-3DGRT + 2W. The surgical incision was completely healed over 1 month after comprehensive treatment of nasal alar metastasis (*Figure 2D*). As of this writing, the patient has continued to receive periodic camrelizumab and intermittent oral apatinib for antitumor therapy. During the period, 3 sessions of TACE and 1 of microwave ablation were performed depending on the condition of intrahepatic lesions. At the latest re-examination on February 20, 2022, the tumor was assessed as a CR according to the modified Response Evaluation Criteria in Solid Tumors (mRECIST) criteria. Multiple lesions in the liver appeared inactive, and the lung and retroperitoneal lymph nodes metastases had disappeared (*Figure 3*). The nasal alar metastasis has not thus far recurred (*Figure 4*). All procedures performed in this study were in accordance with the ethical standards of the institutional and/or national research committee(s) and with the Declaration of Helsinki (as revised in 2013). Written informed consent was obtained from the patient for publication of this case report and accompanying images.



**Figure 2** Surgical excision, postoperative radiotherapy, and local incision healing of the nasal alar mass. (A) The nasal alar mass appeared to be tumor-like and was about 17 mm × 15 mm in size (arrow). (B) Combined with histological morphology, immune markers, and clinical history, postoperative pathology confirmed that the nasal alar lesion was a malignant tumor that had metastasized from the hepatocellular carcinoma. Cancerous tissue was observed at the basal resection margin, but none was detected at the surrounding resection margin (H1 staining method, 20×10). (C) After radiotherapy, the local tissue of the nasal alar metastasis began to heal (arrow). (D) The surgical incision was completely healed more than 1 month after comprehensive treatment of the nasal alar metastasis (arrow). These images are published with the patient's consent.

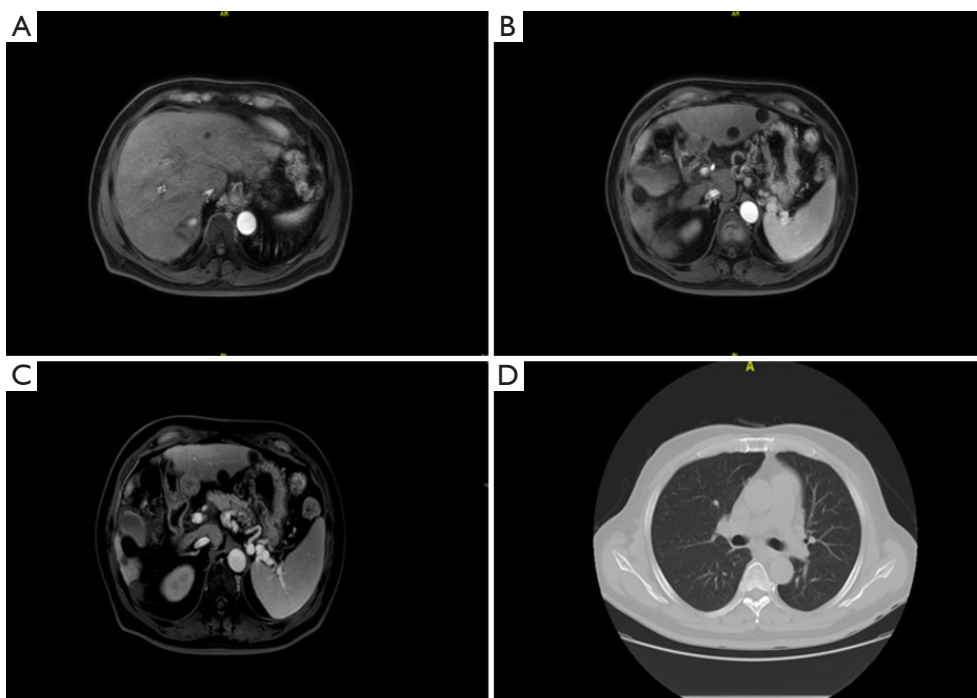
A copy of the written consent is available for review by the editorial office of this journal.

## Discussion

With the development of biomedical technology, systemic therapy has become an important treatment method for advanced HCC in recent years. The main therapeutic drugs are tyrosine kinase inhibitors, programmed cell death receptor 1 (PD-1)/programmed death receptor-1 ligand (PD-L1) inhibitor, and platinum-based chemotherapy. Due to the limited efficacy of a single drug, the combination of 2

or more drugs is recommended.

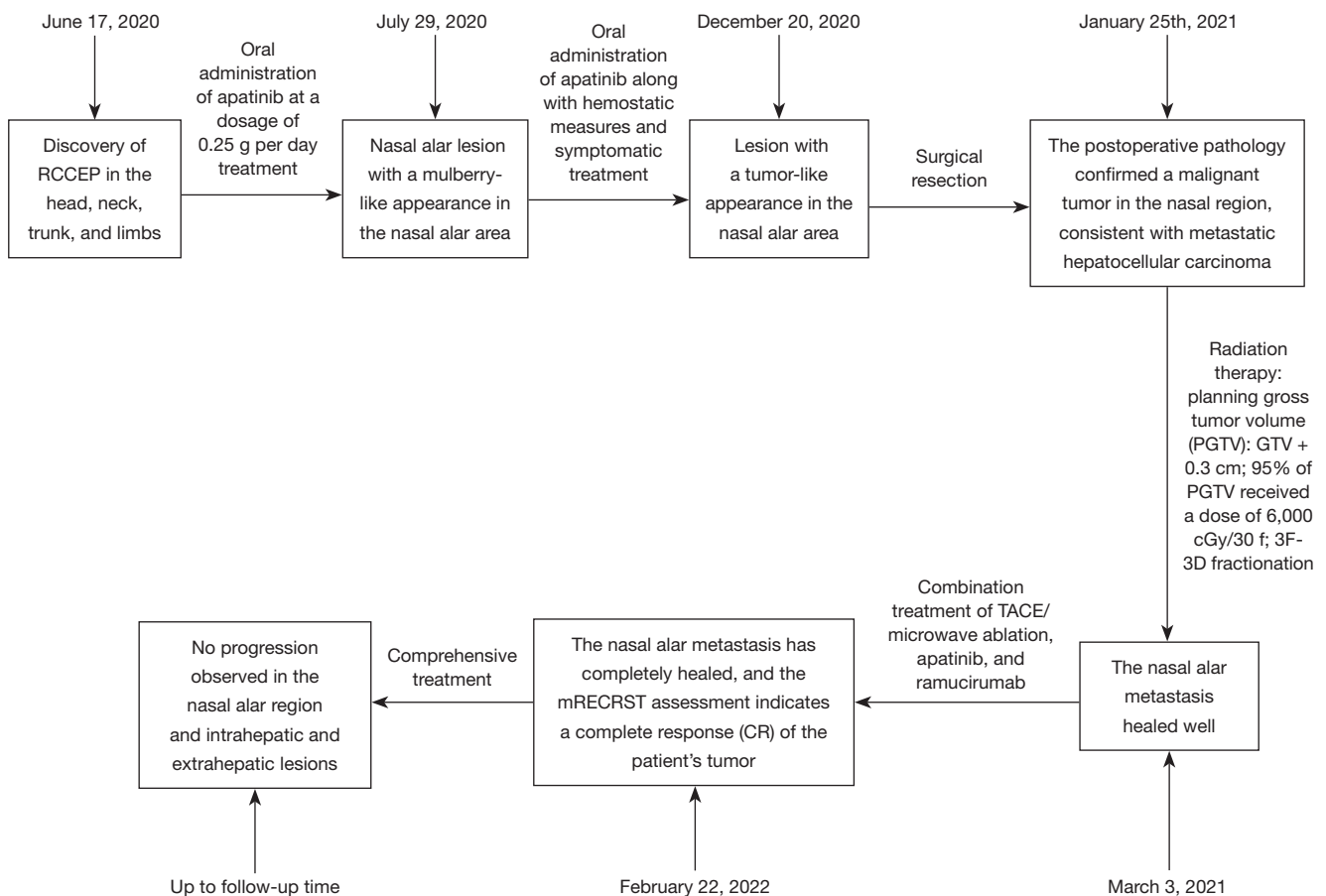
Camrelizumab, a PD-1 monoclonal antibody, was the first drug of its kind to be approved for HCC in China, and its efficacy has been fully validated. In clinical application, RCCEP has been confirmed to be the most common adverse event during camrelizumab monotherapy, with the head, neck, trunk, and limbs being the most common sites for RCCEP (1). RCCEP is usually divided into five types: red-nevus-like, pearl-like, mulberry-like, patch-like, and tumor-like (2). The histopathological manifestations of RCCEP are dermal capillary endothelial hyperplasia and capillary hyperplasia, and no RCCEP-



**Figure 3** Contrast-enhanced abdominal MRI and chest CT on February 20, 2022. (A-C) The imaging showed multiple inactive intrahepatic lesions but no enlarged retroperitoneal lymph nodes. (D) The previous intrapulmonary metastasis had disappeared. MRI, magnetic resonance imaging; CT, computed tomography.

related malignant hyperplasia has been reported thus far (4,5). The pathogenesis of RCCEP is not yet fully understood but may involve the reactivation of the immune response that disrupts the homeostasis between proangiogenic and antiangiogenic factors, resulting in the proliferation of skin capillary endothelial cells (4,6). It has also been shown that (6,7) camrelizumab acts as a vascular endothelial growth factor receptor 2 (VEGFR2) agonist to stimulate angiogenesis and promote the formation of hemangiomas. In the head, neck, trunk, and limbs, this patient developed red-nevus-like and pearl-like RCCEP after the third cycle of camrelizumab, which was consistent with previous reports. Studies have shown that (4,8) apatinib, as a highly selective VEGFR2 inhibitor, can alleviate the clinical symptoms of RCCEP due to its ability to bind to VEGF thus inhibiting the occurrence of RCCEP through blocking signal transduction. In this case, the RCCEP in the whole body subsided significantly after the combination of camrelizumab and apatinib, but the lesion located in the nasal alar gradually became a tumor-like hyperplasia. According to the Chinese Society of Clinical Oncology (CSCO) immune checkpoint inhibitor-related toxicity management guidelines (9), RCCEP in the

nasal alar accompanied by repeated bleeding is classified as grade 2 (moderate), so surgical resection was used. The postoperative pathological result confirmed that this tumor-like hyperplasia was not typical RCCEP but rather a metastatic tumor of HCC—a finding quite different from previous reports. This rare condition might have occurred due to the patient having extensive intrahepatic and extrahepatic metastases before the use of immunotherapy and targeted therapy, and cancer cells were already present in the patient's microcirculatory system. The application of camrelizumab promoted the formation of hemangioma in the nasal alar, which increased blood flow and allowed cancer cells to proliferate in the nasal alar to form metastasis. However, due to the lack of abundant blood supply in the nasal alar and the continuous application of immunotherapy and targeted therapy, the metastasis grew slowly and could not invade the tissue deeply, making it difficult to distinguish it from typical tumor-like RCCEP. The patient received standard radiation therapy after surgery for the nasal alar metastasis, and the incision was completely healed. Later immunotherapy and targeted therapy were not affected, ensuring a good prognosis for the patient.



**Figure 4** Briefly describe the history, treatment, presentation and changing patterns of nasal alar metastasis and RCCEP, pathological findings, treatment for nasal alar metastasis and response, and long-term prognosis of this case. RCCEP, reactive cutaneous capillary endothelial proliferation; TACE, transcatheter arterial chemoembolization; mRECIST, modified Response Evaluation Criteria in Solid Tumors.

## Conclusions

Camrelizumab is an important treatment for advanced primary HCC, and there is no report in the literature of nasal alar metastasis caused by camrelizumab. Sufficient attention should be paid to the occurrence of mulberry-like and tumor-like RCCEP that perseveres on the local skin during the application of camrelizumab.

## Acknowledgments

**Funding:** This study was supported by grants from the Young Talent Project of The First People's Hospital of Lianyungang (No. QN1914) and the Health Science and Technology Project of Lianyungang (No. 202108).

## Footnote

**Reporting Checklist:** The authors have completed the CARE reporting checklist. Available at <https://jgo.amegroups.com/article/view/10.21037/jgo-23-336/rc>

**Peer Review File:** Available at <https://jgo.amegroups.com/article/view/10.21037/jgo-23-336/prf>

**Conflicts of Interest:** All authors have completed the ICMJE uniform disclosure form (available at <https://jgo.amegroups.com/article/view/10.21037/jgo-23-336/coif>). The authors have no conflicts of interest to declare.

**Ethical Statement:** The authors are accountable for all

aspects of the work in ensuring that questions related to the accuracy or integrity of any part of the work are appropriately investigated and resolved. All procedures performed in this study were in accordance with the ethical standards of the institutional and/or national research committee(s) and with the Declaration of Helsinki (as revised in 2013). Written informed consent was obtained from the patient for publication of this case report and accompanying images. A copy of the written consent is available for review by the editorial office of this journal.

*Open Access Statement:* This is an Open Access article distributed in accordance with the Creative Commons Attribution-NonCommercial-NoDerivs 4.0 International License (CC BY-NC-ND 4.0), which permits the non-commercial replication and distribution of the article with the strict proviso that no changes or edits are made and the original work is properly cited (including links to both the formal publication through the relevant DOI and the license). See: <https://creativecommons.org/licenses/by-nc-nd/4.0/>.

## References

1. Ren Z, Qin S, Meng Z, et al. A Phase 2 Study of Camrelizumab for Advanced Hepatocellular Carcinoma: Two-Year Outcomes and Continued Treatment beyond First RECIST-Defined Progression. *Liver Cancer* 2021;10:500-9.
2. Lv JW, Li JY, Luo LN, et al. Comparative safety and efficacy of anti-PD-1 monotherapy, chemotherapy alone, and their combination therapy in advanced nasopharyngeal carcinoma: findings from recent advances in landmark trials. *J Immunother Cancer* 2019;7:159.
3. Traficante D, Assalone P, Tomei F, et al. A case report of HCC cutaneous metastasis. *J Gastrointest Oncol* 2014;5:E65-7.
4. Wang F, Qin S, Sun X, et al. Reactive cutaneous capillary endothelial proliferation in advanced hepatocellular carcinoma patients treated with camrelizumab: data derived from a multicenter phase 2 trial. *J Hematol Oncol* 2020;13:47.
5. Chen X, Ma L, Wang X, et al. Reactive capillary hemangiomas: a novel dermatologic toxicity following anti-PD-1 treatment with SHR-1210. *Cancer Biol Med* 2019;16:173-81.
6. Zhang L, Jiang Y, Xue C, et al. Camrelizumab for the treatment of advanced cervical adenocarcinoma: a case report and literature review. *Ann Transl Med* 2022;10:239.
7. Finlay WJJ, Coleman JE, Edwards JS, et al. Anti-PD1 ‘SHR-1210’ aberrantly targets pro-angiogenic receptors and this polyspecificity can be ablated by paratope refinement. *MAbs* 2019;11:26-44.
8. Wang L, Li X, Cheng Y, et al. Case Report: Addition of PD-1 Antibody Camrelizumab Overcame Resistance to Trastuzumab Plus Chemotherapy in a HER2-Positive, Metastatic Gallbladder Cancer Patient. *Front Immunol* 2021;12:784861.
9. Chinese Society of Clinical Oncology (CSCO). Management of immune checkpoint inhibitor-related toxicity. Beijing: People’s Health Publishing House; 2019:12-15.

(English Language Editor: J. Gray)

**Cite this article as:** Liu J, Cao G, Zhang G, Liu S, Shi D. Nasal alar metastasis of advanced hepatocellular carcinoma misdiagnosed as reactive cutaneous capillary endothelial proliferation in a patient treated with camrelizumab and apatinib: a case report. *J Gastrointest Oncol* 2023;14(3):1643-1649. doi: 10.21037/jgo-23-336